ISSN 2219-2816 (online)

World Journal of *Clinical Urology*

World J Clin Urol 2016 March 24; 5(1): 1-74

Published by Baishideng Publishing Group Inc

WJCU World Journal of Clinical Urology

A peer-reviewed, online, open-access journal of clinical urology

Editorial Board

2016-2019

The *World Journal of Clinical Urology* Editorial Board consists of 201 members, representing a team of worldwide experts in urology. They are from 32 countries, including Australia (2), Austria (1), Belgium (2), Brazil (4), Canada (2), Chile (1), China (19) , Czech Republic (1), Egypt (7), France (3), Germany (7), Greece (7), Hungary (1), India (3), Iran (1), Israel (4), Italy (20), Japan (8), Malaysia (1), Mexico (1), Netherlands (2), Pakistan (3), Portugal (1), Romania (1), Saudi Arabia (3), South Korea (4), Spain (2), Switzerland (1), Thailand (2), Turkey (12), United Kingdom (7), and United States (68).

EDITOR-IN-CHIEF
Makoto Ohori, *Tokyo*

ASSOCIATE EDITOR
Riccardo Schiavina, *Bologna*

GUEST EDITORIAL BOARD MEMBERS
Yen-Ching Chen, *Taipei*
How-Ran Guo, *Tainan*
Kuo-How Huang, *Taipei*
Hung-Hsiang Liou, *Taipei*
Shing-Hwa Lu, *Taipei*
Shih-Bin Su, *Tainan*
Ya-Chung Tian, *Linkou*

MEMBERS OF THE EDITORIAL BOARD

Australia
Nathan Lawrentschuk, *Heidelberg*
Henry H Woo, *Sydney*

Austria
Paul F Engelhardt, *Baden*

Belgium
Dirk PJ Michielsen, *Brussels*
Koenraad Van Renterghem, *Hasselt*

Brazil
Fernando Korkes, *Sao Paulo*
Sonia M Oliani, *Sao Paulo*
Ernani L Rhoden, *Porto Alegre*
Nestor Schor, *Sao Paulo*

Canada
Ben H Chew, *Vancouver*
Fernand Labrie, *Quebec*

Chile
Juan P Valdevenito, *Santiago*

China
Jiang-Hua Chen, *Hangzhou*
Xiang-Mei Chen, *Beijing*
Xue-Zhong Gong, *Shanghai*
Willmann Liang, *Hong Kong*
Xiu-Juan Liu, *Nanchang*
Chi-Fai Ng, *Hong Kong*
Gao Song, *Yangzhou*
Chi-Wai Tang, *Hong Kong*
Yan-Qing Tong, *Changchun*
Gao-Si Xu, Nanchang
Gao-Zhong Xu, Changchun
Yue-Min Xu, Shanghai

Czech Republic
Jiri Sedy, *Prague*

Egypt
Bedeir Ali-El-Dein, *Mansoura*
Sanaa Eissa Mohamed Hamed, *Cairo*
Ahmed MA El-Assmy, *Mansoura*
Ahmed I El-Sakka, *Ismailia*
Ihab A Hekal, *Mansoura*
Salwa I Mohammed, *Cairo*
Hassan S Shaker, *Cairo*

France
Alexandre de la Taille, *Creteil*
Stephane Larre, *Reims Cedex*
Stéphane Oudard, *Paris*

Germany
Michael Froehner, *Dresden*
Oliver W Hakenberg, *Rostock*
Thomas RW Herrmann, *Hanover*
Florian Lang, *Tuebingen*
Daniela Marschall-Kehrel, *Frankfurt*
Axel S Merseburger, *Lübeck*
Hossein Tezval, *Hannover*

Greece
George A Barbalias, *Melissia*
Dimitrios A Kirmizis, *Thessaloniki*
Evangelos N Liatsikos, *Rio Patras*
Aikaterini Papagianni, *Thessaloniki*
Athanasios G Papatsoris, *Athens*
Panagiotis Peitsidis, *Athens*
Giorgos K Sakkas, *Thessaly*

Hungary
Peter Tenke, *Budapest*

India
John Samuel Banerji, *Vellore*
Manisha Sahay, *Hyderabad*
Pratap B Singh, *Delhi*

Iran
Ahmad R Dehpour, *Tehran*

Israel
Juza Chen, *Tel-Aviv*
Ofer N Gofrit, *Jerusalem*
Inna Sinuani, *Zerifin*
Ofer Yossepowitch, *Petah Tiqwa*

Italy
Giuseppe Brisinda, *Rome*
Tommaso Cai, *Trento*
Alessandro Calisti, *Rome*
Stefano Ciatto, *Valeggio sul Mincio*
Elisabetta Costantini, *Perugia*
Paolo Cravedi, *Ranica Bergamo*
Massimiliano Creta, *Naples*
Vassilos Fanos, *Cagliari*
Mariaconsiglia Ferriero, *Rome*
Mauro Gacci, *Firenze*
Fabrizio Gallo, *Savona*
Luigi Mearini, *Perugia*
Angelo Naselli, *Castellanza*
Richard Naspro, *Bergamo*
Antonio L Pastore, *Rome*
Daniele Porru, *Pavia*
Matteo A Russo, *Rome*
Giuseppe Simone, *Rome*
Marco Zaffanello, *Verona*

Japan
Shin Egawa, *Tokyo*
Ryuji Inoue, *Fukuoka*
Yoshinori Marunaka, *Kyoto*
Kaijun Niu, *Sendai*
Hitoshi Oh-oka, *Hyogo*
Sunao Shoji, *Tokyo*
Xiuxian Wu, *Kagawa*

Malaysia
Hatta B Sidi, *Kuala*

Mexico
Rubén GC Patiño, *Mexico City*

Netherlands
Tom PVM de Jong, *Utrecht*
Paul J van Diest, *Utrecht*

Pakistan
Ali AA Lanewala, *Karachi*
Muhammed Mubarak, *Karachi*
Abdul M Rana, *Karachi*

Portugal
Paula A Videira, *Lisbon*

Romania
Cristian P Ilie, *Bucharest*

Saudi Arabia
Khalid A Fouda, *Riyadh*
Khaled Madbouly, *Riyadh*
Mohamed M Sayed-Ahmed, *Riyadh*

South Korea
Young B Jeong, *Jeonju*
Kyu-Sung Lee, *Seoul*
Jae-Seung Paick, *Seoul*
Jong H Park, *Seoul*

Spain
Eduardo García-Cruz, *Barcelona*
Federico Soria, *Caceres*

Switzerland
Martin Spahn, *Bern*

Thailand
Ammarin Thakkinstian, *Bangkok*
Viroj Wiwanitkit, *Bangkok*

Turkey
Ismail C Acar, *Denizli*
Mustafa Arici, *Ankara*
Ugur Boylu, *Istanbul*
Gulgun Engin, *Istanbul*
Saadettin Eskicorapci, *Istanbul*
Ates Kadioglu, *Istanbul*
Cevde Kaya, *Istanbul*
Uner Kayabas, *Malatya*
Mehmet Kilinc, *Konya*
Mustafa Sofikerim, *Kayseri*
Ahmet H Tefekli, *Istanbul*
Faruk H Turgut, *Ankara*

United Kingdom
Hashim U Ahmed, *London*
Linda Cardozo, *London*
Ivo I Donkov, *London*
Nilamadhab Kar, *Wolverhampton*
Evangelos Mazaris, *Huntingdon*
Adrien M Peters, *Brighton*
Prasanna Sooriakumaran, *Oxford*

United States
May Abdel-Wahab, *Coral Gables*
Ashok Agarwal, *Tuscaloosa*
Hossam M Ashour, *Detroit*
Kazem Azadzoi, *Boston*
Jennifer Beebe-Dimmer, *Detroit*
Kailash C Chadha, *Buffalo*
James CM Chan, *Portland*
Yan-Hua Chen, *Greenville*
Shih-Chieh J Chueh, *Cleveland*
Christos E Constantinou, *Stanford*
Eva Corey, *Seattle*
Charles J Diskin, *Opelika*
Roger R Dmochowski, *Nashville*
Michael L Eisenberg, *Houston*
Ahmed R El-Nahas, *Mansoura*
Khurshid R Ghani, *Detroit*
Erik T Goluboff, *New York*
Michael P Goodman, *Davis*
Sanjay Gupta, *Cleveland*
Thomas J Guzzo, *Philadelphia*
Samy L Habib, *San Antonio*
Khaled S Hafez, *Ann Arbor*
Guy Hidas, *Orange*
Pleasant F Hooper, *New Orleans*
Michael H Hsieh, *Stanford*
Mitchell R Humphreys, *Phoenix*
Frank P Hurst, *Washington*
Syed A Imam, *Pasadena*
Debra E Irwin, *Chapel Hill*
James Ji, *Tyler*
Robert P Kauffman, *Amarillo*
Hyung L Kim, *Los Angeles*
Shahriar Koochekpour, *New Orleans*
Adam W Levinson, *New York*
Benyi Li, *Kansas City*
Ruisheng Liu, *Jackson*
Deepak K Malhotra, *Toledo*
Michele Meschia, *Memphis*
Arthur Mourtzinos, *Burlington*
Thomas Nelius, *Lubbock*
George J Netto, *Baltimore*
Macaulay Onuigbo, *Eau Claire*
Robert M Perkins, *Danville*
Michael Perrotti, *New York*
Georgi V Petkov, *Columbia*
Selvarangan Ponnazhagan, *Birmingham*
Raj S Pruthi, *Chapel Hill*
Jules B Puschett, *Temple*
Qi Qian, *Rochester*
Sepehr Salem, *Cleveland*

Jack A Schalken, *Nijmegen*
Joseph I Shapiro, *Toledo*
Shahrokh F Shariat, *New York*
James D Stockand, *San Antonio*
Xin Su, *Minneapolis*
Kevin S Thorneloe, *King of Prussia*
Pradeep Tyagi, *Pittsburgh*
Ulka Vaishampayan, *Detroit*
Robert P Woroniecki, *Bronx*
Paul B Yoo, *Durham*
James J Yoo, *Winston-Salem*
Philip G Zager, *Los Alamos*
Stanley Zaslau, *Morgantown*
Bin-Xian Zhang, *San Antonio*
Jiandong Zhang, *Durham*
Jianjun Zhang, *Indianapolis*
Xin-Jin Zhou, *Dallas*
Shougang Zhuang, *Providence*

WJCU World Journal of Clinical Urology

Contents

Four-monthly Volume 5 Number 1 March 24, 2016

REVIEW

1 Management of penile urethral strictures: Challenges and future directions

Campos-Juanatey F, Bugeja S, Ivaz SL, Frost A, Andrich DE, Mundy AR

MINIREVIEWS

11 Use of synthetic grafts in pelvic reconstruction: A path of continued discovery

Cohen SA, Raz S

18 Bladder cancer exosomes: Getting the message across

Berrondo C, Osinski T, Beckham CJ

24 Cost effectiveness of robot-assisted urologic oncological surgery in the United States

Chen CJ, Humphreys MR

29 Diagnosis of voiding dysfunction by pressure-flow study in women

Valdevenito JP, Walton-Diaz A

37 Chylous ascites in laparoscopic renal surgery: Where do we stand?

Kim BS, Kwon TG

ORIGINAL ARTICLE

Retrospective Cohort Study

45 Adjuvant radiotherapy for pathologically advanced prostate cancer improves biochemical recurrence free survival compared to salvage radiotherapy

Blackwell RH, Gange W, Kandabarow AM, Harkenrider MM, Gupta GN, Quek ML, Flanigan RC

Retrospective Study

53 Perioperative outcomes and survival of radical cystectomy as a function of body mass index

Burge BK, Blackwell RH, Wilson A, Flanigan RC, Gupta GN, Quek ML

60 Robotic-assisted laparoscopic partial nephrectomy: A comparison of approaches to the posterior renal mass

Wetterlin JJ, Blackwell RH, Capodice S, Kliethermes S, Quek ML, Gupta GN

SYSTEMATIC REVIEWS

66 Pre-transplant treatment of large polycystic kidney

Sáez ID, de la Llera JF, Tapia A, Chacón RA, Figueroa PA, Vivaldi BI, Domenech A, Horn CD, Coz F

CASE REPORT

72 Case of intramedullary spinal cord metastasis of renal cell carcinoma

Soga H, Imanishi O

ABOUT COVER

Editorial Board Member of *World Journal of Clinical Urology*, Mehmet Kilinc, MD, Professor, Department of Urology, Meram School of Medicine, Konya 42080, Turkey

AIM AND SCOPE

World Journal of Clinical Urology (*World J Clin Urol*, *WJCU*, online ISSN 2219-2816, DOI: 10.5410) is a peer-reviewed open access academic journal that aims to guide clinical practice and improve diagnostic and therapeutic skills of clinicians.

WJCU covers a variety of clinical medical topics, including genital diseases, urogenital, urogenital abnormalities, urogenital neoplasms, urologic diseases, urogenital surgical procedures, diagnostic imaging, endoscopy, andrology, benign prostatic hyperplasia, urodynamics and urinary dysfunction, incontinence, urinary tract stones, minimally invasive therapy, renal transplantation, urinary reconstruction, evidence-based medicine, and epidemiology.

We encourage authors to submit their manuscripts to *WJCU*. We will give priority to manuscripts that are supported by major national and international foundations and those that are of great clinical significance.

INDEXING/ABSTRACTING

World Journal of Clinical Urology is currently no indexing/abstracting.

FLYLEAF

I-III Editorial Board

EDITORS FOR THIS ISSUE

Responsible Assistant Editor: *Xiang Li*
Responsible Electronic Editor: *Dan Li*
Proofing Editor-in-Chief: *Lian-Sheng Ma*
Responsible Science Editor: *Jin-Xin Kong*
Proofing Editorial Office Director: *Xiu-Xia Song*

NAME OF JOURNAL
World Journal of Clinical Urology

ISSN
ISSN 2219-2816 (online)

LAUNCH DATE
December 28, 2011

FREQUENCY
Four-monthly

EDITOR-IN-CHIEF
Makoto Ohori, MD, Professor, Department of Urology, Tokyo Medical University, 6-7-1 Nishi-shinjuku, Shinjuku-ku, Tokyo 160-0023, Japan

EDITORIAL OFFICE
Jin-Lei Wang, Director
Xiu-Xia Song, Vice Director
World Journal of Clinical Urology
Room 903, Building D, Ocean International Center, No. 62 Dongsihuan Zhonglu, Chaoyang District, Beijing 100025, China
Telephone: +86-10-59080039
Fax: +86-10-85381893
E-mail: editorialoffice@wjgnet.com
Help Desk: http://www.wjgnet.com/esps/helpdesk.aspx
http://www.wjgnet.com

PUBLISHER
Baishideng Publishing Group Inc
8226 Regency Drive,
Pleasanton, CA 94588, USA
Telephone: +1-925-223-8242
Fax: +1-925-223-8243
E-mail: bpgoffice@wjgnet.com
Help Desk: http://www.wjgnet.com/esps/helpdesk.aspx
http://www.wjgnet.com

PUBLICATION DATE
March 24, 2016

COPYRIGHT
© 2016 Baishideng Publishing Group Inc. Articles published by this Open Access journal are distributed under the terms of the Creative Commons Attribution Non-commercial License, which permits use, distribution, and reproduction in any medium, provided the original work is properly cited, the use is non commercial and is otherwise in compliance with the license.

SPECIAL STATEMENT
All articles published in journals owned by the Baishideng Publishing Group (BPG) represent the views and opinions of their authors, and not the views, opinions or policies of the BPG, except where otherwise explicitly indicated.

INSTRUCTIONS TO AUTHORS
Full instructions are available online at http://www.wjgnet.com/bpg/g_info_20160116143427.htm

ONLINE SUBMISSION
http://www.wjgnet.com/esps/

World Journal of Clinical Urology

Submit a Manuscript: http://www.wjgnet.com/esps/
Help Desk: http://www.wjgnet.com/esps/helpdesk.aspx
DOI: 10.5410/wjcu.v5.i1.1

World J Clin Urol 2016 March 24; 5(1): 1-10
ISSN 2219-2816 (online)
© 2016 Baishideng Publishing Group Inc. All rights reserved.

REVIEW

Management of penile urethral strictures: Challenges and future directions

Felix Campos-Juanatey, Simon Bugeja, Stella L Ivaz, Anastasia Frost, Daniela E Andrich, Anthony R Mundy

Felix Campos-Juanatey, Simon Bugeja, Stella L Ivaz, Anastasia Frost, Daniela E Andrich, Anthony R Mundy, Institute of Urology, University College London Hospitals, London NW1 2PG, United Kingdom

Felix Campos-Juanatey, Marques de Valdecilla University Hospital, Santander39008, Spain

Author contributions: Campos-Juanatey F and Bugeja S reviewed the literature and drafted the manuscript; Ivaz SL and Frost A contributed to review the literature; Andrich DE and Mundy AR review the manuscript and made critical revision and edition of the contents; all authors read and approved the final version of the manuscript.

Conflict-of-interest statement: All authors declare no potential conflicts of interest related with the contents of this manuscript.

Open-Access: This article is an open-access article which was selected by an in-house editor and fully peer-reviewed by external reviewers. It is distributed in accordance with the Creative Commons Attribution Non Commercial (CC BY-NC 4.0) license, which permits others to distribute, remix, adapt, build upon this work non-commercially, and license their derivative works on different terms, provided the original work is properly cited and the use is non-commercial. See: http://creativecommons.org/licenses/by-nc/4.0/

Correspondence to: Anthony R Mundy, PhD, MS, FRCS, FRACS, Professor, Medical Director, Institute of Urology, University College London Hospitals, ULCH Trust Headquarters, 2nd floor central, 250 Euston Road, London NW1 2PG, United Kingdom. kelly.higgs@uclh.nhs.uk
Telephone: +44-20-34479099
Fax: +44-20-34479401

Received: September 21, 2015
Peer-review started: September 22, 2015
First decision: November 24, 2015
Revised: December 15, 2015
Accepted: February 23, 2016
Article in press: February 24, 2016
Published online: March 24, 2016

Abstract

The anatomy of the penile urethra presents additional challenges when compared to other urethral segments during open stricture surgery particularly because of its unsuitability for excision and primary anastomosis and its relatively deficient corpus spongiosum. Stricture aetiology, location, length and previous surgical intervention remain the primary factors influencing the choice of penile urethroplasty technique. We have identified what we feel are the most important challenges and controversies in penile urethral stricture reconstruction, namely the use of flaps *vs* grafts, use of skin or oral mucosal tissue for augmentation/substitution and when a single or a staged approach is indicated to give the best possible outcome. The management of more complex cases such as pan-urethral lichen-sclerosus strictures and hypospadias "cripples" is outlined and potential developments for the future are presented.

Key words: Reconstructive surgical procedures; Anterior urethral stricture; Oral mucosa; Tissue transplants; Skin grafting; Hypospadias; Lichen sclerosus

© The Author(s) 2016. Published by Baishideng Publishing Group Inc. All rights reserved.

Core tip: The anatomy of the penile urethra presents additional challenges when compared to other urethral segments. Stricture aetiology, location, length and previous surgical intervention remain the primary factors influencing the choice of penile urethroplasty technique. We described the most important challenges and controversies in penile urethral stricture reconstruction: Use of flaps *vs* grafts, use of skin or oral mucosal tissue for augmentation/substitution and when a single or a staged approach is indicated to give the best possible outcome. The management of more complex cases (pan-urethral lichen-sclerosus strictures and hypospadias "cripples") is outlined and potential developments for the

future are presented.

Campos-Juanatey F, Bugeja S, Ivaz SL, Frost A, Andrich DE, Mundy AR. Management of penile urethral strictures: Challenges and future directions. *World J Clin Urol* 2016; 5(1): 1-10 Available from: URL: http://www.wjgnet.com/2219-2816/full/v5/i1/1.htm DOI: http://dx.doi.org/10.5410/wjcu.v5.i1.1

INTRODUCTION

The treatment of penile urethral strictures is generally more complex when compared with other segments of the urethra by virtue of various anatomical considerations. This is evidenced by the variety of techniques with have been described for reconstruction in this area[1]. Achieving a satisfactory and durable functional outcome (*i.e.,* unobstructed voiding) is the main goal but the cosmetic appearance of the male genitalia also deserves due consideration[2]. Penile shape and length should be preserved and ultimately restored if damaged by injury or scarring from previous surgery[3].

A further concern with penile urethroplasty is erectile function, and in particular, penile shortening and curvature. The risk of transient erectile dysfunction after urethroplasty is clearly described[4]. Loss of penile length and penile curvature are more common after penile urethral surgery[5], particularly when local flaps are used[6].

Mucosal and skin grafts, or local skin flaps, may be considered for penile urethral reconstruction. Consequently the reconstructive surgeon should be skilled at a broad range of techniques and be able to carefully evaluate the benefits and adverse effects of each in individual circumstances[1].

There is a paucity of sound scientific evidence in this field of urology, most of the available literature being based on descriptive case series (not always with homogeneous cohorts of patients) and expert opinions[1,7]. In this paper, we address current practice and the challenges and controversies faced by the reconstructive surgeon in the management of penile urethral strictures. Future developments in this field are also explored.

ANATOMICAL CONSIDERATIONS

The penile (or pendulous) urethra is the distal part of the male anterior urethra. It is about 15 cm in length and extends from the external meatus, the narrowest part of the urethra (21-27 F), to the penoscrotal junction where the bulbar segment starts. The penile urethra presents important anatomical differences compared with the bulbar segment[8]. It is surrounded by the thinnest part of the corpus spongiosum in the penile shaft, meaning that it does not provide the best vascular support for a graft. The glans penis, which is the expanded distal end of the corpus spongiosum, surrounds the navicular fossa and external meatus[9]. On the contrary, this rich glanular blood supply provides an ideal vascular bed for successful graft take.

The urethra and the spongiosum are covered by the anterior extension of Bucki's fascia, and a layer of dartos areolar tissue (continuation of Colles fascia) that provides blood supply to the penile shaft skin[10]. This dartos tissue is also very well vascularised, making it an ideal graft bed or a pedicle for skin grafts.

Unlike the bulbar urethra, which can be mobilised proximally and distally to allow excision of a stricture and a tension-free primary anastomosis, this is not possible in the penile urethra due to the risk of loss of length and curvature during erection. This means that reconstructive techniques in the penile urethra are limited to augmentation or substitution using free grafts or flaps which in themselves may also result in chordee if used incorrectly. Moreover, pendulous strictures usually tend to be longer[11] (in some series nearly twice as long) than in the bulbar urethra.

IMPORTANCE OF STRICTURE AETIOLOGY

The commonest identifiable cause of penile strictures in young and middle-aged adults is lichen sclerosus (LS) or balanitis xerotica obliterans[12] (Figure 1). This was recently evidenced in a large European cohort of patients[13]. The proposed pathophysiology of penile strictures secondary to LS is that the initial changes occur at the urethral meatus when it becomes involved by the scarring affecting the rest of the glans and prepuce[14]. This atrophic fibrosis can extend proximally, affecting the fossa navicularis and penile urethra, which may be associated with palpable thickening at the level of the strictures. The progression of a distal stricture proximally is related to metaplastic changes due to chronic distension and extravasation of urine with subsequent inflammation of the peri-urethral glands as a result of pressure during voiding. This may be reversible if the obstruction is relieved early[12].

The penile urethra is also susceptible to strictures resulting from infection and traumatic instrumentation during catheterisation or transurethral procedures[15]. These are most commonly located in the navicular fossa and at the peno-scrotal junction[2].

The incidence of each causative factor remains unclear, however in some series it is suggested that fossa navicularis strictures are equally of iatrogenic, idiopathic, and inflammatory origin (including LS) but not the result of external trauma[11]. LS is the most common cause of strictures affecting the entire penile and bulbar urethral segments[16].

Another common occurrence is a recurrent penile urethral stricture following previous failed urethroplasty, particularly in hypospadias-related strictures (Figure 2). Recurrence after hypospadias surgery is the most frequent cause of complex anterior urethral strictures[17]

Figure 1 Typical appearance of lichen sclerosus with scarring on the glans, loss of the normal contour of the glans and coronal sulcus, meatal regression and stenosis.

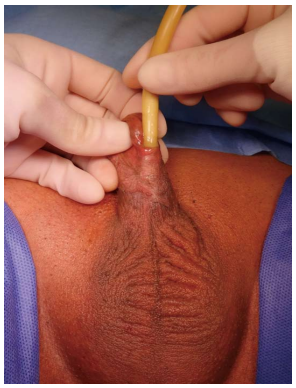

Figure 2 Urethral stricture after failed mid-penile hypospadias reconstruction.

and in some series from tertiary referral centers is the most common indication for staged penile reconstruction[18]. Strictures following failed hypospadias surgery usually occur as a result of early postoperative complications such as infection and consequently become apparent shortly after the surgery. They may however also manifest themselves many years later due to failure of the graft or flap[19].

Stricture aetiology is one of the most important factors determining the choice of management strategy of penile urethral strictures (and indeed all urethral strictures) and particularly the choice of surgical reconstructive procedure[1]. In LS-related strictures the use of mucosal grafts (usually oral but bladder or rectal also possible) is recommended since LS is a skin condition and any skin used for reconstruction is either already, or has the potential to become involved by the disease process[20]. On the other hand, genital skin is suitable for use as a flap or graft for reconstructing the urethra in selected patients with previous hypospadias surgery or instrumentation-related strictures[21].

DISCUSSION

Controversies

Flaps or grafts for penile urethroplasty: In 1968, Orandi[22] first reported on reconstruction of the anterior urethra using a pedicled skin flap. The Orandi longitudinal flap provides a long strip of penile skin with a consistent blood supply, adequate to augment the urethral lumen. This urethroplasty technique has proved to be useful for non-obliterative strictures within the penile shaft that are not secondary to LS[1]. Other skin flaps have been described using preputial, penile and scrotal skin[23-25] to treat strictures in any part of the penile urethra. These flaps achieved satisfactory outcomes in selected cases, mainly as an augmentation patch[26] after having excluded LS as a causative factor[27]. It has been shown that such skin flaps, when tubularised, are associated with a higher failure rate; up to 58% in the intermediate-term[26]. In addition, pedicled flaps are associated with other problems. When penile shaft skin is used, patients tend to report unacceptable scars at the donor site incisions, as well as irregularity of the skin caused by raising and rotating the dartos fascia as a pedicle. Furthermore, a degree of penile torsion can occur as a consequence of the pedicle[21]. In cases reconstructed using a circumferential skin tube, "bow-stringing" of the neo-urethra away from the corpora cavernosa can occur, giving the appearance of ventral webbing of the penis[21]. Scrotal skin is associated with the added complication of hair growth resulting in recurrent urethral obstruction by hairballs and stones.

Traditionally penile flaps were preferred to free grafts for penile urethral reconstruction. This was related to the perception of an initial high failure rate of grafts reported in the penile urethra[8]. A graft is only as good as its bed, and unfortunately, the anatomy of the penile spongiosum means that this is not always guaranteed. The rich glanular tissue on the other hand provides a healthy scaffold for grafting, but adequate penile spongiosal tissue and dartos fascia are not always available and thus do not ensure sufficient support for a graft in all patients.

The use of skin grafts for hypospadias surgery has long been described, as a single procedure[28], or as a staged approach[29], when still present, the foreskin has been the preferred graft source[30]. Since the popularisation of oral tissue as a substitution graft for urethroplasty in 1993[31], it has become the material of choice due to certain characteristic properties[32]. Oral mucosa is typically harvested from the cheek but can also be taken from the tongue and inner lip, resulting in a relatively concealed donor site scar and also providing sufficient graft material for almost every length of stricture[33]. A lack of oral tissue for grafting is usually associated with previous failed procedures.

Early reports suggested that outcomes with oral mucosal grafts were better when used as a patch because the failure rates when used as a tubed substitution were high, similar to the previous experience with tubularised flaps. The management of penile urethral strictures changed dramatically with the description of the dorsal free oral mucosal graft technique[34]. Those patients previously treated using a circumferential substitution in one stage with a tubularised local flap began to be managed in a staged fashion using buccal grafts

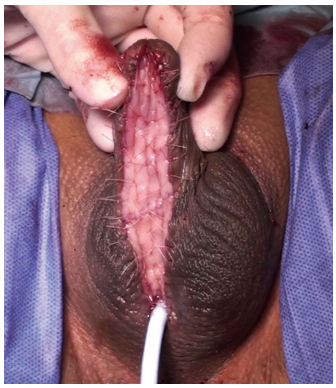

Figure 3 Operative image showing a complete first stage full-length penile urethroplasty using bilateral buccal mucosal grafts quilted dorsally to create a neo-urethral plate of adequate calibre to be retubularised in the second stage.

instead[21] (Figure 3).

In summary, the answer to the question "graft *vs* flap?" needs to be answered on the operating table, each case taken on its own merit, after a careful intraoperative evaluation based on the above-mentioned factors. However as a general rule, one would use a local pedicled flap with its own blood supply preferentially to a free graft in situations where the graft bed is poor, as with severe scarring or following radiotherapy[1].

Skin or oral mucosal grafts for augmentation or substitution: Oral mucosa has become the most widely utilised free graft for urethral reconstruction[35]. The advantages of a concealed donor site and availability have already been alluded to. Harvesting the graft is relatively easy and associated with low morbidity[32,36] (Figure 4). Biological and clinical characteristics explain the consistently good results associated with its use since it was first described[37-39]. Oral mucosa is resistant to infection. It usually hosts a variety of microorganisms hence its minimal inflammatory response to organisms[38]. LS does not tend to recur in oral mucosa as it does in skin[20]. Further anatomical advantages are related to a thick elastin-rich epithelium and a highly resilient lamina propria-oral epithelium interface, making it easy to manipulate. A thin and highly vascular lamina propria facilitates inosculation and imbibition, hence improving graft take. These structural features are retained once transplanted to the genital area with histological studies demonstrating that once in the urethra, buccal graft is often indistinguishable from host tissues[40].

The commonest site for free skin grafts is the prepuce[28] (Figure 5), due to its relative ease of harvesting, it being hairless as well as the satisfactory cosmetic appearance of the circumcising incision. Other non-hairy skin donor sites have been suggested such as the medial aspect of the upper arm and the posterior auricular area[28]. Postauricular skin, when used as a full-thickness free graft (Wolfe graft), is associated with a very satisfactory outcome which may be comparable to that obtained using oral mucosa[21]. Facial skin has a particularly dense subdermal plexus, which allows for better graft take and prevents contraction when used as a full-thickness graft. Full thickness skin grafts generally do not take as well as split-skin grafts, but when they do they tend to contract far less (around 20%)[41].

Some authors suggest that the choice of substitution material (oral mucosa *vs* preputial skin) should be based primarily on surgeon preference and experience[42]. However, several factors need to be taken into consideration including aetiology (skin contraindicated in LS), availability of oral mucosa (such as in revision procedures) and the consequence of any degree of contraction of the grafts particularly chordee, which suggests that split-skin grafts are not suitable for use in the penile urethra.

Single stage or multi-staged penile urethroplasty: When the residual urethral plate is of adequate calibre and the corpus spongiosum, dartos fascia and penile skin are preserved, single stage reconstruction is possible and preferable[18]. Besides avoiding a proximal urethrostomy and its negative impact on quality of life[3,43] for 3-6 mo, the main advantage of a single stage approach is the fewer number of procedures. The staged approach for penile urethral reconstruction is associated with a reported first stage revision rate for graft contracture of between 20% and 31%[18,21,44] ultimately resulting in a three- or more staged procedure.

Several techniques are available for single stage penile urethroplasty. Local skin flaps such as the McAninch preputial flap[24] have been described if the urethral plate can be preserved and no features of LS are evident. The Orandi procedure[22] is recommended by some authors as the best choice for penile urethral augmentation in selected mid-penile short strictures which are not related to LS[1]. Barbagli *et al*[34] described the dorsal free graft oral mucosal graft technique to augment strictures in the penile urethra in a single stage in addition to the well-known dorsal approach to bulbar urethroplasty.

Another technique for the treatment of distal penile strictures using grafts has been suggested as an evolution of the Snodgrass longitudinal incision of the urethral plate in which an oral mucosal graft is placed as an inlay into the incised urethral plate[45]. Based on the same principle of preserving the native urethral plate when available, Asopa *et al*[46] described the technique of dorsal augmentation with skin or oral mucosa as a dorsal inlay *via* a ventral urethrotomy. This procedure is not recommended in cases when the urethral plate is severely scarred, fibrotic or narrowed, but is suitable for less complicated strictures, with the advantage of a less invasive approach through a circumcision incision. Placement of the oral mucosal graft ventrally has also been described in the penile urethra, however due to the lack of adequate spongiosal support, a pseudospongioplasty with dartos tissues is necessary and is not recommended as standard treatment[47].

A significant development in the single stage reconstruction of long penile urethral strictures with a

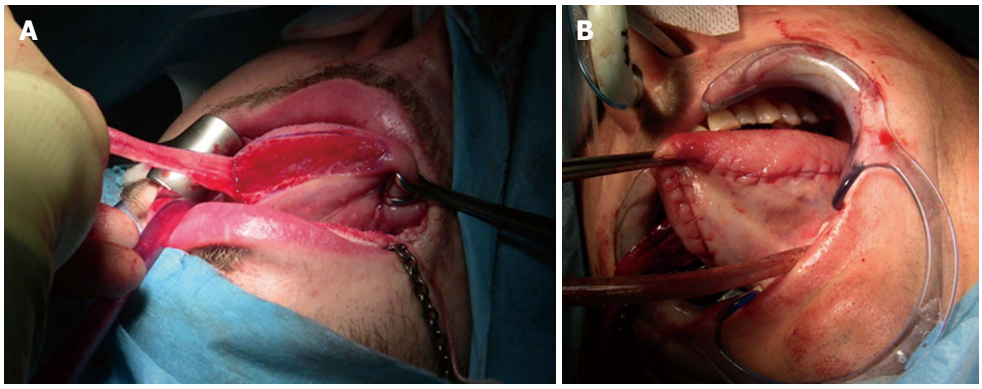

Figure 4 Operative image showing (A) harvesting of a sublingual graft and (B) bilateral sublingual graft donor sites closed primarily.

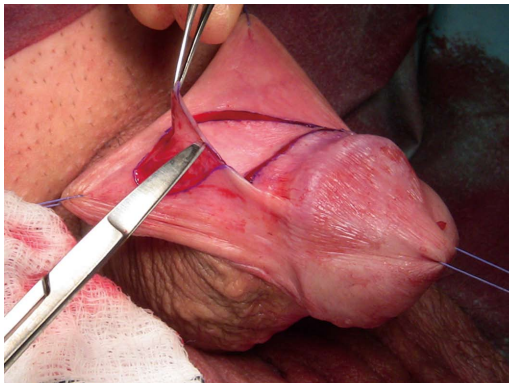

Figure 5 Operative image showing a preputial skin free graft being harvested.

salvageable urethral plate is dorso-lateral augmentation using oral mucosal graft *via* a transperineal approach with invagination of the penis as described by Kulkarni *et al*[48] (Figure 6). This technique is associated with excellent success rates of up to 92% in the short term (12 mo)[48] and 83.7% in the intermediate term (5 years)[49].

Circumferential reconstruction in a single stage using a tubularised local skin flap is associated with an unacceptably high failure rate[24]. A tubularised repair using oral mucosal grafts in one stage has also been described in the penile urethra but the reported outcomes were similar to previous reports using tubularised skin flaps and are therefore not usually recommended[39]. Consequently those patients in whom complete urethral substitution is necessary due to an unsalvageable urethral plate are preferentially managed *via* a staged approach using oral mucosal grafts[21]. A stricturotomy is performed and the diseased segment excised. A roof strip is reconstructed using graft during the first stage to produce a neo-urethral plate of adequate width which is then rolled back into a tube in the second stage 3-6 mo later. The success rate of this staged approach is up to 96% in tertiary referral centers[18]. However, complication rates of up to 35% are reported in some series[50].

We have recently shown that in selected cases it is possible to excise the spongiofibrosis, create a neo-urethral plate using oral mucosa and tubularise it, all in a single stage (Figure 7). We refer to this as a "two-in-one" stage urethroplasty and is dependent on glans size, spongiosal thickness and adequate dartos to provide support for the graft and allow enough tissue mobility for tension-free retubularisation. Previously unoperated, LS-related navicular fossa and distal penile urethral strictures are most suitable for this technique which is associated with a success rate of 90% at a mean follow-up of 16.2 mo[51].

In some cases, such as following failed hypospadias surgery, absence of an adequate spongiosum or lack of dartos and/or penile skin, a staged approach is recommended[52] for the reasons described above. However, as with all urethroplasties, but particularly in the penile urethra, it is not always possible to predict the quality of the local tissues or the residual urethral plate available for reconstruction prior to the surgery. Consequently, in our practice, patients undergoing penile urethroplasty are consented for either approach. The decision as to whether or not a single staged approach should be avoided in favour of a staged procedure is always based on a thorough intraoperative evaluation by an experienced reconstructive surgeon who is able to predict the likelihood of success and complications of either approach[21].

Management of complex cases: Penile urethral strictures range from short strictures (Figure 8) in which the urethral plate is preserved and which are relatively easily treated by augmentation techniques, to complete obliteration of the entire length of the penile urethra due to severe LS or failed hypospadias surgery (Figure 9). Management of the latter, especially those after previous failed attempts at reconstruction, presents additional challenges. The literature relating to these complex cases is sparse and does not provide reliable guidelines[42], particularly because of the heterogeneity of this group of patients. Treatment of such complex strictures commonly involves excision of the original obliterated skin tube and substitution of the entire diseased segment. These cases are often complicated further by urethrocutaneous

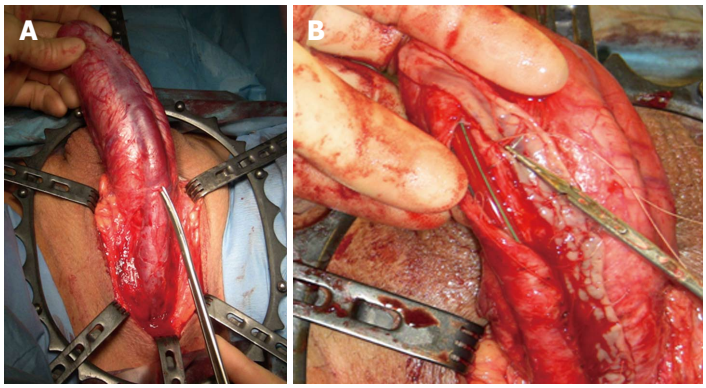

Figure 6 Kulkarni technique for long penile strictures *via* a transperineal approach with (A) invagination of the penis and (B) dorsolateral placement of the sublingual graft.

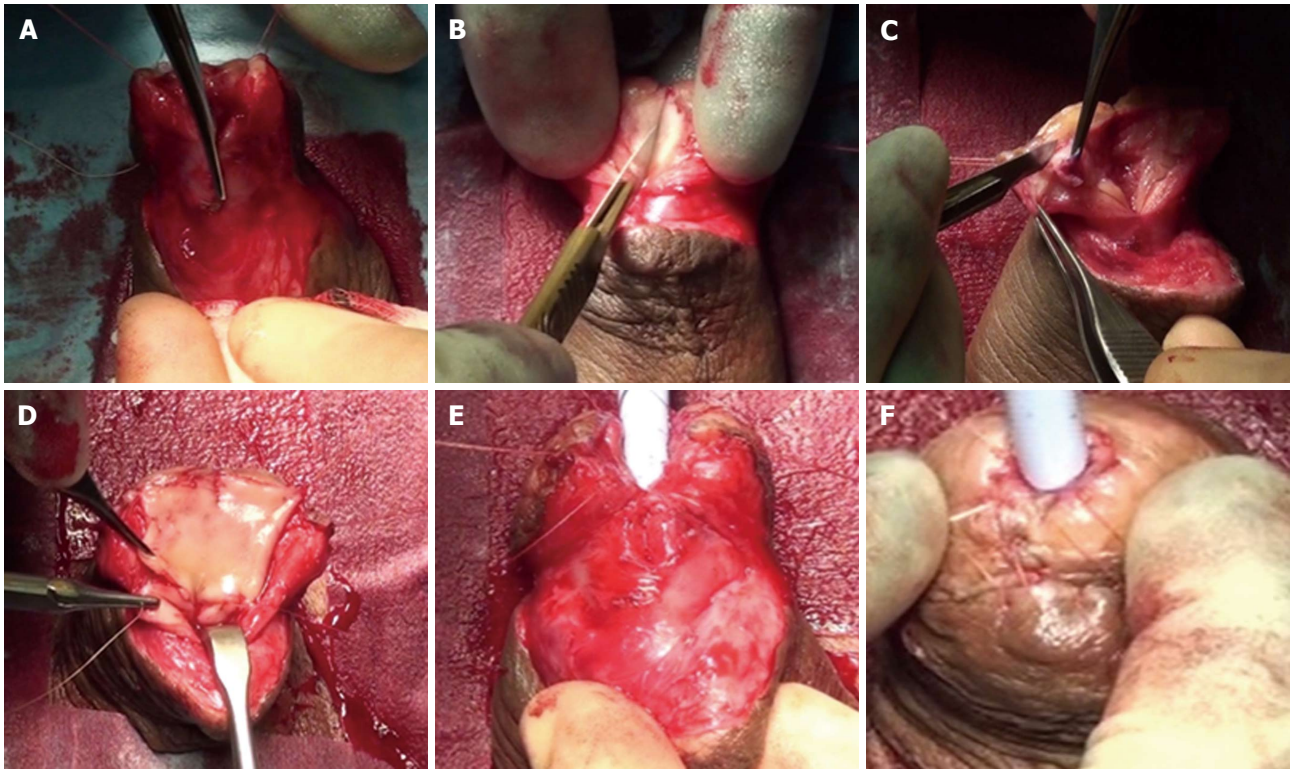

Figure 7 "Two-in-one" stage approach for a distal penile urethral stricture using oral mucosal graft. A: Ventral stricturotomy; B: Glans cleft deepened; C: Spongiofibrosis excised; D: Neo-urethral plate created using oral mucosa; E and F: Retubularised in layers in one stage.

fistulae (Figure 10), penile curvature and loss of penile length. In fact, in some series of penile urethroplasty[17], the reconstruction was restricted solely to the urethra in only 25.5% of the cases, with the rest requiring additional procedures such as correction of chordee or penile lengthening. A staged approach is preferable in these cases[29].

Such surgery, involving reconstruction of the urethra and the corpora cavernosa, should be performed by experienced surgeons in high volume, tertiary referral centres to ensure the best cosmetic and functional outcome for these patients[53]. The best outcome in these patients is achievable during the first reconstructive procedure, with salvage surgery becoming increasingly complex and associated with an increased failure rate.

Not all complex penile urethral strictures are amenable to reconstruction[54] and indeed some patients may not be keen on having further surgical intervention or may not be medically fit for major surgery. In these patients a regime of interval urethral dilatation may be feasible to preserve urethral voiding and adjunctive self-dilatation may prolong the interval between recurrence[55]. Many find this unsustainable due to pain, bleeding and recurrent infections and is generally associated with a poor quality of life[56]. Perineal urethrostomy, though not immediately acceptable to many, does present a feasible salvage treatment option in these patients with a reasonably good functional outcome and minimal

Figure 8 Ascending urethrogram showing a short penile urethral stricture limited to the fossa navicularis.

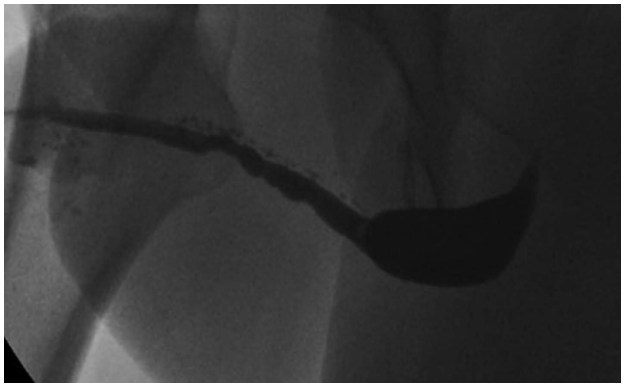

Figure 9 Entire penile and distal bulbar urethra affected by a Lichen Sclerosus-related stricture.

complications[57].

Future directions: Penile urethroplasty has evolved since first attempts at reconstruction using foreskin tubes[28] or a staged approach using penile skin[58]. An increased understanding of the pathophysiology of LS together with the high recurrence rate if skin was used for reconstruction led to the recommended use of oral mucosal grafts in LS strictures[20]. However, to date, very little benefit has been achieved with non-surgical treatment options[59]. Further research in this field may lead to the development of ways and means of stabilising or even inducing remission in this recalcitrant skin pathology.

The main limitations of current penile urethroplasty techniques are the frequent requirement of a staged procedure with its associated patient inconvenience and 20%-31% incidence of graft failure following the first stage requiring further revision surgery prior to retubularisation. Lack of available oral mucosa in full-length penile strictures, particularly in revision cases, presents additional problems. The inability to simply excise obliterative strictures and perform an end-to-end anastomosis means that substitution techniques become necessary however tubularised substitution is inherently associated with a high failure rate.

Extensive research has been carried out in the

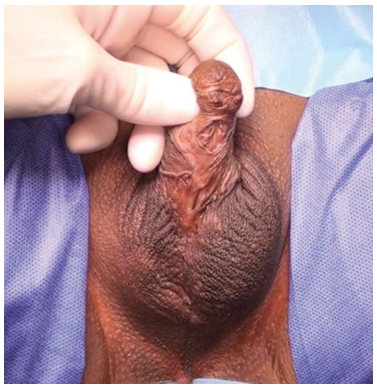

Figure 10 Multiple urethrocutaneous fistulae after failed hypospadias repair.

fields of biomaterials, regenerative medicine and tissue engineering in order to try and overcome some of the limitations related to current penile urethral stricture management outlined above. The primary aim has been to generate a graft with properties similar to oral mucosa but which is readily available "off the shelf", in unlimited quantities and with no morbidity associated with graft harvesting. Despite significant advances, the ideal biomaterial or composite graft has not yet been identified for use in routine clinical practice[60].

Numerous animal models and clinical studies have tested a variety of engineered urethral substitutes over the past 30 years. Both natural and synthetic matrices, biodegradeable and non-absorbable, seeded and unseeded, have been studied. Unseeded, "off the shelf" tubularised grafts have only been successful in replacing urethral defects less than 0.5 cm in length due to failure of epithelialisation of longer grafts from healthy surrounding tissues[61]. Unseeded grafts used as a patch in an onlay or inlay fashion have shown better results in clinical trials[62,63]. Unfortunately this has not been replicated in longer strictures. One hundred percent failure rates were reported in strictures longer than 4 cm[64]. Suboptimal results were demonstrated in patients who have had previous failed urethroplasties or those with an unhealthy vascular bed[65], two patient populations in whom alternatives to conventional substitution materials are generally sought.

In order to treat longer strictures cellularised scaffolds seem to be necessary since graft survival would be independent of epithelial cell ingrowth. Tubularised seeded grafts have shown positive results in a canine model[66] and in the only clinical trial to date[67] albeit both in the bulbar or posterior urethra. A recent review on tissue engineered oral mucosa[68] has shown this to be a "promising alternative" but requires long-term large cohort clinical trials before being advocated for widespread use. Moreover, cellularised grafts require a source of cells for seeding, are laborious, time-consuming and expensive to manufacture[69] which defeat the purpose of having a readily available off the shelf tissue substitute.

Even though the ideal tissue engineered urethral sub-

stitute may be several years away, what can and should certainly be addressed right away is the awareness amongst urological surgeons that urethral reconstruction is a highly specialised discipline and should only be undertaken by experienced surgeons in high volume tertiary units in order to ensure the best possible outcome for patients[70] particularly given the fact that the first procedure is usually the one with the best results.

CONCLUSION

Penile urethral strictures present a therapeutic challenge to the reconstructive urologist and are also associated with a significant negative impact on patient quality of life, many of them starting off with problems in infancy or adolescence and progressing into adult life, often requiring multiple surgical interventions in the process. Short, primary strictures are usually relatively easily reconstructable using oral mucosal grafts or skin flaps in a single or multi-staged approach with high rates of success. The major challenges lie with those patients having extensive LS-related strictures or "hypospadias cripples" for whom current urethroplasty techniques are not always possible or feasible. These commonly end up being managed by repeated endoscopic intervention, self-dilatation or a perineal urethrostomy, often after having undergone multiple failed attempts at urethral reconstruction.

An abundance of penile urethroplasty techniques have been described over the years bearing witness to the difficulty in dealing with this condition. All are however based on stricture aetiology, length, location and previous surgical intervention. It is up to the reconstructive surgeon to carefully evaluate the anatomy of the stricture and supporting tissues intraoperatively and only then decide which technique would give the greatest likelihood of success in any given circumstance. Hence the importance of centralisation of urethroplasty services to high volume units with expertise in a braod range of techniques.

One hopes that ongoing research will give rise to therapeutic modalities which can alter the underlying pathological processes in LS and that advances in restorative medicine would lead to the generation of novel, biocompatible and commercially viable urethral substitutes.

REFERENCES

1 **Andrich DE**, Mundy AR. What is the best technique for urethroplasty? *Eur Urol* 2008; **54**: 1031-1041 [PMID: 18715692 DOI: 10.1016/j.eururo.2008.07.052]

2 **Armenakas NA**, McAninch JW. Management of fossa navicularis strictures. *Urol Clin North Am* 2002; **29**: 477-484 [PMID: 12371237]

3 **Barbagli G**, De Angelis M, Palminteri E, Lazzeri M. Failed hypospadias repair presenting in adults. *Eur Urol* 2006; **49**: 887-894; discussion 895 [PMID: 16476518 DOI: 10.1016/j.eururo.2006.01.027]

4 **Blaschko SD**, Sanford MT, Cinman NM, McAninch JW, Breyer BN. De novo erectile dysfunction after anterior urethroplasty: a systematic review and meta-analysis. *BJU Int* 2013; **112**: 655-663 [PMID: 23924424 DOI: 10.1111/j.1464-410X.2012.11741.x]

5 **Bubanj TB**, Perovic SV, Milicevic RM, Jovcic SB, Marjanovic ZO, Djordjevic MM. Sexual behavior and sexual function of adults after hypospadias surgery: a comparative study. *J Urol* 2004; **171**: 1876-1879 [PMID: 15076297 DOI: 10.1097/01.ju.0000119337.19471.51]

6 **Kim KR**, Suh JG, Paick JS, Kim SW. Surgical outcome of urethroplasty using penile circular fasciocutaneous flap for anterior urethral stricture. *World J Mens Health* 2014; **32**: 87-92 [PMID: 25237658 DOI: 10.5534/wjmh.2014.32.2.87]

7 **Barbagli G**, Morgia G, Lazzeri M. Retrospective outcome analysis of one-stage penile urethroplasty using a flap or graft in a homogeneous series of patients. *BJU Int* 2008; **102**: 853-860 [PMID: 18485036 DOI: 10.1111/j.1464-410X.2008.07741.x]

8 **Wessells H**, McAninch JW. Use of free grafts in urethral stricture reconstruction. *J Urol* 1996; **155**: 1912-1915 [PMID: 8618286 DOI: 10.1016/S0022-5347(01)66045-2]

9 **Humphrey PA**. Genital skin and urethral anatomy. In: Brandes SB, editor. Current clinical urology: Urethral reconstructive surgey. Totowa: Humana Press, 2008: 1-8 [DOI: 10.1007/978-1-59745-103-1_1]

10 **Dwyer ME**, Salgado CJ, Lightner DJ. Normal penile, scrotal, and perineal anatomy with reconstructive considerations. *Semin Plast Surg* 2011; **25**: 179-188 [PMID: 22851909 DOI: 10.1055/s-0031-1281487]

11 **Fenton AS**, Morey AF, Aviles R, Garcia CR. Anterior urethral strictures: etiology and characteristics. *Urology* 2005; **65**: 1055-1058 [PMID: 15913734 DOI: 10.1016/j.urology.2004.12.018]

12 **Mundy AR**, Andrich DE. Urethral strictures. *BJU Int* 2011; **107**: 6-26 [PMID: 21176068 DOI: 10.1111/j.1464-410X.2010.09800.x]

13 **Lumen N**, Hoebeke P, Willemsen P, De Troyer B, Pieters R, Oosterlinck W. Etiology of urethral stricture disease in the 21st century. *J Urol* 2009; **182**: 983-987 [PMID: 19616805 DOI: 10.1016/j.juro.2009.05.023]

14 **Andrich DE**, Mundy AR. Substitution urethroplasty with buccal mucosal-free grafts. *J Urol* 2001; **165**: 1131-1133; discussion 1133-1134 [PMID: 11257653]

15 **Meeks JJ**, Barbagli G, Mehdiratta N, Granieri MA, Gonzalez CM. Distal urethroplasty for isolated fossa navicularis and meatal strictures. *BJU Int* 2012; **109**: 616-619 [PMID: 21615852 DOI: 10.1111/j.1464-410X.2011.10248.x]

16 **Barbagli G**, Mirri F, Gallucci M, Sansalone S, Romano G, Lazzeri M. Histological evidence of urethral involvement in male patients with genital lichen sclerosus: a preliminary report. *J Urol* 2011; **185**: 2171-2176 [PMID: 21497838 DOI: 10.1016/j.juro.2011.02.060]

17 **Barbagli G**, Perovic S, Djinovic R, Sansalone S, Lazzeri M. Retrospective descriptive analysis of 1,176 patients with failed hypospadias repair. *J Urol* 2010; **183**: 207-211 [PMID: 19913825 DOI: 10.1016/j.juro.2009.08.153]

18 **Andrich DE**, Greenwell TJ, Mundy AR. The problems of penile urethroplasty with particular reference to 2-stage reconstructions. *J Urol* 2003; **170**: 87-89 [PMID: 12796651 DOI: 10.1097/01.ju.0000069721.20193.fd]

19 **Tang SH**, Hammer CC, Doumanian L, Santucci RA. Adult urethral stricture disease after childhood hypospadias repair. *Adv Urol*, 2008: 150315 [PMID: 19009025 DOI: 10.1155/2008/150315]

20 **Venn SN**, Mundy AR. Urethroplasty for balanitis xerotica obliterans. *Br J Urol* 1998; **81**: 735-737 [PMID: 9634051 DOI: 10.1046/j.1464-410x.1998.00634.x]

21 **Greenwell TJ**, Venn SN, Mundy AR. Changing practice in anterior urethroplasty. *BJU Int* 1999; **83**: 631-635 [PMID: 10233570 DOI: 10.1046/j.1464-410x.1999.00010.x]

22 **Orandi A**. One-stage urethroplasty. *Br J Urol* 1968; **40**: 717-719 [PMID: 4883846 DOI: 10.1111/j.1464-410X.1968.tb11872.x]

23 **Mundy AR**, Stephenson TP. Pedicled preputial patch urethroplasty. *Br J Urol* 1988; **61**: 48-52 [PMID: 3342301 DOI: 10.1111/j.1464-410X.1988.tb09161.x]

24 **McAninch JW**. Reconstruction of extensive urethral strictures: circular fasciocutaneous penile flap. *J Urol* 1993; **149**: 488-491 [PMID: 8437252]

25 **Jordan GH**. Reconstruction of the fossa navicularis. *J Urol* 1987; **138**: 102-104 [PMID: 3599186]

26 **McAninch JW**, Morey AF. Penile circular fasciocutaneous skin flap in 1-stage reconstruction of complex anterior urethral strictures. *J Urol* 1998; **159**: 1209-1213 [PMID: 9507836 DOI: 10.1016/S0022-5347(01)63558-4]

27 **Virasoro R**, Eltahawy EA, Jordan GH. Long-term follow-up for reconstruction of strictures of the fossa navicularis with a single technique. *BJU Int* 2007; **100**: 1143-1145 [PMID: 17627782 DOI: 10.1111/j.1464-410X.2007.07078.x]

28 **Humby G.** A one-stage operation for hypospadias. *Br J Urol* 1941; **29**: 84-92 [DOI: 10.1002/bjs.18002911312]

29 **Bracka A**. Hypospadias repair: the two-stage alternative. *Br J Urol* 1995; **76** Suppl 3: 31-41 [PMID: 8535768 DOI: 10.1111/j.1464-410X.1995.tb07815.x]

30 **Bracka A**. A versatile two-stage hypospadias repair. *Br J Plast Surg* 1995; **48**: 345-352 [PMID: 7551506 DOI: 10.1016/S0007-1226(95)90023-3]

31 **el-Kasaby AW**, Fath-Alla M, Noweir AM, el-Halaby MR, Zakaria W, el-Beialy MH. The use of buccal mucosa patch graft in the management of anterior urethral strictures. *J Urol* 1993; **149**: 276-278 [PMID: 8426400]

32 **Wood DN**, Allen SE, Andrich DE, Greenwell TJ, Mundy AR. The morbidity of buccal mucosal graft harvest for urethroplasty and the effect of nonclosure of the graft harvest site on postoperative pain. *J Urol* 2004; **172**: 580-583 [PMID: 15247736 DOI: 10.1097/01.ju.0000132846.01144.9f]

33 **Simonato A**, Gregori A, Lissiani A, Galli S, Ottaviani F, Rossi R, Zappone A, Carmignani G. The tongue as an alternative donor site for graft urethroplasty: a pilot study. *J Urol* 2006; **175**: 589-592 [PMID: 16407002 DOI: 10.1016/s0022-5347(05)00166-7]

34 **Barbagli G**, Selli C, Tosto A, Palminteri E. Dorsal free graft urethroplasty. *J Urol* 1996; **155**: 123-126 [PMID: 7490808 DOI: 10.1016/S0022-5347(01)66566-2]

35 **Mangera A**, Patterson JM, Chapple CR. A systematic review of graft augmentation urethroplasty techniques for the treatment of anterior urethral strictures. *Eur Urol* 2011; **59**: 797-814 [PMID: 21353379 DOI: 10.1016/j.eururo.2011.02.010]

36 **Barbagli G**, Fossati N, Sansalone S, Larcher A, Romano G, Dell' Acqua V, Guazzoni G, Lazzeri M. Prediction of early and late complications after oral mucosal graft harvesting: multivariable analysis from a cohort of 553 consecutive patients. *J Urol* 2014; **191**: 688-693 [PMID: 24035880 DOI: 10.1016/j.juro.2013.09.006]

37 **Dubey D**, Vijjan V, Kapoor R, Srivastava A, Mandhani A, Kumar A, Ansari MS. Dorsal onlay buccal mucosa versus penile skin flap urethroplasty for anterior urethral strictures: results from a randomized prospective trial. *J Urol* 2007; **178**: 2466-2469 [PMID: 17937943 DOI: 10.1016/j.juro.2007.08.010]

38 **Filipas D**, Fisch M, Fichtner J, Fitzpatrick J, Berg K, Störkel S, Hohenfellner R, Thüroff JW. The histology and immunohistochemistry of free buccal mucosa and full-skin grafts after exposure to urine. *BJU Int* 1999; **84**: 108-111 [PMID: 10444136 DOI: 10.1046/j.1464-410x.1999.00079.x]

39 **Venn SN**, Mundy AR. Early experience with the use of buccal mucosa for substitution urethroplasty. *Br J Urol* 1998; **81**: 738-740 [PMID: 9634052 DOI: 10.1046/j.1464-410x.1998.00617.x]

40 **Markiewicz MR**, Lukose MA, Margarone JE, Barbagli G, Miller KS, Chuang SK. The oral mucosa graft: a systematic review. *J Urol* 2007; **178**: 387-394 [PMID: 17561150 DOI: 10.1016/j.juro.2007.03.094]

41 **El-Sherbiny MT**, Abol-Enein H, Dawaba MS, Ghoneim MA. Treatment of urethral defects: skin, buccal or bladder mucosa, tube or patch? An experimental study in dogs. *J Urol* 2002; **167**: 2225-2228 [PMID: 11956483 DOI: 10.1016/S0022-5347(05)65133-6]

42 **Barbagli G**, Sansalone S, Djinovic R, Romano G, Lazzeri M. Current controversies in reconstructive surgery of the anterior urethra: a clinical overview. *Int Braz J Urol* 2012; **38**: 307-316; discussion 316 [PMID: 22765862 DOI: 10.1590/S1677-55382012000300003]

43 **Levine LA**, Strom KH, Lux MM. Buccal mucosa graft urethroplasty for anterior urethral stricture repair: evaluation of the impact of stricture location and lichen sclerosus on surgical outcome. *J Urol* 2007; **178**: 2011-2015 [PMID: 17869301 DOI: 10.1016/j.juro.2007.07.034]

44 **Dubey D**, Sehgal A, Srivastava A, Mandhani A, Kapoor R, Kumar A. Buccal mucosal urethroplasty for balanitis xerotica obliterans related urethral strictures: the outcome of 1 and 2-stage techniques. *J Urol* 2005; **173**: 463-466 [PMID: 15643208 DOI: 10.1097/01.ju.0000149740.02408.19]

45 **Hayes MC**, Malone PS. The use of a dorsal buccal mucosal graft with urethral plate incision (Snodgrass) for hypospadias salvage. *BJU Int* 1999; **83**: 508-509 [PMID: 10210581 DOI: 10.1046/j.1464-410x.1999.00043.x]

46 **Asopa HS**, Garg M, Singhal GG, Singh L, Asopa J, Nischal A. Dorsal free graft urethroplasty for urethral stricture by ventral sagittal urethrotomy approach. *Urology* 2001; **58**: 657-659 [PMID: 11711331 DOI: 10.1016/S0090-4295(01)01377-2]

47 **Cordon BH**, Zhao LC, Scott JF, Armenakas NA, Morey AF. Pseudo-spongioplasty using periurethral vascularized tissue to support ventral buccal mucosa grafts in the distal urethra. *J Urol* 2014; **192**: 804-807 [PMID: 24631104 DOI: 10.1016/j.juro.2014.03.003]

48 **Kulkarni S**, Barbagli G, Sansalone S, Lazzeri M. One-sided anterior urethroplasty: a new dorsal onlay graft technique. *BJU Int* 2009; **104**: 1150-1155 [PMID: 19388990 DOI: 10.1111/j.1464-410X.2009.08590.x]

49 **Kulkarni SB**, Joshi PM, Venkatesan K. Management of panurethral stricture disease in India. *J Urol* 2012; **188**: 824-830 [PMID: 22818345 DOI: 10.1016/j.juro.2012.05.020]

50 **Snodgrass W**, Elmore J. Initial experience with staged buccal graft (Bracka) hypospadias reoperations. *J Urol* 2004; **172**: 1720-1724; discussion 1724 [PMID: 15371799]

51 **Campos F,** Bugeja S, Frost A, Fes E, Ivaz S, Andrich DE, Mundy AR. PD14-11 Single stage versus classical staged approach for penile urethral strictures. *J Urol* 2015; **193**: e322-e323 [DOI: 10.1016/j.juro.2015.02.1340]

52 **Barbagli G**, Palminteri E, Lazzeri M, Guazzoni G. Anterior urethral strictures. *BJU Int* 2003; **92**: 497-505 [PMID: 12930407]

53 **Perovic S**, Barbagli G, Djinovic R, Sansalone S, Vallasciani S, Lazzeri M. Surgical challenge in patients who underwent failed hypospadias repair: is it time to change? *Urol Int* 2010; **85**: 427-435 [PMID: 20847550 DOI: 10.1159/000319856]

54 **Kulkarni S**, Barbagli G, Kirpekar D, Mirri F, Lazzeri M. Lichen sclerosus of the male genitalia and urethra: surgical options and results in a multicenter international experience with 215 patients. *Eur Urol* 2009; **55**: 945-954 [PMID: 18691809 DOI: 10.1016/j.eururo.2008.07.046]

55 **Jackson MJ**, Veeratterapillay R, Harding CK, Dorkin TJ. Intermittent self-dilatation for urethral stricture disease in males. *Cochrane Database Syst Rev* 2014; **12**: CD010258 [PMID: 25523166 DOI: 10.1002/14651858.CD010258.pub2]

56 **Lubahn JD**, Zhao LC, Scott JF, Hudak SJ, Chee J, Terlecki R, Breyer B, Morey AF. Poor quality of life in patients with urethral stricture treated with intermittent self-dilation. *J Urol* 2014; **191**: 143-147 [PMID: 23820057 DOI: 10.1016/j.juro.2013.06.054]

57 **Myers JB**, McAninch JW. Perineal urethrostomy. *BJU Int* 2011; **107**: 856-865 [PMID: 21355988 DOI: 10.1111/j.1464-410X.2011.10139.x]

58 **Johanson B**. Reconstruction of the male urethra in strictures: application of the buried intact epithelium technic. *Acta Chir Scand Suppl* 1953; **176**: 1-103

59 **Stewart L**, McCammon K, Metro M, Virasoro R. SIU/ICUD Consultation on Urethral Strictures: Anterior urethra-lichen sclerosus. *Urology* 2014; **83**: S27-S30 [PMID: 24268357 DOI: 10.1016/j.urology.2013.09.013]

60 **Atala A**, Bauer SB, Soker S, Yoo JJ, Retik AB. Tissue-engineered autologous bladders for patients needing cystoplasty. *Lancet* 2006; **367**: 1241-1246 [PMID: 16631879 DOI: 10.1016/s0140-6736(06)68438-9]

61 **Dorin RP**, Pohl HG, De Filippo RE, Yoo JJ, Atala A. Tubularized urethral replacement with unseeded matrices: what is the maximum distance for normal tissue regeneration? *World J Urol* 2008; **26**: 323-326 [PMID: 18682960 DOI: 10.1007/s00345-008-0316-6]

62 **Fiala R**, Vidlar A, Vrtal R, Belej K, Student V. Porcine small intestinal submucosa graft for repair of anterior urethral strictures. *Eur Urol* 2007; **51**: 1702-1708; discussion 1708 [PMID: 17306922 DOI: 10.1016/j.eururo.2007.01.099]
63 **Palminteri E**, Berdondini E, Colombo F, Austoni E. Small intestinal submucosa (SIS) graft urethroplasty: short-term results. *Eur Urol* 2007; **51**: 1695-1701; discussion 1701 [PMID: 17207913 DOI: 10.1016/j.eururo.2006.12.016]
64 **Palminteri E**, Berdondini E, Fusco F, De Nunzio C, Salonia A. Long-term results of small intestinal submucosa graft in bulbar urethral reconstruction. *Urology* 2012; **79**: 695-701 [PMID: 22245298 DOI: 10.1016/j.urology.2011.09.055]
65 **el-Kassaby A**, AbouShwareb T, Atala A. Randomized comparative study between buccal mucosal and acellular bladder matrix grafts in complex anterior urethral strictures. *J Urol* 2008; **179**: 1432-1436 [PMID: 18295282 DOI: 10.1016/j.juro.2007.11.101]
66 **Orabi H**, AbouShwareb T, Zhang Y, Yoo JJ, Atala A. Cell-seeded tubularized scaffolds for reconstruction of long urethral defects: a preclinical study. *Eur Urol* 2013; **63**: 531-538 [PMID: 22877501 DOI: 10.1016/j.eururo.2012.07.041]
67 **Raya-Rivera A**, Esquiliano DR, Yoo JJ, Lopez-Bayghen E, Soker S, Atala A. Tissue-engineered autologous urethras for patients who need reconstruction: an observational study. *Lancet* 2011; **377**: 1175-1182 [PMID: 21388673 DOI: 10.1016/s0140-6736(10)62354-9]
68 **Osman NI**, Hillary C, Bullock AJ, MacNeil S, Chapple CR. Tissue engineered buccal mucosa for urethroplasty: progress and future directions. *Adv Drug Deliv Rev* 2015; **82-83**: 69-76 [PMID: 25451857 DOI: 10.1016/j.addr.2014.10.006]
69 **Mangera A**, Chapple CR. Tissue engineering in urethral reconstruction--an update. *Asian J Androl* 2013; **15**: 89-92 [PMID: 23042444 DOI: 10.1038/aja.2012.91]
70 **Santucci RA**. Should we centralize referrals for repair of urethral stricture? *J Urol* 2009; **182**: 1259-1260 [PMID: 19683307 DOI: 10.1016/j.juro.2009.06.108]

P- Reviewer: Kilinc M, Naselli A
S- Editor: Qi Y **L- Editor**: A **E- Editor**: Li D

World Journal of Clinical Urology

Submit a Manuscript: http://www.wjgnet.com/esps/
Help Desk: http://www.wjgnet.com/esps/helpdesk.aspx
DOI: 10.5410/wjcu.v5.i1.11

World J Clin Urol 2016 March 24; 5(1): 11-17
ISSN 2219-2816 (online)
© 2016 Baishideng Publishing Group Inc. All rights reserved.

MINIREVIEWS

Use of synthetic grafts in pelvic reconstruction: A path of continued discovery

Seth A Cohen, Shlomo Raz

Seth A Cohen, Shlomo Raz, Division of Pelvic Medicine and Reconstructive Surgery, Department of Urology, UCLA Medical Center, David Geffen School of Medicine at UCLA, Los Angeles, CA 90095-7366, United States

Author contributions: All authors equally contributed to this paper with conception and design of the study, literature review and analysis, drafting and critical revision and editing, and final approval of the final version.

Conflict-of-interest statement: No potential conflicts of interest. No financial support.

Open-Access: This article is an open-access article which was selected by an in-house editor and fully peer-reviewed by external reviewers. It is distributed in accordance with the Creative Commons Attribution Non Commercial (CC BY-NC 4.0) license, which permits others to distribute, remix, adapt, build upon this work non-commercially, and license their derivative works on different terms, provided the original work is properly cited and the use is non-commercial. See: http://creativecommons.org/licenses/by-nc/4.0/

Correspondence to: Shlomo Raz, MD, Professor of Urology, Chief (Division of Pelvic Medicine and Reconstructive Surgery), Director (Fellowship Program in Pelvic Medicine and Reconstructive Surgery), Division of Pelvic Medicine and Reconstructive Surgery, Department of Urology, UCLA Medical Center, David Geffen School of Medicine at UCLA, 200 UCLA Medical Plaza, Suite 140, Los Angeles, CA 90095-7366, United States. sraz@mednet.ucla.edu
Telephone: +1-310-7940206
Fax: +1-310-7940211

Received: November 12, 2015
Peer-review started: November 16, 2015
First decision: December 7, 2015
Revised: January 20, 2016
Accepted: February 14, 2016
Article in press: February 16, 2016
Published online: March 24, 2016

Abstract

Since the 1990s, mesh has been used in pelvic reconstruction to augment repairs for stress urinary incontinence and pelvic organ prolapse (POP). In 2008 and 2011, the United States Food and Drug Administration (FDA) issued Public Health Notifications ultimately informing providers and the public that complications associated with the use of synthetic mesh in the transvaginal repair of POP are not rare. In this review, we (1) examine literature characterizing surgical practice-patterns subsequent to the FDA announcements; (2) describe presentation of mesh-associated complications and outcomes of management; (3) discuss the most recent materials science research; and (4) seek to characterize whether or not mesh has lived up to the long-term efficacy promise of a permanent implant. Durability of mesh-augmented anatomical outcomes do not consistently translate into improved patient satisfaction and subjective outcomes. This, when coupled with the possibility of mesh-associated complications, emphasizes the need for continued innovation beyond the status quo of current synthetic grafts.

Key words: Pelvic organ prolapse; Mesh; Synthetic graft; Mesh-associated complications; Mesh extrusion; Mesh erosion; Host response

© The Author(s) 2016. Published by Baishideng Publishing Group Inc. All rights reserved.

Core tip: While mesh-augmented prolapse repair would appear to improve anatomical outcomes, it does not consistently translate into improved patient satisfaction. The use of mesh implantation has to be balanced with the added morbidity of possible delayed mesh-associated complications over-time. We simply seek to recognize that there will be women who will suffer from adverse outcomes after these implants (just as there

can be complications after any type of surgery); it is important to recognize the need and possible benefit of effective intervention, all the while continuing to challenge ourselves to improve the techniques and materials we use in pelvic reconstruction.

Cohen SA, Raz S. Use of synthetic grafts in pelvic reconstruction: A path of continued discovery. *World J Clin Urol* 2016; 5(1): 11-17 Available from: URL: http://www.wjgnet.com/2219-2816/full/v5/i1/11.htm DOI: http://dx.doi.org/10.5410/wjcu.v5.i1.11

INTRODUCTION

Mesh was introduced into surgical reconstruction of abdominal hernias in the 1950s; it was not until the 1990s that pelvic surgeons began using mesh to augment repairs for stress urinary incontinence (SUI) and pelvic organ prolapse (POP)[1]. The United States Food and Drug Administration (FDA) issued approval for the marketing of these mesh products for such indications through a 510(k), which is a premarket submission made to the FDA demonstrating that the device in question is at least as safe and effective as another approved product (which was abdominal mesh in this instance). Synthetic midurethral slings (MUS) composed of polypropylene for SUI, in addition to transvaginal mesh kits devised for use in POP repairs, were introduced through a number of companies in the ensuing decade, with a resultant diffusion of these products. Most physicians were made aware of these new devices and kits through print advertising in professional journals, manufacturers' hospital sales force, and displays at specialty society meetings[2].

In October 2008 and July 2011, the FDA issued Public Health Notifications ultimately informing providers and the public that "serious complications" associated with the use of synthetic mesh in the transvaginal repair of POP are not rare[3,4]. The most commonly reported complications included vaginal mesh extrusion, mesh contraction associated with vaginal shortening, vaginal tightening, and vaginal pain. The FDA also made clear in this release that the warning was for transvaginal mesh placed for POP and was not inclusive of MUS procedures. In 2012, the FDA required manufacturers of transvaginal mesh POP products and single-incision mini-slings for SUI to conduct postmarket surveillance studies on these devices. In April 2014, the FDA released another update saying it was issuing a proposal to reclassify surgical mesh for transvaginal POP repair from a moderate-risk device (class Ⅱ) to a high-risk device (class Ⅲ), requiring manufacturers to submit a premarket approval application for the agency to evaluate safety and effectiveness[5]. In January 2016, this was approved[6].

Khan *et al*[7] has published work evaluating patterns in POP repair using Public Use Files from the Centers for Medicare and Medicaid Services, identifying a 5% random sample of national beneficiaries with diagnosis codes for POP from 1999 through 2009. Procedure codes were used to evaluate non-surgical and surgical management trends in this cohort. After 2005, when codes were made available, mesh/graft repairs were specifically analyzed as well. In any one year in the cohort, they found the number of women with a diagnosis of POP remained stable. There was no significant change in the rates of POP repairs over the decade. The study did note a rapid rise in mesh use, with 41% of all women undergoing surgery in 2009 having mesh or graft placed at the time of repair. In efforts to frame the impact of the national climate on mesh use, Clemons *et al*[8] utilized an electronic survey of American Urogynecologic Society (AUGS) members between December 2011 and January 2012, to determine how the 2011 FDA safety update impacted use of synthetic mesh products by pelvic surgeons. Frequency of graft use in POP (including transvaginal and transabdominal approaches) and SUI were queried. Fifty-three percent (507 of 962 members) responded; before the FDA warning 90% used synthetic mesh and 34% used biologic grafts in POP repair; 99% used synthetic mesh slings for SUI. After the FDA statement update, transvaginal mesh (for POP repair) use decreased by 40%; 12% stopped using it altogether. There was no change in transabdominal mesh POP procedures (*i.e.*, sacrocolpopexy), use of biologics, or synthetic mesh slings. Wang *et al*[9], performed another trend analysis using a 5% Medicare claims database, from 2001 to 2011, identifying POP diagnoses and related procedures with appropriate coding. The rate of mesh use increased dramatically from 2% of repairs in 2005 to 35% by 2008, at which time the initial FDA warning was issued. Subsequent to the FDA warning, the rate of sacrocolpopexy procedures (abdominally-placed mesh, as opposed to transvaginally-placed mesh) almost doubled yearly until 2011.

Anger *et al*[10] examined short-term outcomes between POP repairs with and without mesh using the national Medicare beneficiaries data set. Reoperation was higher in the POP repair/nonmesh cohort *vs* the POP repair/mesh cohort (6%-7% *vs* 4%, $P < 0.02$). The mesh removal rates were higher in the mesh *vs* nonmesh group (4% *vs* 0%-1%, $P < 0.001$). Mesh use was associated with a small decrease in early reoperation for POP; it was also associated with more dyspareunia, mesh-related complications, and urinary retention, even when controlling for concomitant sling. When examining the literature for more long-term outcomes, a retrospective review of sacrocolpopexy complications reported by Arsene *et al*[11] found median time between initial surgery and first reoperation was 3.9 ± 5.7 years. In 2013, Nygaard *et al*[12] publish long-term outcome results of the randomized, masked 2-year colpopexy and urinary reduction efforts trial. At 7 years follow-up, mesh extrusion/erosion probability estimated by Kaplan-Meier method was 10.5% (95%CI: 6.8-16.1), leading the authors to conclude that abdominal sacrocolpopexy effectiveness must be balanced with long-term risks of mesh and/or suture extrusion/erosion. Previous analysis by the same group had concluded that concomitant

Table 1 Presentation of mesh-associated adverse outcomes

Possible patient risk factors	Possible patient complaints
Prior pelvic surgery	Dyspareunia
Chronic steroid use	Hispareunia
Auto-immune disorders	Worsened urinary incontinence
Factors mitigating wound healing	*De novo* urinary urgency
Smoking	Urinary retention
Significant vaginal atrophy	Vaginal pain/scarring
Concomitant hysterectomy	Vaginal bleeding/discharge
Certain mesh types	Recurrent UTIs
Early resumption of intercourse	Secondary prolapse
	Suprapubic pain
	Groin/lower extremity pain
	Defecatory dysfunction

UTIs: Urinary tract infections.

hysterectomy, smoking, and certain mesh types appear to be modifiable risk factors associated with subsequent mesh complications after sacrocolpopexy[13].

PRESENTATION AND MANAGEMENT OF MESH-ASSOCIATED COMPLICATIONS

Mesh-associated adverse events can be viewed within the framework of immediate and late complications. Additionally, the sphere of influence of mesh-associated complications can be further understood in terms of their local, regional, and possibly systemic impacts. Mesh extrusions and erosions (mesh inside the lower urinary or gastrointestinal tract) are examples of adverse outcomes that can actually be either immediate or late complications. Vaginal mesh extrusion occurs secondary to inadequate coverage of vaginal tissue, poor vascularity, early resumption of sexual intercourse, and placement of the mesh within a thin, attenuated vaginal wall[14]. Local signs/symptoms of mesh-associated adverse outcomes can include acute urinary retention, urinary urgency, persistent vaginal bleeding/discharge, vaginal pain/scarring, and dyspareunia (if a male partner reports pain during relations, this has been described as "hispareunia"). Regional complications can include groin pain, leg pain, suprapubic pain, secondary POP, and possibly, defecatory dysfunction. In addition, further areas of ongoing research include possible systemic reactions to implanted synthetic mesh products. It should be clearly stated - there is no objective data yet to date to support a connection or etiology that would explain systemic symptoms caused by placement of synthetic mesh. A mechanism for this may or may not be an actual reality. That being said, at our tertiary referral center, approximately 20% of patients presenting with possible mesh-associated adverse outcomes report a constellation of *de novo* symptoms including but not limited to: Intermittent skin rashes, joint pain, myalgias, cough, and/or alopecia.

The management of mesh complications has developed into an emerging field, termed by some "meshology", with a need for specialized training within Female Pelvic Medicine and Reconstructive Surgery fellowships[15,16]. Methods for the management of vaginal mesh extrusion are described in the literature, ranging from observation alone, to use of topical estrogen or antiseptics, systemic or topical antibiotics, office-based trimming of the extruded material, and operative excision, at times requiring significant pelvic reconstruction[17]. When counseling patients regarding possible mesh complications, those at increased risk have vaginal atrophy, prior surgery, previous chronic steroid use, auto-immune disorders, or other factors which may mitigate wound healing (Table 1). Tijdink *et al*[18] noted differences in mesh-related symptoms, dependent upon the mesh insertion procedure, with pain and dyspareunia mainly seen after vaginal mesh insertion and vaginal bleeding and discharge after sacrocolpopexy. Protrusion of sling material or banding in the lateral fornices has been described as an etiology of persistent dyspareunia in patients with a MUS placed through the transobturator approach[19]. A retrospective review of 90 patients over a year who underwent retropubic placement of a MUS revealed 4 patients with vaginal extrusion of mesh; 2 patients were asymptomatic, with mesh extrusion identified at routine physical examination 6 wk postoperatively. Two patients had persistent vaginal discharge at 6 wk postoperatively, including 1 who complained primarily of partner discomfort during sexual intercourse[20]. Each patient was observed conservatively, without medication or surgical intervention and asked to abstain from sexual intercourse; 3 mo postoperatively all 4 had complete spontaneous epithelialization over the mesh. In a retrospective review of 73 patients who underwent complete and/or partial mesh excisions secondary to mesh-related symptoms subsequent to POP or SUI surgery, 63% failed conservative management with estrogen cream, antibiotics, and/or physiotherapy[18]. Literature supports the surgical excision of mesh if 3 mo of conservative treatment has resulted in no improvement or the erosion is more than 1 cm[21].

Multiple groups have reported outcomes of their series regarding mesh removal in the setting of mesh complications. In a multicenter, retrospective review, Unger *et al*[22] reported the results of surveys given to 101 women treated for vaginal mesh complications; 51% of women in the study underwent surgical management as treatment, and less than 10% required a second surgery. Sixty-three percent (19 of 30) of patients with pain prior to intervention reported significant improvement after treatment; however, almost a third reported worsening pain or no change after surgical management. Less than half of patients with voiding dysfunction improved after intervention[22]. In another study, validated instruments were administered to 84 women whom had experienced complications associated with vaginal mesh; each had undergone some type of treatment (surgical intervention, treatment by pelvic pain specialists, or physical therapists)[23]. The study's mean interval since presentation was 2.3 years. Twenty-two percent of reported vaginal discharge, 15% vaginal

bleeding or spotting, and 45% sexual abstinence due to problems related to mesh. Despite 2 years of tertiary care level multidisciplinary treatment, 29% were the same or worse.

Hammett *et al*[24] reported a single-center, 10-year retrospective review of patient satisfaction after surgical excision of mesh, in the setting of mesh-associated complications; a total of 57-patients (including both MUS and vaginal mesh for POP) were included with a diagnosis of mesh extrusion into the vaginal wall[24]. The International Continence Society (ICS) and International Urogynecological Association classification system was used to describe the mesh complications. The most common presenting patient complaints were chronic pelvic pain (55.9%), dyspareunia (54.4%), and vaginal discharge (30.9%). At a 6-wk post-operative visit, 57.3% of patient's symptoms were completely resolved and 14.6% were improved. Hokenstad *et al*[25] were able to analyze surveys given to 41 patients who had undergone excision of vaginal mesh placed for treatment of POP. Only 54% reported successful outcomes after mesh excision, with only 3 of 23 patients reporting resolution of dyspareunia. The authors found that patients who had complete excision of mesh, new overactive bladder symptoms after mesh placement, and a body mass index higher than 30 kg/m^2 were more likely to report improvement. Blaivas *et al*[26] reported patient improvement after surgical intervention in 47 women with associated mesh-complications. Surgical procedures included sling incision, sling excision, urethrolysis, urethral reconstruction, ureteroneocystoscomy, cystectomy and urinary diversion, and enterocystoplasty. With a median follow-up of 2 years (range 0.25 to 12, mean 3), successful outcome was achieved in 34 of 47 patients (72%) after the initial salvage surgery.

In 2015, Rogo-Gupta *et al*[27] reported outcomes of a large series of women, all of whom had undergone removal of synthetic or biological implants between 2005 and 2012. Of the 306 patients, 57% underwent removal for extrusion or erosion, 46% for pain, and 54% for urinary symptoms or incontinence. Twenty-nine percent of had previous revision. Eleven percent of had POP implants, 48% had sling implants, and 41% had both. Seventy-eight percent of the population with pain reported improvement, 14% had worsening of pain, and 9% reported no change. Overall quality of life significantly improved for those who underwent removal of POP and sling implants, and sling implants alone; however, this was not the case for those with only POP implant removal.

Over the last 5 years, our group has performed over 1200 surgical procedures to remove pelvic mesh (implanted for all indications - including urinary incontinence and POP), in the setting of vaginal bleeding, dyspareunia, and recurrent urinary tract infections with associated mesh extrusion/erosion, in addition to persistent groin and pelvic pain, which only began after mesh implantation. This has provided a robust experience in patient recovery after mesh explantation. Reflecting an oft capitulated concern of worsening incontinence in the setting of mesh removal, we sought to objectively quantify the rate of recurrent urinary incontinence and progression to another anti-incontinence surgery. A portion of this research was recently presented by Ramart *et al*[28] at the ICS 2015 Annual Meeting, entitled "Urinary Incontinence After Suburethral Mesh Removal Requiring Anti-Incontinence Procedures". The research summarizes a retrospective review of 117 continent patients who underwent mid-urethral sling removal for mesh associated complications, most commonly of which was persistent vaginal/pelvic pain [70 retropubic mid-urethral slings (RPMS) and 47 transobturator mid-urethral slings (TOMS)]. At 1-year follow-up, 38.6% of the RPMS and 34% of TOMS had recurrent SUI requiring an anti-incontinence procedure. Thus, in an initially continent population, post-mesh-removal, approximately one-third of patients progressed to an anti-incontinence procedure within 1 year.

ONGOING MATERIALS SCIENCE RESEARCH

The host response to implanted biomaterials is a series of events that could potentially impact overall tissue functionality and contribute to or even detract from clinical outcomes. As researchers look at materials design, there is now a body of research examining the ability to modulate host-response to implanted synthetic grafts in animal models. For instance, work by Nohuz *et al*[29] has investigated the use of hyaluronate carbxymethylcellulose-based bioresorbable membrane and auto-cross-linked polysaccharide hyaluronan-based solution to prevent polypropylene shrinkage in a rat model; there was significantly less shrinkage of mesh (19.12% and 17%) with the application of these materials compared to a control with a median mesh shrinkage of 29% (P-values < 0.05)[28]. The strategy of augmenting the synthetic mesh with an overlying layer or coating is not new. In 2014, Rudnicki *et al*[30] reported their outcomes after implanting collagen-coated mesh for cystocele, comparing it with a conventional anterior colporrhaphy. Although the objective cure rate was significantly improved in the collagen-coated mesh repairs, it was associated with a high exposure rate (13.3%) and no difference in quality of life or sexual function on administered questionnaires, compared to conventional repair. Lo *et al*[31] also reported a notable rate of mesh exposure, 15%, during following-up after implantation of collagen-coated mesh for anterior repair.

In 2014, Wolf *et al*[32] investigated the ability to manipulate macrophage polarization following mesh implantation. They performed spatiotemporal analysis of macrophage polarization in response to uncoated polypropylene mesh and mesh coated with hydrated and dry forms of extracellular matrix (ECM) hydrogels derived from either dermis or urinary bladder. The authors concluded that ECM coatings attenuate the pro-inflammatory M1 macrophage response and reduce the

number of foreign body giant cells to polypropylene mesh *in vivo*. With the goal of contributing to the development of synthetic implants that minimize surface area interface and increase integration with host tissue long-term, Faulk *et al*[33] investigated the effects of an ECM hydrogel coating on the long-term host tissue response to propylene mesh in a rodent model of abdominal muscle injury. At 14 d post implantation, the ECM coated polypropylene mesh devices showed a decreased inflammatory response as characterized by the number and distribution of M1 macrophages around mesh fibers when compared to the uncoated mesh devices. At 180 d, the ECM coated polypropylene showed decreased density of collagen and amount of mature type Ⅰ collagen deposited between mesh fibers when compared to the uncoated mesh devices. The authors concluded this work confirmed and extended the previous findings that an ECM coating mitigates chronic inflammatory response and associated scar tissue deposition. Dias *et al*[34] have examined the use of highly purified collagen gel coating in the immune-inflammatory response, host collagen metabolism, and angiogenesis around propylene mesh in a Wistar rat model. Using 20 Wistar rats, monofilament polypropylene mesh was implanted on one side of the abdominal wall and on the other side a mesh coated with a new highly purified collagen gel was implanted. Sacrificing the animals at 7, 14, 21, and 90 d, multiple assays were performed, including immunohistochemical analysis using interleukin 1 and surface antigen CD-31. The authors concluded that purified collagen coating can impact angiogenesis and the immune reaction of metalloproteinase around mesh implants in rats. This knowledge could contribute to the design of future synthetic grafts used in pelvic floor surgery.

At the 36th Annual Scientific Meeting of AUGS, in October 2015 in Seattle, Washington, Hachim *et al*[35] presented their paper, "Effects of Aging Upon the Host Response to Polypropylene Mesh," in which they sought to define the effects of aging upon the host response to polypropylene mesh, with particular emphasis on the participation of macrophages. After implanting mesh subcutaneously in young mice (6-8 wk old) and aged mice (18-20 mo old), implants were harvested at delayed time points and host response examined with multiple assays including histologic staining, along with subsequent *in vitro* studies to investigate the impact of ECMs on observed macrophage phenotype. The authors concluded that the results suggest differences in the character of the host macrophage response to mesh in aged animals, with possible effects upon downstream integration of implants, finding that the host response appears to be a function of at least both cell-intrinsic defects and the local ECM microenvironement.

As did Hachim *et al*[35] (previously described), Mellano *et al*[36] presented their work entitled: "The role of bacterial biofilms and chronic inflammation in the delayed development of pain following transvaginal placement of mesh slings for incontinence", in October 2015, at the 36th Annual Scientific Meeting of AUGS. The authors examined the possibility of delayed-onset pelvic pain being attributable to bacterial seeding of mesh implanted transvaginally; they described findings from a cohort of women whom reported new onset pelvic pain at least 6 mo after synthetic mesh placement. The study included 20 patients, 18 with delayed-onset pelvic pain and 2 controls (patients with urinary obstruction, no pelvic pain), whom had surgically-removed mesh examined for the presence of bacterial species by polymerase chain reaction-based amplification of bacterial ribosomal RNA (rRNA). Bacterial rRNA transcipts were present in all patients with delayed onset pelvic pain, but not present in the patients with urinary obstruction (no pain). The bacterial species identified were different from vaginal flora cultured at the time of mesh removal (reducing the likelihood the findings were secondary to a contaminated field). The authors concluded that unavoidable colonization of vaginal mesh at the time of transvaginal mesh placement may result in a bacterial biofilm that could contribute to possible delayed-onset pain, through a yet to be characterized mechanism.

CONCLUSION

When introduced into the practices of pelvic floor surgeons, the promise of synthetic mesh was outcomes more durable than biologics and native tissue repairs. Recently, Kenton *et al*[37] reported 5-year outcomes of women enrolled in an observational cohort study after having completed the Trial of Mid-urethral Slings study. The primary outcome, treatment success, was defined as no re-treatment or self-reported SUI symptoms. At 5 years, this was 51.3% in women assigned to the retropubic sling and 43.4% in women assigned to the transobturator sling; contrary to previously held beliefs, just as with biological materials, permanent mesh slings showed a progressive decrease in efficacy over time.

Thus, one has to ask - does the field of pelvic medicine and reconstructive surgery really need polypropylene mesh? Withagen *et al*[38] reported findings from their randomized control trial examining conventional vaginal repair (97 women) *vs* repair with trocar-guided tension free vaginal mesh (93 women), in a population with recurrent POP. Twelve months after surgery, anatomic treatment failure in the treated compartment was observed in 45.2% of the conventional group and 9.6% of the mesh group ($P < 0.001$); subjective improvement was reported in 80% of the conventional group and 81% in the mesh group. Mesh exposure was detected in 16.9% of the mesh repair patients. This is just an example of how important it is to understand that curing the anatomy is not the most important factor for patients' perceptions of success; the subjective outcomes are the same in both arms of this trial. However, the after-effects of mesh-associated complications (and 16.9% of this group had mesh exposure within 12 mo) can linger with patients for years potentially.

While the previously described literature represents advances in biomaterials science and the ability to impact

host-response in animal models, it is not known if this body of knowledge will translate into clinically meaningful and relevant alterations in the design of future synthetic grafts utilized (*i.e.*, would modifications ultimately impact patients long-term outcomes). While mesh augmented POP repair would appear to improve anatomical outcomes, this does not consistently translate into improved patient satisfaction and subjective outcomes. The use of mesh implantation has to be balanced with the added morbidity of possible delayed mesh extrusion/erosion over-time. The future of POP surgical repair may very well be in new, more durable biologics, completely moving beyond any continued use of synthetic materials.

In an opinion-piece in 2013, Chapple *et al*[39] noted that although mesh insertion may seem like an easy procedure, treating complications of mesh surgery may require extensive and complex procedures; even with mesh removal, it is possible that more than 30% of patients may be permanently disabled or experience long-term symptoms. The full scope of patients requiring reoperation in the setting of previous mesh placement may still be largely unknown, as the presentations can occur years later, as women age and post-menopausal status impacts on tissue quality compound. Thus, there is a subset of the patient population that will have mesh-associated complications, some of whom will benefit from surgical revision and a portion of whom will not. The work presented by Ramart *et al*[28] at the recent ICS Annual Meeting provides an objective assessment of progression to additional anti-continence surgery within 1 year of sub-urethral mesh removal (approximately 1/3 of patients). Determining what makes an individual more at-risk for any of the myriad of mesh-associated complications and ameliorating any such risk is the subject of ongoing research efforts. It should be underscored that this review is not a critique of the use of mesh in pelvic surgery. Our national organizations, AUGS and the Society of Urodynamics, Female Pelvic Medicine, and Urogenital Reconstruction, have put forth well-written statements endorsing the safety of the polypropylene mesh mid-urethral sling for SUI[40]. We simply seek to recognize that there will be women who will suffer from complications after these implants (just as there can be complications and poor outcomes after any type of surgery), and it is important to recognize the need and possible benefit of effective intervention, all the while continuing to challenge ourselves to improve the techniques and materials we use in pelvic reconstruction.

REFERENCES

1 **Kuhlmann-Capek MJ**, Kilic GS, Shah AB, Diken ZM, Snyder RR, Phelps JY. Enmeshed in Controversy: Use of Vaginal Mesh in the Current Medicolegal Environment. *Female Pelvic Med Reconstr Surg* 2015; **21**: 241-243 [PMID: 26313491 DOI: 10.1097/SPV.0000000000000192]

2 **Washington JL**. Commercial products for pelvic repair. *Female Pelvic Med Reconstr Surg* 2011; **17**: 218-225 [PMID: 22453104 DOI: 10.1097/SPV.0b013e31822d407a]

3 Public Health Notifications (Medical Devices) - FDA Public Health Notification: Serious Complications Associated with Transvaginal Placement of Surgical Mesh in Repair of Pelvic Organ Prolapse and Stress Urinary Incontinence. 2015. Available from: URL: http://www.fda.gov/medicaldevices/safety/alertsandnotices/publichealthnotifications/ucm061976.htm

4 Safety Communications - UPDATE on Serious Complications Associated with Transvaginal Placement of Surgical Mesh for Pelvic Organ Prolapse: FDA Safety Communication. 2015. Available from: URL: http://www.fda.gov/MedicalDevices/Safety/AlertsandNotices/ucm262435.htm

5 Press Announcements - FDA issues proposals to address risks associated with surgical mesh for transvaginal repair of pelvic organ prolapse. 2015. Available from: URL: http://www.fda.gov/NewsEvents/Newsroom/PressAnnouncements/ucm395192.htm

6 Press Announcements - FDA strengthens requirements for surgical mesh for the transvaginal repair of pelvic organ prolapse to address safety risks. 2016. Available from: URL: http://www.fda.gov/NewsEvents/Newsroom/PressAnnouncements/ucm479732.htm?source=govdelivery&utm_medium=email&utm_source=govdelivery

7 **Khan AA**, Eilber KS, Clemens JQ, Wu N, Pashos CL, Anger JT. Trends in management of pelvic organ prolapse among female Medicare beneficiaries. *Am J Obstet Gynecol* 2015; **212**: 463.e1-463.e8 [PMID: 25446663 DOI: 10.1016/j.ajog.2014.10.025]

8 **Clemons JL**, Weinstein M, Guess MK, Alperin M, Moalli P, Gregory WT, Lukacz ES, Sung VW, Chen BH, Bradley CS. Impact of the 2011 FDA transvaginal mesh safety update on AUGS members' use of synthetic mesh and biologic grafts in pelvic reconstructive surgery. *Female Pelvic Med Reconstr Surg* 2013; **19**: 191-198 [PMID: 23797515 DOI: 10.1097/SPV.0b013e31829099c1]

9 **Wang LC**, Al Hussein Al Awamlh B, Hu JC, Laudano MA, Davison WL, Schulster ML, Zhao F, Chughtai B, Lee RK. Trends in Mesh Use for Pelvic Organ Prolapse Repair From the Medicare Database. *Urology* 2015; **86**: 885-891 [PMID: 26344153 DOI: 10.1016/j.urology.2015.08.022]

10 **Anger JT**, Khan AA, Eilber KS, Chong E, Histed S, Wu N, Pashos CL, Clemens JQ. Short-term outcomes of vaginal mesh placement among female Medicare beneficiaries. *Urology* 2014; **83**: 768-773 [PMID: 24680446 DOI: 10.1016/j.urology.2013.10.072]

11 **Arsene E**, Giraudet G, Lucot JP, Rubod C, Cosson M. Sacral colpopexy: long-term mesh complications requiring reoperation(s). *Int Urogynecol J* 2015; **26**: 353-358 [PMID: 25323309 DOI: 10.1007/s00192-014-2514-7]

12 **Nygaard I**, Brubaker L, Zyczynski HM, Cundiff G, Richter H, Gantz M, Fine P, Menefee S, Ridgeway B, Visco A, Warren LK, Zhang M, Meikle S. Long-term outcomes following abdominal sacrocolpopexy for pelvic organ prolapse. *JAMA* 2013; **309**: 2016-2024 [PMID: 23677313 DOI: 10.1001/jama.2013.4919]

13 **Cundiff GW**, Varner E, Visco AG, Zyczynski HM, Nager CW, Norton PA, Schaffer J, Brown MB, Brubaker L. Risk factors for mesh/suture erosion following sacral colpopexy. *Am J Obstet Gynecol* 2008; **199**: 688.e1-688.e5 [PMID: 18976976 DOI: 10.1016/j.ajog.2008.07.029]

14 **Chermansky CJ**, Winters JC. Complications of vaginal mesh surgery. *Curr Opin Urol* 2012; **22**: 287-291 [PMID: 22617058 DOI: 10.1097/MOU.0b013e32835480b2]

15 **Winters JC**. Vaginal mesh explantation: an emerging urological discipline. *J Urol* 2012; **187**: 1529-1530 [PMID: 22425097 DOI: 10.1016/j.juro.2012.02.012]

16 **Lee D**, Zimmern PE. Management of complications of mesh surgery. *Curr Opin Urol* 2015; **25**: 284-291 [PMID: 26049869 DOI: 10.1097/MOU.0000000000000187]

17 **Marks BK**, Goldman HB. Controversies in the management of mesh-based complications: a urology perspective. *Urol Clin North Am* 2012; **39**: 419-428 [PMID: 22877726 DOI: 10.1016/j.ucl.2012.05.009]

18 **Tijdink MM**, Vierhout ME, Heesakkers JP, Withagen MI. Surgical management of mesh-related complications after prior pelvic floor reconstructive surgery with mesh. *Int Urogynecol J* 2011; **22**: 1395-1404 [PMID: 21681595 DOI: 10.1007/s00192-011-1476-2]

19 **Cholhan HJ**, Hutchings TB, Rooney KE. Dyspareunia associated

with paraurethral banding in the transobturator sling. *Am J Obstet Gynecol* 2010; **202**: 481.e1-481.e5 [PMID: 20227671 DOI: 10.1016/j.ajog.2010.01.061]

20 **Kobashi KC**, Govier FE. Management of vaginal erosion of polypropylene mesh slings. *J Urol* 2003; **169**: 2242-2243 [PMID: 12771759 DOI: 10.1097/01.ju.0000060119.43064.f6]

21 **Huang KH**, Kung FT, Liang HM, Chang SY. Management of polypropylene mesh erosion after intravaginal midurethral sling operation for female stress urinary incontinence. *Int Urogynecol J Pelvic Floor Dysfunct* 2005; **16**: 437-440 [PMID: 15654499 DOI: 10.1007/s00192-004-1275-0]

22 **Unger CA**, Abbott S, Evans JM, Jallad K, Mishra K, Karram MM, Iglesia CB, Rardin CR, Barber MD. Outcomes following treatment for pelvic floor mesh complications. *Int Urogynecol J* 2014; **25**: 745-749 [PMID: 24318564 DOI: 10.1007/s00192-013-2282-9]

23 **Hansen BL**, Dunn GE, Norton P, Hsu Y, Nygaard I. Long-term follow-up of treatment for synthetic mesh complications. *Female Pelvic Med Reconstr Surg* 2014; **20**: 126-130 [PMID: 24763152 DOI: 10.1097/SPV.0000000000000084]

24 **Hammett J**, Peters A, Trowbridge E, Hullfish K. Short-term surgical outcomes and characteristics of patients with mesh complications from pelvic organ prolapse and stress urinary incontinence surgery. *Int Urogynecol J* 2014; **25**: 465-470 [PMID: 24085144 DOI: 10.1007/s00192-013-2227-3]

25 **Hokenstad ED**, El-Nashar SA, Blandon RE, Occhino JA, Trabuco EC, Gebhart JB, Klingele CJ. Health-related quality of life and outcomes after surgical treatment of complications from vaginally placed mesh. *Female Pelvic Med Reconstr Surg* 2015; **21**: 176-180 [PMID: 25349942 DOI: 10.1097/SPV.0000000000000142]

26 **Blaivas JG**, Purohit RS, Weinberger JM, Tsui JF, Chouhan J, Sidhu R, Saleem K. Salvage surgery after failed treatment of synthetic mesh sling complications. *J Urol* 2013; **190**: 1281-1286 [PMID: 23523928 DOI: 10.1016/j.juro.2013.03.044]

27 **Rogo-Gupta L**, Grisales T, Huynh L, Rodríguez LV, Raz S. Symptom Improvement After Prolapse and Incontinence Graft Removal in a Case Series of 306 Patients. *Female Pelvic Med Reconstr Surg* 2015; **21**: 319-324 [PMID: 26506159 DOI: 10.1097/SPV.0000000000000191]

28 **Ramart P**, Ackerman AL, Cohen SA, Kang D, Choi J, Kim JH, Raz S. Abstract 507: Urinary Incontinence After Suburethral Mesh Removal Requiring Anti-incontinence Procedure. *Neurourol Urodyn* 2015; **34** (S3): S423- S425 [DOI: 10.1002/nau.22830]

29 **Nohuz E**, Alaboud M, Darcha C, Alloui A, Aublet-Cuvelier B, Jacquetin B. Effectiveness of Hyalobarrier and Seprafilm to prevent polypropylene mesh shrinkage: a macroscopic and histological experimental study. *Int Urogynecol J* 2014; **25**: 1081-1087 [PMID: 24599179 DOI: 10.1007/s00192-014-2357-2]

30 **Rudnicki M**, Laurikainen E, Pogosean R, Kinne I, Jakobsson U, Teleman P. Anterior colporrhaphy compared with collagen-coated transvaginal mesh for anterior vaginal wall prolapse: a randomised controlled trial. *BJOG* 2014; **121**: 102-110; discussion 110-111 [PMID: 24118844 DOI: 10.1111/1471-0528.12454]

31 **Lo TS**, Tan YL, Khanuengkitkong S, Dass AK, Cortes EF, Wu PY. Assessment of collagen-coated anterior mesh through morphology and clinical outcomes in pelvic reconstructive surgery for pelvic organ prolapse. *J Minim Invasive Gynecol* 2014; **21**: 753-761 [PMID: 24607796 DOI: 10.1016/j.jmig.2014.02.013]

32 **Wolf MT**, Dearth CL, Ranallo CA, LoPresti ST, Carey LE, Daly KA, Brown BN, Badylak SF. Macrophage polarization in response to ECM coated polypropylene mesh. *Biomaterials* 2014; **35**: 6838-6849 [PMID: 24856104 DOI: 10.1016/j.biomaterials.2014.04.115]

33 **Faulk DM**, Londono R, Wolf MT, Ranallo CA, Carruthers CA, Wildemann JD, Dearth CL, Badylak SF. ECM hydrogel coating mitigates the chronic inflammatory response to polypropylene mesh. *Biomaterials* 2014; **35**: 8585-8595 [PMID: 25043571 DOI: 10.1016/j.biomaterials.2014.06.057]

34 **Dias FG**, Prudente A, Siniscalchi RT, de Vidal BC, Riccetto CL. Can highly purified collagen coating modulate polypropylene mesh immune-inflammatory and fibroblastic reactions? Immunohistochemical analysis in a rat model. *Int Urogynecol J* 2015; **26**: 569-576 [PMID: 25335748 DOI: 10.1007/s00192-014-2529-0]

35 **Hachim D**, Mani D, LoPresti ST, Brown BN. Paper Number 21: Effects of Aging Upon the Host Response to Polypropylene Mesh. *Female Pelvic Med Reconstr Surg* 2015; **21**: S10 [DOI: 10.1097/spv.0000000000000205]

36 **Mellano EM**, Lima B, Ramart P, Ackerman AL, Lux R, Shi W, Raz S. Poster 10: The Role of Bacterial Biofilms and Chronic Inflammation in the Delayed Development of Pain Following Transvaginal Placement of Mesh Slings for Incontinence. *Female Pelvic Med Reconstr Surg* 2015; **21**: S59 [DOI: 10.1097/spv.0000000000000207]

37 **Kenton K**, Stoddard AM, Zyczynski H, Albo M, Rickey L, Norton P, Wai C, Kraus SR, Sirls LT, Kusek JW, Litman HJ, Chang RP, Richter HE. 5-year longitudinal followup after retropubic and transobturator mid urethral slings. *J Urol* 2015; **193**: 203-210 [PMID: 25158274 DOI: 10.1016/j.juro.2014.08.089]

38 **Withagen MI**, Milani AL, den Boon J, Vervest HA, Vierhout ME. Trocar-guided mesh compared with conventional vaginal repair in recurrent prolapse: a randomized controlled trial. *Obstet Gynecol* 2011; **117**: 242-250 [PMID: 21252735 DOI: 10.1097/AOG.0b013e318203e6a5]

39 **Chapple CR**, Raz S, Brubaker L, Zimmern PE. Mesh sling in an era of uncertainty: lessons learned and the way forward. *Eur Urol* 2013; **64**: 525-529 [PMID: 23856039 DOI: 10.1016/j.eururo.2013.06.045]

40 **Nager C**, Tulikangas P, Miller D, Rovner E, Goldman H. Position statement on mesh midurethral slings for stress urinary incontinence. *Female Pelvic Med Reconstr Surg* 2014; **20**: 123-125 [PMID: 24763151 DOI: 10.1097/SPV.0000000000000097]

P- Reviewer: Markic D, Santoro GA
S- Editor: Ji FF **L- Editor**: A **E- Editor**: Li D

World Journal of Clinical Urology

Submit a Manuscript: http://www.wjgnet.com/esps/
Help Desk: http://www.wjgnet.com/esps/helpdesk.aspx
DOI: 10.5410/wjcu.v5.i1.18

World J Clin Urol 2016 March 24; 5(1): 18-23
ISSN 2219-2816 (online)
© 2016 Baishideng Publishing Group Inc. All rights reserved.

MINIREVIEWS

Bladder cancer exosomes: Getting the message across

Claudia Berrondo, Thomas Osinski, Carla J Beckham

Claudia Berrondo, Carla J Beckham, Department of Urology, University of Rochester, Rochester, NY 14642, Unites States

Thomas Osinski, School of Medicine and Dentistry, University of Rochester, Rochester, NY 14642, Unites States

Author contributions: Berrondo C contributed to conception, literature review, drafting, editing and final approval of the final version; Osinski T contributed to drafting and final approval of the final version; Beckham CJ contributed to conception, literature review, editing and final approval of the final version.

Conflict-of-interest statement: No potential conflicts of interest.

Open-Access: This article is an open-access article which was selected by an in-house editor and fully peer-reviewed by external reviewers. It is distributed in accordance with the Creative Commons Attribution Non Commercial (CC BY-NC 4.0) license, which permits others to distribute, remix, adapt, build upon this work non-commercially, and license their derivative works on different terms, provided the original work is properly cited and the use is non-commercial. See: http://creativecommons.org/licenses/by-nc/4.0/

Correspondence to: Carla J Beckham, MD, PhD, Assistant professor, Department of Urology, University of Rochester, 601 Elmwood Ave, Rochester, NY 14642,
United States. carla_beckham@urmc.rochester.edu
Telephone: +1-585-2089866
Fax: +1-585-2731068

Received: August 24, 2015
Peer-review started: August 26, 2015
First decision: September 28, 2015
Revised: October 13, 2015
Accepted: January 5, 2016
Article in press: January 7, 2016
Published online: March 24, 2016

Abstract

Bladder cancer is the seventh most common cancer in men and the seventeenth most common in women. It is also the most expensive cancer to treat over the lifetime of a patient, partially due to the necessity of frequent cystoscopy to monitor for tumor recurrence. There have also been no new developments for the treatment of bladder cancer in the last several decades. Exosomes are small, secreted, membrane-bound vesicles representative of the donor cell. Increasing understanding of the role of exosomes in cancer biology has inspired interest in their potential use as a non-invasive diagnostic tool, prognostic markers and/or indicator of recurrence of bladder cancer, and even for use in the treatment of bladder cancer. Exosomes can be readily isolated from urine. Several groups have already demonstrated differences in the protein and micro RNA content of exosomes in bladder cancer patients compared to normal healthy volunteers. Furthermore, cancer cell-derived exosomes mediate tumor progression through the delivery of their biologically active content to recipient cells. Exosomes may be useful for the delivery of targeted molecules for the treatment of bladder cancer.

Key words: Bladder cancer; Cystoscopy; Exosome; Biomarker; Urine

© The Author(s) 2016. Published by Baishideng Publishing Group Inc. All rights reserved.

Core tip: Exosomes are small membrane-bound vesicles representative of their donor cell. There is growing interest in understanding the function of exosomes in diseases such as cancer. Because of their unique properties, there is developing interest in using exosomes as biomarkers, and as a therapeutic modality in cancer. There is a critical need for affordable, non-invasive methods for diagnosis and monitoring for recurrence of bladder cancer as well as novel therapeutic options. Exosomes have the potential to meet these needs. In this review, we explore what is currently known about exosomes and their role in bladder cancer.

Berrondo C, Osinski T, Beckham CJ. Bladder cancer exosomes: Getting the message across. *World J Clin Urol* 2016; 5(1): 18-23

Available from: URL: http://www.wjgnet.com/2219-2816/full/v5/i1/18.htm DOI: http://dx.doi.org/10.5410/wjcu.v5.i1.18

INTRODUCTION

The first reliable documentation of exosomes was in the 1970's with the observation of the release of membrane-bound vesicles into the extracellular space after fusion of an endosome with the plasma membrane[1,2]. For many years, exosomes were thought to be a method of disposing of cellular content. In the late 1990's, a few publications emerged demonstrating that exosomes may have a role in intercellular communication. Raposo *et al*[3] demonstrated that exosomes released by B cells could stimulate $CD4^+$ T cells *in vitro*. Zitvogel *et al*[4] found that exosomes released by human dendritic cells which were tumor peptide-pulsed could suppress or eradicate established murine tumors. These finding led to an increased interest in understanding the role of exosomes in both the normal state, and eventually disease processes.

Exosomes are formed from the endocytic pathway. Early endosomes recognize and incorporate ubiquitinated proteins[5]. This process leads to the formation of an intraluminal vesicle giving rise to multivesicular bodies (MVBs). The MVBs then fuses with the plasma membrane releasing the contents into the extracellular space. Exosomes are the resulting 30-150 nm membrane-bound extra cellular vesicles with a typical density of 1.15 to 1.19 g/mL[5]. Exosomes are secreted by many different cell types, and are found in most body fluids including blood, urine, semen, saliva and breast milk. Exosomes are representative of their cells of origin[5-8]. They contain cytoplasmic and membrane proteins, micro RNA (miRNA), messenger RNA (mRNA), long non-coding RNA (lncRNA), and even short DNA segments. Exosomes are also enriched in certain lipids including cholesterol, ceramide, sphingolipids and phosphoglycerides with long saturated fatty acids[6-8].

Exosomes have many biological functions which are dependent on their cells of origin. Examples include modulation of the immune system, programmed cell death, angiogenesis, inflammation and coagulation. Exosomes also have roles in many pathologic conditions such as infectious diseases, neurodegenerative disease, cardiovascular disease, and cancer[5,7,9].

EXOSOME ISOLATION

There are multiple isolation methods available to the exosome researcher. The investigator must decide what the downstream application of the exosome preparation is intended for in order to determine the most reasonable approach. Isolation by ultracentrifugation is considered the "gold standard" for exosomes isolation in the literature. However, due to the time-commitment associated with this method, several other approaches have been investigated and applied. Each of the following methods can be used for isolation of exosomes from several different sample sources including cell culture medium and urine.

Isolation by ultracentrifugation

Serial centrifugation with or without filtration followed by ultracentrifugation is the most widely accepted method for exosome isolation[6,10-14]. Several protocols have been used in the literature with varying speed, duration and number of low-speed centrifugation and ultra-centrifugation steps. The process begins with a series of low speed centrifugation steps to remove cells and larger vesicles. The supernatants are then collected and subjected to ultracentrifugation. This method alone is insufficient to isolate pure exosomes, but the addition of filtration and the use of a 30% sucrose cushion or 5%-30% sucrose gradient step increases the purity of the isolation. The use of a sucrose cushion or gradient allows the low-density exosomes to be separated from other higher-density vesicles, contaminating particles and protein complexes. This isolation strategy maintains the exosome structure, but is time-consuming[11,12,15-17]. If one wishes to use exosomes for functional studies, purification by ultracentrifugation with sucrose cushion or sucrose gradients yield the most purified exosomes at the lowest cost.

Immunoaffinity

In this method, antibodies to surface proteins on the exosomes are used for isolation. Antibodies are associated with beads or other matrices to immobilize them. The target exosome surface proteins bind covalently to the antibodies allowing isolation from other particles. Immunoaffinity allows for specific exosome isolation. However, it requires a clean-up procedure to remove proteins that are bound in a nonspecific manner. This process is often inefficient, yielding very few exosomes for downstream functional studies, and is very expensive[11,12,15-17].

Ultrafiltration

Ultrafiltration isolates exosomes based on their size using polytherersulfone nanomembrane concentrators. This method has a lower limit of sample volume, and is faster and easier to execute. However, because proteins in the sample can obstruct the filter, this method leads to decreased isolation efficiency[11,12,17]. Serum and urine have abundant levels of albumin and Tams-Horsfall proteins making this technique feasible only in combination with ultracentrifugation or other isolation techniques.

Size-exclusion chromatography following ultracentrifugation

Size-exclusion chromatography also uses exosome size as a principle for isolation. Heteroporous beads are constructed from a neutral, cross-linked polymeric support

placed in a column creating pores of varying sizes. As a solution passes through the column, molecules are separated by their size with the smaller molecules taking longer to pass through the pores. The major advantage of this method is that it excludes high abundant proteins. However, it is time consuming and labor-intensive[11,15-17].

Commercial kits

Several commercial kits for exosome isolation are available. The exact mechanism by which these reagents isolate exosomes is usually not disclosed by the companies. Typical steps in these protocols include incubation with a polymer, precipitation of the mixture, and centrifugation. Kits are simple, fast, and allow for processing of large volumes of sample. However, they tend to yield low quantities of exosomes and can be cost prohibitive[11,12,15-17].

QUALITY CONTROL AND QUANTIFICTION

Western blotting using known exosome marker proteins such as CD63, Alix or Tsg101 can be used to confirm the presence of exosomes in isolated samples. Commercially available Micro Bicinchoninic Acid protein assay kits can be used to quantify total exosome protein concentration[11,16,17].

Electron microscopy can be used to identify exosomes based on size and morphology. Transmission electron microscopy in combination with immune-gold staining outlines more detail and establishes the presence of specific exosome markers[11,12,16,17].

Nanoparticle tracking analysis (NTA) uses an ultramicroscope and laser illumination to calculate the mean velocity of particles suspended in a solution on the basis of Brownian motion. The velocity is then used to determine the particle size and concentration. NTA requires careful optimization and modification and setting adjustments, but is promising as a method for confirming the presence and determining the quantity of particles in the size range of exosomes after isolation by any method[12,15-17]. Western blotting and electron microscopy often accompanies this technique to provide sufficient evidence for the presence of exosomes.

BLADDER CANCER EXOSOMES

Exosomes are representative of the cells from which they originate. They contain miRNA, mRNA, lncRNA and protein. Exosomes play a role in several processes crucial for cancer progression, invasion and metastasis. Cancer cell-derived exosomes have altered content and composition which leads to altered biology. Several studies have demonstrated that exosomes from patients with bladder cancer contain discrete proteins and miRNA not found in the exosomes isolated from healthy volunteers[18,19]. The process of formation and secretion of exosomes as well as the mechanisms by which they influence tumorigenesis is not fully understood. However, there is significant evidence that cancer cell-derived exosomes influence the phenotype of recipient cells through several different mechanisms including angiogenesis, cytotoxicity, cell proliferation, migration, invasion and inhibition of apoptosis[10,13,14,19,20].

Beckham *et al*[10] previously demonstrated that bladder cancer exosomes are involved in tumor progression as exosomes isolated from bladder cancer cell lines or the urine of bladder cancer patients were shown to facilitate angiogenesis, migration and invasion. They demonstrated that exosomes isolated from bladder cancer cell lines contain hundreds of proteins such as epidermal growth factor like repeats and discoidin-1 like domains or EDIL-3. Knockdown of EDIL-3 in the high-grade bladder cancer cell line TCC-SUP resulted in exosomes that could not facilitate migration or angiogenesis, demonstrating an important role for exosome driven tumor progression in bladder cancer[10].

Yang *et al*[20] demonstrated that T24 bladder cancer cells (a high-grade bladder cancer cell line) treated with varying concentrations of exosomes have increased levels of bcl-2 and Cyclin-D1, reduced levels of Bax and caspase-3, and resulted in activation of Akt and ERK tumor cell apoptosis. Zhang *et al*[21] demonstrated that T24 bladder cancer cell exosomes can promote the anti-tumor effect of cytotoxic T lymphocytes *in vitro*.

A recent publication revealed that metastatic bladder cancer cells are dependent on RAB27 to secrete miR23b, miR224 and miR921 *via* exosomes. They also determined that silencing RAB27A or RAB27B halted the secretion of miR23b and miR921 and reduced cellular invasion[22].

BLADDER CANCER EXOSOMES AS BIOMARKERS

Several properties of exosomes make them desirable as biomarkers. As previously discussed, exosomes contain protein, miRNA, mRNA, lncRNA representative of the cell from which they originate. Exosomes are extremely stable, and RNA contained within exosomes is protected from degradation[23,24]. Additionally, they can be isolated from almost every body fluid, including urine. These characteristics give exosomes the potential to be used as a non-invasive biomarker for diagnosis, prognosis and recurrence of bladder cancer.

Bladder cancer tumors contain a high number of variable mutations, and tumors are frequently heterogeneous. Due to this, biomarker discovery will likely include a panel of molecules including bladder cancer specific proteins, miRNA, mRNA and lncRNA rather than a single marker. Welton *et al*[25] discovered several proteins in HT 1376 bladder cancer cell line exosomes using in-depth proteomic analysis. Jeppesen *et al*[26] completed proteomics on fractionated membranes compared to luminal contents of exosomes of metastatic and

non-metastatic bladder cancer cell lines and discovered several proteins important in epithelial-to mesenchymal transition.

Several groups have identified unique proteins and miRNA in the urine of bladder cancer patients which are not found in the urine of healthy volunteers. Chen *et al*[18] identified 22 discrete proteins in the exosomes of bladder cancer patients compared to healthy volunteers. In addition, they identified 7 proteins found differentially enriched patients. Smalley *et al*[27] found 9 exosomes proteins with differential enrichment in bladder cancer patients compared to normal healthy controls. Weber *et al*[19] identified 2 miRNA (miR-200a and miR449b) present in the urine of bladder cancer patients not present in the urine of healthy pregnant women. They also found other miRNA either enriched or reduced in bladder cancer samples compared to normal control samples. The authors speculate that the extracellular miRNA in the urine is transported in urinary exosomes. They also make the observation that quantification and normalization of miRNA is difficult due to the lack of housekeeping gene equivalents.

FUTURE DIRECTIONS

Although there are promising results for bladder cancer biomarker discovery with the use of exosome-derived proteins and miRNA, there are limitations. Microarray for miRNA has been unable to discover novel miRNA signatures for bladder cancer. High-depth RNA-sequencing may be necessary to reveal bladder cancer markers and multi-institutional cooperation may be necessary to overcome the cost barrier.

Further directions in biomarker discovery in bladder cancer may include the use of exosomal mRNA and/or lncRNA. To date, there are no published data on the function or biomarker potential of bladder cancer exosome mRNA or lncRNA. In an attempt to fill this gap, our group recently completed deep RNA-sequencing of 8 bladder cancer patient tumors, distal normal tissue and corresponding urinary exosomes, and the urinary exosomes of 7 normal healthy controls. We identified the enrichment of several mRNA and lncRNA in the bladder cancer patient exosomes compared to healthy normal controls. We used quantitative real-time reverse transcriptase polymerase chain reaction to confirm two lncRNAs enriched in the urine exosomes of bladder cancer patients compared to healthy controls. Further work in an appropriate population will be needed for validation of these transcripts for biomarker use[28].

In addition to their use as biomarkers in bladder cancer, urinary exosomes have the potential to aid in the diagnosis and monitoring of a variety of diseases. Exosome have been proposed as biomarkers for a wide-range of benign and malignant diseases. Detection of biomarker exosomes in the urine could provide a non-invasive option for the diagnosis of an assortment of conditions.

The functional roles of exosomes in cancer continue to be revealed over time. There is evidence that bladder cancer exosomes are involved in angiogenesis, cytotoxicity, cell proliferation, migration, invasion and inhibition of apoptosis. Additional functions of exosomes have been described in other cancers. For example, melanoma-derived exosomes have been shown to prime the metastatic niche[29]. There is also evidence in lung and breast cancer that exosomes may be instrumental in transferring chemotherapeutic drug resistance to chemosensitive cells[14]. There are no published data on the role of bladder cancer exosomes in priming of the metastatic niche or regulating the response to chemotherapeutics. This is another gap left to be filled in the understanding of bladder cancer exosomes.

Urinary exosomes may also be useful in predicting response of patient with bladder cancer to adjuvant therapy. Bladder cancer cells that are likely to respond to therapy may have unique (or differential expression of) proteins, mRNA, miRNA and lncRNA compared to cells that are not likely to respond to therapy. Exosomes are representative of their cells of origin in content and these differences can potentially be identified in urinary exosomes. If these differences can be identified, then urinary exosomes could potentially be used to help predict response to treatment.

There is growing interest in using exosomes in the treatment of cancer. One potential use for exosomes is as a vehicle for targeted therapy delivery in the form of cellular components of pharmaceuticals. A study by Alvarez-Erviti *et al*[30] used exosomes derived from the dendritic cells of bone marrow in mice to deliver siRNA in a targeted fashion to the brain. Another option for treatment, is in the therapeutic removal of exosomes from the circulatory system, but further work is needed to determine whether or not this method may be effective[31]. The observation that tumor-derived exosomes can activate a specific cytotoxic response has been used to initiate Phase Ⅰ and Phase Ⅱ clinical trials in the use of exosomes for the treatment of advanced stage non-small cell lung cancer[5]. There are currently no publications regarding the use of exosomes in the treatment of bladder cancer.

Exosomes show promise as a means for treatment of a variety of cancers. However, there are some limitations. Thus far, investigation into exosomes as therapeutics has been limited by technical and financial difficulties. In addition, there is concern for the safety in using exosomes for treatment. Exosomes for therapeutic use would likely be produced from cell lines grown in animal serum-containing medium. Although exosomes have been shown to be non-immunogenic, exosomes can conceivably carry theoretically harmful particles such as viruses, parasites, prions and transposons[32-34]. One potential advantage in the treatment of bladder cancer is the ability to deliver therapeutics intravesically, potentially avoiding risks associated with the treatment delivered systemically.

CONCLUSION

Exosomes are desirable as biomarker for disease because of their unique properties, including stability, protein and nucleic acid content representative of their donor cell, and presence in most body fluids. Several studies have demonstrated their potential use as biomarkers for bladder cancer. In these studies, both proteins and miRNA unique to bladder cancer patients were found in urinary exosomes. These studies use pooled data, highlighting the importance of developing a reliable panel of biomarkers for bladder cancer diagnosis and monitoring for recurrence of disease. And finally, there is some data to support the use of exosomes in cancer treatment.

REFERENCES

1 **Harding C**, Heuser J, Stahl P. Receptor-mediated endocytosis of transferrin and recycling of the transferrin receptor in rat reticulocytes. *J Cell Biol* 1983; **97**: 329-339 [PMID: 6309857 DOI: 10.1083/jcb.97.2.329]

2 **Pan BT**, Teng K, Wu C, Adam M, Johnstone RM. Electron microscopic evidence for externalization of the transferrin receptor in vesicular form in sheep reticulocytes. *J Cell Biol* 1985; **101**: 942-948 [PMID: 2993317 DOI: 10.1083/jcb.101.3.942]

3 **Raposo G**, Nijman HW, Stoorvogel W, Liejendekker R, Harding CV, Melief CJ, Geuze HJ. B lymphocytes secrete antigen-presenting vesicles. *J Exp Med* 1996; **183**: 1161-1172 [PMID: 8642258 DOI: 10.1084/jem.183.3.1161]

4 **Zitvogel L**, Regnault A, Lozier A, Wolfers J, Flament C, Tenza D, Ricciardi-Castagnoli P, Raposo G, Amigorena S. Eradication of established murine tumors using a novel cell-free vaccine: dendritic cell-derived exosomes. *Nat Med* 1998; **4**: 594-600 [PMID: 9585234]

5 **De Toro J**, Herschlik L, Waldner C, Mongini C. Emerging roles of exosomes in normal and pathological conditions: new insights for diagnosis and therapeutic applications. *Front Immunol* 2015; **6**: 203 [PMID: 25999947 DOI: 10.3389/fimmu.2015.00203]

6 **Vlassov AV**, Magdaleno S, Setterquist R, Conrad R. Exosomes: current knowledge of their composition, biological functions, and diagnostic and therapeutic potentials. *Biochim Biophys Acta* 2012; **1820**: 940-948 [PMID: 22503788 DOI: 10.1016/j.bbagen.2012.03.017]

7 **Lo Cicero A**, Stahl PD, Raposo G. Extracellular vesicles shuffling intercellular messages: for good or for bad. *Curr Opin Cell Biol* 2015; **35**: 69-77 [PMID: 26001269 DOI: 10.1016/j.ceb.2015.04.013]

8 **Hill AF**, Pegtel DM, Lambertz U, Leonardi T, O'Driscoll L, Pluchino S, Ter-Ovanesyan D, Nolte-'t Hoen EN. ISEV position paper: extracellular vesicle RNA analysis and bioinformatics. *J Extracell Vesicles* 2013; **2**; eCollection 2013 [PMID: 24376909 DOI: 10.3402/jev.v2i0.22859]

9 **Webber J**, Yeung V, Clayton A. Extracellular vesicles as modulators of the cancer microenvironment. *Semin Cell Dev Biol* 2015; **40**: 27-34 [PMID: 25662446 DOI: 10.1016/j.semcdb.2015.01.013]

10 **Beckham CJ**, Olsen J, Yin PN, Wu CH, Ting HJ, Hagen FK, Scosyrev E, Messing EM, Lee YF. Bladder cancer exosomes contain EDIL-3/Del1 and facilitate cancer progression. *J Urol* 2014; **192**: 583-592 [PMID: 24530986 DOI: 10.1016/j.juro.2014.02.035]

11 **Wang D**, Sun W. Urinary extracellular microvesicles: isolation methods and prospects for urinary proteome. *Proteomics* 2014; **14**: 1922-1932 [PMID: 24962155 DOI: 10.1002/pmic.201300371]

12 **Liga A**, Vliegenthart AD, Oosthuyzen W, Dear JW, Kersaudy-Kerhoas M. Exosome isolation: a microfluidic road-map. *Lab Chip* 2015; **15**: 2388-2394 [PMID: 25940789 DOI: 10.1039/c5lc00240k]

13 **Lin J**, Li J, Huang B, Liu J, Chen X, Chen XM, Xu YM, Huang LF, Wang XZ. Exosomes: novel biomarkers for clinical diagnosis. *ScientificWorldJournal* 2015; **2015**: 657086 [PMID: 25695100 DOI: 10.1155/2015/657086]

14 **Minciacchi VR**, Freeman MR, Di Vizio D. Extracellular vesicles in cancer: exosomes, microvesicles and the emerging role of large oncosomes. *Semin Cell Dev Biol* 2015; **40**: 41-51 [PMID: 25721812 DOI: 10.1016/j.semcdb.2015.02.010]

15 **Zeringer E**, Barta T, Li M, Vlassov AV. Strategies for isolation of exosomes. *Cold Spring Harb Protoc* 2015; **2015**: 319-323 [PMID: 25834266 DOI: 10.1101/pdb.top074476]

16 **Witwer KW**, Buzás EI, Bemis LT, Bora A, Lässer C, Lötvall J, Nolte-'t Hoen EN, Piper MG, Sivaraman S, Skog J, Théry C, Wauben MH, Hochberg F. Standardization of sample collection, isolation and analysis methods in extracellular vesicle research. *J Extracell Vesicles* 2013; **2**; eCollection 2013 [PMID: 24009894 DOI: 10.3402/jev.v2i0.20360]

17 **Taylor DD**, Shah S. Methods of isolating extracellular vesicles impact down-stream analyses of their cargoes. *Methods* 2015; **87**: 3-10 [PMID: 25766927 DOI: 10.1016/j.ymeth.2015.02.019]

18 **Chen CL**, Lai YF, Tang P, Chien KY, Yu JS, Tsai CH, Chen HW, Wu CC, Chung T, Hsu CW, Chen CD, Chang YS, Chang PL, Chen YT. Comparative and targeted proteomic analyses of urinary microparticles from bladder cancer and hernia patients. *J Proteome Res* 2012; **11**: 5611-5629 [PMID: 23082778 DOI: 10.1021/pr3008732]

19 **Weber JA**, Baxter DH, Zhang S, Huang DY, Huang KH, Lee MJ, Galas DJ, Wang K. The microRNA spectrum in 12 body fluids. *Clin Chem* 2010; **56**: 1733-1741 [PMID: 20847327 DOI: 10.1373/clinchem.2010.147405]

20 **Yang L**, Wu XH, Wang D, Luo CL, Chen LX. Bladder cancer cell-derived exosomes inhibit tumor cell apoptosis and induce cell proliferation in vitro. *Mol Med Rep* 2013; **8**: 1272-1278 [PMID: 23969721 DOI: 10.3892/mmr.2013.1634]

21 **Zhang JM**, Wu XH, Zhang Y, Xia YG, Luo CL. [Exosomes derived form bladder transitional cell carcinoma cells induce CTL cytotoxicity in vitro]. *Zhonghua Zhong Liu Za Zhi* 2009; **31**: 738-741 [PMID: 20021824]

22 **Ostenfeld MS**, Jeppesen DK, Laurberg JR, Boysen AT, Bramsen JB, Primdal-Bengtson B, Hendrix A, Lamy P, Dagnaes-Hansen F, Rasmussen MH, Bui KH, Fristrup N, Christensen EI, Nordentoft I, Morth JP, Jensen JB, Pedersen JS, Beck M, Theodorescu D, Borre M, Howard KA, Dyrskjøt L, Ørntoft TF. Cellular disposal of miR23b by RAB27-dependent exosome release is linked to acquisition of metastatic properties. *Cancer Res* 2014; **74**: 5758-5771 [PMID: 25261234 DOI: 10.1158/0008-5472.CAN-13-3512]

23 **Zhou H**, Yuen PS, Pisitkun T, Gonzales PA, Yasuda H, Dear JW, Gross P, Knepper MA, Star RA. Collection, storage, preservation, and normalization of human urinary exosomes for biomarker discovery. *Kidney Int* 2006; **69**: 1471-1476 [PMID: 16501490 DOI: 10.1038/sj.ki.5000273]

24 **Valadi H**, Ekström K, Bossios A, Sjöstrand M, Lee JJ, Lötvall JO. Exosome-mediated transfer of mRNAs and microRNAs is a novel mechanism of genetic exchange between cells. *Nat Cell Biol* 2007; **9**: 654-659 [PMID: 17486113 DOI: 10.1038/ncb1596]

25 **Welton JL**, Khanna S, Giles PJ, Brennan P, Brewis IA, Staffurth J, Mason MD, Clayton A. Proteomics analysis of bladder cancer exosomes. *Mol Cell Proteomics* 2010; **9**: 1324-1338 [PMID: 20224111 DOI: 10.1074/mcp.M000063-MCP201]

26 **Jeppesen DK**, Nawrocki A, Jensen SG, Thorsen K, Whitehead B, Howard KA, Dyrskjøt L, Ørntoft TF, Larsen MR, Ostenfeld MS. Quantitative proteomics of fractionated membrane and lumen exosome proteins from isogenic metastatic and nonmetastatic bladder cancer cells reveal differential expression of EMT factors. *Proteomics* 2014; **14**: 699-712 [PMID: 24376083 DOI: 10.1002/pmic.201300452]

27 **Smalley DM**, Sheman NE, Nelson K, Theodorescu D. Isolation and identification of potential urinary microparticle biomarkers of bladder cancer. *J Proteome Res* 2008; **7**: 2088-2096 [PMID: 18373357 DOI: 10.1021/pr700775x]

28 **Berrondo C**, Flax J, Kucherov V, Siebert A, Osinski T, Rosenberg A, Fucile C, Richheimer S, Beckham CJ. Expression of the Long Non-Coding RNA HOTAIR Correlates with Disease Progression in Bladder Cancer and Is Contained in Bladder Cancer Patient Urinary Exosomes. *PLoS One* 2016; **11**: e0147236 [PMID: 26800519 DOI: 10.1371/journal.pone.0147236. eCollection 2016]

29 **Peinado H**, Alečković M, Lavotshkin S, Matei I, Costa-Silva B, Moreno-Bueno G, Hergueta-Redondo M, Williams C, García-Santos G, Ghajar C, Nitadori-Hoshino A, Hoffman C, Badal K, Garcia BA, Callahan MK, Yuan J, Martins VR, Skog J, Kaplan RN, Brady MS, Wolchok JD, Chapman PB, Kang Y, Bromberg J, Lyden D. Melanoma exosomes educate bone marrow progenitor cells toward a pro-metastatic phenotype through MET. *Nat Med* 2012; **18**: 883-891 [PMID: 22635005 DOI: 10.1038/nm.2753]

30 **Alvarez-Erviti L**, Seow Y, Yin H, Betts C, Lakhal S, Wood MJ. Delivery of siRNA to the mouse brain by systemic injection of targeted exosomes. *Nat Biotechnol* 2011; **29**: 341-345 [PMID: 21423189 DOI: 10.1038/nbt.1807]

31 **Qin J**, Xu Q. Functions and application of exosomes. *Acta Pol Pharm* 2014; **71**: 537-543 [PMID: 25272880]

32 **György B**, Hung ME, Breakefield XO, Leonard JN. Therapeutic applications of extracellular vesicles: clinical promise and open questions. *Annu Rev Pharmacol Toxicol* 2015; **55**: 439-464 [PMID: 25292428 DOI: 10.1146/annurev-pharmtox-010814-124630]

33 **Ritchie AJ**, Crawford DM, Ferguson DJ, Burthem J, Roberts DJ. Normal prion protein is expressed on exosomes isolated from human plasma. *Br J Haematol* 2013; **163**: 678-680 [PMID: 24117007 DOI: 10.1111/bjh.12543]

34 **Fevrier B**, Vilette D, Archer F, Loew D, Faigle W, Vidal M, Laude H, Raposo G. Cells release prions in association with exosomes. *Proc Natl Acad Sci USA* 2004; **101**: 9683-9688 [PMID: 15210972 DOI: 10.1073/pnas.0308413101]

P- Reviewer: Carey JS, Madbouly K
S- Editor: Kong JX **L- Editor**: A **E- Editor**: Li D

World Journal of Clinical Urology

Submit a Manuscript: http://www.wjgnet.com/esps/
Help Desk: http://www.wjgnet.com/esps/helpdesk.aspx
DOI: 10.5410/wjcu.v5.i1.24

World J Clin Urol 2016 March 24; 5(1): 24-28
ISSN 2219-2816 (online)
© 2016 Baishideng Publishing Group Inc. All rights reserved.

MINIREVIEWS

Cost effectiveness of robot-assisted urologic oncological surgery in the United States

Catherine J Chen, Mitchell R Humphreys

Catherine J Chen, Mitchell R Humphreys, Department of Urology, Mayo Clinic Arizona, Phoenix, AZ 85054, United States

Author contributions: All authors equally contributed to this paper with conception and design of the study, literature review and analysis, drafting and critical revision and editing, and final approval of the final version.

Conflict-of-interest statement: There is no conflict of interest associated with the senior author or coauthors in writing this manuscript or the content of this manuscript.

Open-Access: This article is an open-access article which was selected by an in-house editor and fully peer-reviewed by external reviewers. It is distributed in accordance with the Creative Commons Attribution Non Commercial (CC BY-NC 4.0) license, which permits others to distribute, remix, adapt, build upon this work non-commercially, and license their derivative works on different terms, provided the original work is properly cited and the use is non-commercial. See: http://creativecommons.org/licenses/by-nc/4.0/

Correspondence to: Mitchell R Humphreys, MD, Department of Urology, Mayo Clinic Arizona, 5777 E. Mayo Blvd., Phoenix, AZ 85054, United States. humphreys.mitchell@mayo.edu
Telephone: +1-480-3422793
Fax: +1-480-3422799

Received: August 28, 2015
Peer-review started: September 5, 2015
First decision: November 24, 2015
Revised: December 24, 2015
Accepted: January 5, 2016
Article in press: January 7, 2016
Published online: March 24, 2016

Abstract

Urology has been on the forefront of technological advances in minimally invasive surgery, from laparoscopy to robot-assisted surgeries. As with all new technological advances in medicine, the results of new advances are compared to previously established gold standards. When it comes to robot-assisted urology, morbidity, oncological outcomes, and cost between the same surgeries performed in an open fashion *vs* with robot-assistance should be assessed. Because healthcare spending is increasingly under more scrutiny, there is debate on the cost effectiveness of robot-assisted surgeries given the high acquisition and maintenance cost of robotic systems. This articles aims to critically evaluate the cost effectiveness of robot-assisted surgeries for prostatectomies, cystectomies, and partial nephrectomies in the United States.

Key words: Cost-effectiveness; Robot; Prostatectomy; Cystectomy; Partial nephrectomy

© The Author(s) 2016. Published by Baishideng Publishing Group Inc. All rights reserved.

Core tip: Robot-assisted urologic oncologic surgeries offers significant amounts of benefit, with shorter length of stay, less blood loss and improved peri-operative quality of life. The high fixed cost of robot acquisition and maintenance is offset by increasing the number of robot cases per year, narrowing the gap in cost between robot-assisted surgeries and open surgeries. Cost effective analysis and cost benefit analysis of robot-assisted surgeries are difficult to assess given the difficulties with evaluating indirect costs. However, the measurable differences favor robot-assisted surgeries.

Chen CJ, Humphreys MR. Cost effectiveness of robot-assisted urologic oncological surgery in the United States. *World J Clin Urol* 2016; 5(1): 24-28 Available from: URL: http://www.wjgnet.com/2219-2816/full/v5/i1/24.htm DOI: http://dx.doi.org/10.5410/wjcu.v5.i1.24

INTRODUCTION

Healthcare spending is an important topic as current

practices are under heavy scrutiny and affected by changes in healthcare policy. The cost of medical care has come to the forefront in both the medical and political community. This places pressure on the scientific community to develop technological advances that will not only improve health outcomes but that are also more cost effective. Robot-assisted surgery is a recent technology targeted in the debate regarding cost effectiveness and added value of healthcare.

Since the approval of the Da Vinci Surgical System (Intuitive Surgical, Inc., Sunnyvale, CA) by the Food and Drug Administration (FDA) in 2000, robotic assisted surgery has been rapidly adopted, with more than 1400 systems installed in the United States by 2009, growing by 85% from 2007 to 2009[1]. As of March 2015, Intuitive has reported that 3317 base units have been installed worldwide, with 2254 units in the United States, 556 in Europe, 194 in Japan and 313 in the rest of the world[2].

The urologic community has been quick to adopt robotic assisted laparoscopic surgery especially in urologic oncology, first through embracing robotic assisted prostatectomy and more recently increasing utilization to partial nephrectomies and cystectomies. Currently, the majority of radical prostatectomies are performed robotically in the United States, with estimate in 2009 being 69% performed robotically[3].

Robotic assisted laparoscopic surgery offers several advantages. From the surgeon's perspective, robotic assisted surgery offers improved visual field, including 3-dimentional view, improved freedom of movement through "wristed" instruments, elimination of surgeon tremor and ergonomic benefits[4]. For the patient, benefits include improved cosmetics with smaller incision sites, decrease loss of blood, decreased post-procedure pain, shorter length of stay and faster recovery[4]. However, some reported disadvantages include longer operative time, lack of tactile sensation, and instrument collision resulting in injury to surrounding organs.

Currently in the United States, most patients pay for their healthcare through insurance, and ultimately only pay a small portion directly leading to poor understanding of medical costs. Many studies have demonstrated that robotic surgery can be more expensive due to the high acquisition cost[5-7].

ECONOMICS OF MEDICAL CARE

There are three types of models to assess the economics of medical care (Table 1): Cost-identification analysis, cost effective analysis, and cost-benefit analysis[8]. Cost-identification analysis simply identifies the cost without addressing outcomes. Cost effectiveness analysis is a method used to assess cost and outcomes[9]. It is often presented as an incremental cost effectiveness ratio, where the numerator is the difference of cost between two different interventions and the denominator is the difference between the health outcomes[10]. Health outcomes can be measured in several different ways (*i.e.,* quality of life, disease free survival, life years gained). Cost-benefit analysis evaluates whether the benefit is worth the cost done by measuring cost and outcomes in the same unit[8].

Direct costs are divided into two categories (Figure 1), fixed cost which would not change based off of the number of procedures and variable cost which does change based on the number of procedures done[8]. Indirect costs are measured by cost incurred by loss of livelihood or life due to morbidity or mortality such as lost wages or disability[8]. Given the difficulties in evaluating indirect costs, there has not been any study to evaluate this. Most published literature focus on the direct cost of robotic surgery.

Some of the draw backs to economic analysis are due to bias and uncertainties. It is difficult to obtain precise values for many of the components for necessary cost analysis. Insurance reimbursement also differs compared to actual cost. Currently, Medicare uses cost effective analysis for preventative services but not for treatment.

The direct costs in robotic surgery tend to be higher than open procedures predominantly due to the high acquisition cost of a robotic surgical system as well as cost of disposable instruments and terms of maintenance agreements. Currently, Intuitive Surgical is the only company on the market producing a FDA approved robotic surgical system, thus, holding a monopoly on the market. It is estimated that robotic acquisition is typically around 1.5 million dollars with an annual $150000 service contract. Per the American Hospital Association's 2008 asset life assessment guidelines, most studies amortize this cost over 7 years, dividing the total cost over the total number of robotic cases to determine the cost per case[11-14]. Thus, the cost of robotic utilization per case is lower at a large volume practice compared to a low volume practice. Other direct cost consists of cost for robotic instruments. With programmed obsolesce, robotic instruments are limited to 10 uses per instrument compared to laparoscopic and open instruments, which tend to have unlimited uses.

COST COMPARISON: PROSTATECTOMY

Out of the limited literature published on the cost of robotic assisted urologic surgery, the literature is most robust for radical prostatectomy. Bolenz *et al*[5] published their data on cost from the hospital billing department. They obtained disposable laparoscopic cost, including cost of trocars, specimen entrapment sac, suction irrigator, clip appliers, and use of adjuvant hemostatic agents. Cost specific for the robot included robotic instruments per use. They evaluated operative time to determine OR cost, including cost for anesthesia and OR overhead. The rate for room and board was included, based on length of stay. They concluded that the median direct cost for robotic assisted radical prostatectomy (RARP) was $6752, laparoscopic prostatectomy was $5687 and $4437 for open radical retropubic prostatectomy (RRP)[5]. However, they did not include acquisition cost and maintenance cost in these values, which would only raise the cost of

Table 1 Three types of models to assess the economics of medical care

Economic models of medical care	Definition
Cost identification analysis	Identifies cost without evaluating outcomes
Cost effectiveness analysis	Assess cost and outcomes; represented as an incremental cost effectiveness ratio (difference of cost between two different interventions/ the difference between the health outcomes)
Cost-benefit analysis	Evaluates whether the benefit is worth the cost done by measuring cost and outcomes in the same unit

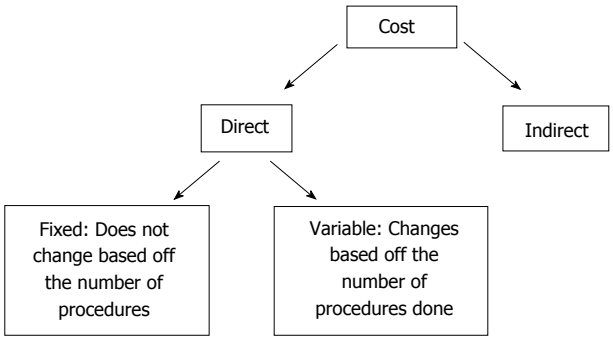

Figure 1 Direct costs two categories.

RARP.

Bolenz *et al*[15] subsequently published a systematic review on the cost of prostatectomy using different methods, including 11 studies that reported the direct cost of the procedure in their final analysis. Out of the 11 studies included, 6 studies compared open RRP with minimally invasive prostatectomy. For minimal invasive prostatectomy, which included both laparoscopic and robotic prostatectomy, the cost ranged from $5058-$11806. For open RRP, the cost ranged from $4075-$6296. The direct cost in minimally invasive prostatectomy was higher than open in 5 out of the 6 studies.

Hyams *et al*[16] specifically evaluated the impact of surgical volume on the cost of radical prostatectomy. They used a statewide database to identify all open and robotic prostatectomies between 2008-2011 in Maryland. They found that in both the open RRP and the RARP groups, the larger the surgical volume, the lower the cost per case. However, they still note that open RRP had lower direct costs even at high volume. This study did not take into account acquisition and maintenance costs; thus, possibly increasing the difference between the cost for RARP and open RRP more.

In a retrospective study of 882 patients (294 in the robot-assisted group and 588 in the open group), Krambeck *et al*[17] demonstrated that there was significant difference in median operation time between the RARP and open RRP groups; however, by the last 100 RARP cases, there was no difference in median operation time. They included docking time of the robot in their analysis. Through their study, they demonstrated that with increased experience, the cost of OR time could be equivalent between the two groups.

There are no studies that have directly analyzed and calculated a value for the indirect cost of robotic assisted prostatectomies. However, there have been studies that indirectly address this through evaluating cancer control and side effects.

In a retrospective study of 400 patients, the overall incidence of positive surgical margin was 15% in the RARP arm compared to 35% in the open RRP arm ($P < 0.001$)[18]. When sub-stratified based on pathological stage, the positive surgical margin was lower in the RARP groups for both pT2 and pT3 disease[18].

Tewari *et al*[19] demonstrated in a prospective comparison between open RRP and RARP that patients in the RARP group had faster return of continence (44 d *vs* 160 d) and erections (180 d *vs* 440 d) compared to those in the open RRP group. They also report that positive margins were more frequent in the open RRP group compared to the RARP group (23% *vs* 9%).

There has only been one study published evaluating and comparing quality of life in men undergoing RARP *vs* open RRP in the peri-operative period. In a prospective study, Miller *et al*[20] had patients complete the SF-12 version 2 Physical and Mental Health Survey Acute Form preoperatively and weekly postoperatively for 6 wk. This questionnaire assesses physical functioning, role limitations due to physical health, pain, general health perceptions, vitality, social functioning, role limitations due to emotional problems, and mental health. This was broken down into a mental component score and a physical component score, which higher scores indicating better functioning. The physical component score was consistently higher in the RARP group starting from week 1 to week 6. There was no statistically difference in the mental component score except on the preoperative survey, where the RARP group scored higher than the open RRP group. Studies that have looked at long term quality of life notice no difference between different methods of RARP and open RRP[21,22].

COST COMPARISON: CYSTECTOMY

The direct cost comparison between robot-assisted radical cystectomy (RARC) and open radical cystectomy (ORC) is less clear compared to that analysis for prostatectomies. There are significantly fewer studies published for cystectomies and as a whole, the urologic community is at an earlier stage in the learning process for cystectomies compared to prostatectomies.

Yu *et al*[23] reported that RARC costs is greater than ORC cost by $3797; however, they did not elaborate on how these numbers were obtained. They report in their retrospective study using the United States Nationwide Inpatient sample no difference in length of hospital stay or transfusion rates between the RARC and ORC groups. The RARC group had lower parenteral nutrition use and

lower inpatient complications, but they were not able to classify or grade these complications.

In a retrospective study on 20 RARC and 20 ORC at a single institute, Smith *et al*[7] demonstrated that the cost of the RARC group was overall higher than the ORC by $1640. They included fixed cost, variable cost, as well as hospital cost. Fixed cost included base cost and disposable equipment cost for ORC. Robotic fixed cost included amortization of the robot as well as maintenance fees. Variable operating room cost depended on the duration of the case, which was higher in the RARC group. Hospital cost was actually higher in the ORC group because of increased transfusion rates and length of stay.

On the other hand, Martin *et al*[14] demonstrate when evaluating actual patient costs there is a 38% cost advantage favoring RARC when combining both operating room and hospital costs. The absolute cost was not given. The costs relating to the operating room was more in the RARC group because of longer procedure time and fixed cost of robot acquisition and maintenance. However, there was a significant difference in the length of stay (LOS), with the mean LOS of 5 d in the RARC group and 10 d in the ORC group. This was a relatively small study with 19 patients in the RARC group and 14 patients in the ORC group.

Lee *et al*[11] also demonstrated similar findings. In a retrospective study on 186 patients, they subdivided the patients based of the type of urinary diversion used. The cost of RARC with orthotopic neobladder was less than the cost ORC with orthotopic neobladder. They conclude that the difference in LOS is able to offset the higher cost of robotic surgery. Furthermore, the overall complication rate within the 90-d global surgery period was lower in the RARC group (49.4%) than the ORC group (61.2%).

The main limitation of cost evaluation of RARC *vs* ORC is the lack of published data on effectiveness as well as comparison of side effects. There is limited data on oncologic outcome, with the longest follow-up of 3.5 years in RARC[24].

COST COMPARISON: PARTIAL NEPHRECTOMY

There are limited studies evaluating the cost of robotic-assisted partial nephrectomy (RAPN), open partial nephrectomy (OPN) and laparoscopic partial nephrectomy (LPN). The studies that have been published are small, with the largest only evaluating 89 patients[12].

Hyams *et al*[25] evaluated 20 consecutive RAPN and OPN from 2009-2010. They calculated that RAPN was $1066.09 more than LPN. This was attributed to the high capital cost for robotic surgery specific to their center. Capital cost was estimated for the purchase and amortization of 2 robotic systems as well as maintenance cost divided by the total number of robotic cases between 2001 and 2009. They concluded that when the fixed robotic cost was calculated based off 1 robotic system with "ideal" utilization of 300 cases per year, the cost difference is only $333.85 per case.

In another study that compared RALN to OLN, Alemozaffar *et al*[13] also conclude that RALN can be cost equivalent to OPN by minimizing OR time and LOS. However, RALN was most expensive when fixed costs were factored.

CONCLUSION

Overall, robotic assisted surgery has offered significant amounts of benefit to urologic surgery, with shorter LOS, less blood loss, and improved peri-operative quality of life. Given the high fixed cost of robotic acquisition and maintenance, robotic assisted surgery is more often than not, more expensive than open procedure when evaluating direct costs. However, the gap in cost between robotic assisted and open surgery can be narrowed in high volume centers where the fixed cost can be divided between a larger number of cases. Also, if the LOS is substantially different between robotic and open groups, such as in cystectomies, the cost of robotic surgery can actually be even lower than an open procedure. Due to the difficulty of identifying indirect costs and health outcomes, it is very difficult to assess cost-benefit of robotic assisted surgery. Furthermore, these cost evaluations do not factor in patient preference and requests for procedures to be done robotically. Ultimately, more data is needed in evaluating and comparing long term surgical outcomes between robotic assisted and open surgery.

REFERENCES

1 **Barbash GI**, Glied SA. New technology and health care costs--the case of robot-assisted surgery. *N Engl J Med* 2010; **363**: 701-704 [PMID: 20818872 DOI: 10.1056/NEJMp1006602]

2 Intuitive surgical/investor FAQ. Available from: URL: http://phx.corporate-ir.net/phoenix.zhtml?c=122359&p=irol-faq

3 **Lowrance WT**, Eastham JA, Savage C, Maschino AC, Laudone VP, Dechet CB, Stephenson RA, Scardino PT, Sandhu JS. Contemporary open and robotic radical prostatectomy practice patterns among urologists in the United States. *J Urol* 2012; **187**: 2087-2092 [PMID: 22498227 DOI: 10.1016/j.juro.2012.01.061]

4 **Yu HY**, Hevelone ND, Lipsitz SR, Kowalczyk KJ, Nguyen PL, Choueiri TK, Kibel AS, Hu JC. Comparative analysis of outcomes and costs following open radical cystectomy versus robot-assisted laparoscopic radical cystectomy: results from the US Nationwide Inpatient Sample. *Eur Urol* 2012; **61**: 1239-1244 [PMID: 22482778 DOI: 10.1016/j.eururo.2012.03.032]

5 **Bolenz C**, Gupta A, Hotze T, Ho R, Cadeddu JA, Roehrborn CG, Lotan Y. Cost comparison of robotic, laparoscopic, and open radical prostatectomy for prostate cancer. *Eur Urol* 2010; **57**: 453-458 [PMID: 19931979 DOI: 10.1016/j.eururo.2009.11.008]

6 **Mir SA**, Cadeddu JA, Sleeper JP, Lotan Y. Cost comparison of robotic, laparoscopic, and open partial nephrectomy. *J Endourol* 2011; **25**: 447-453 [PMID: 21247335 DOI: 10.1089/end.2010.0510]

7 **Smith A**, Kurpad R, Lal A, Nielsen M, Wallen EM, Pruthi RS. Cost analysis of robotic versus open radical cystectomy for bladder cancer. *J Urol* 2010; **183**: 505-509 [PMID: 20006882 DOI: 10.1016/j.juro.2009.09.081]

8 **Eisenberg JM**. Clinical economics. A guide to the economic analysis of clinical practices. *JAMA* 1989; **262**: 2879-2886 [PMID: 2509745]

9 **Russell LB**, Gold MR, Siegel JE, Daniels N, Weinstein MC. The role of cost-effectiveness analysis in health and medicine. Panel

on Cost-Effectiveness in Health and Medicine. *JAMA* 1996; **276**: 1172-1177 [PMID: 8827972]

10 **Detsky AS**, Naglie IG. A clinician's guide to cost-effectiveness analysis. *Ann Intern Med* 1990; **113**: 147-154 [PMID: 2113784]

11 **Lee R**, Ng CK, Shariat SF, Borkina A, Guimento R, Brumit KF, Scherr DS. The economics of robotic cystectomy: cost comparison of open versus robotic cystectomy. *BJU Int* 2011; **108**: 1886-1892 [PMID: 21501370 DOI: 10.1111/j.1464-410X.2011.10114.x]

12 **Ferguson JE**, Goyal RK, Raynor MC, Nielsen ME, Pruthi RS, Brown PM, Wallen EM. Cost analysis of robot-assisted laparoscopic versus hand-assisted laparoscopic partial nephrectomy. *J Endourol* 2012; **26**: 1030-1037 [PMID: 22384936 DOI: 10.1089/end.2011.0568]

13 **Alemozaffar M**, Chang SL, Kacker R, Sun M, DeWolf WC, Wagner AA. Comparing costs of robotic, laparoscopic, and open partial nephrectomy. *J Endourol* 2013; **27**: 560-565 [PMID: 23130756 DOI: 10.1089/end.2012.0462]

14 **Martin AD**, Nunez RN, Castle EP. Robot-assisted radical cystectomy versus open radical cystectomy: a complete cost analysis. *Urology* 2011; **77**: 621-625 [PMID: 21122900 DOI: 10.1016/j.urology.2010.07.502]

15 **Bolenz C**, Freedland SJ, Hollenbeck BK, Lotan Y, Lowrance WT, Nelson JB, Hu JC. Costs of radical prostatectomy for prostate cancer: a systematic review. *Eur Urol* 2014; **65**: 316-324 [PMID: 22981673 DOI: 10.1016/j.eururo.2012.08.059]

16 **Hyams ES**, Mullins JK, Pierorazio PM, Partin AW, Allaf ME, Matlaga BR. Impact of robotic technique and surgical volume on the cost of radical prostatectomy. *J Endourol* 2013; **27**: 298-303 [PMID: 22967039 DOI: 10.1089/end.2012.0147]

17 **Krambeck AE**, DiMarco DS, Rangel LJ, Bergstralh EJ, Myers RP, Blute ML, Gettman MT. Radical prostatectomy for prostatic adenocarcinoma: a matched comparison of open retropubic and robot-assisted techniques. *BJU Int* 2009; **103**: 448-453 [PMID: 18778350 DOI: 10.1111/j.1464-410X.2008.08012.x]

18 **Smith JA**, Chan RC, Chang SS, Herrell SD, Clark PE, Baumgartner R, Cookson MS. A comparison of the incidence and location of positive surgical margins in robotic assisted laparoscopic radical prostatectomy and open retropubic radical prostatectomy. *J Urol* 2007; **178**: 2385-2389; discussion 2389-2390 [PMID: 17936849 DOI: 10.1016/j.juro.2007.08.008]

19 **Tewari A**, Srivasatava A, Menon M. A prospective comparison of radical retropubic and robot-assisted prostatectomy: experience in one institution. *BJU Int* 2003; **92**: 205-210 [PMID: 12887468]

20 **Miller J**, Smith A, Kouba E, Wallen E, Pruthi RS. Prospective evaluation of short-term impact and recovery of health related quality of life in men undergoing robotic assisted laparoscopic radical prostatectomy versus open radical prostatectomy. *J Urol* 2007; **178**: 854-858; discussion 859 [PMID: 17631338 DOI: 10.1016/j.juro.2007.05.051]

21 **Ball AJ**, Gambill B, Fabrizio MD, Davis JW, Given RW, Lynch DF, Shaves M, Schellhammer PF. Prospective longitudinal comparative study of early health-related quality-of-life outcomes in patients undergoing surgical treatment for localized prostate cancer: a short-term evaluation of five approaches from a single institution. *J Endourol* 2006; **20**: 723-731 [PMID: 17094746 DOI: 10.1089/end.2006.20.723]

22 **Namiki S**, Egawa S, Terachi T, Matsubara A, Igawa M, Terai A, Tochigi T, Ioritani N, Saito S, Arai Y. Changes in quality of life in first year after radical prostatectomy by retropubic, laparoscopic, and perineal approach: Multi-institutional longitudinal study in Japan. *Urology* 2006; **67**: 321-327 [PMID: 16442596 DOI: 10.1016/j.urology.2005.09.004]

23 **Yu HY**, Hevelone ND, Lipsitz SR, Kowalczyk KJ, Hu JC. Use, costs and comparative effectiveness of robotic assisted, laparoscopic and open urological surgery. *J Urol* 2012; **187**: 1392-1398 [PMID: 22341274 DOI: 10.1016/j.juro.2011.11.089]

24 **Mmeje CO**, Nunez-Nateras R, Nielsen ME, Pruthi RS, Smith A, Wallen EM, Humphreys MR, Woods ME, Castle EP. Oncologic outcomes for lymph node-positive urothelial carcinoma patients treated with robot assisted radical cystectomy: with mean follow-up of 3.5 years. *Urol Oncol* 2013; **31**: 1621-1627 [PMID: 22534088 DOI: 10.1016/j.urolonc.2012.03.001]

25 **Hyams E**, Pierorazio P, Mullins JK, Ward M, Allaf M. A comparative cost analysis of robot-assisted versus traditional laparoscopic partial nephrectomy. *J Endourol* 2012; **26**: 843-847 [PMID: 22204599 DOI: 10.1089/end.2011.0522]

P- Reviewer: Donkov I, Ilie CP, Pignot G
S- Editor: Qi Y **L- Editor**: A **E- Editor**: Li D

World Journal of Clinical Urology

Submit a Manuscript: http://www.wjgnet.com/esps/
Help Desk: http://www.wjgnet.com/esps/helpdesk.aspx
DOI: 10.5410/wjcu.v5.i1.29

World J Clin Urol 2016 March 24; 5(1): 29-36
ISSN 2219-2816 (online)
© 2016 Baishideng Publishing Group Inc. All rights reserved.

MINIREVIEWS

Diagnosis of voiding dysfunction by pressure-flow study in women

Juan Pablo Valdevenito, Annerleim Walton-Diaz

Juan Pablo Valdevenito, Annerleim Walton-Diaz, Urodynamics Unit, Department of Urology, Hospital Clinico Universidad de Chile, Santiago 8380456, Chile

Author contributions: Valdevenito JP and Walton-Diaz A contributed equally to this manuscript.

Conflict-of-interest statement: Authors have no conflict of interest to declare.

Open-Access: This article is an open-access article which was selected by an in-house editor and fully peer-reviewed by external reviewers. It is distributed in accordance with the Creative Commons Attribution Non Commercial (CC BY-NC 4.0) license, which permits others to distribute, remix, adapt, build upon this work non-commercially, and license their derivative works on different terms, provided the original work is properly cited and the use is non-commercial. See: http://creativecommons.org/licenses/by-nc/4.0/

Correspondence to: Juan Pablo Valdevenito, MD, Associate Professor of Urology, Urodynamics Unit, Department of Urology, Hospital Clinico Universidad de Chile, Santos Dumont 999, Santiago 8380456, Chile. jpvaldevenito@yahoo.com
Telephone: +56-02-29788503
Fax: +56-02 -2070768

Received: May 28, 2015
Peer-review started: June 1, 2015
First decision: August 25, 2015
Revised: November 7, 2015
Accepted: December 1, 2015
Article in press: December 2, 2015
Published online: March 24, 2016

Abstract

Pressure-flow study (PFS) of micturition is the best method to quantitatively analyse voiding function. It allows us to distinguish voiding lower urinary tract symptoms and low urine flow rate caused by bladder outlet obstruction (BOO) from those caused by detrusor underactivity (DU). Voiding dynamics are significantly different in men and women and the established criteria for urodynamic diagnosis in men do not apply to women. Basic principles of voiding mechanics and voiding patterns in asymptomatic women are analyzed. Although attempts have been made to establish a consensus for diagnosis of BOO in women with pressure-flow cutoff, video-urodynamics criteria and nomograms, currently there is no consensus. There is no standard urodynamic test to diagnose and quantify DU in women for which further investigations are needed. Modified projected isovolumetric pressure (to assess detrusor contraction strength) and pressure-flow cutoff criteria have been used. The diagnosis of voiding dysfunction in women is challenging, requiring PFS with very good quality control and often involves integrating clinical and radiographic data to make the final assessment.

Key words: Bladder outlet obstruction; Pressure-flow studies; Urodynamics; Women; Detrusor underactivity

© The Author(s) 2016. Published by Baishideng Publishing Group Inc. All rights reserved.

Core tip: Pressure-flow study of micturition is the best method to quantitatively analyze voiding function. Voiding dynamics differ significantly between men and women and the established criteria for urodynamic diagnosis in men do not apply to women. Although attempts have been made to establish a consensus for diagnosis of bladder outlet obstruction in women with pressure-flow cutoff, video-urodynamics criteria and nomograms, currently there is no consensus. There is no standard urodynamic test to diagnose detrusor underactivity in women for which further investigations are needed. The diagnosis of voiding dysfunction in women is challenging and often involves consideration of clinical and radiographic data to make the final assessment.

by pressure-flow study in women. *World J Clin Urol* 2016; 5(1): 29-36 Available from: URL: http://www.wjgnet.com/2219-2816/full/v5/i1/29.htm DOI: http://dx.doi.org/10.5410/wjcu.v5.i1.29

INTRODUCTION

At present, the best method for quantitative analysis of voiding function is the pressure-flow study (PFS) of micturition, with concomitant recording of intravesical, abdominal, detrusor pressures ($p_{det} = p_{ves} - p_{abd}$) and flow rate[1]. It is defined by the International Continence Society (ICS) as "the method by which the relationship between pressure in the bladder and urine flow is measured during bladder emptying"[2].

PFS is able to evaluate normal voiding as well as detrusor underactivity (DU) and bladder outlet obstruction (BOO). BOO is the term employed for defining obstruction during voiding and corresponds to increased detrusor pressure and reduced urine flow rate. DU is defined as a detrusor contraction "of reduced strength and/or duration, resulting in prolonged bladder emptying and/or failure to achieve complete bladder emptying within a normal time span"[2]. An acontractile detrusor is defined as the one "that cannot be observed to contract during a urodynamic studies resulting in prolonged bladder emptying and/or failure to achieve complete bladder emptying within a normal time span"[3]. Thus, acontractile detrusor may be considered as a more severe form of DU.

PFS is a well established diagnostic tool for evaluating voiding dysfunction in men. This is the result of extensive studies in patients with benign prostatic enlargement which has led to the development of normograms, such as de nomogram described by Abrams *et al*[4], the Passive Urethral Resistance Relation[5,6] and the ICS nomogram[1]. However, due to anatomic differences between men and women their voiding dynamics differ significantly. Women usually void at lower detrusor pressures than those observed in men. Therefore the established criteria for urodynamic diagnosis used in men are not well suited for women. Moreover, up to date there is no equivalent prevalent condition such as benign prostatic enlargement causing BOO in women, making the diagnosis more challenging.

In this article we will discuss the basic principles of voiding mechanics, the voiding patterns in asymptomatic women, the urodynamic criteria currently used to assess BOO and DU in women and some quality control issues of the pressure-flow studies in this gender.

BASIC PRINCIPLES OF VOIDING MECHANICS

The detrusor, as it occurs with other muscles, follows the Hill equation. This equation describes the relation between the muscle's force of contraction and it's shortening velocity[7]. For example, for a given muscle length and it's activation degree, a shortening speed of zero will produce that tension attains its isometric value. As the muscle's shortening speed increases, the tension falls and reaches zero at a maximum shortening velocity characteristic of that muscle (Figure 1)[7,8]. In the case of the bladder, the Hill equation becomes the bladder output relation (BOR). It relates the pressure of the detrusor to urinary flow rate (Figure 2)[8]. For a given detrusor contraction strength, given that there is no obstruction, the pressure needed to drive urine through the urethra is low meanwhile the flow rate is high. Contrarily, if outlet obstruction is present, the pressure required is high and flow rate low. If obstruction develops progressively, voiding conditions alter gradually from low pressure/high flow towards high pressure/low flow[9]. Moreover, the BOR curve is not fixed. When the detrusor decompensate and develops hipo-contractility, the curve shifts to lower pressures and flow rates and may cause urinary retention[9-11].

In other words, voiding arises from the balance between an actively contracting detrusor as source of mechanical energy and the relaxed bladder outlet as a passive conduit with special hydrodynamic characteristics. The detrusor has a specific pattern of energy release in which the outlet determines how the energy provided is converted to attain voiding. Voiding power is proportional to detrusor pressure and to urine flow rate. The detrusor does not produce a particular pressure or flow during voiding. Instead, this muscle is able to provide mechanical power and it is the bladder outlet that dictates the way this power is splited into pressure and flow rate, following an inverse relationship (BOR). The maximum detrusor power is proportional to the filling volume of the bladder. This higher detrusor power explains why, for the same voiding pressure, the peak flow rate is higher at larger voiding volumes (therefore the outlet resistance is not lower at larger volumes). Moreover, the collapsed urethra differs from a rigid pipe in that an increase in intraluminal pressure is required to open the lumen before flow can occur. This urethral opening pressure must also be supplied by detrusor contraction and cannot be converted into flow. Consequently, flow rate will be lower than it could be in a rigid conduit of the same size. A special feature of flow in collapsible and distensible tubes is that the pressure-flow relation can be controlled by a small segment acting as a "flow controlling zone". Under physiologic conditions, this zone is at the level of the pelvic floor. Under pathological outflow conditions, the obstruction itself takes over the role of the flow controlling zone[5].

VOIDING PATTERNS IN ASYMPTOMATIC WOMEN

Most of our knowledge of voiding function has been extrapolated from studies of women with lower urinary tract dysfunction. However, women with and without lower urinary tract symptoms have different voiding patterns.

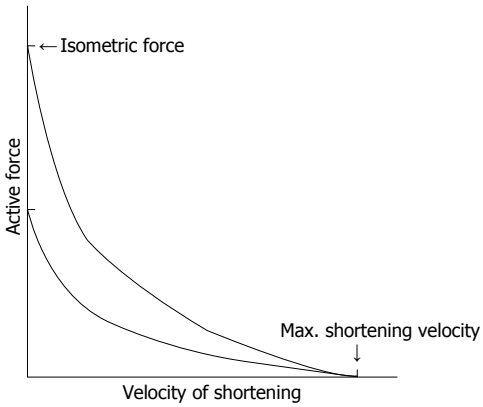

Figure 1 Hill curves relating active force to velocity of shortening at a given muscle length. Curves are shown for two different muscle lengths, corresponding to the same bladder when full (upper curve) and when nearly empty (lower curve: Volume approximately 12.5% of capacity). (From Griffiths[8]. Assessment of detrusor contraction strength or contractility. Neurourol Urodyn 1991; 10: 1; with permission).

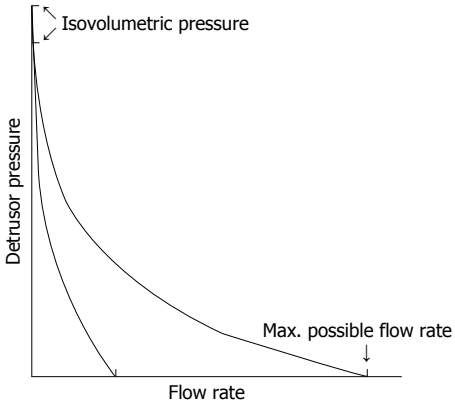

Figure 2 Bladder output relations relating active detrusor pressure to rate of urine flow at a given bladder volume. Curves show Bladder output relations for the same two situations as in Figure 1, corresponding to a full bladder (curve with higher maximum possible flow rate) and a nearly empty bladder (lower maximum possible flow rate; volume approximately 12.5% of capacity). (From Griffiths[8]. Assessment of detrusor contraction strength or contractility. Neurourol Urodyn 1991; 10: 1; with permission).

In their work, Tanagho *et al*[12] studied the initiation of voiding by simultaneously using cineradiography and recording pressures in the urethra, bladder, rectum and anal sphincter. They described 5 different voiding patterns: (1) Decrease in urethral closure pressure followed by contraction of the detrusor; (2) detrusor contraction without decrease in urethral pressure; (3) decrease in urethral closure pressure and increase of intravesical pressure due to straining; (4) increase of intravesical pressure due to straining without decrease in urethral pressure; and (5) decrease in urethral closure pressure without straining or contraction of the detrusor. They stated that only patients with low urethral closure pressure voided with negligible or no detrusor contraction. This leads to question if these types of voiding are indeed normal[12]. Of notice, from our knowledge of the BOR we can asseverate that women with very low bladder outlet resistance who do not strain to void should be using their bladder detrusor to void even if no increase in detrusor pressure is detected.

Few studies have described the voiding patterns of "healthy, continent and/or asymptomatic" women. Furthermore, definitions of what is considered detrusor contraction and straining to void vary between these studies (Table 1)[13-16]. All women included in these reports voided with a measurable detrusor contraction and variable participation of abdominal muscles (0%-73%). Backman *et al*[17] studied 15 normal women of all ages and found that they all initiated voiding by increasing abdominal pressure. However, young women did not use straining during the whole micturition as often as elderly women did. Consequently, the authors argued that the detrusor muscle tends to lose some of its power with age[17].

BOO

BOO "is the generic term for obstruction during voiding and is characterized by increased detrusor pressure and reduced urine flow rate"[2]. Women typically void at lower detrusor pressures than men. Small increases in detrusor pressure or decreases in flow rate, probably considered insignificant in men, could correspond to BOO in women. BOO in women without neurological diseases can be classified as anatomic or functional. Anatomic causes of BOO include high grade pelvic organ prolapse, previous anti-incontinence surgery and urethral disease (stricture, diverticulum). Functional causes of BOO are primary bladder neck obstruction and dysfunctional voiding (also known as learned voiding dysfunction) among other less frequent causes[18]. Currently, no consensus exists regarding urodynamic criteria to define BOO in women. Attempts have been made to establish a standard for the diagnosis of BOO in women, grouping them into one of three categories: (1) Pressure-flow cutoff criteria; (2) video-urodynamics criteria; and (3) nomograms.

The major studies of pressure-flow cutoff criteria for the diagnosis of BOO in women have been reported by the Department of Urology of the University of Texas Southwestern Medical Center. This group published three articles in which they calculated the best combination of maximum flow rate (Q_{max}) and detrusor pressure at maximum flow rate ($p_{det}Q_{max}$) using receiver operating characteristic curves in women who had a clinical diagnosis of BOO[19-21]. In two of their studies, control groups included women suffering stress urinary incontinence, whereas a third study included healthy volunteers to correct for effects of low outlet resistance. Their last study included 169 consecutive women with clinically diagnosed obstruction. That is to say, a history of urethral or bladder neck surgery, pelvic examination revealing urethral hyper-elevation or high grade anterior vaginal wall prolapse and altered voiding cystourethrography and/or endorectal coil magnetic resonance imaging. The study reported high-stage anterior vaginal wall prolapse, previous anti-

Table 1 Voiding patterns of "healthy, continent or asymptomatic" women

	Rud *et al*[13]	Rud *et al*[14]	Karram *et al*[15]	Pauwels *et al*[16]
No. of patients	16	6	30	26
Patients condition	Healthy	Healthy	Asymptomatic, continent	Healthy, history free, continent
Age, yr (range)	33 (23-73)	42 (37–54)	34	26
Definitions				
Detrusor contraction	Not defined	Not defined	Increase in detrusor pressure of 5 cm H_2O above resting pressure	Increase in detrusor pressure of 15 cm H_2O above resting pressure[1]
Strain to void	Not defined	Not defined	Increase in abdominal pressure of at least 10 cm H_2O above baseline	Increase in abdominal pressure of at least 10 cm H_2O above baseline during the entire voiding phase
Voiding pattern				
Drop in urethral pressure	16/16 (100%)	6/6 (100%)	Not studied	Not studied
Detrusor contraction	16/16 (100%)	6/6 (100%)	30/30 (100%)	26/26 (100%)
Strain to void	0/16 (0%)	0/6 (0%)	22/30 (73%)	11/26 (42%)

[1]There was no definition of detrusor contraction but increase in detrusor pressures of at least 15 cm H_2O developed in all women.

incontinence surgery and documented distal urethral obstruction/periurethral fibrosis as causes of anatomic BOO. They excluded patients with neurologic conditions that could affect bladder function, patients with bladder capacity under 100 mL, abdominal strain during voiding greater than 10 cm H_2O, absence of urethral sphincter or pelvic floor relaxation during voiding (evidenced by patch electrode electromyography) together with inability to void for the PFS. Their results showed that "the $p_{det}Q_{max}$ value with a specificity of at least 60% and the greatest sensitivity for the detection of BOO was 25 cm H_2O, and that Q_{max} value resulting in equal sensitivity, specificity, and accuracy (68%) for predicting BOO was close to 12 mL/s" (cutoff criteria: $p_{det}Q_{max} \geq 25$ cm H_2O + $Q_{max} \leq 12$ mL/s)[21]. It is worth remembering that with voided volumes greater than 140 mL a $Q_{max} \leq 12$ mL/s falls under the 5th percentile of the Liverpool nomogram, and over 110 mL of voided volume a $Q_{max} \leq 12$ mL/s falls under the 10th percentile[22].

In a retrospective work, Nitti *et al*[23] described the video-urodynamic criteria used to diagnose BOO in 261 women with non-neurogenic voiding dysfunction, who were able to void during the PFS. They argued that if physological voiding in women take place at low detrusor pressure the bladder response to obstruction by producing higher voiding pressures might be difficult to notice. BOO was characterized as radiographic proof of obstruction from the bladder neck to the distal urethra when observing a sustained contraction the detrusor of any magnitude. This was generally associated with decrease or delay in urinary flow rate. The authors define radiographic obstruction at the bladder neck when it was either closed or narrow during voiding. Radiographic obstruction of the urethra was diagnosed when they detected a distinct area of narrowing with proximal dilatation. This method allows for diagnosis of the zone of obstruction. In this study 67 patients were considered obstructed and 185 patients unobstructed. Patients with BOO had anatomical (cystocele, urethral stricture, urethral diverticulum, iatrogenic obstruction from incontinence surgery, uterine prolapse and rectocele) and functional causes (dysfunctional voiding and primary bladder neck obstruction). When urodynamic parameters were compared, the obstructed cases had significantly higher mean $p_{det}Q_{max}$ (42.8 ± 22.8 cm H_2O *vs* 22.1 ± 11.3 cm H_2O), lower mean Q_{max} (9.0 ± 6.2 mL/s *vs* 20.2 ± 10 mL/s), and higher mean postvoid residual urine (157 ± 183 mL *vs* 33 ± 91 mL) than unobstructed cases. However, given that both groups presented wide intervals for each parameter, it was difficult to assign specific cutoff values[23].

Blaivas *et al*[24] developed a nomogram to asses BOO in women. They analyzed a database of 600 consecutive women referred for evaluation with urodynamic study. They found BOO in 50 patients when using the following criteria: (1) Free $Q_{max} \leq 12$ mL/s in at least two free-flow studies, combined with a maintained contraction of the detrusor and $p_{det}Q_{max} \geq 20$ cm H_2O in the PFS; (2) evident radiographic proof of BOO with a sustained detrusor contraction ≥ 20 cm H_2O and poor Q_{max}, regardless of free Q_{max}; and (3) incapacity to void using a transurethral catheter despite maintained detrusor contraction ≥ 20 cm H_2O. This group of patients was compared to 50 age-matched controls with no evidence of obstruction, 20 with normal urodynamic study and 30 patients presenting sphinteric-incontinence. They used two parameters to assess BOO: (1) Free Q_{max} (noninvasive maximum flow rate) instead of invasive Q_{max}, given that many unobstructed patients presented low Q_{max} because of the adverse effect of the transurethral catheter on Q_{max}; and (2) p_{detmax} (maximum detrusor pressure during voiding) instead of $p_{det}Q_{max}$, because isolated test of the parameters did not reveal a difference considered statistically significant. Also because $p_{det}Q_{max}$ cannot be assesed in presence of urinary retention since there is no measurable flow regardless of the possible presence of a detrusor contraction (whereas p_{detmax} may enable analysis). The analysis reported that the data was distributed in three clusters: (1) Unobstructed group of patients presenting low pressure and high flow; (2) obstructed patients presenting high pressure and low flow; and (3) a group with low-to-intermediate pressure and flow rates, which was subdivided into two categories. A four-zone nomogram was developed (Figure 3). The

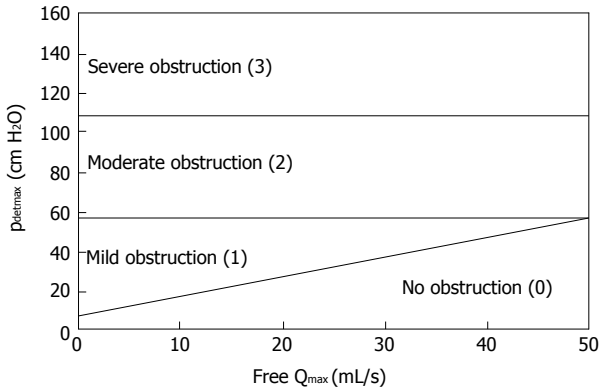

Figure 3 Bladder outlet obstruction nomogram for women. (From Blaivas *et al*[24]. Bladder outlet obstruction nomogram for women with lower urinary tract symptomatology. Neurourol Urodyn 2000; 19: 553; with permission).

boundaries between the four zones were: Between unobstructed and minimally obstructed: (1) A line with slope 1.0 and intercept 7 cm H_2O; *i.e.*, running through the point (0,7) and (50,57); (2) between minimally and moderately obstructed: A horizontal line at p_{detmax} of 57 cm H_2O; and (3) between moderately and severely obstructed: A horizontal line at p_{detmax} of 107 cm H_2O. Using this nomogram, all women with obstruction were correctly classified and further subclassified as mildly obstructed (68%), moderately obstructed (24%), and severely obstructed (8%). The authors found that subjective severity of symptoms (assessed by American Urological Association Symptom Score) was positively correlated to the zones of the nomogram. Of the patients classified as unobstructed, the nomogram correctly identified 80% as unobstructed, 8% as mildly obstructed, and 12% on the borderline between no obstruction and mild obstruction[24].

DU

DU is defined as a "detrusor contraction of reduced strength and/or duration, resulting in prolonged bladder emptying and/or a failure to achieve complete bladder emptying within a normal time span"[2]. This definition has remained unchanged through the last terminology report[3] and is based on two characteristics: (1) A weak strength of detrusor contraction; and (2) a short duration of the detrusor contraction. Both aspects of detrusor contractility seem to be independent. If the detrusor contraction is not adequately sustained, there will be postvoid residual urine[25].

The diagnosis of DU is based on pressure-flow studies and encompasses low-pressure, and poorly sustained contraction of the detrusor associated to low urinary flow[26]. There is no standard urodynamic test for diagnosing and quantifying DU and most measures only assess detrusor contraction strength and not duration[26,27]. It is challenging to make a correct diagnosis since measuring detrusor contraction strength is not easy and the criteria used for men are not applicable to women.

The presence of DU in several clinical groups suggests that its ethiopathogenesis tends to be multifactorial. Among non-neurogenic etiological factors leading to DU in women are: (1) Idiopathic cause due to physiological ageing, unknown causes in younger subjects; (2) myogenic: Long term BOO, overdistension injury, diabetes; (3) iatrogenic: Radical hysterectomy and pelvic surgery, abdominoperineal resection or anterior rectal resection; and (4) pharmacologic: Anticolinergic medication, tricyclic antidepressants[18,26].

According to the principles of voiding mechanics, detrusor contraction strength is expressed partially as pressure and partially as flow. Therefore the contraction strength is not the same as the pressure of the detrusor. In theory, the isovolumetric detrusor pressure obtained when there is interruption in flow or by continuous occluding with a balloon catheter, provides a good appraisal of detrusor contraction strength[28]. It also gives more reliable results than those obtained interrupting flow by voluntary contraction of the urethral sphincter due to reflex bladder contraction inhibition[29]. Because producing mechanical interruption of flow or continuous occlusion with a balloon catheter alters voiding, is difficult to perform and produces discomfort, other methods to estimate detrusor contraction strength have been developed based on the BOR. For example, if we know the slope and curvature of the BOR, we can estimate the isovolumetric detrusor pressure by extrapolating the pressure where it intersects the pressure axis[30].

Schafer simplified the BOR by using a straight line with a fixed slope of 5 cm H_2O/mL per second, not considering bladder volume, and obtaining the projected isovolumetric pressure (PIP) in men[5,6,30]. For a given void, PIP is assesed at the point of maximum flow rate. This was done using the following equation: PIP = $p_{det}Q_{max}$ + 5 Q_{max}. Schafer proposed that PIP values over 150 cm H_2O meant strong contractions; values from 100 to 150 cm H_2O, normal contractions; values from 50 to 100 cm H_2O, weak contractions; and values below 50 cm H_2O very weak contractions. He developed a contractility nomogram by drawing the corresponding BORs on a pressure-flow diagram, allowing the contraction strength to be classified in four groups[5,6,30]. Since 100 cm H_2O is a normal PIP value, the ratio PIP/(100 cm H_2O) is a coefficient with no dimension for which values over 1 represent normal or strong contractions, and values under 1, weak contractions. The ratio was nominated detrusor coefficient (DECO), and if it is expressed as a percentage it is numerically equal to PIP (in cm H_2O) and identical to the bladder contractility index (BCI) described later by Abrams[31].

Tan *et al*[30] compared stop-test isovolumetric pressures with approximate calculations based on pressure flow studies in a cohort of 100 women (mean age 70.1 years; range 53-89) suffering from urgency incontinence. Measurements were documented both pre- and post-treatment with placebo or oxybutynin. This allowed for investigation of test- retest reliability and

Table 2 Comparison of the reference isovolumetric pressure with estimates given by detrusor coefficient/bladder contractility index and projected isovolumetric pressure 1[1]

	Reference isovolumetric pressure (cm H_2O)	DECO/BCI ($p_{det}Q_{max}$ + 5 Q_{max})	PIP_1 ($p_{det}Q_{max}$ + Q_{max})
Mean ± SD (mean)	50 ± 25 (45)	133 ± 45 (128)	49 ± 17 (48)
5 and 95 percentiles	20/112	60/215	29/78
Mean difference (cm H_2O) from reference (95%CI: Wilcoxon signed ranks test)	-	86 (76-96; $P < 0.05$)	0.2 (-5 to 5; $P = 0.98$)
Spearman's coefficient of correlation with reference	-	0.21 ($P = 0.06$)	0.52 ($P < 0.01$)

[1]Modified from Tan *et al*[30]. DECO: Detrusor coefficient; BCI: Bladder contractility index; PIP_1: Projected isovolumetric pressure 1.

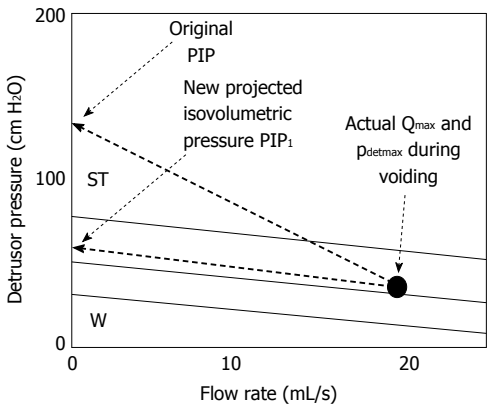

Figure 4 To determine projected isovolumetric pressure 1 the point representing the pressure and flow rate measured during uninterrupted voiding is projected back to the axis with a line of slope -1 cm H_2O/mL per second. (Note that the value of original PIP would be much larger). For this void, the value of PIP1 is about 60 cm H_2O, and the void falls in the band of typical values (unshaded). Values in the regions shaded gray would represent either ST or W contractions than those typical of the subjects in this group. (From Tan *et al*[30]. Stop test or pressure-flow study? Measuring detrusor contractility in older females. Neurourol Urodyn 2004: 23: 184 with permission). PIP: Projected isovolumetric pressure; ST: Stronger; W: Weaker.

responsiveness to small changes in contractility. They reported that the Schafer contractility nomogram and related parameters (DECO and BCI) used in men tend to greatly overestimate isovolumetric pressures in women. They suggested a modification called projected isovolumetric pressure 1 (PIP_1) which provided a more reliable estimate. This was based on the formula: $PIP_1 = p_{det}Q_{max} + Q_{max}$ (Figure 4). PIP_1 responded less to small changes in contraction strength than those observed for isovolumetric pressures measured using mechanical interference. Table 2 presents a comparison between the three variables. They concluded that in the group of elderly women with urgency incontinence, 90% of baseline PIP_1 values were observed between 29 and 78 cm H_2O. Thus, "contractions with PIP_1 smaller than about 30 cm H_2O might be considered unusually weak"[30].

Gotoh *et al*[32] studied the pathophysiology and subjective symptoms in 83 women with postvoid residual urine over 100 mL, most of whom had neurological diseases and postoperative problems after pelvic surgery. They defined impaired detrusor contraction in women who had Q_{max} less than 12 mL/s associated to $p_{det}Q_{max}$ less than 10 cm H_2O and significant rise in abdominal pressure[32]. In this study, the projected isovolumetric pressure to diagnose low detrusor contraction strength would be 20 cm H_2O, quite lower than the 30 cm H_2O proposed by Tan *et al*[30].

QUALITY CONTROL FOR PRESSURE-FLOW STUDIES IN WOMEN

The success of urodynamic studies depends on careful tuning of the equipment and strict quality control over each of the procedures. The ICS recommends using external transducers connected to fluid-filled tubings and catheters for intravesical and abdominal pressure recording. It also recommends circumspect and continuous observation of the signals as they are obtained and an ongoing assessment of their credibility to avoid artifacts which need to be corrected immediately, since they are difficult and often impossible to correct retrospectively[33]. This is especially true in women if we consider that relatively small changes in detrusor pressure (*i.e.*, 15 cm H_2O) can change the diagnosis from BOO to DU. The urodynamicists needs to avoid: (1) Damping of the abdominal pressure measurement specially during straining to void because it can create false high detrusor pressures; and (2) the use of catheter-mounted transducers or air-filled catheters, in which case the detrusor pressure measured depends on the position of the tip of the catheter within the bladder, with up to 8-10 cm H_2O differences if the tip of the catheter is at the top or at the bottom of the bladder[34,35]. Finally, it is important to remember that voluntary straining in healthy women can increase free Q_{max} by an average of 30%[36], making diagnosis of voiding dysfunction even more challenging.

Table 3 summarizes the urodynamic criteria used to define BOO and DU in women.

CONCLUSION

PFS of micturition is the best method to quantitatively analyze voiding function. Voiding dynamics differ significantly between men and women and the established criteria for urodynamic diagnosis in men do not apply to women. Although attempts have been made to standardize the diagnosis BOO in women, currently there is no consensus. There is no standard urodynamic test to

Table 3 Urodynamic criteria to define bladder outlet obstruction and detrusor underactivity in women

Bladder outlet obstruction	
Cutoff criteria[21]	$p_{det}Q_{max} \geq 25$ cm H_2O + $Q_{max} \leq 12$ mL/s
Video-urodynamic criteria[23]	Radiographic evidence of obstruction between the bladder neck and distal urethra in the presence of a sustained detrusor contraction of any magnitude, usually associated with reduced or delayed urinary flow rate
Nomogram[24]	See Figure 3
Detrusor underactivity	
Projected isovolumetric pressure 1[30]	$p_{det}Q_{max} + Q_{max} < 30$ cm H_2O
Cutoff criteria[32]	$p_{det}Q_{max} < 10$ cm H_2O + $Q_{max} < 12$ mL/s "and significant rise in abdominal pressure"

diagnose DU in women for which further investigations are needed. The diagnosis of voiding dysfunction in women is challenging and often involves consideration of clinical and radiographic data to make the final assessment.

REFERENCES

1 **Griffiths D**, Höfner K, van Mastrigt R, Rollema HJ, Spångberg A, Gleason D. Standardization of terminology of lower urinary tract function: pressure-flow studies of voiding, urethral resistance, and urethral obstruction. International Continence Society Subcommittee on Standardization of Terminology of Pressure-Flow Studies. *Neurourol Urodyn* 1997; **16**: 1-18 [PMID: 9021786]

2 **Abrams P**, Cardozo L, Fall M, Griffiths D, Rosier P, Ulmsten U, van Kerrebroeck P, Victor A, Wein A. The standardisation of terminology of lower urinary tract function: report from the Standardisation Sub-committee of the International Continence Society. *Neurourol Urodyn* 2002; **21**: 167-178 [PMID: 11857671]

3 **Haylen BT**, de Ridder D, Freeman RM, Swift SE, Berghmans B, Lee J, Monga A, Petri E, Rizk DE, Sand PK, Schaer GN. An International Urogynecological Association (IUGA)/International Continence Society (ICS) joint report on the terminology for female pelvic floor dysfunction. *Int Urogynecol J* 2010; **21**: 5-26 [PMID: 19937315 DOI: 10.1002/nau.20798]

4 **Abrams PH**, Griffiths DJ. The assessment of prostatic obstruction from urodynamic measurements and from residual urine. *Br J Urol* 1979; **51**: 129-134 [PMID: 465971]

5 **Schäfer W**. Principles and clinical application of advanced urodynamic analysis of voiding function. *Urol Clin North Am* 1990; **17**: 553-566 [PMID: 1695782]

6 **Schäfer W**. Analysis of bladder-outlet function with the linearized passive urethral resistance relation, linPURR, and a disease-specific approach for grading obstruction: from complex to simple. *World J Urol* 1995; **13**: 47-58 [PMID: 7773317 DOI: 10.1007/BF00182666]

7 **Hill AV**. The heat of shortening and the dynamic constants of muscle. *Proc R Soc London* (Biol) 1938; **126**: 136-193

8 **Griffiths DJ**. Assessment of detrusor contraction strength or contractility. *Neurourol Urodyn* 1991; **10**: 1-18 [DOI: 10.1002/nau.1930100102]

9 **Griffiths D**. Basics of pressure-flow studies. *World J Urol* 1995; **13**: 30-33 [PMID: 7773315]

10 **Griffiths DJ**. The mechanics of the urethra and of micturition. *Br J Urol* 1973; **45**: 497-507 [PMID: 4270633]

11 **Griffiths DJ**, van Mastrigt R. The routine assessment of detrusor contraction strength. *Neurourol Urodyn* 1985; **4**: 77-87

12 **Tanagho EA**, Miller ER. Initiation of voiding. *Br J Urol* 1970; **42**: 175-183 [PMID: 5420157]

13 **Rud T**, Ulmsten U, Andersson KE. Initiation of voiding in healthy women and those with stress incontinence. *Acta Obstet Gynecol Scand* 1978; **57**: 457-462 [PMID: 569418]

14 **Rud T**, Ulmsten U, Westby M. Initiation of micturition: a study of combined urethrocystometry and urethrocystography in healthy and stress incontinent females. *Scand J Urol Nephrol* 1979; **13**: 259-264 [PMID: 575232]

15 **Karram MM**, Partoll L, Bilotta V, Angel O. Factors affecting detrusor contraction strength during voiding in women. *Obstet Gynecol* 1997; **90**: 723-726 [PMID: 9351752]

16 **Pauwels E**, De Laet K, De Wachter S, Wyndaele JJ. Healthy, middle-aged, history-free, continent women--do they strain to void? *J Urol* 2006; **175**: 1403-1407 [PMID: 16516008]

17 **Backman KA**, von Garrelts B, Sundblad R. Micturition in normal women. Studies of pressure and flow. *Acta Chir Scand* 1966; **132**: 403-412 [PMID: 5969907]

18 **Blaivas J**, Chancellor M, Weiss J, Verhaaren M. Atlas of urodynamics, 2nd ed. Oxford: Blackwell Publishing Ltd, 2007: 120-144

19 **Chassagne S**, Bernier PA, Haab F, Roehrborn CG, Reisch JS, Zimmern PE. Proposed cutoff values to define bladder outlet obstruction in women. *Urology* 1998; **51**: 408-411 [PMID: 9510344]

20 **Lemack GE**, Zimmern PE. Pressure flow analysis may aid in identifying women with outflow obstruction. *J Urol* 2000; **163**: 1823-1828 [PMID: 10799191]

21 **Defreitas GA**, Zimmern PE, Lemack GE, Shariat SF. Refining diagnosis of anatomic female bladder outlet obstruction: comparison of pressure-flow study parameters in clinically obstructed women with those of normal controls. *Urology* 2004; **64**: 675-679; discussion 679-681 [PMID: 15491697]

22 **Haylen BT**, Ashby D, Sutherst JR, Frazer MI, West CR. Maximum and average urine flow rates in normal male and female populations--the Liverpool nomograms. *Br J Urol* 1989; **64**: 30-38 [PMID: 2765766]

23 **Nitti VW**, Tu LM, Gitlin J. Diagnosing bladder outlet obstruction in women. *J Urol* 1999; **161**: 1535-1540 [PMID: 10210391]

24 **Blaivas JG**, Groutz A. Bladder outlet obstruction nomogram for women with lower urinary tract symptomatology. *Neurourol Urodyn* 2000; **19**: 553-564 [PMID: 11002298]

25 **Griffiths D**. Detrusor contractility--order out of chaos. *Scand J Urol Nephrol Suppl* 2004; **215**: 93-100 [PMID: 15545203]

26 **van Koeveringe GA**, Vahabi B, Andersson KE, Kirschner-Herrmans R, Oelke M. Detrusor underactivity: a plea for new approaches to a common bladder dysfunction. *Neurourol Urodyn* 2011; **30**: 723-728 [PMID: 21661020]

27 **Osman NI**, Chapple CR, Abrams P, Dmochowski R, Haab F, Nitti V, Koelbl H, van Kerrebroeck P, Wein AJ. Detrusor underactivity and the underactive bladder: a new clinical entity? A review of current terminology, definitions, epidemiology, aetiology, and diagnosis. *Eur Urol* 2014; **65**: 389-398 [PMID: 24184024 DOI: 10.1016/j.eururo.2013.10.015]

28 **Tan TL**, Bergmann M, Griffiths D, Resnick N. Detrusor contractility: order out of chaos. *Neurourol Urodyn* 2002; **21**: 339

29 **Tan TL**, Bergmann MA, Griffiths D, Resnick NM. Which stop test is best? Measuring detrusor contractility in older females. *J Urol* 2003; **169**: 1023-1027 [PMID: 12576837]

30 **Tan TL**, Bergmann MA, Griffiths D, Resnick NM. Stop test or pressure-flow study? Measuring detrusor contractility in older females. *Neurourol Urodyn* 2004; **23**: 184-189 [PMID: 15098212]

31 **Abrams P**. Bladder outlet obstruction index, bladder contractility index and bladder voiding efficiency: three simple indices to define bladder voiding function. *BJU Int* 1999; **84**: 14-15 [PMID: 10444116]

32 **Gotoh M**, Yoshikawa Y, Ohshima S. Pathophysiology and subjective symptoms in women with impaired bladder emptying. *Int J Urol* 2006; **13**: 1053-1057 [PMID: 16903929]

33 **Schäfer W**, Abrams P, Liao L, Mattiasson A, Pesce F, Spangberg A, Sterling AM, Zinner NR, van Kerrebroeck P. Good urodynamic practices: uroflowmetry, filling cystometry, and pressure-flow studies. *Neurourol Urodyn* 2002; **21**: 261-274 [PMID: 11948720]
34 **Abrams P**. Urodynamics. 3rd ed. London: Springer-Verlag, 2006
35 **Gammie A**, Clarkson B, Constantinou C, Damaser M, Drinnan M, Geleijnse G, Griffiths D, Rosier P, Schäfer W, Van Mastrigt R. International Continence Society guidelines on urodynamic equipment performance. *Neurourol Urodyn* 2014; **33**: 370-379 [PMID: 24390971 DOI: 10.1002/nau.22546]
36 **Devreese AM**, Nuyens G, Staes F, Vereecken RL, De Weerdt W, Stappaerts K. Do posture and straining influence urinary-flow parameters in normal women? *Neurourol Urodyn* 2000; **19**: 3-8 [PMID: 10602243]

P- Reviewer: Ali-El-Dein B, Ching CB
S- Editor: Ji FF **L- Editor**: A **E- Editor**: Li D

World Journal of Clinical Urology

Submit a Manuscript: http://www.wjgnet.com/esps/
Help Desk: http://www.wjgnet.com/esps/helpdesk.aspx
DOI: 10.5410/wjcu.v5.i1.37

World J Clin Urol 2016 March 24; 5(1): 37-44
ISSN 2219-2816 (online)
© 2016 Baishideng Publishing Group Inc. All rights reserved.

MINIREVIEWS

Chylous ascites in laparoscopic renal surgery: Where do we stand?

Bum Soo Kim, Tae Gyun Kwon

Bum Soo Kim, Department of Urology, Kyungpook National University Hospital, Kyungpook National University School of Medicine, Daegu 41944, South Korea

Tae Gyun Kwon, Department of Urology, Chilgok Kyungpook National University Hospital, Kyungpook National University School of Medicine, Daegu 41404, South Korea

Author contributions: All authors equally contributed to this paper with conception and design of the study, literature review and analysis, drafting and critical revision and editing, and final approval of the final version.

Conflict-of-interest statement: No potential conflicts of interest. No financial support.

Open-Access: This article is an open-access article which was selected by an in-house editor and fully peer-reviewed by external reviewers. It is distributed in accordance with the Creative Commons Attribution Non Commercial (CC BY-NC 4.0) license, which permits others to distribute, remix, adapt, build upon this work non-commercially, and license their derivative works on different terms, provided the original work is properly cited and the use is non-commercial. See: http://creativecommons.org/licenses/by-nc/4.0/

Correspondence to: Tae Gyun Kwon, MD, PhD, Department of Urology, Chilgok Kyungpook National University Hospital, Kyungpook National University School of Medicine, 807 Hoguk-ro, Buk-gu, Daegu 41404, South Korea. tgkwon@knu.ac.kr
Telephone: +82-53-2003516
Fax: +82-53-4219618

Received: August 26, 2015
Peer-review started: August 31, 2015
First decision: November 27, 2015
Revised: November 30, 2015
Accepted: December 29, 2015
Article in press: January 4, 2016
Published online: March 24, 2016

Abstract

Postoperative chylous ascites, which is caused by the disruption of lymphatic channels and persistent lymphatic leakage, was a rare complication in the urologic field before laparoscopic surgery was introduced. Now that laparoscopic urologic surgery, especially laparoscopic nephrectomy, is widely performed, chylous ascites as a complication of laparoscopic renal surgery has been reported more frequently. With these accumulated experiences and data comes knowledge about the proper diagnosis and management of chylous ascites, although there is still some debate regarding the correct protocol for diagnosis and management. Therefore, we performed a systematic review of the current literature regarding the etiology, incidence, diagnosis, management, and prognosis of chylous ascites after laparoscopic renal surgery, as well as strategies used to prevent it, and discuss current perspectives on overcoming this complication in the laparoscopic age.

Key words: Chylous ascites; Kidney; Laparoscopy; Nephrectomy; Postoperative complications

© The Author(s) 2016. Published by Baishideng Publishing Group Inc. All rights reserved.

Core tip: Now that laparoscopic renal surgery is widely performed, postoperative chylous ascites is encountered more frequently. Although most cases can be managed conservatively without any critical sequelae, severe refractory cases may cause malnutrition and immunological deficiency and require interventional treatment. To overcome this complication, early diagnosis and proper choice of management strategies are necessary. Moreover, understanding the mechanism of and postoperative chylous ascites preventing its occurrence are the most important factors. Meticulous clipping around the great vessels and the use of hemostatic agents during laparoscopic nephrectomy can reduce the incidence of postoperative chylous ascites.

Kim BS, Kwon TG. Chylous ascites in laparoscopic renal

surgery: Where do we stand? *World J Clin Urol* 2016; 5(1): 37-44 Available from: URL: http://www.wjgnet.com/2219-2816/full/v5/i1/37.htm DOI: http://dx.doi.org/10.5410/wjcu.v5.i1.37

INTRODUCTION

Since Clayman *et al*[1] first reported the use of laparoscopic nephrectomy in 1991, the technique has been widely performed and includes simple, living-donor, radical, partial nephrectomy and nephroureterectomy. There are several advantages of laparoscopic nephrectomy, such as reduced blood loss and postoperative pain, faster recovery, better cosmesis, and an earlier return to normal activities compared to open nephrectomy. Although laparoscopic nephrectomy has gained popularity due to these merits, unique complications are associated with this technique[2-5].

Chylous ascites, which is the accumulation of chyle in the peritoneal cavity, is mostly caused by diseases that interfere with the abdominal or retroperitoneal lymphatic glands[6]. Postoperative chylous ascites, which is caused by the disruption of lymphatic channels and persistent chyle leakage, was a rare complication in urologic field before the introduction of laparoscopic surgery[6,7]. The reported incidence of chylous ascites after laparoscopic nephrectomy ranges from 0.013% to 5.9% and is more common after radical or donor nephrectomy[7-12]. Although most cases of chylous ascites after laparoscopic nephrectomy can be successfully managed conservatively without critical sequelae, severe refractory cases can develop even with proper medical management. These severe refractory cases can cause devastating complications such as malnutrition, infection, and immunological deficiency and often require invasive and aggressive treatment, because chyle is rich in fat, lymphyocytes and immunoglobulins, therefore, loss of chyle means a loss of nutritional energy and immunocompetence[6].

To our knowledge, the first case of chylous ascites after laparoscopic nephrectomy was reported by Shafizadeh *et al*[13] in 2002. It occurred after laparoscopic donor nephrectomy, and the patient was conservatively managed with an elemental diet and diuretics for 2 wk. Since that time, many case reports as well as large population-based studies have reported chylous ascites after laparoscopic nephrectomy. Although many studies demonstrated that chylous ascites after laparoscopic nephrectomy is rare, it seems this complication occurs more frequently after laparoscopic renal surgery than after open procedures.

Because laparoscopic renal surgery is becoming more common, urologists need to know how to properly diagnose and manage postoperative chylous ascites. Here, we review the current literature related to chylous ascites after laparoscopic renal surgeries as well as open procedures and discuss current perspectives on the development, management, and prevention of this complication.

LITERATURE SEARCH

We performed a PubMed search of the literature on chylous ascites after laparoscopic renal surgery using "chylous ascites" or "chyloperitoneum" and "nephrectomy" as the subject heading. The search yielded 58 articles, 46 of which were related to chylous ascites after renal surgery. Most (31 articles) were case reports, and of the studies with results distinguished by type of surgery, 20 studies involved donor nephrectomy, 17 involved radical nephrectomy, 7 involved simple nephrectomy, 4 involved nephroureterectomy, and 2 involved partial nephrectomy. Among these, 28 articles were associated with laparoscopic nephrectomy, including 4 retroperitoneoscopic procedures.

ETIOLOGY AND INCIDENCE

Chylous ascites can be caused by several pathological conditions, such as congenital defects of the lymphatic system, malignant neoplasm, liver cirrhosis, blunt or surgical trauma, surgical injury to the lymphatic channels, and peritoneal infections caused by nonspecific bacteria, parasite and tuberculosis[6]. Abdominal malignancy in adults and congenital lymphatic abnormalities in children are the most common causes of chylous ascites[14]. Meanwhile, postoperative chylous ascites was a rare complication, especially in the urologic field. The mechanism of postoperative chylous ascites is operative damage to the thoracic duct, cisterna chili, or other major retroperitoneal lymphatic channel that results in lymphoperitoneal fistula formation and accumulation of chyle in the peritoneal cavity[6,7]. Thus, abdominal aortic surgery is the most common cause of postoperative chylous ascites, accounting for more than 80% of postoperative chylous complications[15]. Although the main cause of postoperative chylous ascites is abdominal aortic surgery, spinal surgeries that use a transabdominal approach or gynecologic and urologic surgeries have also been reported to cause this complication. Postoperative chylous ascites in the urologic field has traditionally been reported after retroperitoneal surgery involving extensive lymphadenectomy for testicular or kidney cancer[16-25].

Since the introduction of laparoscopy to the field of urologic surgery, reports of chylous ascites following laparoscopic nephrectomy have become more frequent[7-9,11-13,26-46]. The reported incidence of chylous ascites after laparoscopic nephrectomy ranges from 0.6% to 5.9%[7-11]. The proposed cause for this increased incidence of chylous ascites after laparoscopic nephrectomy is that lymphatics are not routinely ligated during laparoscopic surgery, even though they are usually burned with energy-based sealing devices such as monopolar or bipolar electrocautery and ultrasonic shears[9,11,47,48]. Although chylous ascites after laparoscopic nephrectomy

is frequently reported, reported incidence of chylous ascites was quite different. These differences in incidence may be due to the differences in surgical technique among surgeons and the placement and indwelling time of the drainage catheter. If a surgeon prefers wide dissection and extensive lymphadenectomy during laparoscopic radical nephrectomy and usually performs extensive dissection around the hilar area and skeletonizing renal pedicle, aorta, and/or inferior vena cava during any type of laparoscopic nephrectomy, the incidence of postoperative chylous ascites may increase. In addition, many milder cases of chyle leak due to minor lymphatic channel disruption can improve spontaneously, without the need for any additional treatment. However, routine placement of the drainage catheter and indwelling it until oral intake is resumed may lead to early diagnosis of these milder cases of chylous ascites, which can spontaneously improve and may not be diagnosed if a drainage catheter is not placed[7]. This may be another reason for the variation in the reported incidence of chylous ascites after laparoscopic nephrectomy.

DIAGNOSIS

Chylous ascites is defined by the presence of chylomicrones, which are however difficult to measure, so that triglycerides are usually taken as surrogate parameters. Use of an indwelling drainage catheter is the easiest and earliest means by which to diagnose postoperative chylous ascites. If the color of the drainage fluid changes to milky white, chylous ascites can be suspected. However, if a drainage catheter is not placed, early diagnosis is difficult. Moreover, the milky aspect may be misleading if the patient is fasting (in the absence of fat absorption, no triglycerides are transported) or if the ascites is chylous and bloody, which may resemble pus. Clinical diagnosis can be made by physical signs and symptoms of peritoneal fluid accumulation, similar to those of ascites due to other causes, including abdominal distention, dyspnea due to limitations of diaphragmatic movement, and weight gain. Nonspecific gastrointestinal symptoms such as nausea, vomiting, dyspepsia, and rarely wound site ascites leakage can be present. Most studies did not mention the time to presentation of these symptoms, but it is generally variable, ranging from several days to months after surgery[6].

When patients present these symptoms and accumulation of ascitic fluid is found by physical examination and/or imaging studies, such as abdominal ultrasound or computed tomography (CT), chylous ascites can be confirmed by analyzing the ascites obtained by diagnostic paracentesis. It is typically milky in color, odorless, and sterile, and it has a high triglyceride content (usually 2- to 8-fold that of plasma or greater than 150-200 mg/dL)[6,7]. However, sterility is not necessary for the diagnosis of chylous ascites, which may become superinfected.

Several imaging techniques can be used to diagnose chylous ascites. CT can be used to confirm the accumulation of ascitic fluid in the peritoneal cavity, but CT findings are not specific to chylous ascites, and it is indistinguishable from urine, bile, bowel secretions, and simple ascites[6,49]. Lymphangiography is useful for the diagnosis of chylous ascites, enabling localization of the exact site of injury to the lymphatic channels[50]. However, an invasive procedure must be performed to find the exact site of chyle leakage, which is not necessary for cases that can be managed conservatively. Thus, lymphangiography should be considered for patients in whom conservative treatment fails and for whom surgical repair is planned to localize the exact site of chyle leakage[7]. Lymphoscintigraphy and radionuclide scans, such as a simple diaminetriamine-pentaacetic acid renal scan, can also be used as noninvasive, physiological radiologic diagnostic tools for the diagnosis of chylous ascites. Lymphoscintigraphy may be especially useful when lymphangiography is contraindicated[51], and it can also be used during patient follow-up to confirm a decrease or cessation of chyle leakage[52]. These imaging techniques may indicate the cause of chylous ascites, but are not adequate to diagnose chylous ascites.

MANAGEMENT

Although the severity of chylous ascites varies, several cases may spontaneously resolve without any specific treatment, because a small amount of ascitic fluid can be absorbed in the peritoneal cavity and a small leakage site of the lymphatic channel can close spontaneously. Therefore, many clinically insignificant cases might not be detected if a drain tube is not routinely placed after surgery. This may explain why the incidence of chylous ascites after laparoscopic nephrectomy is lower in most studies than in those conducted by Kim *et al*[7] and Capocasale *et al*[9].

Several strategies have been used to treat postoperative chylous ascites, and some investigators have reported their own management protocol[6,11]. Although there is still some debate over the correct approach, most authors advocate conservative treatment as an initial treatment modality[6,7,9,11,28]. Conservative treatment aims to decrease mesenteric lymphatic flow and consequently limit the leakage of chyle into the peritoneum. Moreover, other goals of conservative treatment are relief of the mechanical symptoms, such as abdominal distention, and restoration of nutritional losses. The success rate of conservative treatment ranges from 67% to 100%[6,10,11].

Conservative treatment includes therapeutic paracentesis, dietary modification, total parenteral nutrition, and the use of somatostatin analogs. If the drainage tube is placed when chylous ascites is detected, natural continuous drainage of ascitic fluid can be expected and accumulation of ascites in the peritoneal cavity can be prevented. However, in cases of delayed suspicion of chylous ascites without a drainage tube, paracentesis may be necessary to confirm the diagnosis of chylous ascites and relieve abdominal fullness. Nevertheless,

there are some concerns that repeat paracentesis or permanent drainage catheter placement may cause prolonged leakage, increasing both nutritional and immunological depletion and the risk of infection[6,17,53,54]. Intravenous reinfusion of ascitic fluid may prevent the nutritional losses associated with paracentesis or percutaneous drainage, but this carries the risk of serious complications, such as fat embolism and infection[55].

Dietary intervention, which includes medium-chain triglycerides and high-protein and low-fat intake, is normally used as a first-line treatment. It can reduce the lymphatic flow in the major lymphatic channels and facilitate the closure of chylous leakage[6,9]. Approximately 50% of mild cases of chylous ascites can be resolved using dietary intervention alone, and this treatment should be continued for several weeks or months to prevent recurrences[6,11].

Total parenteral nutrition is also an effective conservative management modality for postoperative chylous ascites. It can reduce the production and flow of lymph by allowing the bowels to rest[6]. The success rate of total parenteral nutrition alone or combined with a medium-chain triglyceride, high-protein, and low-fat diet for several weeks ranges from 60% to 100%[6,7,9,11]. Many investigators recommend total parenteral nutrition as a second-line treatment when conservative management with dietary modification fails. However, several studies, including our previous study, demonstrated that an early trial of total parenteral nutrition in patients with postoperative chylous ascites may be more effective and facilitate earlier improvement[7,53]. Total parenteral nutrition can also be used as a last treatment regimen when interventional or surgical treatment fails[6]. More recently, Jairath *et al*[11] suggested that if the daily drainage output of chylous ascites is less than 500 mL, dietary modification should be tried first, but if the drain output is greater than 500 mL per day, total parenteral nutrition should be used as a first-line treatment.

Since Ulíbarri *et al*[56] reported the effectiveness of continuous intravenous high-dose somatostatin for the closure of postoperative lymphatic drainage in 1990, somatostatin and its analogs are widely used, although their exact mechanism of action is not clearly understood[11]. Somatostatin is known to decrease the intestinal absorption of fats and attenuate lymphatic flow in the major lymphatic channels. Moreover, it reduces gastric, pancreatic, and intestinal secretions, inhibits intestinal activity and slows intestinal absorption, and decreases splanchnic blood flow, which may contribute to reduced lymphatic production[6]. Based on these data and clinical experience, earlier use of somatostatin and its analogue are highly recommended in combination with dietary intervention[6,11].

Although many cases of postoperative chylous ascites can be successfully managed using conservative treatment, there are severe refractory cases that require surgical repair. The purpose of surgical repair is direct ligation of the chyle leakage site. It was historically performed using an open procedure, but with the development of laparoscopic techniques, successful management can be expected using a laparoscopic approach[34,38,57]. Although the exact timing of surgical intervention remains controversial, previous studies recommend 4 to 12 wk of conservative treatment before surgery[6,7,9,11]. However, some authors have recommended early interventional treatment to provide a better chance of direct visualization of the injured lymphatics and definite repair, thus preventing nutritional and immunological deficiency and prolonged hospitalization[6,58,59]. Since the most important step in surgical repair is to identify the chylous leakage point, several authors have suggested milk ingestion or a high-fat diet before surgery or intravenous indigo carmine injection during surgery[34,60]. If a leakage point cannot be identified, nonselective suturing of the periaortic or pericaval tissues can resolve chyle leakage. In addition, application of a hemostatic agent, such as fibrin glue, can also effectively occlude disrupted lymphatic channels[6,9].

Alternatively, peritoneovenous shunting and percutaneous transabdominal embolization can be performed, especially in patients with poor performance status and persistent severe chyle leakage[6,61-63]. Although peritoneovenous shunting does not cause nutritional deficiency, as ascitic fluid is recirculated, and has a lower risk of infection compared to repeat paracentesis, it can also carry the risk of serious complications, such as fat embolism, disseminated intravascular coagulation, and sepsis[6,11,53]. Cope *et al*[62] reported successful embolization of the lymphatic ducts using a transabdominal percutaneous puncture, but there are limited data related to percutaneous embolization, and more studies are needed to validate the efficacy and safety of this procedure.

PROGNOSIS

Chylous ascites after laparoscopic nephrectomy is most commonly reported after living-donor nephrectomy, although it can occur after any type of laparoscopic nephrectomy (radical, partial, simple, nephroureterectomy, or donor) (Table 1). The success rate of conservative treatment in published studies of laparoscopic nephrectomy ranges from 50% to 100%, except in case reports or original articles involving only 1 or 2 cases of chylous ascites[7,9,11,12,44]. In this review, 89 patients of chylous ascites after laparoscopic nephrectomy were included from original articles and case reports. Of these patients, 70 cases (78.7%) were success fully managed by conservative treatment (Table 1).

The prognosis of chylous ascites depends on the underlying pathological disease and can be poor, as mortality rates can be as high as 43% to 83%[6,55,64]. However, the prognosis of postoperative chylous ascites is generally favorable, with a significantly lower mortality rate[6,53]. Although it is likely that published reports of chylous ascites after laparoscopic nephrectomy contain more severe cases, most of these cases were successfully

Table 1 Previously reported cases of chylous ascites after laparoscopoic nephrectomy

Ref.	Type of laparoscopic nephrectomy	Success rate of conservative treatment (%)	Interventional treatment
Original articles			
Jairath *et al*[11]	Radical, donor, simple	67.7 (6/9)	Surgery
Tiong *et al*[12]	Donor	50 (5/10)	Surgery
Wan *et al*[44]	Partial	100 (5/5)	
Capocasale *et al*[9]	Donor	100 (8/8)	
He *et al*[31]	Donor	0 (0/1)	Surgery
Kim *et al*[3]	Radical, donor, simple, partial, nephroureterectomy	96.9 (31/32)	Surgery
Breda *et al*[8]	Donor	100 (2/2)	
Wadström[43]	Donor	0 (0/1)	Surgery
Ramani *et al*[39]	Donor	0 (0/1)	Surgery
Wu *et al*[45]	Donor	100 (1/1)	
Seo *et al*[46]	Donor	100 (2/2)	
Case reports			
Monge Mirallas *et al*[35]	Radical	100 (1/1)	
Itou *et al*[65]	Radical	0 (0/1)	Percutaneous obliteration
Fariña *et al*[29]	Radical	100 (1/1)	
Nishizawa *et al*[38]	Radical	0 (0/1)	Surgery
Meulen *et al*[33]	Donor	100 (1/1)	
Gagliano *et al*[30]	Donor	100 (1/1)	
Sinha *et al*[41]	Donor	0 (0/1)	Surgery
Aerts *et al*[26]	Donor	0 (0/1)	Surgery
Caumartin *et al*[28]	Donor	0 (0/1)	Surgery
Bachmann *et al*[27]	Donor	100 (1/1)	
Sharma *et al*[40]	Donor	100 (1/1)	
Molina *et al*[34]	Donor	0 (0/1)	Surgery
Shafizadeh *et al*[13]	Donor	100 (1/1)	
von Rundstedt *et al*[42]	Nephroureterectomy	100 (1/1)	
Negoro *et al*[37]	Nephroureterectomy	50 (1/2)	Sclerotherapy
Jensen *et al*[32]	Simple	100 (1/1)	

managed using conservative treatment. Moreover, even cases managed using interventional therapy successfully improved without any critical sequelae. Thus, one can expect a good prognosis if early diagnosis and proper management are achieved, although some severe cases will need to be managed using interventional therapy.

PREVENTION

With accumulated experience and understanding of the mechanisms of occurrence, early diagnosis and proper management of postoperative chylous ascites can be facilitated. However, although the incidence of postoperative chylous ascites is not very high, this complication can decrease a patient's quality of life and prolong hospitalization. Thus, the best treatment strategy is obviously the prevention of postoperative chylous ascites during the initial surgery. In our experience, appropriate lymphostasis cannot be achieved with monopolar, bipolar, or ultrasound devices, which are the most commonly used for hemostasis in laparoscopic nephrectomy[7]. Therefore, lymphatic channels should be identified and carefully divided during surgery (Figure 1A). In addition, if disruption of the lymphatic channels occurs and extravasation of lymphatic fluid is recognized intraoperatively, careful ligation of the lymphatic duct using hemoclips should be performed (Figure 1B). Moreover, empirical application of hemostatic agents over the dissected area, such as biological tissue adhesive and fibrin glue, can also be helpful, regardless of whether lymphatic disruption or extravasation is identified[9] (Figure 1C). Furthermore, the placement of a drainage tube in patients who are suspected to be at high risk of postoperative chylous ascites, such as obese patients, those undergoing extensive lymphadenectomy, or patients with obvious lymphatic leakage during surgery, can be useful for the early diagnosis of chylous ascites.

CONCLUSION

As laparoscopic nephrectomy has gained popularity, postoperative chylous ascites is no longer a very rare complication. Although many studies have reported a good prognosis for postoperative chylous ascites, it can become a highly morbid complication of laparoscopic renal surgery that requires early diagnosis and proper management. The treatment strategy should be individualized according to the severity of chylous ascites and its consequences. Initial management should be conservative treatment using high-protein, low-fat dietary modification with medium-chain triglycerides, total parenteral nutrition, and somatostatin or its analogs for several weeks. Depending on the severity of chylous ascites and the response to conservative treatment, interventional therapy including surgery, sclerotherapy, and peritoneovenous shunting should be considered. The prevention of postoperative chylous ascites is the most important factor. Therefore, careful dissection of the

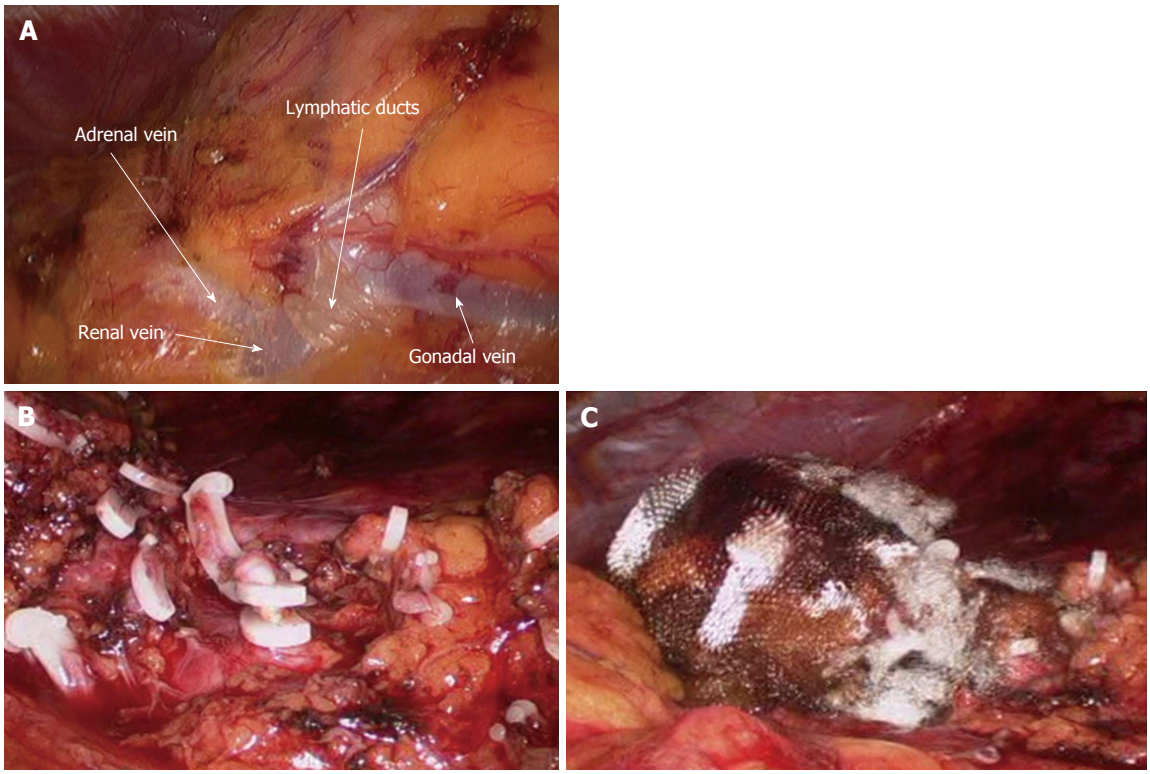

Figure 1 Intraoperative image of the hilar area during left-sided laparoscopic donor nephrectomy. A: Prominent lymphatic ducts cross the renal vein; B: The perihilar and retroperitoneal fatty tissue is meticulously clipped; C: The hilar area is completely sealed using surgicel and fibrin glue.

great vessels and renal pedicle, meticulous clipping and application of hemostatic agents to the area of perihilar and retroperitoneal fatty tissue, and placement of a drainage tube is highly recommended in patients at high risk of chylous ascites.

REFERENCES

1 **Clayman RV**, Kavoussi LR, Soper NJ, Dierks SM, Meretyk S, Darcy MD, Roemer FD, Pingleton ED, Thomson PG, Long SR. Laparoscopic nephrectomy: initial case report. *J Urol* 1991; **146**: 278-282 [PMID: 1830346]

2 **Hsu TH**, Su LM, Ratner LE, Kavoussi LR. Renovascular complications of laparoscopic donor nephrectomy. *Urology* 2002; **60**: 811-815; discussion 815 [PMID: 12429304]

3 **Kim BS**, Yoo ES, Kwon TG. Complications of transperitoneal laparoscopic nephrectomy: a single-center experience. *Urology* 2009; **73**: 1283-1287 [PMID: 19362334 DOI: 10.1016/j.urology.2009.01.017]

4 **Simon SD**, Castle EP, Ferrigni RG, Lamm DL, Swanson SK, Novicki DE, Andrews PE. Complications of laparoscopic nephrectomy: the Mayo clinic experience. *J Urol* 2004; **171**: 1447-1450 [PMID: 15017195 DOI: 10.1097/01.ju.0000117942.61971.41]

5 **Siqueira TM**, Kuo RL, Gardner TA, Paterson RF, Stevens LH, Lingeman JE, Koch MO, Shalhav AL. Major complications in 213 laparoscopic nephrectomy cases: the Indianapolis experience. *J Urol* 2002; **168**: 1361-1365 [PMID: 12352393 DOI: 10.1097/01.ju.0000023288.55478.42]

6 **Leibovitch I**, Mor Y, Golomb J, Ramon J. The diagnosis and management of postoperative chylous ascites. *J Urol* 2002; **167**: 449-457 [PMID: 11792897]

7 **Kim BS**, Yoo ES, Kim TH, Kwon TG. Chylous ascites as a complication of laparoscopic nephrectomy. *J Urol* 2010; **184**: 570-574 [PMID: 20639020 DOI: 10.1016/j.juro.2010.03.128]

8 **Breda A**, Veale J, Liao J, Schulam PG. Complications of laparoscopic living donor nephrectomy and their management: the UCLA experience. *Urology* 2007; **69**: 49-52 [PMID: 17270612 DOI: 10.1016/j.urology.2006.09.030]

9 **Capocasale E**, Iaria M, Vistoli F, Signori S, Mazzoni MP, Dalla Valle R, De Lio N, Perrone V, Amorese G, Mosca F, Boggi U. Incidence, diagnosis, and treatment of chylous leakage after laparoscopic live donor nephrectomy. *Transplantation* 2012; **93**: 82-86 [PMID: 22143459 DOI: 10.1097/TP.0b013e31823b2d8e]

10 **Harper JD**, Breda A, Leppert JT, Veale JL, Gritsch HA, Schulam PG. Experience with 750 consecutive laparoscopic donor nephrectomies--is it time to use a standardized classification of complications? *J Urol* 2010; **183**: 1941-1946 [PMID: 20303114 DOI: 10.1016/j.juro.2010.01.021]

11 **Jairath A**, Singh A, Ganpule A, Mishra S, Sabnis R, Desai M. Management Protocol for Chylous Ascites After Laparoscopic Nephrectomy. *Urology* 2015; **86**: 521-528 [PMID: 26210005 DOI: 10.1016/j.urology.2015.06.001]

12 **Tiong HY**, Goel RK, White WM, Goldfarb DA, Kaouk JH. Chylous ascites after laparoscopic donor nephrectomy. *Asian J Endosc Surg* 2015; **8**: 34-39 [PMID: 25384614 DOI: 10.1111/ases.12144]

13 **Shafizadeh SF**, Daily PP, Baliga P, Rogers J, Baillie GM, Rajagopolan PR, Chavin KD. Chylous ascites secondary to laparoscopic donor nephrectomy. *Urology* 2002; **60**: 345 [PMID: 12137847]

14 **Browse NL**, Wilson NM, Russo F, al-Hassan H, Allen DR. Aetiology and treatment of chylous ascites. *Br J Surg* 1992; **79**: 1145-1150 [PMID: 1467885]

15 **Combe J**, Buniet JM, Douge C, Bernard Y, Camelot G. [Chylothorax and chylous ascites following surgery of an inflammatory aortic aneurysm. Case report with review of the literature]. *J Mal Vasc* 1992; **17**: 151-156 [PMID: 1613407]

16 **Allen W**, Parrott TS, Saripkin L, Allan C. Chylous ascites following retroperitoneal lymphadenectomy for granulosa cell tumor of the testis. *J Urol* 1986; **135**: 797-798 [PMID: 3959207]

17 **Baniel J**, Foster RS, Rowland RG, Bihrle R, Donohue JP. Management of chylous ascites after retroperitoneal lymph node

dissection for testicular cancer. *J Urol* 1993; **150**: 1422-1424 [PMID: 8411415]
18 **Bigley HA**, Chenault OW. Chylous ascites following retroperitoneal lymphadenectomy. *J Urol* 1975; **114**: 948-950 [PMID: 1195482]
19 **Eberl W**, Kwee T, Mau G. [Chylous ascites after tumor nephrectomy with retroperitoneal lymphadenectomy]. *Monatsschr Kinderheilkd* 1991; **139**: 47-50 [PMID: 1851534]
20 **Ferrigni RG**, Novicki DE. Chylous ascites complicating genitourinary oncological surgery. *J Urol* 1985; **134**: 774-776 [PMID: 4032594]
21 **Isa Kroon WA**, Sánchez de la Muela P, Ucar Terren A, Robles García JE, Zudaire Bergera JJ, Berián Polo JM. [Post-lymphadenectomy lymphorrhagia caused by renal adenocarcinoma]. *Actas Urol Esp* 1988; **12**: 371-373 [PMID: 3189031]
22 **Jansen TT**, Debruyne FM, Delaere KP, de Vries JD. Chylous ascites after retroperitoneal lymph node dissection. *Urology* 1984; **23**: 565-567 [PMID: 6730125]
23 **Miedema EB**, Bissada NK, Finkbeiner AE, Casali RE. Chylous ascites complicating retroperitoneal lymphadenectomy for testis tumors: management with peritoneovenous shunting. *J Urol* 1978; **120**: 377-382 [PMID: 682267]
24 **Spence CR**, Solomon HD, Agee RE, Gangai MP. Chylous ascites: an unusual complication following retroperitoneal lymphadenectomy for testis tumor. *J Urol* 1977; **117**: 676-677 [PMID: 859211]
25 **Jayabose S**, Kogan S, Berezin S, Slim M, San Filippo JA, Godine L, Beneck D, Tugal O, Sunkara S. Combined occurrence of chyloperitoneum and chylothorax after surgery and chemotherapy for Wilms' tumor. *Cancer* 1989; **64**: 1790-1795 [PMID: 2551473]
26 **Aerts J**, Matas A, Sutherland D, Kandaswamy R. Chylous ascites requiring surgical intervention after donor nephrectomy: case series and single center experience. *Am J Transplant* 2010; **10**: 124-128 [PMID: 19958336 DOI: 10.1111/j.1600-6143.2009.02883.x]
27 **Bachmann A**, Ruszat R, Dickenmann M, Giannini O, Mayr M, Steiger J, Gasser TC, Sulser T. Chyloretroperitoneum with secondary chylothorax after retroperitoneoscopic donor nephrectomy. *Urology* 2005; **66**: 881 [PMID: 16230168 DOI: 10.1016/j.urology.2005.04.025]
28 **Caumartin Y**, Pouliot F, Sabbagh R, Dujardin T. Chylous ascites as a complication of laparoscopic donor nephrectomy. *Transpl Int* 2005; **18**: 1378-1381 [PMID: 16297058 DOI: 10.1111/j.1432-2277.2005.00219.x]
29 **Fariña LA**, Martínez MC. [Chylous ascites following radical nephrectomy. Conservative management whithout paracentesis]. *Actas Urol Esp* 2009; **33**: 703-705 [PMID: 19711757]
30 **Gagliano M**, Veroux P, Corona D, Cannizzaro MA, Giuffrida G, Giaquinta A, Veroux M. Chylous ascites following laparoscopic living donor nephrectomy. Case report. *Ann Ital Chir* 2011; **82**: 499-503 [PMID: 22229241]
31 **He B**, Mitchell A, Delriviere L, Shannon T, Pemberton R, Tan A, Bremner A, Vivian J. Laparoscopic donor nephrectomy. *ANZ J Surg* 2011; **81**: 159-163 [PMID: 21342388 DOI: 10.1111/j.1445-2197.2010.05568.x]
32 **Jensen JB**, Ostraat EO. [Chyloascites after laparoscopic nephrectomy]. *Ugeskr Laeger* 2008; **170**: 2892 [PMID: 18796289]
33 **Meulen ST**, van Donselaar-van der Pant KA, Bemelman FJ, Idu MM. Chylous ascites after laparoscopic hand-assisted donor nephrectomy: Is it specific for the left-side? *Urol Ann* 2013; **5**: 45-46 [PMID: 23662011 DOI: 10.4103/0974-7796.106967]
34 **Molina WR**, Desai MM, Gill IS. Laparoscopic management of chylous ascites after donor nephrectomy. *J Urol* 2003; **170**: 1938 [PMID: 14532813 DOI: 10.1097/01.ju.0000091660.15018.66]
35 **Monge Mirallas JM**, Asensio Lahoz LA, Ruiz Izquierdo F, Campos Sañudo JA, Martínez Bretones F, Martín Cuesta L. Chylous ascytis causing abdominal distension after laparoscopic radical nephrectomy. *Arch Esp Urol* 2014; **67**: 575-578 [PMID: 25048591]
36 **Mullins JK**, Pierorazio PM, Hyams ES, Mitchell SE, Allaf ME. Lymphangiography with sclerotherapy: a novel therapy for refractory chylous ascites. *Can J Urol* 2012; **19**: 6250-6254 [PMID: 22704307]
37 **Negoro H**, Oka H, Kawakita M. Two cases of chyloretroperitoneum following retroperitoneoscopic nephroureterectomy. *Int J Urol* 2006; **13**: 487-489 [PMID: 16734885 DOI: 10.1111/j.1442-2042.2006.01427.x]
38 **Nishizawa K**, Ito N, Yamamoto S, Kamoto T, Ogawa O. Successful laparoscopic management of chylous ascites following laparoscopic radical nephrectomy. *Int J Urol* 2006; **13**: 619-621 [PMID: 16771738 DOI: 10.1111/j.1442-2042.2006.01372.x]
39 **Ramani AP**, Gill IS, Steinberg AP, Abreu SC, Kilciler M, Kaouk J, Desai M. Impact of intraoperative heparin on laparoscopic donor nephrectomy. *J Urol* 2005; **174**: 226-228 [PMID: 15947643 DOI: 10.1097/01.ju.0000162048.15746.52]
40 **Sharma A**, Heer M, Subramanaym Malladi SV, Minz M. Chylous ascites after laparoscopic donor nephrectomy. *J Endourol* 2005; **19**: 839-840 [PMID: 16190840 DOI: 10.1089/end.2005.19.839]
41 **Sinha A**, Mamode N. Laparoscopic management of chylous ascites following laparoscopic donor nephrectomy. *BMJ Case Rep* 2010; **2010**: bcr0820092141 [PMID: 22242080 DOI: 10.1136/bcr.08.2009.2141]
42 **von Rundstedt FC**, Kamper L, Brandt AS, Lazica D, Roth S. [Chylous ascites after laparoscopic nephroureterectomy]. *Aktuelle Urol* 2009; **40**: 44-48 [PMID: 19177321 DOI: 10.1055/s-0028-1098713]
43 **Wadström J**. Hand-assisted retroperitoneoscopic live donor nephrectomy: experience from the first 75 consecutive cases. *Transplantation* 2005; **80**: 1060-1066 [PMID: 16278586]
44 **Wan Y**, Tang Z, Chen Z, Tian W, Xiao L, Luo K, Li D. [Chylous leakage after retroperitoneoscopic upper-pole heminephrectomy for duplex kidney]. *Zhong Nan Da Xue Xue Bao Yi Xue Ban* 2012; **37**: 405-407 [PMID: 22561573 DOI: 10.3969/j.issn.1672-7347.2012.04.015]
45 **Wu CT**, Chiang YJ, Liu KL, Chu SH. Laparoscopic donor nephrectomy: new combination of hand-assisted and standard approaches. *Transplant Proc* 2004; **36**: 1909-1911 [PMID: 15518695 DOI: 10.1016/j.transproceed.2004.08.096]
46 **Seo SI**, Kim JC, Hwangbo K, Park YH, Hwang TK. Comparison of hand-assisted laparoscopic and open donor nephrectomy: a single-center experience from South Korea. *J Endourol* 2005; **19**: 58-62 [PMID: 15735385 DOI: 10.1089/end.2005.19.58]
47 **Kajiyama Y**, Iwanuma Y, Tomita N, Amano T, Hattori K, Tsurumaru M. Sealing the thoracic duct with ultrasonic coagulating shears. *Hepatogastroenterology* 2005; **52**: 1053-1056 [PMID: 16001628]
48 **Abe K**, Terashima M, Fujiwara H, Takagane A, Uesugi N, Saito K. Experimental evaluation of bursting pressure in lymphatic vessels with ultrasonically activated shears. *World J Surg* 2005; **29**: 106-109 [PMID: 15592912 DOI: 10.1007/s00268-004-7547-5]
49 **Patten RM**, Calkins CM, Moore EE. Isolated traumatic rupture of the cisterna chyli: CT diagnosis. *J Comput Assist Tomogr* 1999; **23**: 701-702 [PMID: 10524850]
50 **Sachs PB**, Zelch MG, Rice TW, Geisinger MA, Risius B, Lammert GK. Diagnosis and localization of laceration of the thoracic duct: usefulness of lymphangiography and CT. *AJR Am J Roentgenol* 1991; **157**: 703-705 [PMID: 1892021 DOI: 10.2214/ajr.157.4.1892021]
51 **Baulieu F**, Baulieu JL, Mesny J, Ducouret N, Benhamou AC, Barsotti J, Itti R. Visualization of the thoracic duct by lymphoscintigraphy. *Eur J Nucl Med* 1987; **13**: 264-265 [PMID: 3665972]
52 **Andrews JT**, Binder LJ. Lymphoscintigraphy pre- and post-surgical lymphatic leak repair. *Australas Radiol* 1996; **40**: 19-21 [PMID: 8838882]
53 **Pabst TS**, McIntyre KE, Schilling JD, Hunter GC, Bernhard VM. Management of chyloperitoneum after abdominal aortic surgery. *Am J Surg* 1993; **166**: 194-198; discussion 198-199 [PMID: 8352415]
54 **DeHart MM**, Lauerman WC, Conely AH, Roettger RH, West JL, Cain JE. Management of retroperitoneal chylous leakage. *Spine* (Phila Pa 1976) 1994; **19**: 716-718 [PMID: 8009338]
55 **Vasko JS**, Tapper RI. The surgical significance of chylous ascites.

Arch Surg 1967; **95**: 355-368 [PMID: 4166570]
56 **Ulíbarri JI**, Sanz Y, Fuentes C, Mancha A, Aramendia M, Sánchez S. Reduction of lymphorrhagia from ruptured thoracic duct by somatostatin. *Lancet* 1990; **336**: 258 [PMID: 1973814]
57 **Geary B**, Wade B, Wollmann W, El-Galley R. Laparoscopic repair of chylous ascites. *J Urol* 2004; **171**: 1231-1232 [PMID: 14767309 DOI: 10.1097/01.ju.0000110104.68489.70]
58 **Aalami OO**, Allen DB, Organ CH. Chylous ascites: a collective review. *Surgery* 2000; **128**: 761-778 [PMID: 11056439 DOI: 10.1067/msy.2000.109502]
59 **Boran N**, Cil AP, Tulunay G, Ozgul N, Kose MF. Chylous ascites following para-aortic lymphadenectomy: a case report. *Gynecol Oncol* 2004; **93**: 711-714 [PMID: 15196870 DOI: 10.1016/j.ygyno.2004.03.022]
60 **Ma L**, Pu Q, Zhu Y, Liu L. Chyle leakage in port incision after video-assisted thoracoscopic surgery: case report. *J Cardiothorac Surg* 2010; **5**: 83 [PMID: 20950471 DOI: 10.1186/1749-8090-5-83]
61 **Akhan O**, Karcaaltincaba M, Ozmen MN, Akinci D, Karcaaltincaba D, Ayhan A. Percutaneous transcatheter ethanol sclerotherapy and catheter drainage of postoperative pelvic lymphoceles. *Cardiovasc Intervent Radiol* 2007; **30**: 237-240 [PMID: 17205362 DOI: 10.1007/s00270-006-0180-y]
62 **Cope C**. Diagnosis and treatment of postoperative chyle leakage via percutaneous transabdominal catheterization of the cisterna chyli: a preliminary study. *J Vasc Interv Radiol* 1998; **9**: 727-734 [PMID: 9756057]
63 **Matsufuji H**, Nishio T, Hosoya R. Successful treatment for intractable chylous ascites in a child using a peritoneovenous shunt. *Pediatr Surg Int* 2006; **22**: 471-473 [PMID: 16477467 DOI: 10.1007/s00383-006-1648-1]
64 **Ablan CJ**, Littooy FN, Freeark RJ. Postoperative chylous ascites: diagnosis and treatment. A series report and literature review. *Arch Surg* 1990; **125**: 270-273 [PMID: 2405815]
65 **Itou C**, Koizumi J, Myojin K, Yamashita T, Mori N, Imai Y. A case of refractory chylous ascites after nephrectomy successfully treated with percutaneous obliteration using adhesive glue. *Jpn J Radiol* 2013; **31**: 71-74 [PMID: 23065489 DOI: 10.1007/s11604-012-0146-8]

P- Reviewer: Lutz P **S- Editor**: Ji FF
L- Editor: A **E- Editor**: Li D

World Journal of Clinical Urology

Submit a Manuscript: http://www.wjgnet.com/esps/
Help Desk: http://www.wjgnet.com/esps/helpdesk.aspx
DOI: 10.5410/wjcu.v5.i1.45

World J Clin Urol 2016 March 24; 5(1): 45-52
ISSN 2219-2816 (online)
© 2016 Baishideng Publishing Group Inc. All rights reserved.

ORIGINAL ARTICLE

Retrospective Cohort Study

Adjuvant radiotherapy for pathologically advanced prostate cancer improves biochemical recurrence free survival compared to salvage radiotherapy

Robert H Blackwell, William Gange, Alexander M Kandabarow, Matthew M Harkenrider, Gopal N Gupta, Marcus L Quek, Robert C Flanigan

Robert H Blackwell, Gopal N Gupta, Marcus L Quek, Robert C Flanigan, Department of Urology, Loyola University Medical Center, Maywood, IL 60153, United States

William Gange, Alexander M Kandabarow, Stritch School of Medicine, Loyola University Chicago, Maywood, IL 60153, United States

Matthew M Harkenrider, Department of Radiation Oncology, Loyola University Medical Center, Maywood, IL 60153, United States

Author contributions: All the authors contributed to this paper.

Institutional review board statement: The study was approved by the institutional review board.

Informed consent statement: Given the retrospective nature of this study with minimal risk of harm, patient informed consent was waived by the institutional review board.

Conflict-of-interest statement: All of the authors report no conflict of interest (financial or otherwise) related to the manuscript.

Open-Access: This article is an open-access article which was selected by an in-house editor and fully peer-reviewed by external reviewers. It is distributed in accordance with the Creative Commons Attribution Non Commercial (CC BY-NC 4.0) license, which permits others to distribute, remix, adapt, build upon this work non-commercially, and license their derivative works on different terms, provided the original work is properly cited and the use is non-commercial. See: http://creativecommons.org/licenses/by-nc/4.0/

Correspondence to: Robert H Blackwell, MD, Department of Urology, Loyola University Medical Center, 2160 S, First Avenue, Building 54, Room 261, Maywood, IL 60153, United States. rblackwell@lumc.edu
Telephone: +1-708-2165100
Fax: +1-708-2161699

Received: September 2, 2015
Peer-review started: September 8, 2015
First decision: October 16, 2015
Revised: November 24, 2015
Accepted: January 8, 2016
Article in press: January 11, 2016
Published online: March 24, 2016

Abstract

AIM: To evaluate the long-term outcomes of patients receiving adjuvant and salvage radiotherapy following prostatectomy with adverse pathologic features and an undetectable prostate specific antigen (PSA).

METHODS: A retrospective review was performed of patients who received post-prostatectomy radiation at Loyola University Medical Center between 1992 and 2013. Adverse pathologic features (Gleason score ≥ 8, seminal vesicle invasion, extracapsular extension, pathologic T4 disease, and/or positive surgical margins) and an undetectable PSA following prostatectomy were required for inclusion. Adjuvant patients received therapy with an undetectable PSA, salvage patients following biochemical recurrence (BCR). Post-radiation BCR, overall survival, bone metastases, and initiation of hormonal therapy were assessed. Kaplan-Meier time-to-event analyses and stepwise Cox proportional hazards regression (HR) were performed.

RESULTS: Post-prostatectomy patients (n = 134) received either adjuvant (n = 47) or salvage (n = 87) radiation. Median age at radiotherapy (RT) was 63

years, and median follow-up was 53 mo. Five-year post-radiation BCR-free survival was 78% for adjuvant *vs* 50% salvage radiotherapy (SRT) (Logrank P = 0.001). Patients with radiation administered following a detectable PSA had an increased risk of BCR compared to undetectable: PSA > 0.0-0.2: HR = 4.1 (95%CI: 1.5-11.2; P = 0.005); PSA > 0.2-1.0: HR = 4.4 (95%CI: 1.6-11.9; P = 0.003); and PSA > 1.0: HR = 52 (95%CI: 12.9-210; P < 0.001). There was no demonstrable difference in rates of overall survival, bone metastases or utilization of hormonal therapy between adjuvant and SRT patients.

CONCLUSION: Adjuvant RT improves BCR-free survival compared to SRT in patients with adverse pathologic features and an undetectable post-prostatectomy PSA.

Key words: Radiotherapy; Adjuvant; Radiotherapy; Salvage therapy; Recurrence; Prostatic neoplasms

© The Author(s) 2016. Published by Baishideng Publishing Group Inc. All rights reserved.

Core tip: We evaluated the outcomes of patients who received post-prostatectomy radiotherapy (RT) who had adverse features on the pathologic specimen and an immediately undetectable prostate specific antigen (PSA) postoperatively. In this cohort of patients, those who received RT in the adjuvant therapy (*e.g.*, while PSA remains undetectable) had an improved 5-year biochemical recurrence (BCR)-free survival of 78%, compared to 50% for patients receiving RT in the salvage setting (*e.g.*, after the postoperative PSA has again become detectable). As such, adjuvant RT improves BCR free survival in post-prostatectomy patients with adverse pathologic features and an undetectable PSA compared to salvage RT.

Blackwell RH, Gange W, Kandabarow AM, Harkenrider MM, Gupta GN, Quek ML, Flanigan RC. Adjuvant radiotherapy for pathologically advanced prostate cancer improves biochemical recurrence free survival compared to salvage radiotherapy. *World J Clin Urol* 2016; 5(1): 45-52 Available from: URL: http://www.wjgnet.com/2219-2816/full/v5/i1/45.htm DOI: http://dx.doi.org/10.5410/wjcu.v5.i1.45

INTRODUCTION

An estimated 233000 men in the United States will be diagnosed with prostate cancer (PCa) in 2014[1]. While radical prostatectomy (RP) is a curative treatment for many patients, approximately one-third of patients will experience recurrence of disease within 10 years of surgery[2-4]. Pathological features such as positive surgical margins (PSM), seminal vesicle invasion (SVI), extracapsular extension (ECE), Gleason score ≥ 8, and/or pathologic adjacent organ invasion are associated with a higher risk of biochemical recurrence (BCR)[5-8]. In these high risk patients adjuvant radiotherapy (ART) can be offered, however this leads to overtreatment of approximately 55% of patients who may never experience a BCR[4,9]. Patients who defer initial adjuvant therapy are closely monitored and offered salvage radiotherapy (SRT) if and when they experience BCR.

Three randomized controlled trials (SWOG 8794, EORTC 22911, and ARO 96-02) have been conducted comparing ART with observation following RP in patients with adverse pathologic features and an undetectable prostate specific antigen (PSA). These have demonstrated improved BCR-free survival with ART compared with observation (patients may or may not have received SRT)[5,6,10,11]. Despite these convincing data, only approximately 11.7% of patients with pT3-4N0 disease undergo ART according to an analysis of the Surveillance Epidemiology and End Results database[12]. Investigation into SRT in this same patient population (adverse pathologic features with undetectable PSA) has not been as purposefully studied in randomized controlled trials, although several retrospective studies[9,13-18], including two matched-control analyses[17,18], have been performed in this area.

In this study, we present our experience with the outcomes of ART and SRT in post-RP patients at a high risk for recurrence, with adverse pathologic features and an initial post-RP undetectable PSA.

MATERIALS AND METHODS

Patient selection

Following institutional review board approval a retrospective chart review was performed. All patients who were counseled for RT for PCa between 1992 and 2013 were identified. Of the 886 patients who subsequently received RT at our institution, 248 had a history of prior RP.

The patient demographic and pathologic PCa information listed in Table 1 was abstracted from *via* a comprehensive review of physician notes and laboratory reports (bloodwork, pathology reports, *etc.*).

Post-prostatectomy RT patients were grouped according to pathologic characteristics, postoperative PSA nadir level, and the timing of administration of post-prostatectomy RT (before/after BCR). Adjuvant therapy candidates were defined as patients with one or more adverse pathologic features (total Gleason score ≥ 8, SVI, PSM, ECE, and/or adjacent organ invasion) and an undetectable post-RP nadir PSA level. For this study, an undetectable PSA was defined as a PSA with a value of < 0.05 ng/mL. Patients with a detectable post-RP PSA (n = 54, 21.8%), the absence of adverse pathologic features (n = 50, 20.2%), or both of the aforementioned criteria (n = 10, 4.0%) were not considered to be adjuvant therapy candidates and excluded from analysis. Adjuvant therapy candidates who received RT with an

Table 1 Patient characteristics

		Received adjuvant therapy	Adjuvant candidate and received salvage radiotherapy	*P* value
Age at RT (median, IQR), mo		60 (54-65)	63 (59-68)	0.2
Follow-up (mo)		53 (19-83)	50 (22-854)	0.1
Time from RP to RT, mo	0-12	43 (93%)	12 (14%)	< 0.001
	> 12-24	3 (7%)	18 (21%)	
	> 24-48	0 (0%)	29 (33%)	
	> 48	0 (0%)	28 (32%)	
Pre-RT PSA	Undetectable	46 (100%)	0 (0%)	< 0.001
	> 0-0.2	0 (0%)	39 (46%)	
	> 0.2-1.0	0 (0%)	38 (45%)	
	> 1.0	0 (0%)	7 (8%)	
Received	No	37 (79%)	67 (77%)	0.8
Peri-RT ADT	Yes	10 (21%)	20 (23%)	
Coronary artery disease	No	36 (86%)	64 (84%)	0.8
	Yes	6 (14%)	12 (16%)	
Diabetes mellitus, type Ⅱ	No	37 (88%)	58 (76%)	0.1
	Yes	5 (12%)	18 (24%)	
Hypertension	No	19 (45%)	37 (49%)	0.6
	Yes	23 (55%)	39 (51%)	
Obesity	No	31 (74%)	51 (67%)	0.4
	Yes	11 (26%)	25 (33%)	
Peripheral vascular disease	No	39 (93%)	73 (96%)	0.4
	Yes	3 (7%)	3 (4%)	
Smoking history	No	37 (88%)	70 (92%)	0.5
	Yes	5 (12%)	6 (8%)	
Pathologic	2-6	9 (20%)	18 (21%)	0.4
Gleason score	7	21 (48%)	48 (57%)	
	8-10	14 (32%)	18 (21%)	
Pathologic	T1	0 (0%)	0 (0%)	0.08
Tumor stage	T2	11 (25%)	35 (41%)	
	T3/T4	33 (75%)	51 (59%)	
Positive surgical margin	Absent	12 (25%)	28 (32%)	0.4
	Present	35 (75%)	59 (68%)	
Extracapsular extension	Absent	20 (43%)	41 (47%)	0.6
	Present	27 (57%)	46 (53%)	
Seminal vesicle invasion	Absent	37 (79%)	80 (92%)	0.03
	Present	10 (21%)	7 (8%)	

RP: Radical prostatectomy; RT: Radiotherapy; IQR: Interquartile range; ADT: Androgen deprivation therapy; PSA: Prostate specific antigen.

undetectable PSA were classified as having received ART. Salvage therapy candidates were defined as those who following an undetectable postoperative PSA level, who later developed a detectable PSA level. Phoenix criteria of post-RP BCR were utilized (a PSA of ≥ 0.2 ng/mL, with a second consecutive test at or above this level) to define BCR following RT[19].

Treatment

Standard post-prostatectomy RT was provided to patients as either adjuvant or SRT (as above) and administered at 66.6 Gy fractionated over approximately 37 doses to the prostatic fossa and seminal vesicle remnants, if present.

Endpoints

The outcomes of interest that were evaluated include time to BCR, overall survival (OS), bone metastasis (BMet), and hormonal therapy (HT). BCR was considered to take place on the date of the first of two or more successive PSA values ≥ 0.2 ng/mL after RT. OS was defined as death from any cause. BMet was defined as any radiologic, pathologic, or clinical evidence of bony metastasis. HT was defined the initiation of androgen deprivation therapy following post-RT BCR.

Statistical analysis

Kaplan-Meier method was utilized to analyze BCR-, OS-. BMet, and HT-free survival functions. The time span between the event of interest and the final day of RT was analyzed. Patients entered the model at the date of completion of RT. If an event did not occur, the patient was considered to be right-censored for that event with the time between the day of the last follow-up and the final day of RT. A stepwise Cox proportion hazard regression was modelled to evaluate the independent effect of the categorical variables and treatment modalities in Table 1. Variables were selected in a forward fashion, with P = 0.05 meeting the standard for inclusion into the model. Variables with $P \geq 0.10$ were deemed insignificant and removed from the model.

SPSS® version 20 (SPSS, Chicago, IL), was utilized, with all comparisons 2-sided and a P-value < 0.05 was

considered statistically significant.

RESULTS

Between 1992 and 2013 our institution treated 886 patients with RT for PCa, of whom 248 received post-prostatectomy RT. Patients with adverse pathologic features, an undetectable nadir PSA, and who received post-RP RT accounted for 134 patients. Of these, 47 (35%) received ART and 87 (65%) received SRT. The median follow-up after RT was 53 (22-96) mo, and median age at RT was 63 (58-68) years old (Table 1).

For patients receiving ART *vs* SRT, pre-RT patient characteristics differed only in time from RP to RT (93% ART patients received therapy within 12 mo, compared with 14% SRT, $P < 0.001$), pre-RT PSA level (undetectable in 100% ART and 0% SRT, $P < 0.001$), and a higher rate of SVI in the ART cohort (12% *vs* 8%, $P = 0.028$). Medical comorbidities were comparable between the groups. There were no statistical differences in total Gleason score or frequency of PSM, ECE, or pathologic T4 disease between the two treatment groups.

BCR free survival

Kaplan-Meier 5-year BCR-free survival were 78% and 50% for ART and SRT, respectively (Logrank, $P = 0.001$) (Figure 1). On univariate analysis, receipt of RT at an undetectable level, and pathologic Gleason score < 8 were associated with improved BCR-free survival. On multivariate analysis, the predominant factor associated with BCR was PSA level at time of RT. Compared with RT administered with an undetectable PSA (ART), BCR was more likely when RT was administered as SRT with detectable pre-RT PSA levels as follows: > 0.0 to 0.2 ng/mL (HR = 4.1; $P = 0.005$), > 0.2-1.0 ng/mL (HR = 5.5; $P = 0.003$), and ≥ 1.0 ng/mL (HR = 52, $P < 0.001$) (Table 2). A sensitivity analysis was performed with pre-RT cutoff of PSA ≤ 0.5 ng/mL compared to undetectable, which demonstrated a similar improved BCR-free survival with adjuvant therapy (data not shown). Pathologic Gleason score of ≥ 8 also increases risk of BCR in the multivariate model (HR = 3.1; $P = 0.02$).

OS

Kaplan-Meier estimates of 5-year OS were 97% for both ART and SRT patients. A total of 3 (6%) ART and 8 (9%) SRT patients have died since RT (Logrank, $P = 0.5$). No variables contributed to OS on multivariate analysis (Table 2).

Bone metastasis

Five-year actuarial risks of bone metastasis were 0% and 6% for ART and SRT, respectively (Logrank, $P = 0.9$). Three ART patients (6%) and five SRT patients (6%) developed metastatic disease to the bone over the course of follow-up. On univariate analysis, patients who received ART had improved bone metastasis-free survival (Logrank $P = 0.004$). On multivariate analysis, patients who received SRT with a PSA ≥ 1.0 had an increased risk of bone metastases (HR = 39.806; $P = 0.02$) compared to patients who received ART (undetectable PSA) (Table 2).

Time to hormonal therapy

There was trend toward decreased utilization of hormonal therapy at 5 years post-RT in ART (6%) compared with SRT (21%) patients (Logrank, $P = 0.08$). Median time from RT to additional treatment was 218 mo for ART and 142 mo for SRT. Based on pre-RT PSA level, there was a worse HT-free survival in patients receiving RT with a PSA > 1.0, which remained true on multivariate analysis (HR = 67.841; $P < 0.001$) (Table 2). A sensitivity analysis run with pre-RT PSA ≤ 0.5 ng/mL compared to undetectable demonstrated a similar risk of progression to HT. With a PSA >0.5 ng/mL, there was an increased risk of receipt of HT (data not shown). Further, a pathologic Gleason score of 8-10 was associated with an increased risk for receipt of HT on univariate and multivariate analyses (Table 2).

DISCUSSION

Our results demonstrate that patients with adverse pathologic features (Gleason 8-10, SVI, ECE, PSM, and/or pathologic T4 disease) and an undetectable PSA have improved oncologic results with ART compared to SRT. When patients were observed until PSA became detectable and then received SRT there was an increased risk of post-RT BCR, even in the early RT (PSA < 0.2) setting. When SRT was administered with a pre-RT PSA level > 1.0, the risk of BCR, BMet and HT increased dramatically. While pathologic Gleason score 8-10 was also associated with BCR, and both pathologic Gleason 8-10 and SVI were associated with progression to HT, the receipt of RT prior to detectable PSA was shown to be the only modifiable risk factor available to the treating clinician to impact BCR-free survival.

Three randomized controlled trials (SWOG 8794, EORTC22911, and ARO 96-02) have definitely demonstrated that ART in this high-risk patient population results in improved BCR-free survival compared to RP and observation alone[5,6,10,11]. Two of these studies (SWOG 8794 and EORTC 22911) have demonstrated reduced need for salvage therapy for RT failure when patients were administered ART compared to RP and observation[5,10]. The benefit of an observational approach would be to spare men exposure to RT until they experience a BCR, which would never occur for an as of yet unspecified population. The question of whether there is a benefit to administration of ART compared with SRT at the time of BCR, as assessed in this study, has yet to be reported in a randomized controlled trial. Three trials which will address this question are currently enrolling patients in Australia/New Zealand (RAVES)[20], France (GETUG-17)[21], and in the United Kingdom and Canada (RADICALS)[22], although results are pending.

Table 2 Stepwise cox regression multivariate analysis

		Biochemical recurrence		Overall survival		Bone metastases		Hormonal therapy	
		HR (95%CI)	*P* value	HR (95%CI)	*P* value	HR (95%CI)	*P* value	HR (95%CI)	*P* value
Pathologic gleason score	2-6	Referent	0.01	Referent	0.4	Referent	0.3	Referent	0.005
	7	1.2 (0.4-3.1)	0.8		0.7		0.9	1.2 (0.3-4.6)	0.8
	8-10	3.1 (1.2-8.1)	0.02		0.2		0.1	4.9 (1.4-16.7)	0.01
Pre-RT PSA	Undetectable	Referent	< 0.001	Referent	0.8	Referent	0.045	Referent	< 0.001
	> 0.0-0.2	4.1 (1.5 -11.2)	0.005		0.8	3.3 (0.2-54.2)	0.4	2.6 (0.8-9.1)	0.1
	> 0.2-1.0	4.4 (1.6-11.9)	0.003		0.6	0.6 (0.04-8.6)	0.7	1.7 (0.5-5.8)	0.4
	> 1.0	52 (12.9-210)	< 0.001		0.7	39.8 (1.8-868)	0.02	67.8 (13.7-336)	< 0.001
Received peri-RT ADT			0.7		0.2		0.1		0.6
Seminal vesicle invasion		2.2 (0.99-4.8)	0.053		0.9		0.2	2.7 (1.1-6.6)	0.036
Positive surgical margin			0.056		0.08		0.08		0.09
Extracapsular extension			0.3		0.1		0.6		0.6
Pathologic stage	T2	Referent	0.9	Referent	0.1	Referent	0.9	Referent	0.8
	T3/4								

RT: Radiotherapy; PSA: Prostate specific antigen; ADT: Androgen deprivation therapy; CI: Confidence interval.

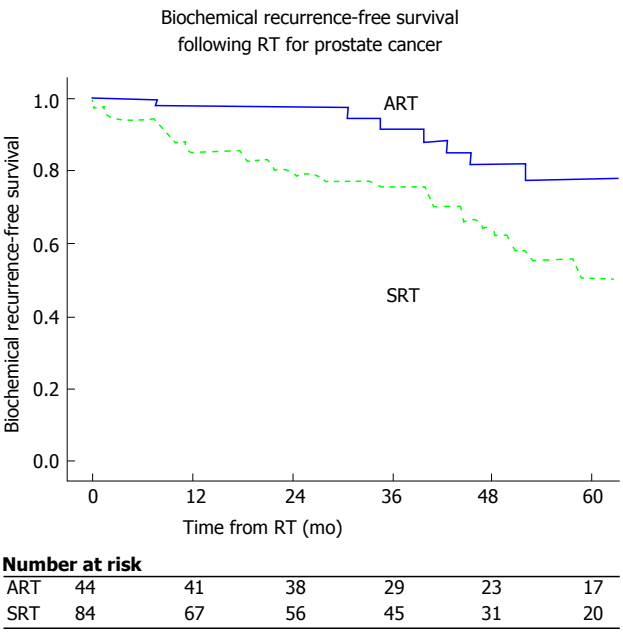

Figure 1 Biochemical recurrence-free survival for adjuvant candidates receiving adjuvant *vs* salvage radiotherapy for prostate cancer. RT: Radiotherapy; SRT: Salvage radiotherapy; ART: Adjuvant radiotherapy.

Until these trials meet accrual and have sufficient follow-up to produce meaningful conclusion, the literature remains sparse. A recent review and meta-analysis has been performed on the available, retrospective data, demonstrating an improved BCR-free survival in ART-treated patients compared to those treated with SRT[23]. While this analysis is in agreement with our findings, caution is necessary when interpreting a review of this topic. The current literature has markedly variability of the definitions of both ART and SRT, which confound generalizability and interpretation. Our study included strict inclusion criteria for analysis, including only patients with adverse pathologic features following RP and an undetectable post-RP PSA. Of the 18 studies included in the review above, eight did not require an undetectable post-RP PSA for SRT patients and four allowed ART patients to have a detectable post-RP PSA. While SRT may be administered in a different settings (*e.g.*, detectable PSA immediately post-RP, rising PSA from undetectable post-RP), ART should be administered within 6-12 mo post-operatively with an undetectable PSA. It is important to strictly define these criteria prior to analysis in order to compare treatment effects on comparable baseline patient cohorts.

Of the retrospective studies available, three deserve special mention and represent the best evidence to date regarding ART *vs* SRT in post-RP patients with adverse pathologic features and an undetectable PSA. Trabulsi *et al*[18] reported on 449 patients received postoperative RT for adverse pathologic features with an undetectable postoperative nadir PSA. After propensity score matching, 96 patients remained in each treatment group (ART and SRT). With a median follow-up of 73 mo from RT, there was improvement in five-year BCR-free survival in the ART group (73% *vs* 50%; HR = 2.3; $P = 0.007$). Comparable to the present study, pathologic Gleason score 8-10 was found to be associated with BCR (HR = 2.5; $P = 0.005$).

Ost *et al*[17] and coworkers reported a comparable match-controlled analysis of 178 patients, with 89 in each group. Three-year BCR-free survival was improved for ART *vs* SRT (90% and 65%, $P < 0.05$) in this analysis as well. Further, patients with Gleason score ≥ 4 + 3, preoperative PSA > 10 ng/mL, and omission of concomitant androgen deprivation therapy had an increase in risk for BCR.

Briganti *et al*[9] performed a multi-institutional retrospective review of 390 patients who received ART. These patients were matched in a one-to-one fashion based on pathologic Gleason score, pathologic stage and surgical margin status, with patients who underwent initial observation and SRT as needed for BCR. Kaplan-Meier analysis indicated comparable BCR-free survival between the ART and observation/SRT matched cohorts. While this analysis does examine optimal patient management with

post-RP SRT prior to PSA 0.5 ng/mL, exclusion of patients who may have presented with a recurrence PSA of ≥ 0.5 ng/mL may omit more aggressive cases, and artificially improve BCR-free survival rates in the observation/SRT cohort. Further, Briganti's study assesses time to BCR following RP, while Ost, Trabulsi, and the present study assess time to BCR following RT, limiting the ability to make comparisons between the studies.

Taken together with the present studies, it appears that when patients are compared following the receipt of RT, there is improvement in BCR-free survival with ART compared to SRT. The randomized, controlled trials above will hopefully provide definitive evidence regarding the timing of RT following RP, as well as define the patients who are adjuvant therapy candidates (adverse pathologic features with an undetectable post-RP PSA) who will or will not ultimately experience a BCR necessitating RT.

The primary limitation of our study is selection bias, specifically how patients arrived at the decision to pursue ART *vs* SRT. This decision is not solely dependent on pathologic and laboratory values, and patients may have been counseled to either of these treatment strategies based on personal preference, physician preference, their recovery from surgery, and convenience of therapy availability. Further, the potential side-effects of RT (including urethral stricture disease, hematuria, proctitis, cystitis, secondary malignancy, *etc.*) are well documented[24-30], and play an integral role in the decision making process for both the patient and provider. These subjective choices are not reflected in our analysis. This analysis also does not have the denominator for how many patients elected for observational follow-up and did not recur. Avoiding overtreatment of patients with RT is a commendable goal, however until prospective trials are completed it is difficult to characterize which patients will or will not experience BCR. Finally, there was greater SVI in the ART compared to the SRT group. While this difference between treatment groups does exist, it should not influence the reported results as the greater SVI should have negatively impacted outcomes in the ART cohort, which was not seen.

COMMENTS

Background

Radiotherapy (RT) for prostate cancer (PCa) following RT is a treatment option available for patients with adverse pathologic features (positive surgical margins, seminal vesicle invasion, extracapsular extension, a Gleason score ≥ 8, and/or pathologic adjacent organ invasion. While prior prospective, randomized trials have shown improved biochemical recurrence (BCR) free survival following adjuvant radiotherapy (ART) (immediately following recovery from prostatectomy) compared to observation, the comparison of adjuvant compared to salvage radiotherapy (SRT) [after postoperative prostate specific antigen (PSA) has risen from an undetectable level] has yet to be as rigorously studied.

Research frontiers

While adjuvant post-prostatectomy RT is known to improve BCR free survival, the optimal timing of administration RT is yet to be determined. Given the additional morbidity of RT and potential overtreatment of patients who may never recur with adjuvant radiation, the results of this study contribute to the understanding of outcomes between early (adjuvant) RT compared to delayed (salvage) RT in the post-prostatectomy population.

Innovations and breakthroughs

In this study, patients who received either adjuvant or SRT following radical prostatectomy with the presence of adverse pathologic features and an undetectable PSA were identified. This was a well-matched group when comparing baseline and pathologic characteristics. It is clear that patients who received ART had an improved BCR free survival at 5 years (78%) compared to those who received SRT (50%).

Applications

This study suggests that the receipt of ART for post-prostatectomy adverse pathologic features improved BCR free survival compared to patients who receive salvage radiation following a rise in PSA from undetectable.

Terminology

PSA: Prostate specific antigen, a serum marker produced only by prostate and PCa cells. Adverse pathologic features: Poor prognostic findings on the prostate specimen including positive surgical margins, seminal vesicle invasion, extracapsular extension, a Gleason score ≥ 8, and/or pathologic adjacent organ invasion. ART: The administration of radiation to the prostatectomy surgical bed following recovery of surgery, while the patient has an undetectable PSA. SRT: The administration of radiation to the prostatectomy surgical bed following recovery of surgery, following an increase in PSA from undetectable to a detectable value.

Peer-review

This is an interesting retrospective study comparing the effects of adjuvant *vs* SRT on BCR free survival of high risk PCa pts with initially undetectable post-op PSA. This is well-written work and both the results and limitations of the study are adequately documented.

REFERENCES

1 American Cancer Society: Prostate cancer key statistics 2014. [accessed 2015 Dec 14]. Available from: URL: http//www.cancer.org/cancer/prostatecancer/detailedguide/prostate-cancer-key-statistics

2 **Amling CL**, Blute ML, Bergstralh EJ, Seay TM, Slezak J, Zincke H. Long-term hazard of progression after radical prostatectomy for clinically localized prostate cancer: continued risk of biochemical failure after 5 years. *J Urol* 2000; **164**: 101-105 [PMID: 10840432 DOI: 10.1016/S0022-5347(05)67457-5]

3 **Roehl KA**, Han M, Ramos CG, Antenor JA, Catalona WJ. Cancer progression and survival rates following anatomical radical retropubic prostatectomy in 3,478 consecutive patients: long-term results. *J Urol* 2004; **172**: 910-914 [PMID: 15310996 DOI: 10.1097/01.ju.0000134888.22332.bb]

4 **Thompson IM**, Valicenti RK, Albertsen P, Davis BJ, Goldenberg SL, Hahn C, Klein E, Michalski J, Roach M, Sartor O, Wolf JS, Faraday MM. Adjuvant and salvage radiotherapy after prostatectomy: AUA/ASTRO Guideline. *J Urol* 2013; **190**: 441-449 [PMID: 23707439 DOI: 10.1016/j.juro.2013.05.032]

5 **Bolla M**, van Poppel H, Collette L, van Cangh P, Vekemans K, Da Pozzo L, de Reijke TM, Verbaeys A, Bosset JF, van Velthoven R, Maréchal JM, Scalliet P, Haustermans K, Piérart M. Postoperative radiotherapy after radical prostatectomy: a randomised controlled trial (EORTC trial 22911). *Lancet* 2005; **366**: 572-578 [PMID: 16099293 DOI: 10.1016/S0140-6736(05)67101-2]

6 **Bolla M**, van Poppel H, Tombal B, Vekemans K, Da Pozzo L, de Reijke TM, Verbaeys A, Bosset JF, van Velthoven R, Colombel M, van de Beek C, Verhagen P, van den Bergh A, Sternberg C, Gasser T, van Tienhoven G, Scalliet P, Haustermans K, Collette L. Postoperative radiotherapy after radical prostatectomy for high-risk prostate cancer: long-term results of a randomised controlled trial (EORTC trial 22911). *Lancet* 2012; **380**: 2018-2027 [PMID:

23084481 DOI: 10.1016/S0140-6736(12)61253-7]

7 **Stephenson AJ**, Scardino PT, Kattan MW, Pisansky TM, Slawin KM, Klein EA, Anscher MS, Michalski JM, Sandler HM, Lin DW, Forman JD, Zelefsky MJ, Kestin LL, Roehrborn CG, Catton CN, DeWeese TL, Liauw SL, Valicenti RK, Kuban DA, Pollack A. Predicting the outcome of salvage radiation therapy for recurrent prostate cancer after radical prostatectomy. *J Clin Oncol* 2007; **25**: 2035-2041 [PMID: 17513807 DOI: 10.1200/JCO.2006.08.9607]

8 **Venyo A**, Imran S, Shah S, Gordon R, Barnes D. Serum PSA, Gleason Score and Clinical Staging in Predicting Biochemical (PSA) Failure After Radical Prostatectomy for Carcinoma of Prostate. *Webmed Central Urology* 2012; **3**: WMC003222 [DOI: 10.9754/journal.wmc.2012.003222]

9 **Briganti A**, Wiegel T, Joniau S, Cozzarini C, Bianchi M, Sun M, Tombal B, Haustermans K, Budiharto T, Hinkelbein W, Di Muzio N, Karakiewicz PI, Montorsi F, Van Poppel H. Early salvage radiation therapy does not compromise cancer control in patients with pT3N0 prostate cancer after radical prostatectomy: results of a match-controlled multi-institutional analysis. *Eur Urol* 2012; **62**: 472-487 [PMID: 22633803 DOI: 10.1016/j.eururo.2012.04.056]

10 **Thompson IM**, Tangen CM, Paradelo J, Lucia MS, Miller G, Troyer D, Messing E, Forman J, Chin J, Swanson G, Canby-Hagino E, Crawford ED. Adjuvant radiotherapy for pathologically advanced prostate cancer: a randomized clinical trial. *JAMA* 2006; **296**: 2329-2335 [PMID: 17105795 DOI: 10.1001/jama.296.19.2329]

11 **Wiegel T**, Bottke D, Steiner U, Siegmann A, Golz R, Störkel S, Willich N, Semjonow A, Souchon R, Stöckle M, Rübe C, Weissbach L, Althaus P, Rebmann U, Kälble T, Feldmann HJ, Wirth M, Hinke A, Hinkelbein W, Miller K. Phase III postoperative adjuvant radiotherapy after radical prostatectomy compared with radical prostatectomy alone in pT3 prostate cancer with postoperative undetectable prostate-specific antigen: ARO 96-02/AUO AP 09/95. *J Clin Oncol* 2009; **27**: 2924-2930 [PMID: 19433689 DOI: 10.1200/JCO.2008.18.9563]

12 **Gandaglia G**, Karakiewicz PI, Briganti A, Trudeau V, Trinh QD, Kim SP, Montorsi F, Nguyen PL, Abdollah F, Sun M. Early radiotherapy after radical prostatectomy improves cancer-specific survival only in patients with highly aggressive prostate cancer: validation of recently released criteria. *Int J Urol* 2015; **22**: 89-95 [PMID: 25141965 DOI: 10.1111/iju.12605]

13 **Wadasaki K**, Kaneyasu Y, Kenjo M, Matsuura K, Murakami Y, Hashimoto Y, Ito K, Kiriu H, Ito A. Treatment results of adjuvant radiotherapy and salvage radiotherapy after radical prostatectomy for prostate cancer. *Int J Clin Oncol* 2007; **12**: 37-41 [PMID: 17380439 DOI: 10.1007/s10147-006-0622-1]

14 **Taylor N**, Kelly JF, Kuban DA, Babaian RJ, Pisters LL, Pollack A. Adjuvant and salvage radiotherapy after radical prostatectomy for prostate cancer. *Int J Radiat Oncol Biol Phys* 2003; **56**: 755-763 [PMID: 12788182 DOI: 10.1016/S0360-3016(03)00069-5]

15 **Catton C**, Gospodarowicz M, Warde P, Panzarella T, Catton P, McLean M, Milosevic M. Adjuvant and salvage radiation therapy after radical prostatectomy for adenocarcinoma of the prostate. *Radiother Oncol* 2001; **59**: 51-60 [PMID: 11295206 DOI: 10.1016/S0167-8140(01)00302-4]

16 **Morris MM**, Dallow KC, Zietman AL, Park J, Althausen A, Heney NM, Shipley WU. Adjuvant and salvage irradiation following radical prostatectomy for prostate cancer. *Int J Radiat Oncol Biol Phys* 1997; **38**: 731-736 [PMID: 9240639 DOI: 10.1016/S0360-3016(97)00080-1]

17 **Ost P**, De Troyer B, Fonteyne V, Oosterlinck W, De Meerleer G. A matched control analysis of adjuvant and salvage high-dose postoperative intensity-modulated radiotherapy for prostate cancer. *Int J Radiat Oncol Biol Phys* 2011; **80**: 1316-1322 [PMID: 20675081 DOI: 10.1016/j.ijrobp.2010.04.039]

18 **Trabulsi EJ**, Valicenti RK, Hanlon AL, Pisansky TM, Sandler HM, Kuban DA, Catton CN, Michalski JM, Zelefsky MJ, Kupelian PA, Lin DW, Anscher MS, Slawin KM, Roehrborn CG, Forman JD, Liauw SL, Kestin LL, DeWeese TL, Scardino PT, Stephenson AJ, Pollack A. A multi-institutional matched-control analysis of adjuvant and salvage postoperative radiation therapy for pT3-4N0 prostate cancer. *Urology* 2008; **72**: 1298-1302; discussion 1302-1304 [PMID: 18672274 DOI: 10.1016/j.urology.2008.05.057]

19 **Roach M**, Hanks G, Thames H, Schellhammer P, Shipley WU, Sokol GH, Sandler H. Defining biochemical failure following radiotherapy with or without hormonal therapy in men with clinically localized prostate cancer: recommendations of the RTOG-ASTRO Phoenix Consensus Conference. *Int J Radiat Oncol Biol Phys* 2006; **65**: 965-974 [PMID: 16798415 DOI: 10.1016/j.ijrobp.2006.04.029]

20 **Pearse M**, Fraser-Browne C, Davis ID, Duchesne GM, Fisher R, Frydenberg M, Haworth A, Jose C, Joseph DJ, Lim TS, Matthews J, Millar J, Sidhom M, Spry NA, Tang CI, Turner S, Williams SG, Wiltshire K, Woo HH, Kneebone A. A Phase III trial to investigate the timing of radiotherapy for prostate cancer with high-risk features: background and rationale of the Radiotherapy -- Adjuvant Versus Early Salvage (RAVES) trial. *BJU Int* 2014; **113** Suppl 2: 7-12 [PMID: 24894850 DOI: 10.1111/bju.12623]

21 **Richaud P**, Sargos P, Henriques de Figueiredo B, Latorzeff I, Mongiat-Artus P, Houédé N, Salomon L, Wallerand H. [Postoperative radiotherapy of prostate cancer]. *Cancer Radiother* 2010; **14**: 500-503 [PMID: 20810300 DOI: 10.1016/j.canrad.2010.07.224]

22 **Parker C**, Sydes MR, Catton C, Kynaston H, Logue J, Murphy C, Morgan RC, Mellon K, Morash C, Parulekar W, Parmar MK, Payne H, Savage C, Stansfeld J, Clarke NW. Radiotherapy and androgen deprivation in combination after local surgery (RADICALS): a new Medical Research Council/National Cancer Institute of Canada phase III trial of adjuvant treatment after radical prostatectomy. *BJU Int* 2007; **99**: 1376-1379 [PMID: 17428247 DOI: 10.1111/j.1464-410X.2007.06844.x]

23 **Chen C**, Lin T, Zhou Y, Li D, Xu K, Li Z, Fan X, Zhong G, He W, Chen X, He X, Huang J. Adjuvant and salvage radiotherapy after prostatectomy: a systematic review and meta-analysis. *PLoS One* 2014; **9**: e104918 [PMID: 25121769 DOI: 10.1371/journal.pone.0104918]

24 **Blackwell RH**, Kandabarow AM, Gupta GN, Harkenrider MM, Quek ML, Flanigan RC. Long-term incidence of hematuria, urethral stricture and bladder cancer after radiation therapy for prostate cancer. *Urology Practice* 2015; **2**: 349-358 [DOI: 10.1016/j.urpr.2015.01.001]

25 **Albert M**, Tempany CM, Schultz D, Chen MH, Cormack RA, Kumar S, Hurwitz MD, Beard C, Tuncali K, O'Leary M, Topulos GP, Valentine K, Lopes L, Kanan A, Kacher D, Rosato J, Kooy H, Jolesz F, Carr-Locke DL, Richie JP, D'Amico AV. Late genitourinary and gastrointestinal toxicity after magnetic resonance image-guided prostate brachytherapy with or without neoadjuvant external beam radiation therapy. *Cancer* 2003; **98**: 949-954 [PMID: 12942561 DOI: 10.1002/cncr.11595]

26 **Crook J**, Esche B, Futter N. Effect of pelvic radiotherapy for prostate cancer on bowel, bladder, and sexual function: the patient's perspective. *Urology* 1996; **47**: 387-394 [PMID: 8633407 DOI: 10.1016/S0090-4295(99)80458-0]

27 **Nguyen LN**, Pollack A, Zagars GK. Late effects after radiotherapy for prostate cancer in a randomized dose-response study: results of a self-assessment questionnaire. *Urology* 1998; **51**: 991-997 [PMID: 9609638 DOI: 10.1016/S0090-4295(98)00028-4]

28 **Hunter GK**, Reddy CA, Klein EA, Kupelian P, Angermeier K, Ulchaker J, Chehade N, Altman A, Ciezki JP. Long-term (10-year) gastrointestinal and genitourinary toxicity after treatment with external beam radiotherapy, radical prostatectomy, or brachytherapy for prostate cancer. *Prostate Cancer* 2012; **2012**: 853487 [PMID: 22577562 DOI: 10.1155/2012/853487]

29 **Feng M**, Hanlon AL, Pisansky TM, Kuban D, Catton CN, Michalski JM, Zelefsky MJ, Kupelian PA, Pollack A, Kestin LL, Valicenti RK, DeWeese TL, Sandler HM. Predictive factors for late genitourinary and gastrointestinal toxicity in patients with prostate cancer treated with adjuvant or salvage radiotherapy. *Int J Radiat Oncol Biol Phys* 2007; **68**: 1417-1423 [PMID: 17418972 DOI: 10.1016/j.ijrobp.2007.01.049]

30 **Elliott SP**, Meng MV, Elkin EP, McAninch JW, Duchane J, Carroll PR. Incidence of urethral stricture after primary treatment for prostate cancer: data From CaPSURE. *J Urol* 2007; **178**: 529-534; discussion 534 [PMID: 17570425 DOI: 10.1016/j.juro.2007.03.126]

P- Reviewer: Gofrit ON, Vlachostergios PJ **S- Editor**: Qiu S
L- Editor: A **E- Editor**: Li D

World Journal of Clinical Urology

Submit a Manuscript: http://www.wjgnet.com/esps/
Help Desk: http://www.wjgnet.com/esps/helpdesk.aspx
DOI: 10.5410/wjcu.v5.i1.53

World J Clin Urol 2016 March 24; 5(1): 53-59
ISSN 2219-2816 (online)
© 2016 Baishideng Publishing Group Inc. All rights reserved.

ORIGINAL ARTICLE

Retrospective Study

Perioperative outcomes and survival of radical cystectomy as a function of body mass index

Bethany K Burge, Robert H Blackwell, Andrew Wilson, Robert C Flanigan, Gopal N Gupta, Marcus L Quek

Bethany K Burge, Robert H Blackwell, Robert C Flanigan, Gopal N Gupta, Marcus L Quek, Department of Urology, Loyola University Medical Center, Maywood, IL 60153, United States

Andrew Wilson, Stritch School of Medicine, Loyola University, Maywood, IL 60153, United States

Author contributions: Burge BK conceived of the study, carried out data acquisition and analysis, and helped to draft the final manuscript; Blackwell RH performed statistical analysis and helped to draft the final manuscript; Wilson A participated in data acquisition and initial drafting of the manuscript; Flanigan RC, Gupta GN, and Quek ML helped with data acquisition and carried out critical revision of the manuscript; all authors read and approved the final manuscript.

Institutional review board statement: This study was reviewed and approved by the Loyola University Medical Center Institutional Review Board.

Informed consent statement: This is a retrospective study of a chart review nature and is therefore exempt from informed consent.

Conflict-of-interest statement: The authors have no conflicts of interest to report.

Data sharing statement: Technical appendix, statistical code, and dataset available from the corresponding author at Bethany.burge@luhs.org. This study was exempt from informed consent given its retrospective, chart review nature. The presented data are anonymized and risk of identification if low.

Open-Access: This article is an open-access article which was selected by an in-house editor and fully peer-reviewed by external reviewers. It is distributed in accordance with the Creative Commons Attribution Non Commercial (CC BY-NC 4.0) license, which permits others to distribute, remix, adapt, build upon this work non-commercially, and license their derivative works on different terms, provided the original work is properly cited and the use is non-commercial. See: http://creativecommons.org/licenses/by-nc/4.0/

Correspondence to: Bethany K Burge, MD, Department of Urology, Loyola University Medical Center, 2160 S. First Avenue, Fahey Center, Room 261, Maywood, IL 60153, United States. bethany.burge@luhs.org
Telephone: +1-217-7415054
Fax: +1-708-2161699

Received: August 29, 2015
Peer-review started: August 31, 2015
First decision: October 8, 2015
Revised: October 30, 2015
Accepted: February 14, 2016
Article in press: February 16, 2016
Published online: March 24, 2016

Abstract

AIM: To evaluate the perioperative and long term outcomes of cystectomy in obese patients.

METHODS: This is a retrospective review of 580 patients for whom radical cystectomy (RC) was performed for primary urothelial bladder cancer between November 1996-April 2013 at a single institution. Body mass index (BMI) was available for 424 patients who were categorized as underweight (< 18.5), normal (18.5-24.9), overweight (25.0-29.9), and obese (≥ 30). Baseline demographics, perioperative outcomes, and survival were assessed. Overall survival (OS) and disease specific survival (DSS) was estimated by Kaplan-Meier method. Medians were compared using the Mann-Whitney U Test. Categorical variables were compared using the χ^2 test. A *P*-value of < 0.05 was considered statistically significant. Statistical analyses were performed using the Software Package for the Social Sciences (SPSS), Version 20 (International Business Machines SPSS, Chicago, IL, United States).

RESULTS: The median age of all patients was 69 years (inter-quartile range 60-75) and median follow-up was 23.4 mo (8.7-55.1). Patients were characterized as underweight [9, (2.1%)], normal [113, (26.7%)],

overweight [160, (37.8%)], or obese [142, (33.5%)]. Estimated blood loss during RC was higher in the obese group (800 mL) as compared to the normal weight group (500 mL). However, need for transfusion (47.7% *vs* 52.1%), number of lymph nodes resected (32 *vs* 30), length of stay (9 d *vs* 8 d), and 30-d readmission (29.7% *vs* 25.2%) between obese and normal BMI patients were similar. Obese patients underwent ileal neobladder diversion in 42% of cases, compared to 24% of normal BMI patients (0.003). Normal BMI and obese patients had comparable urinary incontinence (21.4% *vs* 25.6%, P = 0.343), and need for intermittent catheterization (14.3% *vs* 5.2%, P = 0.685) at 2 years follow-up. Overall survival was better in obese compared to normal BMI patients on univariate analysis, with median survival of 67 mo *vs* 37 mo, respectively (P = 0.031). Disease specific survival in these populations followed the same Kaplan Meier curve, with the obese group having a significantly improved OS, P = 0.016. Underweight patients had a significantly worse prognosis, with a median overall survival of 19 mo (P = 0.018). Disease specific survival was significantly worse in the underweight group compared to the obese group, P = 0.007. On multivariate analysis underweight patients remained at increased risk for death (HR = 3.1, P = 0.006), as were older patients (HR = 1.6, P = 0.006), those with multiple nodal metastases (HR = 3.7, P = 0.007), and those who had received neoadjuvant chemotherapy (HR = 2.0, P = 0.015).

CONCLUSION: Perioperative outcomes and survival following RC in obese patients is comparable with non-obese patients. Underweight patients have the worst OS and DSS.

Key words: Urinary bladder neoplasms; Body mass index; Obesity; Cystectomy; Underweight

© The Author(s) 2016. Published by Baishideng Publishing Group Inc. All rights reserved.

Core tip: As obesity rates increase, more obese patients will require radical cystectomy for muscle invasive bladder cancer. Anecdotally, obesity increases the technical difficulty of an operation. Literature regarding outcomes of obese patients undergoing radical cystectomy is limited. This study shows obese patients do better than their non-obese counterparts in terms of perioperative outcomes and overall and disease specific survival. However, we found that underweight patients have a significantly decreased overall and disease specific survival compared with obese and patients.

Burge BK, Blackwell RH, Wilson A, Flanigan RC, Gupta GN, Quek ML. Perioperative outcomes and survival of radical cystectomy as a function of body mass index. *World J Clin Urol* 2016; 5(1): 53-59 Available from: URL: http://www.wjgnet.com/2219-2816/full/v5/i1/53.htm DOI: http://dx.doi.org/10.5410/wjcu.v5.i1.53

INTRODUCTION

The prevalence of obesity in the United States continues to rise on a yearly basis[1]. Defined as a body mass index (BMI) > 30, it is estimated that 27.2% of the American population in 2013 was obese, increased from 25.5% in 2008. The estimated population that is overweight, defined as a BMI of 25 to < 30, accounted for 35.5%, making greater than half of the population heavier than their ideal body weight[1]. These rates may be underestimated, as the National Center for Health Sciences estimated in 2009-2010 that obesity was present in 35.7% in adults and 16.9% in children[2].

Regardless of the discrepancies, it is clear that an ever growing percentage of our population is overweight or obese. It follows then that an increasing number of patients presenting for surgical management of invasive bladder cancer will be subject to this trend. Anecdotally, increasing body habitus negatively impacts technical ease of surgery. For example, in the general surgery literature, obesity has been correlated with longer operating times during cholecystectomy, mastectomy, and colectomy[3]. Similar findings were demonstrated by Maurer *et al*[4] in 2009 for radical cystectomy, with increased operative time in obese compared with non-obese patients.

The current literature regarding other surgical outcomes of radical cystectomy in obese patients is limited. Furthermore, to our knowledge, studies evaluating the impact of BMI on surgical outcomes do not differentiate underweight patients from the normal weight cohort. Herein we examine the impact of BMI on perioperative and long term outcomes of radical cystectomy.

MATERIALS AND METHODS

A retrospective chart review was performed for 580 patients who underwent radical cystectomy at a single institution for urothelial cell carcinoma of the bladder between November 1996 and April 2013. Baseline patient demographics, comorbidities, and clinical cancer characteristics were recorded (Table 1). Surgical technique (open *vs* robotic-assisted laparoscopic) was chosen at the discretion of the primary surgeon (557 *vs* 23, respectively). BMI was calculated from height and weight data recorded prior to cystectomy (kg/m^2). BMI information was available for 424 patients, who were used in the final analysis. Patients were categorized into underweight (BMI < 18.5), normal weight (BMI 18.5-24.9), overweight (BMI 25-29.9), and obese (BMI ≥ 30) using World Health Organization BMI criteria[5].

BMI subgroups were evaluated for perioperative, pathologic, and long term outcomes including estimated blood loss, need for blood product transfusion, number of lymph nodes resected, admission length of stay, 30-d readmission rate, rate of continent diversions (ileal neobladder or continent catheterizable stoma), rate of node positive disease, and overall and disease specific survival (months). Follow-up was computed from the

Table 1 Preoperative patient characteristics

		Normal Weight (BMI 18.5-24.9)	Underweight (BMI < 18.5)	Overweight (BMI 25.0-29.9)	Obese (BMI > 30)	*P* value
Age at surgery (median, IQR), yr		70 (63-76)	78 (68-79)	70 (61-76)	67 (58-72)	0.126
Gender	Male	74 (66%)	4 (44%)	130 (81%)	106 (75%)	0.005
	Female	39 (35%)	5 (56%)	30 (19%)	36 (25%)	
Clinical tumor stage	cT0	1 (1%)	0 (0%)	1 (1%)	1 (1%)	0.05
	cTis	0 (0%)	0 (0%)	8 (5%)	11 (8%)	
	cTa	7 (7%)	1 (11%)	9 (6%)	10 (8%)	
	cT1	30 (28%)	2 (22%)	26 (17%)	35 (26%)	
	cT2	65 (61%)	4 (44%)	103 (67%)	67 (50%)	
	cT3	3 (3%)	2 (22%)	4 (3%)	5 (4%)	
	cT4	1 (1%)	0 (0%)	3 (2%)	4 (3%)	
Prior intravesical therapy	No	86 (78%)	6 (67%)	113 (71%)	83 (59%)	0.018
	Yes	25 (22%)	3 (33%)	47 (29%)	57 (41%)	
Prior neoadjuvant chemotherapy	No	100 (90%)	9 (100%)	150 (94%)	129 (92%)	0.478
	Yes	11 (10%)	0 (0%)	9 (6%)	11 (8%)	
Race	Caucasian	105 (92%)	9 (100%)	151 (94%)	134 (94%)	0.492
	Hispanic	3 (3%)	0 (0%)	0 (0%)	0 (0%)	
	Black	3 (3%)	0 (0%)	6 (4%)	7 (5%)	
	Asian	1 (1%)	0 (0%)	2 (1%)	0 (0%)	
	Unknown	1 (1%)	0 (0%)	1 (1%)	1 (1%)	
Hypertension	No	52 (46%)	2 (22%)	73 (46%)	33 (23%)	< 0.001
	Yes	60 (54%)	7 (78%)	87 (54%)	108 (77%)	
Diabetes mellitus, type Ⅱ	No	99 (88%)	8 (89%)	132 (82%)	100 (71%)	0.006
	Yes	13 (12%)	1 (11%)	28 (18%)	40 (29%)	
Coronary artery disease	No	89 (80%)	9 (100%)	125 (78%)	103 (74%)	0.248
	Yes	23 (20%)	0 (0%)	35 (22%)	37 (26%)	
Cardiac arrhythmia	No	102 (91%)	7 (78%)	143 (89%)	129 (92%)	0.491
	Yes	10 (9%)	2 (22%)	17 (11%)	11 (8%)	
History of coronary vascular accident	No	106 (95%)	8 (89%)	156 (97%)	139 (99%)	0.068
	Yes	6 (5%)	1 (11%)	4 (3%)	1 (1%)	
Pulmonary disease	No	94 (84%)	7 (78%)	147 (92%)	115 (82%)	0.063
	Yes	18 (16%)	2 (22%)	13 (8%)	25 (18%)	
Liver disease	No	110 (98%)	8 (89%)	159 (99%)	138 (99%)	0.077
	Yes	2 (2%)	1 (11%)	1 (1%)	1 (1%)	
Nephrolithiasis	No	101 (91%)	9 (100%)	149 (93%)	126 (90%)	0.606
	Yes	10 (9%)	0 (0%)	11 (7%)	14 (10%)	
Preoperative renal function	Normal	58 (72%)	7 (88%)	79 (70%)	70 (71%)	0.652
	CKD stage 3	19 (24%)	1 (12%)	31 (28%)	26 (27%)	
	CKD stage 4	2 (2%)	0 (0%)	2 (2%)	2 (2%)	
	CKD stage 5	2 (2%)	0 (0%)	0 (0%)	0 (0%)	
Smoking history	No	27 (24%)	1 (11%)	42 (27%)	36 (26%)	0.76
	Yes	84 (76%)	8 (89%)	116 (73%)	103 (74%)	

BMI: Body mass index; CKD: Chronic kidney disease; IQR: Inter-quartile range.

date of surgery to last clinic appointment with urologic or medical oncologist. Dates of death were confirmed by the Social Security Death Index[6].

Overall and disease specific survival was estimated by Kaplan-Meier method. Medians were compared using the Mann-Whitney U Test and categorical variables were compared using the χ^2 test. A *P*-value of < 0.05 was considered statistically significant. Statistical analyses were performed using the Software Package for the Social Sciences (SPSS), Version 20 (International Business Machines SPSS, Chicago, IL USA).

RESULTS

Perioperative and pathologic characteristics are demonstrated in Table 2. Of the 424 patients who underwent radical cystectomy for urothelial carcinoma and for whom BMI data was available, the median age was 69 years (range 60-75 years). There was a median follow-up of 23.4 mo (8.7-55.1). Of these 424 patients, there were 9 (2.1%) underweight, 113 (26.7%) normal BMI, 160 (37.8%) overweight, and 142 (33.5%) obese.

The median estimated blood loss was higher in the obese patients compared with the normal BMI group (500 mL and 800 mL, respectively). The median number of lymph nodes resected was comparable between the normal BMI and obese, at 30 and 32, respectively. The need for transfusion (52.1% and 47.7%), admission length of stay [8 d (7-10) and 9 d (7-14)], and 30 d readmissions (25.2% and 29.7%) also showed no significant differences.

Rates of orthotopic ileal neobladder urinary diversion were higher in obese patients than in normal weight and obese patients (41.5% *vs* 23.9%, respectively, *P* = 0.003). At 2 years follow-up, there was no statistical differences in rates of urinary incontinence (21.4% *vs*

Table 2 Postoperative patient characteristics

		Normal weight (BMI 18.5-24.9)	Underweight (BMI < 18.5)	Overweight (BMI 25.0-29.9)	Obese (BMI > 30)	*P* value
Length of stay (median, IQR), d		8 (7-10)	13 (10-16)	8 (7-11)	9 (7-14)	0.054
Prolonged length of stay (> 7 d)	No	39 (35%)	0 (0%)	61 (38%)	49 (35%)	0.137
	Yes	73 (65%)	9 (100%)	99 (62%)	93 (65%)	
Estimated blood loss (median, IQR), mL		500 (400-700)	600 (450-925)	700 (500-1000)	800 (600-1100)	< 0.001
Urinary diversion	Ileal conduit	70 (61.9%)	8 (88.9%)	88 (55%)	68 (47.9%)	0.160
	Orthotopic ileal neobladder	27 (23.9%)	1 (11.1%)	58 (26.2%)	59 (41.5%)	
	Continent cutaneous diversion	14 (12.3%)	0 (0%)	12 (7.4%)	11 (7.7%)	
	Cutaneous ureterostomy	0 (0%)	0 (0%)	1 (0.6%)	0 (0%)	
	None	4 (3.5%)	0 (0%)	2 (1.2%)	1 (0.7%)	
Pathologic tumor/nodal stage	No evidence of disease (pT0)	8 (7%)	0 (0%)	2 (1%)	9 (6%)	0.01
	Localized disease (pT0-2bN0)	45 (40%)	2 (22%)	73 (46%)	76 (53%)	
	Locally advanced disease (pT3-4bN0)	25 (22%)	6 (67%)	49 (30%)	33 (23%)	
	Solitary nodal metastasis (pT × N1)	12 (11%)	0 (0%)	14 (9%)	12 (9%)	
	Multiple nodal metastases (pT × N2-3)	23 (20%)	1 (11%)	22 (14%)	12 (9%)	
Readmission within 30 d	No	83 (75%)	6 (67%)	113 (71%)	97 (70%)	0.85
	Yes	28 (25%)	3 (33%)	46 (29%)	41 (30%)	
Adjuvant chemotherapy	No	74 (67%)	7 (78%)	105 (66%)	93 (67%)	0.907
	Yes	36 (33%)	2 (22%)	54 (34%)	45 (33%)	
Recurrence of disease	No	81 (72%)	5 (56%)	113 (71%)	97 (69%)	0.031
	Yes	31 (28%)	4 (44%)	47 (29%)	44 (31%)	
Deceased	No	59 (52%)	2 (22%)	95 (59%)	91 (64%)	0.727
	Yes	54 (48%)	7 (78%)	65 (41%)	50 (36%)	

BMI: Body mass index; IQR: Inter-quartile range.

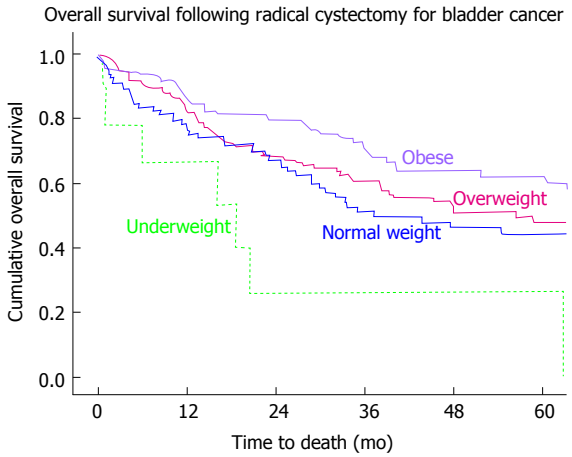

Number at risk						
Normal weight BMI 18.5-24.9	113	74	56	34	26	18
Underweight BMI ≤ 18.5	9	5	3	1	1	1
Overweight BMI 25-29.9	158	113	79	60	45	31
Obese BMI ≥ 30	139	102	78	58	38	35

Figure 1 Improved overall survival in obese patients compared with normal body mass index patients. BMI: Body mass index.

25.6%, P = 0.343) or need for intermittent catheterization (14.3% *vs* 5.2%, P = 0.685) between normal BMI and obese patients with an ileal neobladder urinary diversion.

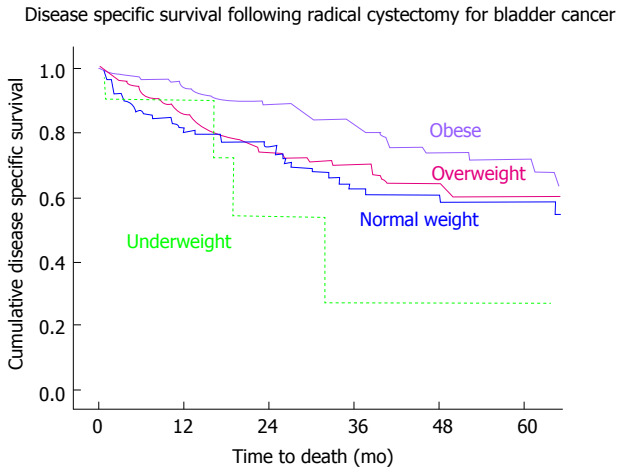

Figure 2 Decreased disease specific survival of patients in the underweight group compared with other weight groups.

While overall survival was improved in obese patients when compared with normal BMI patients [median survival of 67 mo (57-77) and 37 mo (16-58), respectively], it was significantly decreased in the underweight population with a median survival of 19 mo (2-35), P < 0.001 (Figure 1). A similar trend was seen in disease specific survival, with patients in the underweight group having a decreased DSS when compared with other weight groups. DSS in the underweight group, when compared to the obese group was significantly lower, P = 0.007 (Figure 2, Table 3).

On multivariate analysis (Table 4) underweight patients had an increased risk of death (HR = 3.129, P = 0.006) compared to normal BMI patients, as did older

Table 3 Pairwise comparison of disease specific survival according to body mass index

	BMI	0		1		2		3	
		χ^2	Sig.	χ^2	Sig.	χ^2	Sig.	χ^2	Sig.
Log rank (Mantel-cox)	0			1.204	0.272	2.144	0.143	7.160	0.007
	1	1.204	0.272			0.961	0.327	5.838	0.016[2]
	2	2.144	0.143	0.961	0.327			2.189	0.139
	3	7.160	0.007[1]	5.838	0.016	2.189	0.139		

[1]DSS for underweight *vs* obese: 0.007. [2]DSS for obese *vs* normal: 0.016. BMI: Body mass index; DSS: Disease specific survival; 0: Underweight; 1: Normal; 2: Overweight; 3: Obese.

Table 4 Cox stepwise multivariate regression

		HR (95%CI)	*P* value
Age at surgery ≥ 65 yr		1.62 (1.15-2.29)	0.006
Gender			0.330
BMI	Normal weight (BMI 18.5-24.9)	Referent	0.015
	Underweight (BMI ≤ 18.5)	3.13 (1.39-7.07)	0.006
	Overweight (BMI 25.0-29.9)	0.94 (0.64-1.38)	0.764
	Obese (BMI ≥ 30)	0.83 (0.56-1.24)	0.370
Coronary artery disease			0.808
Cardiac arrhythmia			0.722
Pulmonary disease			0.192
Hypertension			0.110
Diabetes mellitus, type Ⅱ			0.217
Smoking history			0.657
Intravesical therapy			0.560
Neoadjuvant chemotherapy		2.02 (1.14-3.56)	0.015
Adjuvant chemotherapy			0.251
Pathologic stage	pT0	Referent	< 0.001
	pT1-2N0	0.78 (0.30-1.99)	0.602
	pT3-4N0	1.47 (0.56-3.80)	0.430
	pT × N1	2.48 (0.91-6.77)	0.076
	pT × N2-3	3.73 (1.43-9.74)	0.007

BMI: Body mass index.

patients (age ≥ 65 years) (HR = 1.622, P = 0.006), patients with > 1 nodal metastasis (HR = 3.730, P = 0.007), and patients who had received neoadjuvant chemotherapy (HR = 2.017, P = 0.015).

DISCUSSION

Radical cystectomy appears to be safe in the obese population, with perioperative and overall survival outcomes comparable to the normal BMI population. We find no clinically or statistically significant differences in rate of blood product transfusion, length of hospital stay, or 30-d readmission. This echoes a NSQIP population-based comparison between these groups, which demonstrated no increase in 30-d mortality or in perioperative complications[7]. Other prior studies have demonstrated an increase in operative time in the obese[4,7].

Further, 59 (42%) obese patients in our series received orthotopic ileal neobladder urinary diversion. While there is a theoretical concern for increased urinary incontinence given the increased intra-abdominal pressure, this was not demonstrated (26.7% *vs* 26.3%, obese *vs* normal BMI). Compared to normal BMI patients with orthotopic neobladder, obese patients had a trend toward a lower rate of intermittent catheterization (2% *vs* 11%, P = NS). Given that orthotopic neobladder patients have been shown to have improved physical functioning[8] without the same body image concerns present in patients with ileal conduits[9], orthotopic neobladder stands out as an appropriate option in the obese population.

An unexpected finding was the significant decrease in overall and disease specific survival in the underweight group. We hypothesize that this tendency toward a worse outcome is the result of a systemic manifestation of cancer-related nutritional deficiency and sarcopenia, resulting in a lower physiologic reserve in the underweight patients. This group did notably have a high proportion of pT3-4N0 disease compared to patients in other BMI distributions, however less incidence of nodal involvement. On multivariate analysis underweight patients had an increased risk of death compared to normal BMI patients (HR = 3.1, P = 0.006). As such, underweight BMI may serve as a surrogate marker for poor outcome following radical cystectomy.

Radical cystectomy patients are known to be nutritionally deficient. Jensen *et al*[8] reported that 26% of

patients are at a preoperative nutritional risk prior to cystectomy. Further, Gregg *et al*[9] demonstrated that in 538 patients, 19% were nutritionally deficient (defined as BMI < 18.5, albumin < 3.5, pre-surgical weight loss > 5% of body weight). The 90-d mortality in this population was 16.5%, and their 3-year overall survival was decreased compared to nutritionally normal patients (44% *vs* 68%, respectively)[10].

Radical cystectomy patients are also at increased risk for nutritional deficiency postoperatively. Following surgery these patients are in a catabolic state secondary to the stress response to surgery and wound healing. They may develop ileus and also suffer a loss of lymphatic fluid intra- and post-operatively that can contribute further to their nutritional deficiency[11]. In a case series reported by Mathur *et al*[12], it was demonstrated that there are significant decreases in mean protein levels and water in the first 2 wk following cystectomy. What is most striking is that it required greater than 6 mo to regain 67% of the protein lost following surgery. In a prospective, randomized trial, Roth *et al*[10] demonstrated that while patients who received parenteral nutrition had earlier improvements in serum prealbumin (mg/L) and total protein (g/L), there was no improvement in time to gastrointestinal recovery or length of stay. Furthermore, there were increased postoperative infectious complications in this group.

All of the above data suggest that preoperatively underweight and nutritionally deficient patients are at a disadvantage following radical cystectomy. A recent review of the colorectal surgery literature found that the use of preoperative nutritional supplements improved time to return of gastrointestinal function, and decreased time to discharge and postoperative muscle mass loss. It follows that preoperative nutritional intervention may lead to improved outcomes. More will be known in the radical cystectomy population following the results of a pilot study that is currently in enrollment to assess the impact of an enriched oral nutritional shake to improve preoperative nutritional status on patient's outcomes following radical cystectomy.

Limitations of our study include retrospective design with its inherent bias, as well as small sample size, particularly in the underweight patient group.

While obesity may increase the technical difficulty of surgical management of invasive bladder cancer, perioperative outcomes and survival following radical cystectomy appear better than non-obese patients. Obese patients with orthotopic neobladders have comparable urinary function to patients with a normal BMI, making continent diversion a reasonable option in this population. A paradigm shift may be warranted to incorporate preoperative nutritional assessment and supplementation, particularly in underwent patients, to improve radical cystectomy outcomes. Prospective studies evaluating the effect of nutritional supplementation or hyperalimentation prior to radical cystectomy are necessary to determine how to best improve the nutritional status and outcomes in this nutritionally compromised population.

ACKNOWLEDGMENTS

Stephanie Kliethermes, PhD, biostatistical analysis, for assistance with statistical analysis.

COMMENTS

Background

Radical cystectomy is the gold standard for treatment of muscle invasive bladder cancer. As obesity rates in the Unites States increase, so will the rates of obese patients that require radical cystectomy. Currently, literature in other surgical fields note increased operating times in the obese population. However, these studies did not evaluate how these patients tolerated the surgery and how well they did postoperatively. In this study the authors evaluated perioperative outcomes and survival, both overall and disease specific, of patients undergoing radical cystectomy according to their body mass index (BMI). The authors' hypothesis was that obese patients would have more technically difficult operations leading to increased need for transfusion, less complete oncologic outcomes (specifically evaluated by number of lymph nodes resected), longer hospital stay, and increased 30-d readmissions. However, no significant difference was found between obese and normal weight patient groups with regards to these perioperative factors. An unexpected finding was underweight patients had a significantly decreased overall and disease specific survival when compared with other weight groups.

Research frontiers

Given the high complication rate of radical cystectomy of up to 30% in the literature, increased hospital length of stay, and high rate of readmission there is a need for information on preoperative optimization for these patients. The finding that underweight patients have a decreased survival could point to the fact that they are nutritionally deficient prior to surgery. Further studies are necessary to determine if, and by what method, preoperative nutritional supplementation would benefit this patient group.

Innovations and breakthroughs

This study provides information on perioperative factors and survival. Other studies that have looked at BMI and its relation to surgical outcomes have focused on the technical aspects of the surgery alone. Those that have evaluated perioperative outcomes and survival as a function of BMI did not specifically evaluate how underweight patients fared, as this study does.

Applications

This study highlights the need for future prospective studies evaluating preoperative nutritional optimization for patients undergoing radical cystectomy.

Peer-review

This study is the first and most extensive study. The presented article is well written and can contribute to current data. The paper describes the relationship between preoperative BMI and long-term outcome. The results are very interesting, showing a substantially decreased overall survival in the underweight group. Separate analysis of cancer-specific survival would improve the manuscript.

REFERENCES

1 **Sharpe L**. U.S. Obesity Rate Climbing in 2013. Gallup Well-Being. [Updated 2013 Nov 1]. Available from: URL: http://www.Gallup.com/poll/165671/obesity-rate-climbing-2013.aspx

2 **Ogden CL**, Carroll MD, Kit BK, Flegal KM. Prevalence of obesity in the United States, 2009-2010. *NCHS Data Brief* 2012; **82**: 1-8 [PMID: 22617494]

3 **Hawn MT**, Bian J, Leeth RR, Ritchie G, Allen N, Bland KI, Vickers SM. Impact of obesity on resource utilization for general surgical

procedures. *Ann Surg* 2005; **241**: 821-826; discussion 826-828 [PMID: 15849518 DOI: 10.1097/01.sla.0000161044.20857.24]

4 **Maurer T**, Maurer J, Retz M, Paul R, Zantl N, Gschwend JE, Treiber U. Influence of body mass index on operability, morbidity and disease outcome following radical cystectomy. *Urol Int* 2009; **82**: 432-439 [PMID: 19506411 DOI: 10.1159/000218533]

5 WHO Global Database on Body Mass Index. Available from: URL: http://apps.who.int/bmi/

6 Social Security Death Index. Available from: URL: http://go.fold3.com/ssdi/

7 **Butt ZM**, Fazili A, Tan W, Wilding GE, Filadora V, Kim HL, Mohler JL, O'Leary KA, Guru KA. Does the presence of significant risk factors affect perioperative outcomes after robot-assisted radical cystectomy? *BJU Int* 2009; **104**: 986-990 [PMID: 19549262 DOI: 10.1111/j.1464-410X.2009.08539.x]

8 **Jensen BT**, Laustsen S, Petersen AK, Borre M, Soendergaard I, Ernst-Jensen KM, Lash TL, Borre M. Preoperative risk factors related to bladder cancer rehabilitation: a registry study. *Eur J Clin Nutr* 2013; **67**: 917-921 [PMID: 23839668 DOI: 10.1038/ejcn.2013.120]

9 **Gregg JR**, Cookson MS, Phillips S, Salem S, Chang SS, Clark PE, Davis R, Stimson CJ, Aghazadeh M, Smith JA, Barocas DA. Effect of preoperative nutritional deficiency on mortality after radical cystectomy for bladder cancer. *J Urol* 2011; **185**: 90-96 [PMID: 21074802 DOI: 10.1016/j.juro.2010.09.021]

10 **Roth B**, Birkhäuser FD, Zehnder P, Thalmann GN, Huwyler M, Burkhard FC, Studer UE. Parenteral nutrition does not improve postoperative recovery from radical cystectomy: results of a prospective randomised trial. *Eur Urol* 2013; **63**: 475-482 [PMID: 22695241 DOI: 10.1016/j.eururo.2012.05.052]

11 **Jones C**, Badger SA, Hannon R. The role of carbohydrate drinks in pre-operative nutrition for elective colorectal surgery. *Ann R Coll Surg Engl* 2011; **93**: 504-507 [PMID: 22004631 DOI: 10.1308/147870811X13137608455136]

12 **Mathur S**, Plank LD, Hill AG, Rice MA, Hill GL. Changes in body composition, muscle function and energy expenditure after radical cystectomy. *BJU Int* 2008; **101**: 973-977; discussion 977 [PMID: 18005200 DOI: 10.1111/j.1464-410X.2007.07337.x]

P- Reviewer: Behzatoglu K, Sandblom G
S- Editor: Kong JX **L- Editor**: A **E- Editor**: Li D

World Journal of Clinical Urology

Submit a Manuscript: http://www.wjgnet.com/esps/
Help Desk: http://www.wjgnet.com/esps/helpdesk.aspx
DOI: 10.5410/wjcu.v5.i1.60

World J Clin Urol 2016 March 24; 5(1): 60-65
ISSN 2219-2816 (online)
© 2016 Baishideng Publishing Group Inc. All rights reserved.

ORIGINAL ARTICLE

Retrospective Study

Robotic-assisted laparoscopic partial nephrectomy: A comparison of approaches to the posterior renal mass

Jessica J Wetterlin, Robert H Blackwell, Sarah Capodice, Stephanie Kliethermes, Marcus L Quek, Gopal N Gupta

Jessica J Wetterlin, Robert H Blackwell, Marcus L Quek, Gopal N Gupta, Department of Urology, Loyola University Medical Center, Maywood, IL 60153, United States

Sarah Capodice, Stritch School of Medicine, Loyola University Medical Center, Maywood, IL 60153, United States

Stephanie Kliethermes, Department of Public Health, Loyola University Medical Center, Maywood, IL 60153, United States

Author contributions: Wetterlin JJ, Blackwell RH, Capodice S, Quek ML and Gupta GN performed the research; Wetterlin JJ, Blackwell RH, Capodice S and Gupta GN wrote the paper; Wetterlin JJ, Gupta GN designed the research study; Kliethermes S contributed analytic tools.

Institutional review board statement: Our project was performed with institutional IRB approval LU#280388 at Loyola University Medical Center.

Informed consent statement: Our study does not involve human subjects research so there was no need for informed consent.

Conflict-of-interest statement: We have no financial relationships to disclose.

Data sharing statement: No additional data are available.

Open-Access: This article is an open-access article which was selected by an in-house editor and fully peer-reviewed by external reviewers. It is distributed in accordance with the Creative Commons Attribution Non Commercial (CC BY-NC 4.0) license, which permits others to distribute, remix, adapt, build upon this work non-commercially, and license their derivative works on different terms, provided the original work is properly cited and the use is non-commercial. See: http://creativecommons.org/licenses/by-nc/4.0/

Correspondence to: Jessica J Wetterlin, MD, Department of Urology, Loyola University Medical Center, 2160 S. First Avenue, Fahey Center, Room 261, Maywood, IL 60153, United States. jwetterlin@lumc.edu
Telephone: +1-708-2165100
Fax: +1-708-2161699

Received: September 10, 2015
Peer-review started: September 10, 2015
First decision: October 27, 2015
Revised: February 10, 2016
Accepted: March 7, 2016
Article in press: March 9, 2016
Published online: March 24, 2016

Abstract

AIM: To evaluate outcomes of robotic-assisted laparoscopic partial nephrectomy performed for posterior renal tumors *via* a transperitoneal or retroperitoneal approach.

METHODS: Retrospective review was performed for patients who underwent robotic-assisted laparoscopic partial nephrectomy (RALPN) for a posterior renal tumor between 2009-2015. Patient demographic characteristics, operative factors, pathology, oncologic outcomes, renal function, and tumor complexity were obtained. Radius of the tumor, exophytic/endophytic properties of the tumor, nearness of tumor to the collecting system, anterior/posterior position, location relative to the polar line (RENAL) nephrometry scores were calculated. nephrometry scores were calculated. The operative approach was determined by the primary surgeon.

RESULTS: A total of 91 patients were identified who underwent RALPN for a posterior renal tumor. Fifty-four procedures were performed *via* the retroperitoneal (RP) approach, and 37 *via* the transperitoneal (TP) approach. There were no significant differences in patient factors (race, sex, age and body mass index), RENAL nephrometry scores, tumor size, conversion rates, or margin status. Among procedures performed on-clamp, there

was no significant difference in warm ischemia times. Total operative time (180.7 min for RP *vs* 227.8 min for TP, $P < 0.001$), robotic console time (126.9 min for RP *vs* 164.3 min for TP, $P < 0.001$), and median estimated blood loss (32.5 mL for RP *vs* 150 mL for TP, $P < 0.001$) were significantly lower *via* the RP approach. Off-clamp RALPN was performed for 31 (57.4%) of RP procedures *vs* 9 (24.3%) of TP procedures. Oncologic and renal functional outcomes were equivalent.

CONCLUSION: The RP approach to RALPN for posterior renal tumors is superior with regard to operative time and blood loss and the ability to be performed off-clamp.

Key words: Retroperitoneal; Transperitoneal; Robotic-assisted laparoscopic partial nephrectomy; Posterior renal masses

© The Author(s) 2016. Published by Baishideng Publishing Group Inc. All rights reserved.

Core tip: A retrospective review was completed to evaluate perioperative outcomes of robotic-assisted laparoscopic partial nephrectomy (RALPN) performed for posterior renal tumors performed *via* a transperitoneal or retroperitoneal (RP) approach. Ninety-one patients underwent RALPN for a posterior renal tumor. Fifty-four procedures were performed *via* the RP approach. Total operative time, robotic console time, and median estimated blood loss were significantly lower *via* the RP approach. Fifty-seven percent of RP procedures were performed off-clamp. The RP approach to RALPN for posterior renal tumors is superior with regard to operative time and blood loss and the ability to perform the procedure off-clamp.

Wetterlin JJ, Blackwell RH, Capodice S, Kliethermes S, Quek ML, Gupta GN. Robotic-assisted laparoscopic partial nephrectomy: A comparison of approaches to the posterior renal mass. *World J Clin Urol* 2016; 5(1): 60-65 Available from: URL: http://www.wjgnet.com/2219-2816/full/v5/i1/60.htm DOI: http://dx.doi.org/10.5410/wjcu.v5.i1.60

INTRODUCTION

Robotic-assisted laparoscopic partial nephrectomy (RALPN) is increasingly utilized as an alternative to laparoscopic or open partial nephrectomy for surgical extirpation of renal masses. RALPN can be performed *via* a transperitoneal (TP) or retroperitoneal (RP) approach, but the majority of the literature describes the TP approach as it has been more widely adopted and provides a larger working space with more familiar anatomical landmarks[1]. The RP approach, however, has specific advantages including direct access to posterior and lateral tumors without whole kidney mobilization, direct access to the renal artery, and does not require bowel mobilization[1,2]. Additionally, several recent studies have indicated that the RP approach for RALPN is associated with decreased operative time, decreased length of hospital stay, decreased estimated blood loss (EBL), decreased warm ischemia time (WIT), decreased narcotic use, and permitted quicker return of bowel function with comparable oncologic outcomes[1-11].

While the current literature suggests the RP approach to RALPN provides an acceptable alternative to the TP approach, there are no studies that compare these two methods for posteriorly located tumors. The current study evaluates the use of RALPN for posterior renal tumors *via* the TP and RP approaches in regards to perioperative, renal functional, and oncological outcomes.

MATERIALS AND METHODS

A retrospective review was performed in our prospectively-maintained RALPN institutional database to identify patients who underwent RALPN for a posteriorly-located renal tumor from September 2009 to January 2015. Tumor characteristics, including posterior location, were based on radius of the tumor, exophytic/endophytic properties of the tumor, nearness of tumor to the collecting system, anterior/posterior position, location relative to the polar line (RENAL) nephrometry scores. Information regarding patient demographic characteristics, operative factors, renal function, tumor histology, and oncological outcomes were obtained by chart review. Surgical approach was determined by the primary surgeon based on tumor location and characteristics.

Surgical technique

The RP approach to RALPN has been previously described, and our technique had little variation[12]. In brief, patients were instructed to hold anticoagulation and antiplatelet agents prior to surgery. No bowel preparation was administered. Patients were placed in a full flank position over a beanbag, secured and appropriately padded, with the table flexed. The flank and abdomen were prepped and bony landmarks identified. An incision was made at the level of the tip of the 12th rib, one centimeter superior to the anterior superior iliac spine. Blunt dissection was then used to enter the retroperitoneum. A balloon trocar was placed to dilate the RP space, after which pneumoretroperitoneum was established. Under direct visualization, two 8 mm robotic ports and a single 12 mm assistant port were placed. The robot was docked over the ipsilateral shoulder at a 15 degree angle towards the spine. Arterial vascular dissection was immediately performed by elevating the kidney off the psoas muscle to identify the renal hilum. For RALPN performed with WIT, only the artery was clamped with bulldog clamps. Intraoperative ultrasound was used to correctly identify the tumor, Gerota's fat overlying the tumor was removed and sent for pathological analysis, and the tumor was excised using sharp dissection. The decision to perform the procedure with or without clamping of the renal hilum was made by

the primary surgeon. Renorrhaphy and placement of hemostatic agents was performed as deemed necessary.

Alternatively, patients undergoing the TP approach were placed in a modified flank position with the table maximally flexed to provide optimal exposure. Insufflation was obtained with the Veress needle. Ports were placed in the supraumbilical area, lateral to the rectus sheath, one 8 mm port superior in the midline, and one inferiorly in the midclavicular line. A 12 mm assistant port was placed inferiorly, and a 5 mm assistant port superiorly. For right-sided procedures, an additional 5 mm assistant port was occasionally placed along the contralateral margin for liver retraction. The robot was docked over the ipsilateral shoulder, after which the kidney and renal hilum were identified in a standard fashion. During the TP approach, the kidney required complete mobilized to facilitate visualization of the posterior tumor.

Outcomes

The patient characteristics that were evaluated included age at time of procedure, gender, race, and body mass index (BMI). Operative factors examined included length of total procedure, robotic console time, conversion to open, EBL and WIT. Renal function was evaluated by comparing preoperative creatinine to postoperative creatinine; postoperative creatinine was measured at an average of 4.5 (1.7-15.3) mo after surgery. Postoperative creatinine levels were routinely measured on postoperative day one, and daily throughout patient's hospital stay. There was no standardization of postoperative creatinine measurement after patient discharge, and was performed on an individual basis. Tumor characteristics evaluated included RENAL nephrometry scores, tumor histology, size, laterality, and surgical margin status. Patients were followed postoperatively for radiographic evidence of tumor recurrence and or metastasis.

The RENAL nephrometry score is a scoring system to objectively describe anatomic characteristics of renal tumors including tumor radius, amount of tumor that is exophytic, nearness of deepest portion of the tumor to the collecting system or renal sinus, anterior or posterior location, and location relative to the polar line[13].

Statistical analysis

Standard statistical methods were used to describe characteristics of individuals in both groups. Continuous variables were primarily represented as means and standard deviations, whereas categorical variables were represented as frequencies and percentages. Univariable analyses were conducted to compare differences in patient characteristics, tumor characteristics and operative outcomes between the two groups. Independent *t*-tests were used for continuous variables and Pearson c^2 or Fisher's exact tests were used for categorical comparisons. Due to the non-normality of WIT and EBL, medians and interquartile ranges were presented and Wilcoxon rank sum tests used.

RESULTS

All procedures were performed by 5 surgeons at a single institution from September 2009 to January 2015. A total of 91 patients underwent RALPN for a posterior renal tumor. Fifty-four procedures were performed *via* the RP approach, and 37 *via* the TP approach. There were no significant differences in patient factors including race, sex, age, and BMI (Table 1). The only significant difference with regard to tumor characteristics was laterality of the tumor. A majority of patients with left-sided tumors underwent resection *via* the TP approach (59.5%), whereas a majority of patients with right-sided tumors were *via* the RP approach (63%, P = 0.04). There were no significant differences in tumor size or RENAL nephrometry scores, including individual components (Table 2).

Off-clamp RALPN was performed for 57.4% of RP procedures *vs* 24.3% of TP procedures. Among procedures performed on-clamp, there was no significant difference in warm ischemia times. There were no significant differences in conversion rates or surgical margin status between the two groups. One patient in the RP group had a positive surgical margin *vs* three in the TP group. Total operative time (180.7 min for RP *vs* 227.8 min for TP, $P < 0.001$), robotic console time (126.9 min for RP *vs* 164.3 min for TP, $P < 0.001$), and median EBL (32.5 mL for RP *vs* 150 mL for TP, $P < 0.001$) were significantly lower *via* the RP approach (Table 3). There was no significant difference in postoperative renal function between both groups, measured at an average of 4.5 (1.7-15.3) mo postoperatively (Table 4).

Patients in both groups were followed postoperatively for evidence of radiographic recurrence or metastasis. No patients in either group had evidence of disease recurrence or metastasis after median follow-up of 187 d for the TP group, 104 d for the RP group. Tumor histology was assessed in all patients that underwent RALPN, with the majority of patients in both groups being diagnosed with clear cell renal cell carcinoma (Figure 1).

DISCUSSION

Minimally invasive techniques and nephron sparing surgery for the management of renal masses are increasingly utilized and have comparable oncologic outcomes to the open approach. Partial nephrectomy remains the standard of care for small renal masses in appropriately selected patients according to current guidelines[14]. Minimally invasive techniques have demonstrated the added advantage of faster postoperative convalescence and shorter hospital stay[7]. In comparison to the TP approach, the RP approach has been less commonly used, even for posteriorly located tumors. This may be attributed to less operative familiarity, a smaller working space, and less familiarity with surgical landmarks[7]. Despite these obstacles, an increasing amount of data supports the use of the RP approach for RALPN. To our knowledge, no prior studies have examined the use of the

Table 1 Patient characteristics

	RP (n = 54)	TP (n = 37)	P
Age at time of surgery, mean (SD)	56.5 (13)	57.2 (11.6)	0.80[1]
BMI (SD)	31.1 (5.8)	32.1 (7.0)	0.51[1]
Race			
Asian	1 (1.9%)	0	0.45[2]
Black	3 (5.6%)	3 (8.1%)	
Hispanic	7 (13.0%)	2 (5.4%)	
Other	0	1 (2.7%)	
White	43 (79.6%)	31 (83.8%)	
Sex			
Female	17 (31.5%)	17 (46.0%)	0.16[3]
Male	37 (68.5%)	20 (54.1%)	
Preoperative creatinine, mean (SD)	0.95 (0.21) n = 53	0.90 (0.17) n = 36	0.27[1]

P = Significance based on: [1]Independent samples t-test; [2]Fisher exact test; [3]Pearson χ^2 test. RP: Retroperitoneal; TP: Transperitoneal; BMI: Body mass index; SD: Standard deviation.

Table 2 Tumor characteristics

	RP (n = 54)	TP (n = 37)	P
Renal location			
Left	20 (37.0%)	22 (59.5%)	0.04[3]
Right	34 (63.0%)	15 (40.5%)	
Pathologic tumor size (cm), mean (SD)	3.1 (1.6) n = 53	2.9 (1.2) n = 36	0.54[1]
Surgical margin			
Negative	50 (98.0%)	32 (91.4%)	0.30[2]
Positive	1 (2.0%)	3 (8.6%)	
RENAL score, mean (SD)	6.5 (1.9)	6.6 (1.8)	0.71[1]
Radius			
1	42 (77.8%)	33 (89.2%)	0.41[2]
2	10 (18.5%)	4 (10.8%)	
3	2 (3.7%)	0	
Exophytic			
1	29 (53.7%)	15 (40.5%)	0.41[2]
2	20 (37.0%)	19 (51.4%)	
3	5 (9.3%)	3 (8.1%)	
Nearness			
1	23 (42.6%)	15 (40.5%)	0.94[3]
2	8 (14.8%)	5 (13.5%)	
3	23 (42.6%)	17 (46.0%)	
Location relative to polar line			
1	30 (55.6%)	19 (51.4%)	0.51[3]
2	12 (22.2%)	6 (16.2%)	
3	12 (22.2%)	12 (32.4%)	

P = Significance based on: [1]Independent samples t-test; [2]Fisher exact test; [3]Pearson χ^2 test. RP: Retroperitoneal; TP: Transperitoneal; SD: Standard deviation; RENAL: Radius of the tumor, exophytic/endophytic properties of the tumor, nearness of tumor to the collecting system, anterior/posterior position, location relative to the polar line.

RP *vs* TP approach exclusively for posterior renal tumors.

RENAL nephrometry score has been widely used to objectively describe anatomic characteristics of renal tumors including tumor radius, amount of tumor that is exophytic, nearness of the tumor to the collecting system or renal sinus, anterior or posterior location, and location relative to the polar line[13]. Prior studies have evaluated the impact of RENAL nephrometry scores on outcomes of partial nephrectomy and have demonstrated that higher nephrometry scores were associated with more EBL, and longer hospital stay and warm ischemia times[10,13]. Ellison *et al*[10] found that the nearness of the tumor to the renal sinus had the greatest impact on perioperative outcomes. Hayn *et al*[13] found that nephrometry score did not impact overall operative times, transfusion rate, complication rate, or pre- and post-operative creatinine clearance. Similarly, our study demonstrated no significant difference in outcomes between RP *vs* TP approaches with regard to RENAL nephrometry score. In our study, the nephrometry score was only useful to classify the tumor as anterior or posterior.

In a study comparing perioperative outcomes of all

Table 3 Operative factors

	RP (n = 54)	TP (n = 37)	P
Total operative time (SD)	180.7 (62.3)	227.8 (59.0)	< 0.001[1]
Robot console time, mean (SD)	126.9 (40.0)	164.3 (51.3)	< 0.001[1]
WIT, median (IQR)[4]	28.0 (20-31) n = 23	27.0 (21-31) n = 28	0.96[3]
Conversion			
No	52 (96.3%)	32 (86.5%)	0.12[2]
Yes	2 (3.7%)	5 (13.5%)	
EBL, median (IQR)	32.5 (20-100)	150.0 (50-250)	< 0.001[3]

P = Significance based on: [1]Independent samples t-test; [2]Fisher exact test; [3]Wilcoxon-Rank Sum test; [4]Excludes patients with WIT = 0. RP: Retroperitoneal; TP: Transperitoneal; SD: Standard deviation; IQR: Interquartile range; WIT: Warm ischemia time; EBL: Estimated blood loss.

Table 4 Renal function

	RP (n = 54)	TP (n = 37)	P
Preoperative creatinine, mean (SD)	0.95 (0.21) n = 53	0.90 (0.17) n = 36	0.27[1]
Postop creatinine, mean (SD)	1.0 (0.21) n = 46	1.0 (0.18) n = 28	0.67[1]

P = Significance based on: [1]Independent samples t-test. RP: Retroperitoneal; TP: Transperitoneal; SD: Standard deviation.

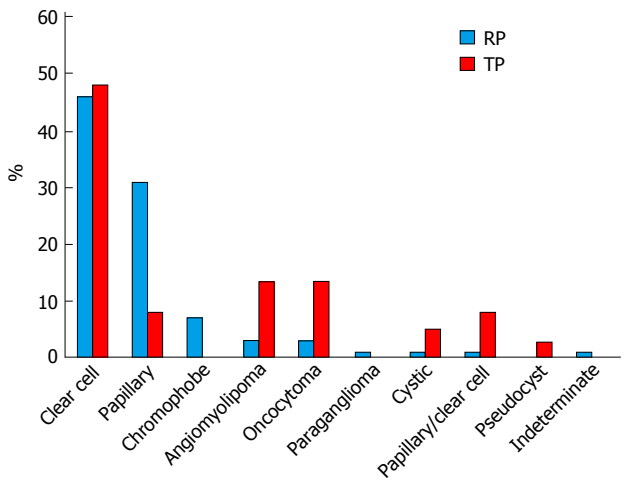

Figure 1 Tumor histology. RP: Retroperitoneal; TP: Transperitoneal.

renal tumors regardless of anterior or posterior location that underwent RALPN *via* TP or RP approach, Gin *et al*[7] found that after adjusting for tumor complexity that less complex tumors based on RENAL nephrometry score were more likely to undergo RP RALPN. They demonstrated that more patients (69%) with posterior renal tumors underwent excision *via* the RP approach, and this was associated with lower EBL and lower rates of readmission[7].

Further, benefits to the RP approach have been shown with regard to multiple perioperative factors including operative time, EBL, length of hospital stay, and return of bowel function[3,9,15]. A meta-analysis by Ren *et al*[5], including eight retrospective studies evaluating the use of TP *vs* RP laparoscopic partial nephrectomy found that RP partial nephrectomy was associated with shorter operative times, lower EBL, and a shorter hospital stay. A similar meta-analysis by Fan *et al*[2], comparing TP *vs* RP laparoscopic and robotic partial nephrectomy demonstrated that the RP approach was associated with shorter time to renal hilum control, shorter operative time, shorter length of hospital stay, and a lower overall complication rate.

The RP approach eliminates the need for bowel mobilization thus limiting the potential for injury to abdominal organs and the development of intra-abdominal adhesions and intestinal obstruction[16]. The literature supports the fact that lack of bowel mobilization and faster access to the renal hilum contributes to the shorter operative times and results in earlier return of bowel function postoperatively[9,15]. We also believe that lack of total renal mobilization to access the posterior surface of the kidney contributes to shorter operative times and a lower EBL.

The ability to perform more procedures off-clamp *via* the RP approach was likely due to the simplicity and speed at which the renal hilum could be identified, thereby also allowing for easy identification of the renal hilum to place a bulldog clamp if necessary during tumor excision. Conversion to an open procedure was performed more commonly during the TP approach at 13.5% *vs* 3.7% in *via* the RP group. Although not statistically significant, this is likely due to the ease at which the renal hilum can be accessed and lack of bowel mobilization required for the RP approach. Regarding the differences in laterality of tumors, specifically that a majority of patients with left-sided tumors underwent resection *via* the TP approach (59.5%), whereas a majority of patients with right-sided tumors were *via* the RP approach (63%, $P = 0.04$), remains unclear. This difference is possibly due to anatomical reasons, such that there is no need for liver retraction and placement of an additional port for RALPN for right-sided tumors when performed *via* the RP approach.

Most patients were discharged on postoperative day one or two after RP or TP RALPN, and therefore length of hospital stay was not evaluated in our study.

Partial nephrectomy remains the standard of care for small renal masses in appropriately selected patients[14]. The RP approach to RALPN has proven an effective approach for posterior renal masses with acceptable oncologic and morbidity outcomes, including preservation of postoperative renal function[6]. In our study, more RP procedures were performed off-clamp. Despite the fact that there was no significant difference in postoperative renal function, we believe in the importance of performing RALPN off-clamp if it is deemed safe and possible, in an attempt to maximally preserve renal function.

The oncological outcomes after RP partial nephrectomy have proven similar to those of competing approaches including rate of recurrence and positive margins. The literature demonstrates positive margin rates of 0%-5.6% for RP RALPN, and recurrence rates of 1.5%-6%. Of note, positive margin rates for open partial nephrectomy and laparoscopic RP partial nephrectomy are similar at 1.3%-1.5% and 2%-7.1%, respectively[6]. Our incidence of positive margins was lower *via* the RP approach (2%) when compared to the TP approach (8.6%), however this was not statistically significant. We believe that it is important to note the dramatic difference, which may be due to better tumor visualization during excision *via* the RP approach. Our recurrence rate was low for both approaches, with only one recurrence in the RP group.

Our results support existing literature demonstrating the superiority of the RP approach to RALPN with regard to operative time, blood loss, preservation of renal function, and oncologic outcomes[2,5]. The current study, however, was the first to evaluate outcomes of RP RALPN exclusively for posterior renal masses. With an increasing body of data to support its use, increased familiarity with the RP approach to RALPN may lead to widespread adaptation of this technique, particularly for posterior renal tumors.

The limitations of our study include the retrospective design and lack of randomization. A selection bias likely existed as the surgical approach was determined by the primary surgeon based on the tumor location and characteristics. Patients with posterior renal tumors were more likely to be selected to undergo the RP approach to RALPN. Despite this, however, the findings of decreased total operative time, robotic console time, and EBL remain significant. A prospective, randomized trial is necessary to remedy this selection bias. Randomization should include both right- and left-sided posterior renal tumors performed *via* the RP and TP approaches. Another limitation includes the short follow-up interval for assessment of postoperative renal function, which was measured at an average of only 4.5 mo. Long-term assessment of oncological outcomes is needed, as our study included radiographic follow-up at an average of less than 1 year postoperatively.

In conclusion, the TP and RP approach to RALPN are feasible approaches for posterior renal masses. The RP approach to RALPN, however, is superior with regard to operative time and blood loss when compared to the more familiar TP approach.

COMMENTS

Background

Robotic-assisted laparoscopic partial nephrectomy (RALPN) is increasingly utilized as an alternative to laparoscopic or open partial nephrectomy for surgical extirpation of renal masses, and can be performed *via* a transperitoneal (TP) or retroperitoneal (RP) approach. The majority of the literature describes the TP approach as it has been more widely adopted, however the RP approach has been shown to have specific advantages. No study has evaluated the use of the RP approach to RALPN specifically for posteriorly located renal tumors.

Research frontiers

The literature suggests that the RP approach to RALPN is an acceptable alternative to the TP approach, however no studies have compared these methods specifically for posteriorly located tumors. The current study evaluates the use of RALPN for posterior renal tumors *via* the TP and RP approaches in regards to perioperative, renal functional, and oncological outcomes.

Innovations and breakthroughs

The RP approach to RALPN has been proven to have specific advantages over the TP approach including direct access to posterior and lateral tumors without whole kidney mobilization, direct access to the renal artery, and lack of need for bowel mobilization. This study was the first study to examine the use of the RP approach to RALPN specifically for posteriorly located renal tumors. The authors concluded that the RP approach to RALPN for posterior renal tumors is associated with decreased total operative time, robotic console time, and estimated blood loss, and is more likely to be performed off-clamp when compared to the TP approach.

Applications

This study suggests that the RP approach to RALPN is a safe alternative to the more familiar TP approach for surgical extirpation of posterior renal tumors, and is associated with decreased total operative time, robotic console time, and estimated blood loss. The RP approach to RALPN is also more likely to be performed off-clamp, and is associated with similar oncological outcomes and postoperative renal function. The authors' findings support the use of the RP approach to RALPN for posteriorly located renal tumors.

Terminology

The RENAL nephrometry score is a scoring system to objectively describe anatomic characteristics of renal tumors including tumor radius, amount of tumor that is exophytic, nearness of deepest portion of the tumor to the collecting system or renal sinus, anterior or posterior location, and location relative to the polar line.

Peer-review

The study is interesting.

REFERENCES

1 **Choo SH**, Lee SY, Sung HH, Jeon HG, Jeong BC, Jeon SS, Lee HM, Choi HY, Seo SI. Transperitoneal versus retroperitoneal robotic partial nephrectomy: matched-pair comparisons by nephrometry scores. *World J Urol* 2014; **32**: 1523-1529 [PMID: 24817141 DOI: 10.1007/s00345-014-1312-7]

2 **Fan X**, Xu K, Lin T, Liu H, Yin Z, Dong W, Huang H, Huang J. Comparison of transperitoneal and retroperitoneal laparoscopic nephrectomy for renal cell carcinoma: a systematic review and meta-analysis. *BJU Int* 2013; **111**: 611-621 [PMID: 23106964 DOI: 10.1111/j.1464-410X.2012.11598.x]

3 **Marszalek M**, Chromecki T, Al-Ali BM, Meixl H, Madersbacher S, Jeschke K, Pummer K, Zigeuner R. Laparoscopic partial nephrectomy: a matched-pair comparison of the transperitoneal versus the retroperitoneal approach. *Urology* 2011; **77**: 109-113 [PMID: 20970830 DOI: 10.1016/j.urology.2010.02.057]

4 **Benway BM**, Bhayani SB, Rogers CG, Dulabon LM, Patel MN, Lipkin M, Wang AJ, Stifelman MD. Robot assisted partial nephrectomy versus laparoscopic partial nephrectomy for renal tumors: a multi-institutional analysis of perioperative outcomes. *J Urol* 2009; **182**: 866-872 [PMID: 19616229 DOI: 10.1016/j.juro.2009.05.037]

5 **Ren T**, Liu Y, Zhao X, Ni S, Zhang C, Guo C, Ren M. Transperitoneal approach versus retroperitoneal approach: a meta-analysis of laparoscopic partial nephrectomy for renal cell carcinoma. *PLoS One* 2014; **9**: e91978 [PMID: 24658032 DOI: 10.1371/journal.pone.0091978]

6 **Hu JC**, Treat E, Filson CP, McLaren I, Xiong S, Stepanian S, Hafez KS, Weizer AZ, Porter J. Technique and outcomes of robot-assisted retroperitoneoscopic partial nephrectomy: a multicenter study. *Eur Urol* 2014; **66**: 542-549 [PMID: 24857539 DOI: 10.1016/j.eururo.2014.04.028]

7 **Gin GE**, Maschino AC, Spaliviero M, Vertosick EA, Bernstein ML, Coleman JA. Comparison of perioperative outcomes of retroperitoneal and transperitoneal minimally invasive partial nephrectomy after adjusting for tumor complexity. *Urology* 2014; **84**: 1355-1360 [PMID: 25288573 DOI: 10.1016/j.urology.2014.07.045]

8 **Patel M**, Porter J. Robotic retroperitoneal partial nephrectomy. *World J Urol* 2013; **31**: 1377-1382 [PMID: 23404196 DOI: 10.1007/s00345-013-1038-y]

9 **Ng CS**, Gill IS, Ramani AP, Steinberg AP, Spaliviero M, Abreu SC, Kaouk JH, Desai MM. Transperitoneal versus retroperitoneal laparoscopic partial nephrectomy: patient selection and perioperative outcomes. *J Urol* 2005; **174**: 846-849 [PMID: 16093967]

10 **Ellison JS**, Montgomery JS, Hafez KS, Miller DC, He C, Wolf JS, Weizer AZ. Association of RENAL nephrometry score with outcomes of minimally invasive partial nephrectomy. *Int J Urol* 2013; **20**: 564-570 [PMID: 23126585 DOI: 10.1111/j.1442-2042.2012.03222.x]

11 **Patel M**, Porter J. Robotic retroperitoneal surgery: a contemporary review. *Curr Opin Urol* 2013; **23**: 51-56 [PMID: 23159992 DOI: 10.1097/MOU.0b013e32835b61f4]

12 **Ghani KR**, Porter J, Menon M, Rogers C. Robotic retroperitoneal partial nephrectomy: a step-by-step guide. *BJU Int* 2014; **114**: 311-313 [PMID: 24571203 DOI: 10.1111/bju.12709]

13 **Hayn MH**, Schwaab T, Underwood W, Kim HL. RENAL nephrometry score predicts surgical outcomes of laparoscopic partial nephrectomy. *BJU Int* 2011; **108**: 876-881 [PMID: 21166761 DOI: 10.1111/j.1464-410X.2010.09940.x]

14 **Novick AC**, Campbell SC, Belldegrun A, Blute ML, Chow GK, Derweesh IH, Kaouk JH, Leveillee RJ, Matin SF, Russo P, Uzzo RG. Guideline for Management of the Clinical Stage 1 Renal Mass. American Urological Association Education and Research, Inc., 2009: 1-76

15 **Wright JL**, Porter JR. Laparoscopic partial nephrectomy: comparison of transperitoneal and retroperitoneal approaches. *J Urol* 2005; **174**: 841-845 [PMID: 16093966]

16 **Garg M**, Singh V, Sinha RJ, Sharma P. Prospective randomized comparison of transperitoneal vs retroperitoneal laparoscopic simple nephrectomy. *Urology* 2014; **84**: 335-339 [PMID: 24975713 DOI: 10.1016/j.urology.2014.04.038]

P- Reviewer: Stavroulopoulos A, Taheri S
S- Editor: Gong XM **L- Editor**: A **E- Editor**: Li D

World Journal of Clinical Urology

Submit a Manuscript: http://www.wjgnet.com/esps/
Help Desk: http://www.wjgnet.com/esps/helpdesk.aspx
DOI: 10.5410/wjcu.v5.i1.66

World J Clin Urol 2016 March 24; 5(1): 66-71
ISSN 2219-2816 (online)
© 2016 Baishideng Publishing Group Inc. All rights reserved.

SYSTEMATIC REVIEWS

Pre-transplant treatment of large polycystic kidney

Iván D Sáez, Juan F de la Llera, Andrés Tapia, Rodrigo A Chacón, Pedro A Figueroa, Bruno I Vivaldi, Alfredo Domenech, Christopher D Horn, Fernando Coz

Iván D Sáez, Juan F de la Llera, Andrés Tapia, Rodrigo A Chacón, Pedro A Figueroa, Bruno I Vivaldi, Alfredo Domenech, Christopher D Horn, Fernando Coz, Department of Urology, Military Hospital, Facultad de Medicina, Universidad de los Andes, Santiago 7850000, Chile

Author contributions: Sáez ID contributed to the literature search, revision, analysis and writing of the manuscript; de la Llera JF and Tapia A to the literature search, revision and writing of the manuscript; Chacón RA, Figueroa PA, Vivaldi BI and Domenech A contributed to the literature analysis and revision of the manuscript; Horn CD contributed to the literature search; Coz F contributed as head author.

Conflict-of-interest statement: There are no potential conflicts of interest. No financial support was received.

Open-Access: This article is an open-access article which was selected by an in-house editor and fully peer-reviewed by external reviewers. It is distributed in accordance with the Creative Commons Attribution Non Commercial (CC BY-NC 4.0) license, which permits others to distribute, remix, adapt, build upon this work non-commercially, and license their derivative works on different terms, provided the original work is properly cited and the use is non-commercial. See: http://creativecommons.org/licenses/by-nc/4.0/

Correspondence to: Fernando Coz, MD, Professor, Chairman, Department of Urology, Military Hospital, Facultad de Medicina, Universidad de los Andes, Avenida Larraín 9100, Metropolitan Region, Santiago 7850000, Chile. dr.fcoz@gmail.com
Telephone: +56-2-23316982
Fax: +56-2-23317168

Received: August 28, 2015
Peer-review started: September 2, 2015
First decision: November 24, 2015
Revised: December 11, 2015
Accepted: January 16, 2016
Article in press: January 19, 2016
Published online: March 24, 2016

Abstract

AIM: To evaluate the indications, optimal timing and outcomes of native nephrectomy and other techniques in pretransplant treatment of autosomal dominant polycystic kidney disease (PKD).

METHODS: A literature review was conducted using the PubMed and Epistemonikos databases. Keywords for pre-transplant surgical management of polycystic kidneys were: Transplant, treatment and PKD. Keywords for pre-treatment embolization of PKD were: Embolization, transplant and polycystic kidney disease. The inclusion criterions were all articles found using this search method. The exclusion criterions were articles found to include bias and not attending pre-transplant treatment options. Fifteen articles were included in our final analysis. Ten articles were found regarding embolization of PKD of which three reviews were selected for final analysis. The reviews were divided into pre transplant and intra transplant treatment for the surgical treatment of PKD. All articles meeting inclusion criteria were thoroughly analyzed by two independent reviewers. A third independent reviewer was consulted if the reviewers did not agree upon the inclusion or exclusion of a specific article. No statistical analysis was performed.

RESULTS: Studies vary regarding the technique used (open or laparoscopic), laterality (single or bilateral) and temporality of nephrectomy with respect to renal transplant (pre-transplant or simultaneous to transplant). Several groups argue in favor of simultaneous nephrectomy and kidney transplant since it avoids the deleterious effects of being anefric. Long-term results and patient satisfaction are acceptable. However, it is associated with increased operative time, transfusion rate, morbidity and length of hospital stay. Based on small sample studies, bilateral nephrectomy prior to transplant has been associated with a higher risk of morbidity and mortality. Studies on laparoscopic approach report it as a feasible and safe alternative to the open surgery approach, highlighting its lower complication rate, transfusions and shorter hospital stay. Arterial embolization of the kidney appears as an effective

and low morbid alternative for the management of large native kidneys. The reduction in renal size allow transplant in a significant number of patients, which makes it an appealing alternative to surgery.

CONCLUSION: There is limited evidence regarding best pretrasnplant treatment of large PKD but to date embolization seems an appealing alternative to augment space for renal graft allocation.

Key words: Polycystic Kidneys; Kidney transplant; End stage renal disease; Kidney embolization

© The Author(s) 2016. Published by Baishideng Publishing Group Inc. All rights reserved.

Core tip: Pre-transplant management of polycystic kidneys for patients with end-stage renal disease is unclear. A number of studies have advocated in favor of bilateral nephrectomy prior to transplant, others promote simultaneous nephrectomy and kidney transplant. Arterial embolization to reduce native kidney volume appears as an effective and attractive alternative.

Sáez ID, de la Llera JF, Tapia A, Chacón RA, Figueroa PA, Vivaldi BI, Domenech A, Horn CD, Coz F. Pre-transplant treatment of large polycystic kidney. *World J Clin Urol* 2016; 5(1): 66-71 Available from: URL: http://www.wjgnet.com/2219-2816/full/v5/i1/66.htm DOI: http://dx.doi.org/10.5410/wjcu.v5.i1.66

INTRODUCTION

Autosomal dominant polycystic kidney disease (ADPKD) is responsible for approximately 10% of all cases of end stage renal disease[1] and is the leading cause of inherited kidney failure in the United States and Europe[2-7].

For patients with ADPKD who reach end stage renal disease, the preferred treatment is kidney transplant, which permits an improved survival and lower morbidity rate compared to other forms of renal replacement therapy[8-13].

The indications for native nephrectomy in patients with ADPKD are: (1) Very large kidneys, causing lack of space for the transplant; (2) chronic and severe abdominal or lumbar pain attributable to the mass; (3) recurrent UTI or urosepsis due to cyst infection, especially in those not responding to medical treatment; (4) hematuria requiring recurrent or persistent blood transfusions; (5) gastrointestinal symptoms (early satiety) secondary to mass compression; and (6) suspicious of malignancy on preoperative diagnostic images.

These indications and timing of nephrectomy in ADPKD patients remains controversial for those undergoing renal transplant. While most ADPKD patients do not require either a unilateral or bilateral nephrectomy to facilitate kidney transplant, the size of the kidneys and associated symptoms in some cases provide sufficient indications for surgery. Some authors advocate for native unilateral or bilateral nephrectomy prior to transplant; others promote unilateral or bilateral native nephrectomy at the time of transplant, and others suggest doing the native nephrectomy following the transplant[14]. Another method described is the "sandwich technique", where the most severely affected native kidney is removed prior to transplant and the other native kidney is removed subsequently[15]. All these approaches have been described with open surgical techniques, but lately, some centers have published their experience with laparoscopy showing promising results[16].

Arterial embolization and secondary shrinkage of very enlarged kidneys has been proposed as an alternative to nephrectomy in selected cases, with the sole objective of making anatomical space for transplant or treating symptoms related to kidney volume [17].

All of the above methods show advantages and disadvantages.

The aim of this review is to evaluate the indications, optimal timing and outcomes of native nephrectomy and other techniques in patients with ADPKD as related to kidney transplant.

MATERIALS AND METHODS

A literature review was conducted using the PubMed and Epistemonikos databases. Keywords for pre-transplant surgical management of polycystic kidneys were: Transplant, treatment and polycystic kidney disease. Keywords for pre-treatment embolization of PKD were: Embolization, transplant and polycystic kidney disease. The inclusion criterion was all articles found using this search method. The exclusion criterions were articles found to include bias and not attending pre-transplant treatment options. As a result of our search, 15 articles were found for surgical treatment and included in our final analysis. Ten articles were found in the embolization search with 3 reviews subject for final analysis. The reviews were divided into pre transplant and intra transplant treatment for the surgical treatment of PKD. All articles meeting inclusion criteria were thoroughly analyzed by 2 independent reviewers. A third independent reviewer was consulted if the reviewers did not agree about the inclusion or exclusion of a specific article. No statistical analysis was carried out.

RESULTS

Fifteen articles present results of surgical treatment in ADPKD and renal transplant. They vary with regard to the technique used (open or laparoscopic), laterality (single or bilateral) and temporality with respect to renal transplant (pre-transplant or simultaneous to transplant). Table 1 shows the results of these series.

Unilateral or bilateral nephrectomy simultaneous to renal transplant

The majority of series incorporate this modality. This

Table 1 Summary of the nephrectomy series results

Author	Year	*n*	Technique Open/ laparoscopic	Side Uni/Bilateral	Relation with trasplant Pre-trasplant/ simultaneous/posttrasplant	Transfusion (units)	Complications (%)	Mortality
Song	2011	31	Open	Bilateral	Simultaneous	4.68 ± 1.51	32	No
Glassman	2000	10	Open	Bilateral	Simultaneous	2.3	20	No
Tabibi	2005	13	Open	7 UI/6 bilat	Simultaneous	ND	ND	No
Skauby	2012	78	Open	Bilateral	Simultaneous	1.6 (0-11)	30	No
Kramer	2009	20	Laparoscopic	Bilateral	Simultaneous	3.3 (0 - 8)	20	No
Dunn	1999	11	Laparoscopic	7 UI/2 bilateral	Pre-trasplant	ND	55	No
Nunes	2007	16	Open	Unilateral	Simultaneous	1.81	6.3	No
Lucas	2010	42	Laparoscopic	18 UI/24 bilateral	Pre/posttrasplant	ND	25	No
Desai	2007	13	Laparoscopic	5 UI/7 bilateral	Pre/postrasplant	0.9	60	No
Krol	2006	20	Open	Bilateral	Pretrasplant	3.2	45	No
Neeff	2012	100	Open	Unilateral	Simultaneous	ND	22	No
Wagner	2006	32	Open	Bilateral	17 simultaneous/15 pretrasplant	2.2	70 (simultaneous) 75 (pretrasplant)	No
Kirkman	2010	35	Open	10 UI/10 bilateral	Pretrasplant	ND	35	Yes (2 patients, bilateral group)
Tyson	2013	2368	Open	Bilateral	271 simultaneous/2097 pretrasplant	ND	ND	Yes (1.1% simultaneous-15.8% pretrasplant)

procedure does not show major risks when compared to renal transplant exclusively[18-25].

These series have longer surgical times, higher transfusion and complication rates when compared to renal transplant alone. However, they all coincide on favorable long-term results of renal graft function and global survival. These series do not show mortality rates.

Song *et al*[18] reports that 32 patients with ADPKD who were transplanted without nephrectomy had a greater incidence of hypertension (91% *vs* 66%) and urinary tract infection (31% *vs* 6.4%) compared to a similar group where simultaneous bilateral nephrectomy and renal transplant was performed.

Glassman reports that in nine transplanted patients, postoperative creatinine was 2.2 *vs* 1.6 in the simultaneous nephrectomy and transplant group. This study incorporates a non-validated user satisfaction survey: 70% of patients submitted to the double procedure were satisfied. In patients submitted to transplant exclusively, 7 out of 9 would have preferred simultaneous nephrectomy[19].

Neeff *et al*[24] presents a series of 100 patients with ADPKD submitted to nephrectomy with a prolonged unilateral midline Gibson incision. Only 12% of patients presented postoperative complications (linfocele, hernia, hematoma, haemorrhage). Four percent of patients had to be operated due to one of these complications. Overall renal graft survival was of 96% and 80% in years 1 and 5, respectively. Graft survival rates are similar to series without nephrectomy. This study does not present a control group.

Fuller at UCLA presents 32 patients submitted to nephrectomy at all times. Seven patients underwent nephrectomy before transplant, 16 simultaneous with renal transplant and nine post-transplant. There were no differences in terms of complications. This study suggests performing unilateral or bilateral nephrectomy simultaneous to transplant, especially in the live donor setting[25].

Other authors study results in patients submitted to bilateral nephrectomy; some patients were also transplanted simultaneously. In these series, surgical times and complications rates in the compared groups were similar[16,26,27].

Wagner *et al*[26] reports shorter hospitalization stay in patients with simultaneous nephrectomy and transplant (6.9 d) *vs* differed nephrectomy and transplant (11.8 d for both hospitalization periods).

Tyson *et al*[27] presents the analysis of the Nationwide Inpatient Sample Database, demonstrating lesser mortality in the nephrectomy and transplant (OR = 0.06) compared with the bilateral nephrectomy without transplant group. This difference is not found when analyzing high volume centers only.

Martin *et al*[16] reports better postoperative creatinine values in patients submitted to laparoscopic bilateral nephrectomy and simultaneous transplant compared to differed transplant (1.6 *vs* 2.3 mg/dL).

Pre-transplant bilateral nephrectomy

Two authors present very small series with pre-transplant nephrectomy with differed transplant. Both show the highest postoperative complications rate and mortality.

Kirkman analyzes outcomes of patients submitted to unilateral or bilateral nephrectomy before or after transplant. Mortality is present in this series. In the pre transplant bilateral nephrectomy group 2 of 10 patients died, while in the bilateral differed nephrectomy group 1 of 10 patients died. All deaths were due to colonic ischemia leading to multiorgan failure. There is no statistical analysis for this difference[14].

Król *et al*[28] presents 20 patients in hemodialysis submitted to open bilateral nephrectomy. Postoperative complications were present in 9 of 20 patients (45%).

Table 2 Serum creatinin at discharge in transplant and nephrectomy series

Author	Year	Creatinin at discharge	
		Transplant	Transplant + nephrectomy
Wagner	2006	2	1.6
Lucas	2010	1.6	1.5
Nunes	2007	1.79	1.6
Kramer	2009	2	1.6
Tabibi	2005	1.2	1.3
Glassman	2000	2.2	1.6
Wagner	2007	2	1.6
Martin	2012	2.3	1.6

Complications described include hernia, chronic abdominal pain, peptic ulcer and ileum. This series does not present mortality.

Laparoscopic nephrectomy

Two authors present small laparoscopic nephrectomy series, with no control group. There is a lesser complication, transfusion, pain and hospital stay rate as compared to cohorts with open surgery. There is no mention of graft function or survival with this technique[29,30].

Pre-transplant embolization of polycystic kidneys

There are few cohorts that show the effect of embolization of renal arteries to reduce the size of polycystic kidneys for graft space. In 2010, Cornelis *et al*[17] published their experience of 25 patients with ADPKD awaiting renal transplant treated with embolization. Renal size was evaluated with computed tomography scan pre embolization and at 3 and 6 mo post procedure. Thirty-six percent and 84% of patients had a reduction of renal size at 3 and 6 mo, allowing renal transplant. Mean reduction in renal size at these times was 42% and 54%. The main complication reported was post embolization syndrome in five patients. This syndrome is characterized by low fever and severe lumbar pain. Pain was managed with opioid derivatives, disappearing in 2 wk post procedure. One patient developed a pseudo-aneurism at the puncture site, managed with manual compression. These authors conclude that trans-arterial embolization prior to renal transplant is an option to nephrectomy and suggest a post-therapy pain management protocol[17].

This same group published their results in 2014, presenting now a series of 73 patients in which 82 procedures were performed in 76 rental units. Renal artery embolization was successful in diminishing renal size by 89.5% at 5.6 mo after treatment (range 2.8 to 24.3 mo). Mean renal size reduction was 59% 3 mo post embolization. Post embolization syndrome was present in 15 procedures (18.3%). Complications described in this series include one pulmonary embolism, one iliac artery thrombosis, a pseudo aneurysm of the femoral artery and an infection of a renal cyst, all categorized as grade Ⅱ complications according to the Clavien Dindo classification. This group describes 43 successful transplants with previous renal embolization[31].

DISCUSSION

All published series present small patient cohorts. This does not allow categorical conclusions regarding pre-treatment options of very large ADPKD. The largest series, presented by Skauby *et al*[21] and Tyson *et al*[27], coincide in that there is a longer surgery time and complication rate in nephrectomy with concomitant transplant than in transplant alone. Tyson also refers to the possible better prognosis for patients that receive transplant with simultaneous nephrectomy. However, this difference could be accounted for by technical experience more than a graft-related determinant factor.

Another factor to consider is the function of the graft at the moment of hospital discharge. Reports seem to indicate that the function of the graft may be better when it is done with simultaneous nephrectomy as compared to transplant and differed nephrectomy (Table 2).

It seems that the worst moment for nephrectomy is before or after the transplant. Although these series are small, Kirkman *et al*[14] and Król *et al*[28] report higher rates of complications and mortality -up to 20%- in patients with bilateral nephrectomy without immediate transplant. The factors that may explain this are anephric time and permanence in dialysis.

Post-transplant nephrectomy, though not a central objective of our study, seems to have a greater rate of urinary tract infection due to cyst infection. This greater infection rate may be due to immune-suppression in the transplanted patient. This argument is frequently employed to perform nephrectomy pre or intra transplant.

There are few reports studying renal embolization for volume management of ADPKD. There is only one group actively working on this subject, with excellent results in terms of reduction of renal size and pain control[17,31].

While our experience in embolization previous to transplant is limited, our results coincide with those shown previously in diminishing renal size and augmenting space for renal graft allocation. If we could suggest something it would be to use an epidural catheter for pain control after embolization. Another suggestion would be to embolize using not only coils but also ethanol to attain an adequate level of ischemia and posterior renal atrophy. We strongly believe that embolization of polycystic kidneys will have a leading role in the near future.

COMMENTS

Background

Autosomal dominant polycystic kidney disease plays a key role in chronic kidney disease. So far, the timing of the surgical procedure remains unclear, especially related to kidney transplantation.

Research frontiers

To find the best timing for kidney transplantation (before, concomitant, or after nephrectomy), comparing both living and cadaveric donors. Strong evidence supported by collaborative multi centric trials is necessary. The authors believe embolization of polycystic kidney disease plays an important role in this setting,

especially in low volume centers.

Innovations and breakthroughs

Embolization only requires an interventional radiologist that allows adequate management with a minimally invasive approach. This technique should be considered as a first line treatment instead of nephrectomy.

Applications

End stage and complicated autosomal dominant polycystic kidney disease (ADPKD).

Peer-review

The authors reviewed the literature regarding surgical approach and timing for the native nephrectomy for patients with ADPKD being scheduled kidney transplantation. The paper is well-written and provides important information regarding this aspect.

REFERENCES

1 **Gabow PA**. Autosomal dominant polycystic kidney disease. *N Engl J Med* 1993; **329**: 332-342 [PMID: 8321262 DOI: 10.1056/NEJM199307293290508]

2 **Torres VE**, Harris PC, Pirson Y. Autosomal dominant polycystic kidney disease. *Lancet* 2007; **369**: 1287-1301 [PMID: 17434405 DOI: 10.1016/S0140-6736(07)60601-1]

3 **Harris PC**, Torres VE. Polycystic kidney disease. *Annu Rev Med* 2009; **60**: 321-337 [PMID: 18947299 DOI: 10.1146/annurev.med.60.101707.125712]

4 **Ong AC**, Harris PC. Molecular pathogenesis of ADPKD: the polycystin complex gets complex. *Kidney Int* 2005; **67**: 1234-1247 [PMID: 15780076 DOI: 10.1111/j.1523-1755.2005.00201.x]

5 **Iglesias CG**, Torres VE, Offord KP, Holley KE, Beard CM, Kurland LT. Epidemiology of adult polycystic kidney disease, Olmsted County, Minnesota: 1935-1980. *Am J Kidney Dis* 1983; **2**: 630-639 [PMID: 6846334 DOI: 10.1016/S0272-6386(83)80044-4]

6 **Davies F**, Coles GA, Harper PS, Williams AJ, Evans C, Cochlin D. Polycystic kidney disease re-evaluated: a population-based study. *Q J Med* 1991; **79**: 477-485 [PMID: 1946928]

7 **Collins AJ,** Kasiske B, Herzog C, Chavers B, Foley R, Gilbertson D, Grimm R, Liu J, Louis T, Manning W, Matas A, McBean M, Murray A, St Peter W, Xue J, Fan Q, Guo H, Li S, Li S, Roberts T, Snyder J, Solid C, Wang C, Weinhandl E, Arko C, Chen SC, Dalleska F, Daniels F, Dunning S, Ebben J, Frazier E, Johnson R, Sheets D, Forrest B, Berrini D, Constantini E, Everson S, Frederick P, Eggers P, Agodoa L; United States Renal Data System. Excerpts from the United States Renal Data System 2004 annual data report: atlas of end-stage renal disease in the United States. *Am J Kidney Dis* 2005; **45** (1 Suppl 1): A5-A7, S1-S280 [PMID: 15640975]

8 **Alam A**, Perrone RD. Management of ESRD in patients with autosomal dominant polycystic kidney disease. *Adv Chronic Kidney Dis* 2010; **17**: 164-172 [PMID: 20219619 DOI: 10.1053/j.ackd.2009.12.006]

9 **Haynes R**, Kheradmand F, Winearls CG. Survival after starting renal replacement treatment in patients with autosomal dominant polycystic kidney disease: a single-centre 40-year study. *Nephron Clin Pract* 2012; **120**: c42-c47 [PMID: 22205054 DOI: 10.1159/000334429]

10 **Mosconi G**, Persici E, Cuna V, Pedone M, Tonioli M, Conte D, Ricci A, Feliciangeli G, La Manna G, Nanni Costa A, Stefoni S. Renal transplant in patients with polycystic disease: the Italian experience. *Transplant Proc* 2013; **45**: 2635-2640 [PMID: 24034011 DOI: 10.1016/j.transproceed.2013.07.016]

11 **Jacquet A**, Pallet N, Kessler M, Hourmant M, Garrigue V, Rostaing L, Kreis H, Legendre C, Mamzer-Bruneel MF. Outcomes of renal transplantation in patients with autosomal dominant polycystic kidney disease: a nationwide longitudinal study. *Transpl Int* 2011; **24**: 582-587 [PMID: 21352383 DOI: 10.1111/j.1432-2277.2011.01237.x]

12 **Orskov B**, Rømming Sørensen V, Feldt-Rasmussen B, Strandgaard S. Improved prognosis in patients with autosomal dominant polycystic kidney disease in Denmark. *Clin J Am Soc Nephrol* 2010; **5**: 2034-2039 [PMID: 20671227 DOI: 10.2215/CJN.01460210]

13 **Perrone RD**, Ruthazer R, Terrin NC. Survival after end-stage renal disease in autosomal dominant polycystic kidney disease: contribution of extrarenal complications to mortality. *Am J Kidney Dis* 2001; **38**: 777-784 [PMID: 11576881 DOI: 10.1053/ajkd.2001.27720]

14 **Kirkman MA**, van Dellen D, Mehra S, Campbell BA, Tavakoli A, Pararajasingam R, Parrott NR, Riad HN, McWilliam L, Augustine T. Native nephrectomy for autosomal dominant polycystic kidney disease: before or after kidney transplantation? *BJU Int* 2011; **108**: 590-594 [PMID: 21166760 DOI: 10.1111/j.1464-410X.2010.09938.x]

15 **Cassuto-Viguier E**, Quintens H, Chevallier D, Derrier M, Jambou P, Toubol J, Duplay H. Transplantation and nephrectomy in autosomal dominant polycystic disease. *Clin Nephrol* 1991; **36**: 105-106 [PMID: 1934658]

16 **Martin AD**, Mekeel KL, Castle EP, Vaish SS, Martin GL, Moss AA, Mulligan DC, Heilman RL, Reddy KS, Andrews PE. Laparoscopic bilateral native nephrectomies with simultaneous kidney transplantation. *BJU Int* 2012; **110**: E1003-E1007 [PMID: 22882539 DOI: 10.1111/j.1464-410X.2012.11379.x]

17 **Cornelis F**, Couzi L, Le Bras Y, Hubrecht R, Dodré E, Geneviève M, Pérot V, Wallerand H, Ferrière JM, Merville P, Grenier N. Embolization of polycystic kidneys as an alternative to nephrectomy before renal transplantation: a pilot study. *Am J Transplant* 2010; **10**: 2363-2369 [PMID: 21143393 DOI: 10.1111/j.1600-6143.2010.03251.x]

18 **Song WL**, Zheng JM, Mo CB, Wang ZP, Fu YX, Feng G, Shen ZY. Kidney transplant for autosomal dominant polycystic kidney disease: the superiority of concurrent bilateral nephrectomy. *Urol Int* 2011; **87**: 54-58 [PMID: 21677416 DOI: 10.1159/000324603]

19 **Glassman DT**, Nipkow L, Bartlett ST, Jacobs SC. Bilateral nephrectomy with concomitant renal graft transplantation for autosomal dominant polycystic kidney disease. *J Urol* 2000; **164**: 661-664 [PMID: 10953121 DOI: 10.1097/00005392-200009010-00011]

20 **Tabibi A**, Simforoosh N, Abadpour P, Gholamrezaie HR, Nafar M. Concomitant nephrectomy of massively enlarged kidneys and renal transplantation in autosomal dominant polycystic kidney disease. *Transplant Proc* 2005; **37**: 2939-2940 [PMID: 16213267 DOI: 10.1016/j.transproceed.2005.07.053]

21 **Skauby MH**, Øyen O, Hartman A, Leivestad T, Wadström J. Kidney transplantation with and without simultaneous bilateral native nephrectomy in patients with polycystic kidney disease: a comparative retrospective study. *Transplantation* 2012; **94**: 383-388 [PMID: 22828736 DOI: 10.1097/TP.0b013e31825812b9]

22 **Kramer A**, Sausville J, Haririan A, Bartlett S, Cooper M, Phelan M. Simultaneous bilateral native nephrectomy and living donor renal transplantation are successful for polycystic kidney disease: the University of Maryland experience. *J Urol* 2009; **181**: 724-728 [PMID: 19091353 DOI: 10.1016/j.juro.2008.10.008]

23 **Nunes P**, Mota A, Alves R, Figueiredo A, Parada B, Macário F, Rolo F. Simultaneous renal transplantation and native nephrectomy in patients with autosomal-dominant polycystic kidney disease. *Transplant Proc* 2007; **39**: 2483-2485 [PMID: 17954154 DOI: 10.1016/j.transproceed.2007.07.035]

24 **Neeff HP**, Pisarski P, Tittelbach-Helmrich D, Karajanev K, Neumann HP, Hopt UT, Drognitz O. One hundred consecutive kidney transplantations with simultaneous ipsilateral nephrectomy in patients with autosomal dominant polycystic kidney disease. *Nephrol Dial Transplant* 2013; **28**: 466-471 [PMID: 23042709 DOI: 10.1093/ndt/gfs118]

25 **Fuller TF**, Brennan TV, Feng S, Kang SM, Stock PG, Freise CE. End stage polycystic kidney disease: indications and timing of native nephrectomy relative to kidney transplantation. *J Urol* 2005; **174**: 2284-2288 [PMID: 16280813 DOI: 10.1097/01.

ju.0000181208.06507.aa]
26 **Wagner MD**, Prather JC, Barry JM. Selective, concurrent bilateral nephrectomies at renal transplantation for autosomal dominant polycystic kidney disease. *J Urol* 2007; **177**: 2250-2254; discussion 2254 [PMID: 17509331 DOI: 10.1016/j.juro.2007.01.146]
27 **Tyson MD**, Wisenbaugh ES, Andrews PE, Castle EP, Humphreys MR. Simultaneous kidney transplantation and bilateral native nephrectomy for polycystic kidney disease. *J Urol* 2013; **190**: 2170-2174 [PMID: 23727414 DOI: 10.1016/j.juro.2013.05.057]
28 **Król R**, Ziaja J, Cierniak T, Pawlicki J, Chudek J, Wiecek A, Cierpka L. Simultaneous transabdominal bilateral nephrectomy in potential kidney transplant recipients. *Transplant Proc* 2006; **38**: 28-30 [PMID: 16504655 DOI: 10.1016/j.transproceed.2005.12.099]
29 **Desai MR**, Nandkishore SK, Ganpule A, Thimmegowda M. Pretransplant laparoscopic nephrectomy in adult polycystic kidney disease: a single centre experience. *BJU Int* 2008; **101**: 94-97 [PMID: 17922857]
30 **Dunn MD**, Portis AJ, Elbahnasy AM, Shalhav AL, Rothstein M, McDougall EM, Clayman RV. Laparoscopic nephrectomy in patients with end-stage renal disease and autosomal dominant polycystic kidney disease. *Am J Kidney Dis* 2000; **35**: 720-725 [PMID: 10739795 DOI: 10.1016/S0272-6386(00)70021-7]
31 **Petitpierre F**, Cornelis F, Couzi L, Lasserre AS, Tricaud E, Le Bras Y, Merville P, Combe C, Ferriere JM, Grenier N. Embolization of renal arteries before transplantation in patients with polycystic kidney disease: a single institution long-term experience. *Eur Radiol* 2015; **25**: 3263-3271 [PMID: 25981217 DOI: 10.1007/s00330-015-3730-3]

P- Reviewer: Watanabe T, Yorioka N
S- Editor: Qi Y **L- Editor**: A **E- Editor**: Li D

World Journal of Clinical Urology

Submit a Manuscript: http://www.wjgnet.com/esps/
Help Desk: http://www.wjgnet.com/esps/helpdesk.aspx
DOI: 10.5410/wjcu.v5.i1.72

World J Clin Urol 2016 March 24; 5(1): 72-74
ISSN 2219-2816 (online)
© 2016 Baishideng Publishing Group Inc. All rights reserved.

CASE REPORT

Case of intramedullary spinal cord metastasis of renal cell carcinoma

Hideo Soga, Osamu Imanishi

Hideo Soga, Department of Urology, Sanda City Hospital, Sanda, Hyogo 669-132, Japan

Osamu Imanishi, Department of Urology, Imanishi Urological Clinic, Kobe, Hyogo 657-0846, Japan

Author contributions: All authors contributed equally to this work.

Institutional review board statement: None.

Informed consent statement: None.

Conflict-of-interest statement: None.

Open-Access: This article is an open-access article which was selected by an in-house editor and fully peer-reviewed by external reviewers. It is distributed in accordance with the Creative Commons Attribution Non Commercial (CC BY-NC 4.0) license, which permits others to distribute, remix, adapt, build upon this work non-commercially, and license their derivative works on different terms, provided the original work is properly cited and the use is non-commercial. See: http://creativecommons.org/licenses/by-nc/4.0/

Correspondence to: Hideo Soga, MD, PhD, Department of Urology, Sanda City Hospital, 3-1-1, Keyaki-dai, Sanda, Hyogo 669-132, Japan. uro-hideo@pop11.odn.ne.jp
Telephone: +81-79-5658000
Fax: +81-79-5658017

Received: June 6, 2015
Peer-review started: June 10, 2015
First decision: August 18, 2015
Revised: November 13, 2015
Accepted: December 17, 2015
Article in press: December 18, 2015
Published online: March 24, 2016

Abstract

Intramedullary spinal cord tumors are rare. The improved survival resulting from more effective treatments for many cancers has led to an increased number of publications concerning intramedullary spinal cord metastasis (ISCM), including case reports and literature reviews; however, ISCM remains extremely rare in renal cancer. A 69-year-old man with a medical history of renal cell carcinoma (RCC) presented with urinary retention and bilateral paralysis of the lower extremities. A neurological examination revealed bilateral paraparesis below L1. Although brain magnetic resonance imaging (MRI), bone scintigraphy, and abdominal contrast-enhanced computed tomography revealed no abdominal findings, the thraco-lumbar MRI indicated a spot on the spinal cord at the Th12 level that exhibited hyperintensity on T2-weighted imaging and gadolinium diethylenetriaminepentaacetic acid enhancement on T1-weighted imaging. Accordingly, an ISCM of RCC was diagnosed. The patient rejected all treatments for these metastases except the steroid therapy. The patient's condition deteriorated owing to metastatic progression, and he died 3 mo after the appearance of ISCM symptoms. The prognosis of this condition was poor. The mean survival durations were 8 mo with surgical treatment, 4 mo with irradiation, and 2 mo with palliative treatments. In cases involving neurological features and if brain or bone metastasis or spinal cord compression is not clearly observed, gadolinium-enhanced MRI should be performed to determine the existence of ISCM. Recently, some authors have reported the efficacy of ISCM resection. Surgical treatment could potentially yield improvements in the nervous symptoms or a longer survival after treatment. Although the prognosis was poor in most cases of ISCM, surgical treatment may improve the patient's quality of life.

Key words: Renal cancer; Intramedullary spinal cord metastasis; Magnetic resonance imaging

© The Author(s) 2016. Published by Baishideng Publishing Group Inc. All rights reserved.

Core tip: Intramedullary spinal cord metastasis (ISCM)

is extremely rare in renal cancer. A 69-year-old man with a medical history of renal cell carcinoma presented with urinary retention and bilateral paralysis of the lower extremities. A neurological examination revealed bilateral paraparesis below L1. ISCM of renal cell carcinoma was diagnosed *via* thracolumbar gadolinium-enhanced magnetic resonance imaging (MRI). In a case involving neurological features and if brain or bone metastasis or spinal cord compression is not clearly observed, gadolinium-enhanced MRI should be performed to reveal the existence of ISCM.

Soga H, Imanishi O. Case of intramedullary spinal cord metastasis of renal cell carcinoma. *World J Clin Urol* 2016; 5(1): 72-74 Available from: URL: http://www.wjgnet.com/2219-2816/full/v5/i1/72.htm DOI: http://dx.doi.org/10.5410/wjcu.v5.i1.72

INTRODUCTION

Intramedullary spinal cord tumors are rare. The improved survival resulting from more effective treatments for many cancers has led to an increased number of publications concerning intramedullary spinal cord metastasis (ISCM), including case reports and literature reviews; however, it is still extremely rare in renal cancer. Lung cancer and breast cancer are the most common primary tumors associated with ISCM[1,2]. In the present case, a 69-year-old man with a medical history of renal cell carcinoma (RCC) presented with urinary retention and bilateral paralysis of lower extremities. Magnetic resonance imaging (MRI) revealed an ISCM of RCC.

CASE REPORT

A 69-year-old man presented with cough since the previous month. The patient was diagnosed with stage Ⅳ renal cancer and multiple pulmonary metastases following a radical left nephrectomy and right segmental lung resection. A histopathological examination confirmed clear cell carcinoma, grade 2, pT1b, pM1-pul. Immunotherapy was initiated, with interferon alpha as an adjuvant therapy. Three months after adjuvant therapy initiation, the patient observed urinary retention after experiencing gait unsteadiness. The results of serum biochemical and hematological evaluations were normal. A neurological examination revealed bilateral paraparesis below L1. Deep tendon reflexes were absent in both legs. Brain MRI and bone scintigraphy revealed no abnormal findings. An abdominal contrast-enhanced computed tomography did not reveal a lymphatic mass or liver metastasis; however thracolumbar MRI indicated a spot on the spinal cord at the level of the Th12 level that exhibited hyperintensity on T2-weighted imaging and gadolinium diethylenetriaminepentaacetic acid enhancement on T1-weighted imaging (Figure 1). According to the radiographic findings and clinical history, the patient was diagnosed with an ISCM of RCC. The patient rejected all treatment for these metastases except steroid therapy. His condition deteriorated due to metastatic progression, and he died 3 mo after the appearance of ISCM symptoms.

DISCUSSION

Intramedullary spinal cord tumor is rare. Clinically, intramedullary metastatic disease affects only 0.1%-0.4% of all cancer patients and comprises only 1%-3% of all intramedullary spinal cord neoplasms[3]. Furthermore, intramedullary metastatic disease clinically affects only 4%-8.5% of all cancer patients with central nervous system metastases[4,5]. In a study of 1096 autopsy cases with neoplasms, 200 cases (18%) were found to harbor central nerves system metastases, and ISCMs were found in 10 cases (0.9%) of those cases. In that report, 199 of the 200 metastatic cases had lung tumors. ISCM might result from venous dissemination *via* the Batson's plexus or direct nerve root invasion[6]. Most cases of ISCM might have additional metastases with various clinical features that cause unique symptoms such as gait disturbance or leg weakness; however, Rykken *et al*[1] reported that the clinical presentation of the ISCM preceded the primary tumor diagnosis in 20% of patients. Those authors suggested that the lack of a known primary malignancy should not dissuade clinicians from considering an ISCM when faced with a spinal cord mass[1]. MRI is generally a useful modality for the diagnosis of ISCM; furthermore, gadolinium-enhanced MRI is recommended as the most efficient diagnostic method, because unenhanced MRI dose not routinely yield critical findings.

Based on an understanding of the mechanism underlying RCC initiation and progression, several clinical trials evaluated the molecular targeting of RCC and observed efficacy against metastatic RCC[7]. However, no reports described the efficacy of the molecular targeting therapies against ISCM, possibly because some metastases already existed at the time of ISCM diagnosis. Several therapies, such as laminectomy, tumor reduction surgery, irradiation therapy, or steroid therapy, are used for ISCM treatment. The mean survival durations were 8 mo with surgical treatment, 4 mo with irradiation, and 2 mo with palliative treatment. Recently, some authors reported the efficacy of surgical ISCM removal[2,8]. Despite the poor prognosis of most cases, surgical treatment could potentially yield improvements in the nervous symptoms or survival duration one of more than 1 year after treatment[8]. Therefore, surgical treatment might be considered to effectively improve the patient's quality of life. In the present case, we selected palliative steroid treatment because of the rapid lung metastasis growth and patient's wishes. Steroid therapy significantly reduced the edematous infiltration observed

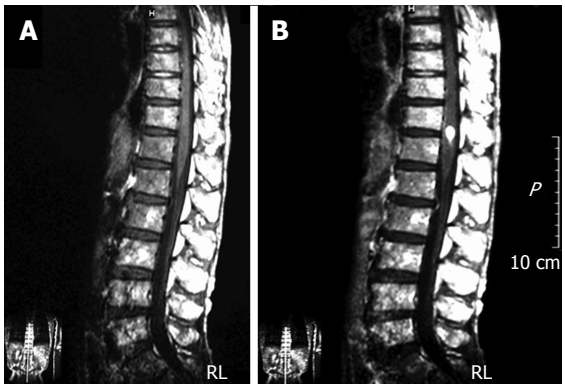

Figure 1 The thracolumbar T1-wighted magnetic resonance imaging. Though unenhanced magnetic resonance imaging (MRI) revealed no abnormal finding (A), gadolinium diethylenetriaminepentaacetic acid enhanced MRI indicated a spot on the spinal cord at the Th12 level (B).

on MRI, but did not improve the patient's symptoms in our case.

In a case involving neurological features and if brain or bone metastasis or spinal cord compression is not evident, gadolinium-enhanced MRI should be performed to reveal the existence of ISCM. Depending on the patient's condition, surgical treatment may be selected to improve the patient's quality of life.

COMMENTS

Case characteristics

A 69-year-old man with a medical history of renal cell carcinoma presented with urinary retention and paralysis of bilateral lower extremities.

Clinical diagnosis

Neurological examination revealed bilateral paraparesis below L1.

Differential diagnosis

Bone metastasis, brain metastasis, and pathological compression fracture.

Laboratory diagnosis

The results of serum biochemical and hematological evaluations were normal.

Imaging diagnosis

The thracolumbar magnetic resonance imaging (MRI) indicated a spot on the spinal cord at the Th12 level that exhibited gadolinium diethylenetriaminepentaacetic acid (DTPA) enhancement on T1-weighted imaging.

Pathological diagnosis

Although histopathological examination of renal tumor confirmed renal cell carcinoma (clear cell carcinoma, grade 2, pT1b), pathologic examination of tumor in spinal cord was not performed.

Treatment

The patient rejected all treatments for metastases except the steroid therapy.

Related reports

According to some reviews concerning intramedullary spinal cord metastasis (ISCM), lung cancer was the most frequent primary malignant disease, followed by brain and breast cancers.

Term explanation

ISCM is rare, which comprises only 1%-3% of all intramedullary spinal cord neoplasms.

Experiences and lessons

The gadolinium DTPA enhanced MRI is the most efficient diagnostic method, and early diagnosis and surgical treatment might improve the patient's quality of life.

Peer-review

The paper describes an unusual metastasis in renal carcinoma and also provides information concerning the frequency of this rare spinal cord metastasis by other neoplasm.

REFERENCES

1 **Rykken JB**, Diehn FE, Hunt CH, Schwartz KM, Eckel LJ, Wood CP, Kaufmann TJ, Lingineni RK, Carter RE, Wald JT. Intramedullary spinal cord metastases: MRI and relevant clinical features from a 13-year institutional case series. *AJNR Am J Neuroradiol* 2013; **34**: 2043-2049 [PMID: 23620071 DOI: 10.3174/ajnr.A3526]

2 **Payer S**, Mende KC, Westphal M, Eicker SO. Intramedullary spinal cord metastases: an increasingly common diagnosis. *Neurosurg Focus* 2015; **39**: E15 [PMID: 26235013 DOI: 10.3171/2015.5.FOCUS15149]

3 **Ateaque A**, Martin JL, O'Brien C. Intramedullary spinal cord metastases from a hypernephroma 11 years following the diagnosis and treatment of the primary lesion. *Br J Neurosurg* 2000; **14**: 474-476 [PMID: 11198775 DOI: 10.1080/02688690050175337]

4 **Chason JL**, Walker FB, Landers JW. Metastatic carcinoma in the central nervous system and dorsal root ganglia. A prospective autopsy study. *Cancer* 1963; **16**: 781-787 [PMID: 14020314 DOI: 10.1002/1097-0142(196306)16:6<781::AID-CNCR2820160614>3.0.CO;2-M]

5 **Schiff D**, O'Neill BP. Intramedullary spinal cord metastases: clinical features and treatment outcome. *Neurology* 1996; **47**: 906-912 [PMID: 8857717 DOI: 10.1212/WNL.47.4.906]

6 **Edelson RN**, Deck MD, Posner JB. Intramedullary spinal cord metastases. Clinical and radiographic findings in nine cases. *Neurology* 1972; **22**: 1222-1231 [PMID: 4346871 DOI: 10.1212/WNL.22.12.1222]

7 **Skolarikos AA**, Papatsoris AG, Alivizatos G, Deliveliotis C. Molecular pathogenetics of renal cancer. *Am J Nephrol* 2006; **26**: 218-231 [PMID: 16733347 DOI: 10.1159/000093631]

8 **Park J**, Chung SW, Kim KT, Cho DC, Hwang JH, Sung JK, Lee D. Intramedullary spinal cord metastasis in renal cell carcinoma: a case report of the surgical experience. *J Korean Med Sci* 2013; **28**: 1253-1256 [PMID: 23960457 DOI: 10.3346/jkms.2013.28.8.1253]

P- Reviewer: Eirini G, Hakenberg OW, Papatsoris AG
S- Editor: Gong XM **L- Editor**: A **E- Editor**: Li D

Published by **Baishideng Publishing Group Inc**
8226 Regency Drive, Pleasanton, CA 94588, USA
Telephone: +1-925-223-8242
Fax: +1-925-223-8243
E-mail: bpgoffice@wjgnet.com
Help Desk: http://www.wjgnet.com/esps/helpdesk.aspx
http://www.wjgnet.com

© 2016 Baishideng Publishing Group Inc. All rights reserved.

ISSN 2219-2816 (online)

World Journal of *Clinical Urology*

World J Clin Urol 2016 July 24; 5(2): 75-89

Published by Baishideng Publishing Group Inc

WJCU World Journal of Clinical Urology

A peer-reviewed, online, open-access journal of clinical urology

Editorial Board

2016-2019

The *World Journal of Clinical Urology* Editorial Board consists of 201 members, representing a team of worldwide experts in urology. They are from 32 countries, including Australia (2), Austria (1), Belgium (2), Brazil (4), Canada (2), Chile (1), China (19) , Czech Republic (1), Egypt (7), France (3), Germany (7), Greece (7), Hungary (1), India (3), Iran (1), Israel (4), Italy (20), Japan (8), Malaysia (1), Mexico (1), Netherlands (2), Pakistan (3), Portugal (1), Romania (1), Saudi Arabia (3), South Korea (4), Spain (2), Switzerland (1), Thailand (2), Turkey (12), United Kingdom (7), and United States (68).

EDITOR-IN-CHIEF
Makoto Ohori, *Tokyo*

ASSOCIATE EDITOR
Riccardo Schiavina, *Bologna*

GUEST EDITORIAL BOARD MEMBERS
Yen-Ching Chen, *Taipei*
How-Ran Guo, *Tainan*
Kuo-How Huang, *Taipei*
Hung-Hsiang Liou, *Taipei*
Shing-Hwa Lu, *Taipei*
Shih-Bin Su, *Tainan*
Ya-Chung Tian, *Linkou*

MEMBERS OF THE EDITORIAL BOARD

Australia
Nathan Lawrentschuk, *Heidelberg*
Henry H Woo, *Sydney*

Austria
Paul F Engelhardt, *Baden*

Belgium
Dirk PJ Michielsen, *Brussels*
Koenraad Van Renterghem, *Hasselt*

Brazil
Fernando Korkes, *Sao Paulo*
Sonia M Oliani, *Sao Paulo*
Ernani L Rhoden, *Porto Alegre*
Nestor Schor, *Sao Paulo*

Canada
Ben H Chew, *Vancouver*
Fernand Labrie, *Quebec*

Chile
Juan P Valdevenito, *Santiago*

China
Jiang-Hua Chen, *Hangzhou*
Xiang-Mei Chen, *Beijing*
Xue-Zhong Gong, *Shanghai*
Willmann Liang, *Hong Kong*
Xiu-Juan Liu, *Nanchang*
Chi-Fai Ng, *Hong Kong*
Gao Song, *Yangzhou*
Chi-Wai Tang, *Hong Kong*
Yan-Qing Tong, *Changchun*
Gao-Si Xu, Nanchang
Gao-Zhong Xu, Changchun
Yue-Min Xu, Shanghai

Czech Republic
Jiri Sedy, *Prague*

Egypt
Bedeir Ali-El-Dein, *Mansoura*
Sanaa Eissa Mohamed Hamed, *Cairo*
Ahmed MA El-Assmy, *Mansoura*
Ahmed I El-Sakka, *Ismailia*
Ihab A Hekal, *Mansoura*
Salwa I Mohammed, *Cairo*
Hassan S Shaker, *Cairo*

France
Alexandre de la Taille, *Creteil*
Stephane Larre, *Reims Cedex*
Stéphane Oudard, *Paris*

Germany
Michael Froehner, *Dresden*
Oliver W Hakenberg, *Rostock*
Thomas RW Herrmann, *Hanover*
Florian Lang, *Tuebingen*
Daniela Marschall-Kehrel, *Frankfurt*
Axel S Merseburger, *Lübeck*
Hossein Tezval, *Hannover*

Greece
George A Barbalias, *Melissia*
Dimitrios A Kirmizis, *Thessaloniki*
Evangelos N Liatsikos, *Rio Patras*
Aikaterini Papagianni, *Thessaloniki*
Athanasios G Papatsoris, *Athens*
Panagiotis Peitsidis, *Athens*
Giorgos K Sakkas, *Thessaly*

Hungary
Peter Tenke, *Budapest*

India
John Samuel Banerji, *Vellore*
Manisha Sahay, *Hyderabad*
Pratap B Singh, *Delhi*

Iran
Ahmad R Dehpour, *Tehran*

Israel
Juza Chen, *Tel-Aviv*
Ofer N Gofrit, *Jerusalem*
Inna Sinuani, *Zerifin*
Ofer Yossepowitch, *Petah Tiqwa*

Italy
Giuseppe Brisinda, *Rome*
Tommaso Cai, *Trento*
Alessandro Calisti, *Rome*
Stefano Ciatto, *Valeggio sul Mincio*
Elisabetta Costantini, *Perugia*
Paolo Cravedi, *Ranica Bergamo*
Massimiliano Creta, *Naples*
Vassilos Fanos, *Cagliari*
Mariaconsiglia Ferriero, *Rome*
Mauro Gacci, *Firenze*
Fabrizio Gallo, *Savona*
Luigi Mearini, *Perugia*
Angelo Naselli, *Castellanza*
Richard Naspro, *Bergamo*
Antonio L Pastore, *Rome*
Daniele Porru, *Pavia*
Matteo A Russo, *Rome*
Giuseppe Simone, *Rome*
Marco Zaffanello, *Verona*

Japan
Shin Egawa, *Tokyo*
Ryuji Inoue, *Fukuoka*
Yoshinori Marunaka, *Kyoto*
Kaijun Niu, *Sendai*
Hitoshi Oh-oka, *Hyogo*
Sunao Shoji, *Tokyo*
Xiuxian Wu, *Kagawa*

Malaysia
Hatta B Sidi, *Kuala*

Mexico
Rubén GC Patiño, *Mexico City*

Netherlands
Tom PVM de Jong, *Utrecht*
Paul J van Diest, *Utrecht*

Pakistan
Ali AA Lanewala, *Karachi*
Muhammed Mubarak, *Karachi*
Abdul M Rana, *Karachi*

Portugal
Paula A Videira, *Lisbon*

Romania
Cristian P Ilie, *Bucharest*

Saudi Arabia
Khalid A Fouda, *Riyadh*
Khaled Madbouly, *Riyadh*
Mohamed M Sayed-Ahmed, *Riyadh*

South Korea
Young B Jeong, *Jeonju*
Kyu-Sung Lee, *Seoul*
Jae-Seung Paick, *Seoul*
Jong H Park, *Seoul*

Spain
Eduardo García-Cruz, *Barcelona*
Federico Soria, *Caceres*

Switzerland
Martin Spahn, *Bern*

Thailand
Ammarin Thakkinstian, *Bangkok*
Viroj Wiwanitkit, *Bangkok*

Turkey
Ismail C Acar, *Denizli*
Mustafa Arici, *Ankara*
Ugur Boylu, *Istanbul*
Gulgun Engin, *Istanbul*
Saadettin Eskicorapci, *Istanbul*
Ates Kadioglu, *Istanbul*
Cevde Kaya, *Istanbul*
Uner Kayabas, *Malatya*
Mehmet Kilinc, *Konya*
Mustafa Sofikerim, *Kayseri*
Ahmet H Tefekli, *Istanbul*
Faruk H Turgut, *Ankara*

United Kingdom
Hashim U Ahmed, *London*
Linda Cardozo, *London*
Ivo I Donkov, *London*
Nilamadhab Kar, *Wolverhampton*
Evangelos Mazaris, *Huntingdon*
Adrien M Peters, *Brighton*
Prasanna Sooriakumaran, *Oxford*

United States
May Abdel-Wahab, *Coral Gables*
Ashok Agarwal, *Tuscaloosa*
Hossam M Ashour, *Detroit*
Kazem Azadzoi, *Boston*
Jennifer Beebe-Dimmer, *Detroit*
Kailash C Chadha, *Buffalo*
James CM Chan, *Portland*
Yan-Hua Chen, *Greenville*
Shih-Chieh J Chueh, *Cleveland*
Christos E Constantinou, *Stanford*
Eva Corey, *Seattle*
Charles J Diskin, *Opelika*
Roger R Dmochowski, *Nashville*
Michael L Eisenberg, *Houston*
Ahmed R El-Nahas, *Mansoura*
Khurshid R Ghani, *Detroit*
Erik T Goluboff, *New York*
Michael P Goodman, *Davis*
Sanjay Gupta, *Cleveland*
Thomas J Guzzo, *Philadelphia*
Samy L Habib, *San Antonio*
Khaled S Hafez, *Ann Arbor*
Guy Hidas, *Orange*
Pleasant F Hooper, *New Orleans*
Michael H Hsieh, *Stanford*
Mitchell R Humphreys, *Phoenix*
Frank P Hurst, *Washington*
Syed A Imam, *Pasadena*
Debra E Irwin, *Chapel Hill*
James Ji, *Tyler*
Robert P Kauffman, *Amarillo*
Hyung L Kim, *Los Angeles*
Shahriar Koochekpour, *New Orleans*
Adam W Levinson, *New York*
Benyi Li, *Kansas City*
Ruisheng Liu, *Jackson*
Deepak K Malhotra, *Toledo*
Michele Meschia, *Memphis*
Arthur Mourtzinos, *Burlington*
Thomas Nelius, *Lubbock*
George J Netto, *Baltimore*
Macaulay Onuigbo, *Eau Claire*
Robert M Perkins, *Danville*
Michael Perrotti, *New York*
Georgi V Petkov, *Columbia*
Selvarangan Ponnazhagan, *Birmingham*
Raj S Pruthi, *Chapel Hill*
Jules B Puschett, *Temple*
Qi Qian, *Rochester*
Sepehr Salem, *Cleveland*

Jack A Schalken, *Nijmegen*
Joseph I Shapiro, *Toledo*
Shahrokh F Shariat, *New York*
James D Stockand, *San Antonio*
Xin Su, *Minneapolis*
Kevin S Thorneloe, *King of Prussia*
Pradeep Tyagi, *Pittsburgh*
Ulka Vaishampayan, *Detroit*
Robert P Woroniecki, *Bronx*
Paul B Yoo, *Durham*
James J Yoo, *Winston-Salem*
Philip G Zager, *Los Alamos*
Stanley Zaslau, *Morgantown*
Bin-Xian Zhang, *San Antonio*
Jiandong Zhang, *Durham*
Jianjun Zhang, *Indianapolis*
Xin-Jin Zhou, *Dallas*
Shougang Zhuang, *Providence*

WJCU World Journal of Clinical Urology

Contents

Four-monthly Volume 5 Number 2 July 24, 2016

EDITORIAL

75 Efficacy and safety of onabotulinum toxin A for overactive bladder

Patel CK, Mourtzinos AP

MINIREVIEWS

80 Does the molecular classification of breast cancer point the way for biomarker identification in prostate cancer?

Green WJF, Ball G, Powe D

World Journal of Clinical Urology
Volume 5 Number 2 July 24, 2016

Contents

ABOUT COVER

Editorial Board Member of *World Journal of Clinical Urology*, Mitchell R Humphreys, MD, Associate Professor, Department of Urology, Mayo Clinic College of Medicine, Phoenix, AZ 85054, United States

AIM AND SCOPE

World Journal of Clinical Urology (*World J Clin Urol*, *WJCU*, online ISSN 2219-2816, DOI: 10.5410) is a peer-reviewed open access academic journal that aims to guide clinical practice and improve diagnostic and therapeutic skills of clinicians.

WJCU covers a variety of clinical medical topics, including genital diseases, urogenital, urogenital abnormalities, urogenital neoplasms, urologic diseases, urogenital surgical procedures, diagnostic imaging, endoscopy, andrology, benign prostatic hyperplasia, urodynamics and urinary dysfunction, incontinence, urinary tract stones, minimally invasive therapy, renal transplantation, urinary reconstruction, evidence-based medicine, and epidemiology.

We encourage authors to submit their manuscripts to *WJCU*. We will give priority to manuscripts that are supported by major national and international foundations and those that are of great clinical significance.

INDEXING/ABSTRACTING

World Journal of Clinical Urology is currently no indexing/abstracting.

FLYLEAF

I-II Editorial Board

EDITORS FOR THIS ISSUE

Responsible Assistant Editor: *Xiang Li*
Responsible Electronic Editor: *Huan-Liang Wu*
Proofing Editor-in-Chief: *Lian-Sheng Ma*
Responsible Science Editor: *Shui Qiu*
Proofing Editorial Office Director: *Xiu-Xia Song*

NAME OF JOURNAL
World Journal of Clinical Urology

ISSN
ISSN 2219-2816 (online)

LAUNCH DATE
December 28, 2011

FREQUENCY
Four-monthly

EDITOR-IN-CHIEF
Makoto Ohori, MD, Professor, Department of Urology, Tokyo Medical University, 6-7-1 Nishi-shinjuku, Shinjuku-ku, Tokyo 160-0023, Japan

EDITORIAL OFFICE
Jin-Lei Wang, Director
Xiu-Xia Song, Vice Director
World Journal of Clinical Urology
Room 903, Building D, Ocean International Center, No. 62 Dongsihuan Zhonglu, Chaoyang District, Beijing 100025, China
Telephone: +86-10-59080039
Fax: +86-10-85381893
E-mail: editorialoffice@wjgnet.com
Help Desk: http://www.wjgnet.com/esps/helpdesk.aspx
http://www.wjgnet.com

PUBLISHER
Baishideng Publishing Group Inc
8226 Regency Drive,
Pleasanton, CA 94588, USA
Telephone: +1-925-223-8242
Fax: +1-925-223-8243
E-mail: bpgoffice@wjgnet.com
Help Desk: http://www.wjgnet.com/esps/helpdesk.aspx
http://www.wjgnet.com

PUBLICATION DATE
July 24, 2016

COPYRIGHT
© 2016 Baishideng Publishing Group Inc. Articles published by this Open Access journal are distributed under the terms of the Creative Commons Attribution Non-commercial License, which permits use, distribution, and reproduction in any medium, provided the original work is properly cited, the use is non commercial and is otherwise in compliance with the license.

SPECIAL STATEMENT
All articles published in journals owned by the Baishideng Publishing Group (BPG) represent the views and opinions of their authors, and not the views, opinions or policies of the BPG, except where otherwise explicitly indicated.

INSTRUCTIONS TO AUTHORS
Full instructions are available online at http://www.wjgnet.com/bpg/gerinfo/204

ONLINE SUBMISSION
http://www.wjgnet.com/esps/

World Journal of Clinical Urology

Submit a Manuscript: http://www.wjgnet.com/esps/
Help Desk: http://www.wjgnet.com/esps/helpdesk.aspx
DOI: 10.5410/wjcu.v5.i2.75

World J Clin Urol 2016 July 24; 5(2): 75-79
ISSN 2219-2816 (online)
© 2016 Baishideng Publishing Group Inc. All rights reserved.

EDITORIAL

Efficacy and safety of onabotulinum toxin A for overactive bladder

Chintan K Patel, Arthur P Mourtzinos

Chintan K Patel, Arthur P Mourtzinos, Institute of Urology, Lahey Hospital and Medical Center, Burlington, MA 01805, United States

Author contributions: Patel CK played an integral role in the conception of the article, acquisition of literature and also drafted the manuscript; Mourtzinos AP is the senior author who reviewed and made critical revisions to the manuscript.

Conflict-of-interest statement: The authors declare no conflicts of interest regarding this manuscript.

Open-Access: This article is an open-access article which was selected by an in-house editor and fully peer-reviewed by external reviewers. It is distributed in accordance with the Creative Commons Attribution Non Commercial (CC BY-NC 4.0) license, which permits others to distribute, remix, adapt, build upon this work non-commercially, and license their derivative works on different terms, provided the original work is properly cited and the use is non-commercial. See: http://creativecommons.org/licenses/by-nc/4.0/

Manuscript source: Invited manuscript

Correspondence to: Chintan K Patel, MD, Resident in Urology, Institute of Urology, Lahey Hospital and Medical Center, 41 Burlington Mall Rd., Burlington, MA 01805, United States. chintan.patel@lahey.org
Telephone: +1-781-7445100

Received: March 17, 2016
Peer-review started: March 19, 2016
First decision: May 17, 2016
Revised: May 26, 2016
Accepted: July 11, 2016
Article in press: July 13, 2016
Published online: July 24, 2016

Abstract

Overactive bladder (OAB) syndrome is a condition which affects 16.9% of women and 16.2% of men with a significant negative impact on quality of life. It is a condition characterized by urgency, with or without urge incontinence, frequency and nocturia. Behavioral modifications and oral anti-muscurinic medications are first and second-line therapies for OAB but are frequently ineffective or poorly tolerated. For refractory cases of OAB, onabotulinum toxin can be offered and this therapy was approved by the Food and Drug Administration in January of 2013. In this editorial, we will review the indications, usage, efficacy and safety data for intradetrusor injection of onabotulinum toxin A.

Key words: Onabotulinum toxin A; Botox; Overactive bladder; Overactive bladder; Neurogenic bladder; Urinary bladder; Detrusor overactivity

© The Author(s) 2016. Published by Baishideng Publishing Group Inc. All rights reserved.

Core tip: Overactive bladder (OAB) remains a highly prevalent and frequently, a recalcitrant constellation of symptoms. For patients who are refractory to oral medical therapy, there is sufficient level I evidence to support the use of onabotulinum toxin A injection therapy. It is a safe and very effective 2nd line treatment for OAB, even in the elderly population. The suggested Food and Drug Administration approved dose is 100 U to maximize the benefits and minimize the adverse effects of this therapy. Risks of the intradetrusor injection of onabotulinum toxin A include urinary tract infection, increased post void residual, urinary retention which may lead to necessity of self catherization for a period of time.

Patel CK, Mourtzinos AP. Efficacy and safety of onabotulinum toxin A for overactive bladder. *World J Clin Urol* 2016; 5(2): 75-79 Available from: URL: http://www.wjgnet.com/2219-2816/full/v5/i2/75.htm DOI: http://dx.doi.org/10.5410/wjcu.v5.i2.75

BACKGROUND

Overactive bladder (OAB) is defined by the International

Continence Society as "urinary urgency, usually accompanied by frequency and nocturia with or without urgency urinary incontinence in the absence of pathological or metabolic conditions that might explain these symptoms"[1]. Based on the National Overactive Bladder Evaluation Program, a validated United States national telephone survey, the overall prevalence of OAB in women is 16.9% and men is 16.2%[2]. OAB negatively impacts work productivity, mental well-being as well as sleep. These patients have significantly lower quality of life (QOL) scores compared to patients without OAB and which can lead to higher levels of depression and anxiety[3,4]. Furthermore, patients with OAB are burdened with time consuming and costly treatments for management of their bothersome symptoms[5]. The American Urological Association and the Society of Urodynamics, Female Pelvic Medicine and Urogenital Reconstruction published a comprehensive evidence-based guideline on the diagnosis and management of OAB in 2012[6]. In this guideline, treatments are recommended in a step-wise, hierarchical fashion. First line therapies consist of behavioral therapy which may consist of bladder training, bladder control strategies, pelvic floor muscle training and fluid management. Complete symptom relief is rarely achieved with behavioral strategies alone but QOL improvement may be seen. Medications are second line therapy and by far, the most common treatment for OAB. Options include oxybutynin, solifenacin, fesoterodine, darifenacin, trospium, tolterodine as well as the newer beta 3 agonists. The side effect profile of these antimuscarinics may vary slightly but overall are very similar and they can be quite bothersome for some patients. Common side effects include dry mouth, constipation, dry eyes, blurred vision, dyspepsia and impaired cognitive function[7]. The cognitive side effects can be further debilitating for the elderly, who represent a significant proportion of patients with OAB. In a study published by Brostom and Hallas[8], the continuation rates of the majority of antimuscarinics at 6 mo was less than 50%. Third line therapies of OAB after failure or discontinuation of second line treatments consist of sacral neuromodulation, peripheral tibial nerve stimulation and intradetrusor injection of onabotulinum toxin A. Intradetrusor injection of onabotulinum toxin A was approved by the Food and Drug Administration (FDA) for the management of OAB in January of 2013. This editorial will focus on the mechanism of action, delivery, efficacy and side effect profile of this therapy.

BOTULINUM TOXIN

Botulinum toxin is a potent neurotoxin produced from a gram positive anaerobic bacterium, Clostridium botulinum, was first isolated by van Ermengem in 1897[9]. Of the specific subtypes, botulinum toxin A has the longest duration of action and is used in clinical medicine[10]. For proper neuromuscular function and release of acetylcholine at the synapse, three proteins are required which make up the soluble N-ethylmaleimide-sensitive factor attachment protein receptor (SNARE) complex. The light chains of the botulinum toxin disrupt the SNARE complex by cleaving the integral proteins responsible for the exocytosis of ACh, specifically synaptobrevin, SNAP-25, and syntaxin, making attachment of the ACh vesicles to the SNARE complex and release of the ACh into the synaptic cleft impossible[11]. Further research is ongoing to further elucidate the mechanism in more detail with several other hypotheses being studied[12,13].

INDICATIONS AND CLINICAL USE FOR ONABOTULINUM TOXIN A

Onabotulinum toxin A was first introduced into urology as a treatment for detrusor external sphincter dyssynergia[14]. Subsequently, the FDA has approved onabotulinum toxin A injections for neurogenic detrusor overactivity as well as OAB. Onabotulinum toxin A is injected into several sites in the bladder wall *via* flexible or rigid cystoscopy in the clinic or ambulatory setting with either general or local anesthesia. Before injecting, the bladder should be filled to ensure adequate visualization. An injection needle is inserted *via* the cystoscope and the onabotulinum toxin A is then injected into the detrusor at multiple sites, usually avoiding the trigone. For an OAB patient, 100 U of onabotulinum toxin A is the approved FDA dose. The 100 U of onabotulinum toxin A is reconstituted in 10 cc of sterile saline and injected into the detrusor muscle just underneath the level of the bladder mucosa. The depth of injection is approximately 2 mm into the detrusor. If the injection site is too superficial, the patient will not have a therapeutic effect, and if placed too deep, the toxin may leak into adjacent structures. Injections can be started in the midline just above the inter-ureteric ridge and then, moving to either direction, at 0.5 cm intervals to the level of the bladder sidewall. Once the initial set of injections is completed, the surgeon can move upward 0.5 to 1 cm and start another series of injections[15]. Maximal effect of the onabotulinum toxin A injection is seen after one week.

EFFICACY OF ONABOTULINUM TOXIN A

The use of onabotulinum toxin A for OAB has been tremendously successful and has revolutionized treatment for this syndrome. Multiple, placebo-controlled, randomized controlled trials have shown that injection of onabotulinum toxin A is superior to placebo in both objective and subjective measurements. One of the earliest of these studies was published by Brubaker *et al*[16]. In their sample size of 43 females, they showed that local injection of 200 U onabotulinum toxin A was an effective and durable treatment for refractory overactive bladder. In 2011, Rovner *et al*[17] randomized 313 patients with OAB to double-blind intradetrusor injection with placebo or 50 to 300 U of onabotulinum

toxin A. They found that changes from baseline in maximum cystometric capacity and volume at first involuntary detrusor contraction in the onabotulinum group were superior to placebo at week 12. Also, they reported continence rates of 16% in the placebo group compared to 30%-57% in the botulinum group. More recently, in 2013, two large scale randomized controlled trials were published which demonstrated onabotulinum toxin A was well tolerated and demonstrated significant and clinically relevant improvement in all aspects of OAB. Chappel *et al*[18] performed a multi-center, double-blind, randomized, placebo-controlled trial with > 270 patients in each arm. The onabotulinum toxin group had significantly decreased urinary incontinence episodes at week 12 as well as reductions from baseline in all other OAB symptoms. They reported clinically meaningful improvements from baseline in all Incontinence Quality of Life (I-QOL) and King's Health Questionnaire (KHQ) multi-item domains indicating a positive impact on health-related quality of life. Nitti *et al*[19] reported the results of another large scale (557 patients), phase 3, placebo-controlled trial of onabotulinum toxin A in patients with OAB and urinary incontinence inadequately managed with anticholinergics. In this cohort, there was a 47.9% reduction in urinary incontinence episodes from baseline in the onabotulinum toxin A group compared to 12.5% in the placebo group. Complete continence was achieved by 22.9% of patients treated with onabotulinum toxin A compared to 6.5% of those receiving placebo. On the treatment benefit scale, 60.8% of patients in the onabotulinum group reported a positive response compared to 29.2% of patients in the placebo group. Statistically significant differences between onabotulinum toxin A and placebo were noted for all of secondary endpoints (decreases from baseline at week 12 in mean micturition, urgency, and nocturia, as well as impact on patient health-related quality of life using I-QOL and KHQ). In summation, all of these high quality studies suggest that intradetrusor injection of onabotulinum toxin A for OAB treatment is associated with significant subjective and objective improvements in OAB refractory to oral medications.

SIDE EFFECTS OF BOTULINUM

The most common adverse effects in trials for onabotulinum toxin A were urinary tract infection (UTI) and urinary retention necessitating clean intermittent catherization. Systemic effects are rarely observed with lower urinary tract injection of onabotulinum toxin A. However, due to its paralytic mechanism, theoretical concerns for systemic adverse effects do remain. Rare cases of generalized weakness have been reported with 300 U of onabotulinum toxin A and the reported duration of such symptoms varies from two weeks to 2 mo[20]. Rates of UTI from published trials range from 3.6% to 54.5% with rates generally increasing in a dose dependent fashion[21]. In a more contemporary, phase Ⅲ, double-blinded study, Nitti *et al*[19] reported an overall UTI rate of 15.5% in the onabotulinum toxin A group in the first 12 wk of the injection. All UTIs were uncomplicated. In our practice, a prophylactic antibiotic is provided to the patient prior to the procedure. Urinary retention is quantified by measuring a post void residual (PVR) and the definition of an elevated PVR varies across studies, with most studies using a threshold of 150 mL. Although elevations in PVR do occur following this procedure, this does not necessitate self catherization in all patients[17,22]. Similar to the rates of UTIs, rates of urinary retention increase in a dose dependent pattern, ranging from 5% to 21.2%. In their study of 278 randomized patients who received onabotulinum toxin A, Nitti *et al*[19] reported a PVR > 200 in 8.7% of patients with an overall rate of self catherization of 6.1%. The duration of urinary retention is variable and the condition can persist for the duration of the effect of the drug as demonstrated by Visco *et al*[23]. In their study of women receiving 100 U of onabotulinum toxin, 5% of women were in retention at 2 mo, 3% at 4 mo and 1% at 6 mo. Furthermore, in patients requiring self catherization, their QOL scores were comparable to those who did not need self catherization[24]. In 2011, Kuo *et al*[25] investigated the risk factors of increasing adverse effects after onabotulinum toxin A injection in 217 patients with refractory idiopathic detrusor overactivity[25]. They performed a multivariate analysis and demonstrated that male gender and baseline PVR of > 100 mL were independent predictors of acute urinary retention. Further studies are needed to better define the risk factors predisposing patients to urinary retention and subsequent self catherization. In patients receiving multiple onabotulinum toxin A injections, their risk for urinary retention remains stable over subsequent injections. Of patients who had a successful first injection, 87% had another retention-free result after their second injection[26]. As our population is aging and due to the considerable cognitive side effects of antimuscuranics, onabotulinum toxin A injection serves as a reasonable alternative in these patients; however, the question arises whether this therapy is safe in the elderly? White *et al*[27] investigated this question and showed that this onbotulinum toxin A therapy is safe and effective in the elderly[27]. In 21 patients with a mean age of 81.2 years, they found that after a single 200 U intradetrusor injection, 76% of patients showed a positive clinical response with no treatment related complications. Liao *et al*[28] performed a larger study in 2013, and subdivided 166 patients into three groups: Frail elderly (61), elderly without frailty (63) and younger than 65 years (42)[28]. Frail elderly was defined as age greater than 65 years and 3 or more of these criteria: Unintentional weight loss, self-reported exhaustion, weakness, slow walking speed and/or low physical activity. Even though they reported a lower long term success and higher PVR in the frail elderly group, they concluded that the safety and efficacy of the therapy was similar between elderly patients without frailty and younger patients. Based on these

above studies, age in itself should not be a deterrent for receiving onabotulinum toxin A injection therapy. Lastly, there have been reports of onabotulinum toxin A resistance in a small percentage of patients undergoing repetitive treatment for non-urological conditions[29]. Concerns of treatment resistance and the role of antibody formation are currently being investigated.

SUMMARY

OAB remains a highly prevalent and frequently, a recalcitrant constellation of symptoms. For patients who are refractory to oral medical therapy, there is sufficient level Ⅰ evidence to support the use of onabotulinum toxin A injection therapy. It is a safe and very effective 2nd line treatment for OAB, even in the elderly population. The suggested FDA-approved dose is 100 U to maximize the benefits and minimize the adverse effects of this therapy. Risks of the intradetrusor injection of onabotulinum toxin A include UTI, increased PVR, urinary retention which may lead to necessity of self catherization for a period of time.

REFERENCES

1 **Haylen BT**, de Ridder D, Freeman RM, Swift SE, Berghmans B, Lee J, Monga A, Petri E, Rizk DE, Sand PK, Schaer GN. An International Urogynecological Association (IUGA)/International Continence Society (ICS) joint report on the terminology for female pelvic floor dysfunction. *Neurourol Urodyn* 2010; **29**: 4-20 [PMID: 19941278 DOI: 10.1002/nau.20798]

2 **Stewart WF**, Van Rooyen JB, Cundiff GW, Abrams P, Herzog AR, Corey R, Hunt TL, Wein AJ. Prevalence and burden of overactive bladder in the United States. *World J Urol* 2003; **20**: 327-336 [PMID: 12811491]

3 **Coyne KS**, Payne C, Bhattacharyya SK, Revicki DA, Thompson C, Corey R, Hunt TL. The impact of urinary urgency and frequency on health-related quality of life in overactive bladder: results from a national community survey. *Value Health* 2004; **7**: 455-463 [PMID: 15449637 DOI: 10.1111/j.1524-4733.2004.74008.x]

4 **Coyne KS**, Wein AJ, Tubaro A, Sexton CC, Thompson CL, Kopp ZS, Aiyer LP. The burden of lower urinary tract symptoms: evaluating the effect of LUTS on health-related quality of life, anxiety and depression: EpiLUTS. *BJU Int* 2009; **103** Suppl 3: 4-11 [PMID: 19302497 DOI: 10.1111/j.1464-410x.2009.08371.x]

5 **Irwin DE**, Mungapen L, Milsom I, Kopp Z, Reeves P, Kelleher C. The economic impact of overactive bladder syndrome in six Western countries. *BJU Int* 2009; **103**: 202-209 [PMID: 19278532 DOI: 10.1111/j.1464-410x.2008.08036.x]

6 **Gormley EA**, Lightner DJ, Burgio KL, Chai TC, Clemens JQ, Culkin DJ, Das AK, Foster HE, Scarpero HM, Tessier CD, Vasavada SP. Diagnosis and treatment of overactive bladder (non-neurogenic) in adults: AUA/SUFU guideline. *J Urol* 2012; **188**: 2455-2463 [PMID: 23098785 DOI: 10.1016/j.juro.2012.09.079]

7 **Chapple CR**, Khullar V, Gabriel Z, Muston D, Bitoun CE, Weinstein D. The effects of antimuscarinic treatments in overactive bladder: an update of a systematic review and meta-analysis. *Eur Urol* 2008; **54**: 543-562 [PMID: 18599186 DOI: 10.1016/j.eururo.2008.06.047]

8 **Brostrøm S**, Hallas J. Persistence of antimuscarinic drug use. *Eur J Clin Pharmacol* 2009; **65**: 309-314 [PMID: 19107469 DOI: 10.1007/s00228-008-0600-9]

9 **van Ermengem E**. Classics in infectious diseases. A new anaerobic bacillus and its relation to botulism. E. van Ermengem. Originally published as "Ueber einen neuen anaëroben Bacillus und seine Beziehungen zum Botulismus" in Zeitschrift für Hygiene und Infektionskrankheiten 26: 1-56, 1897. *Rev Infect Dis* 1979; **1**: 701-719 [PMID: 399378 DOI: 10.1007/bf02220526]

10 **Andersson KE**. New developments in the management of overactive bladder: focus on mirabegron and onabotulinumtoxinA. *Ther Clin Risk Manag* 2013; **9**: 161-170 [PMID: 23637536 DOI: 10.2147/tcrm.s33052]

11 **Chancellor MB**, Fowler CJ, Apostolidis A, de Groat WC, Smith CP, Somogyi GT, Aoki KR. Drug Insight: biological effects of botulinum toxin A in the lower urinary tract. *Nat Clin Pract Urol* 2008; **5**: 319-328 [PMID: 18461049 DOI: 10.1038/ncpuro1124]

12 **Apostolidis A**, Dasgupta P, Fowler CJ. Proposed mechanism for the efficacy of injected botulinum toxin in the treatment of human detrusor overactivity. *Eur Urol* 2006; **49**: 644-650 [PMID: 16426734 DOI: 10.1016/j.eururo.2005.12.010]

13 **Drake MJ**. Mechanisms of action of intravesical botulinum treatment in refractory detrusor overactivity. *BJU Int* 2008; **102** Suppl 1: 11-16 [PMID: 18665973 DOI: 10.1111/j.1464-410x.2008.07822.x]

14 **Dykstra DD**, Sidi AA, Scott AB, Pagel JM, Goldish GD. Effects of botulinum A toxin on detrusor-sphincter dyssynergia in spinal cord injury patients. *J Urol* 1988; **139**: 919-922 [PMID: 3361663]

15 **Shenot PJ**, Mark JR. Intradetrusor onabotulinumtoxinA injection: how I do it. *Can J Urol* 2013; **20**: 6649-6655; discussion 6655 [PMID: 23433140]

16 **Brubaker L**, Richter HE, Visco A, Mahajan S, Nygaard I, Braun TM, Barber MD, Menefee S, Schaffer J, Weber AM, Wei J. Refractory idiopathic urge urinary incontinence and botulinum A injection. *J Urol* 2008; **180**: 217-222 [PMID: 18499184 DOI: 10.1016/j.juro.2008.03.028]

17 **Rovner E**, Kennelly M, Schulte-Baukloh H, Zhou J, Haag-Molkenteller C, Dasgupta P. Urodynamic results and clinical outcomes with intradetrusor injections of onabotulinumtoxinA in a randomized, placebo-controlled dose-finding study in idiopathic overactive bladder. *Neurourol Urodyn* 2011; **30**: 556-562 [PMID: 21351127 DOI: 10.1002/nau.21021]

18 **Chapple C**, Sievert KD, MacDiarmid S, Khullar V, Radziszewski P, Nardo C, Thompson C, Zhou J, Haag-Molkenteller C. OnabotulinumtoxinA 100 U significantly improves all idiopathic overactive bladder symptoms and quality of life in patients with overactive bladder and urinary incontinence: a randomised, double-blind, placebo-controlled trial. *Eur Urol* 2013; **64**: 249-256 [PMID: 23608668 DOI: 10.1016/j.eururo.2013.04.001]

19 **Nitti VW**, Dmochowski R, Herschorn S, Sand P, Thompson C, Nardo C, Yan X, Haag-Molkenteller C. OnabotulinumtoxinA for the treatment of patients with overactive bladder and urinary incontinence: results of a phase 3, randomized, placebo controlled trial. *J Urol* 2013; **189**: 2186-2193 [PMID: 23246476 DOI: 10.1016/j.juro.2012.12.022]

20 **De Laet K**, Wyndaele JJ. Adverse events after botulinum A toxin injection for neurogenic voiding disorders. *Spinal Cord* 2005; **43**: 397-399 [PMID: 15741978 DOI: 10.1038/sj.sc.3101736]

21 **Dmochowski R**, Chapple C, Nitti VW, Chancellor M, Everaert K, Thompson C, Daniell G, Zhou J, Haag-Molkenteller C. Efficacy and safety of onabotulinumtoxinA for idiopathic overactive bladder: a double-blind, placebo controlled, randomized, dose ranging trial. *J Urol* 2010; **184**: 2416-2422 [PMID: 20952013 DOI: 10.1016/j.juro.2010.08.021]

22 **Flynn MK**, Amundsen CL, Perevich M, Liu F, Webster GD. Outcome of a randomized, double-blind, placebo controlled trial of botulinum A toxin for refractory overactive bladder. *J Urol* 2009; **181**: 2608-2615 [PMID: 19375091 DOI: 10.1016/j.juro.2009.01.117]

23 **Visco AG**, Brubaker L, Richter HE, Nygaard I, Paraiso MF, Menefee SA, Schaffer J, Lowder J, Khandwala S, Sirls L, Spino C, Nolen TL, Wallace D, Meikle SF. Anticholinergic therapy vs. onabotulinumtoxina for urgency urinary incontinence. *N Engl J Med* 2012; **367**: 1803-1813 [PMID: 23036134 DOI: 10.1056/nejmoa1208872]

24 **Kessler TM**, Khan S, Panicker J, Roosen A, Elneil S, Fowler CJ. Clean intermittent self-catheterization after botulinum neurotoxin type A injections: short-term effect on quality of life. *Obstet Gynecol* 2009; **113**: 1046-1051 [PMID: 19384119 DOI: 10.1097/

aog.0b013e3181a1f5ea]
25 **Kuo HC**, Liao CH, Chung SD. Adverse events of intravesical botulinum toxin a injections for idiopathic detrusor overactivity: risk factors and influence on treatment outcome. *Eur Urol* 2010; **58**: 919-926 [PMID: 20864251 DOI: 10.1016/j.eururo.2010.09.007]
26 **Khan S**, Kessler TM, Apostolidis A, Kalsi V, Panicker J, Roosen A, Gonzales G, Haslam C, Elneil S, Fowler CJ, Dasgupta P. What a patient with refractory idiopathic detrusor overactivity should know about botulinum neurotoxin type a injection. *J Urol* 2009; **181**: 1773-1778 [PMID: 19233414 DOI: 10.1016/j.juro.2008.11.110]
27 **White WM**, Pickens RB, Doggweiler R, Klein FA. Short-term efficacy of botulinum toxin a for refractory overactive bladder in the elderly population. *J Urol* 2008; **180**: 2522-2526 [PMID: 18930481 DOI: 10.1016/j.juro.2008.08.030]
28 **Liao CH**, Kuo HC. Increased risk of large post-void residual urine and decreased long-term success rate after intravesical onabotulinumtoxinA injection for refractory idiopathic detrusor overactivity. *J Urol* 2013; **189**: 1804-1810 [PMID: 23178902 DOI: 10.1016/j.juro.2012.11.089]
29 **Greene P**, Fahn S, Diamond B. Development of resistance to botulinum toxin type A in patients with torticollis. *Mov Disord* 1994; **9**: 213-217 [PMID: 8196686 DOI: 10.1002/mds.870090216]

P- Reviewer: Ilie CP, Peitsidis P **S- Editor**: Qiu S **L- Editor**: A
E- Editor: Wu HL

World Journal of Clinical Urology

Submit a Manuscript: http://www.wjgnet.com/esps/
Help Desk: http://www.wjgnet.com/esps/helpdesk.aspx
DOI: 10.5410/wjcu.v5.i2.80

World J Clin Urol 2016 July 24; 5(2): 80-89
ISSN 2219-2816 (online)
© 2016 Baishideng Publishing Group Inc. All rights reserved.

MINIREVIEWS

Does the molecular classification of breast cancer point the way for biomarker identification in prostate cancer?

William JF Green, Graham Ball, Des Powe

William JF Green, Department of Urology, Nottingham City Hospital, Nottingham University Hospitals NHS Trust, Nottingham, NG7 2UH, United Kingom

William JF Green, Graham Ball, Des Powe, the John van Geest Cancer Research Centre, Nottingham Trent University, Nottingham, NG11 8NS, United Kingom

Des Powe, Department of Cellular Pathology, Queen's Medical Centre, Nottingham University Hospitals NHS Trust, Nottingham NG7 2UH, United Kingom

Author contributions: Green WJF and Powe D contributed equally to this work, both conceptually and in its authorship; Ball G contributed detailed information on bioinfomatic processes and techniques.

Conflict-of-interest statement: All authors declare no conflict of interest.

Open-Access: This article is an open-access article which was selected by an in-house editor and fully peer-reviewed by external reviewers. It is distributed in accordance with the Creative Commons Attribution Non Commercial (CC BY-NC 4.0) license, which permits others to distribute, remix, adapt, build upon this work non-commercially, and license their derivative works on different terms, provided the original work is properly cited and the use is non-commercial. See: http://creativecommons.org/licenses/by-nc/4.0/

Manuscript source: Invited manuscript

Correspondence to: Dr. Des Powe, PhD, Department of Cellular Pathology, Queen's Medical Centre, Nottingham University Hospitals NHS Trust, Derby Road, Nottingham, NG7 2UH, United Kingom. des.powe@nottingham.ac.uk
Telephone: +44-0115-9249924-63484

Received: April 26, 2016
Peer-review started: April 27, 2016
First decision: June 16, 2016
Revised: June 27, 2016
Accepted: July 11, 2016
Article in press: July 13, 2016
Published online: July 24, 2016

Abstract

There is significant variation in clinical outcome between patients diagnosed with prostate cancer (CaP). Although useful, statistical nomograms and risk stratification tools alone do not always accurately predict an individual's need for and response to treatment. The factors that determine this variation are not fully elucidated. In particular, cellular response to androgen ablation and subsequent paracrine/autocrine adaptation is poorly understood and despite best therapies, median survival in castrate resistant patients is only approximately 35 mo. We propose that one way of understanding this is to look for correlates in other comparable malignancies, such as breast cancer, where markers of at least 4 distinct gene clusters coding for 4 different phenotypic subtypes have been identified. These subtypes have been shown to demonstrate prognostic significance and successfully guide appropriate treatment regimens. In this paper we assess and review the evidence demonstrating parallels in the biology and treatment approach between breast and CaP, and consider the feasibility of patients with CaP being stratified into different molecular classes that could be used to complement prostate specific antigen and histological grading for clinical decision making. We show that there are significant correlations between the molecular classification of breast and CaP and explain how techniques used successfully to predict response to treatment in breast cancer can be applied to the prostate. Molecular phenotyping is possible in CaP and identification of distinct subtypes may allow personalised risk stratification way beyond that currently available.

Key words: Prostate cancer; Molecular classification; Biomarker; Breast cancer; Prognostic

© The Author(s) 2016. Published by Baishideng Publishing Group Inc. All rights reserved.

Core tip: This paper demonstrates that prostate cancer (CaP) has defined molecular subtypes in a similar manner to breast cancer. The molecular classification

and subsequent personalised treatment of breast cancer has revolutionised its management. It is becoming increasingly apparent that the same principles may be applied to CaP, allowing more individualised treatment and informing clinical decision making.

Green WJF, Ball G, Powe D. Does the molecular classification of breast cancer point the way for biomarker identification in prostate cancer? *World J Clin Urol* 2016; 5(2): 80-89 Available from: URL: http://www.wjgnet.com/2219-2816/full/v5/i2/80.htm DOI: http://dx.doi.org/10.5410/wjcu.v5.i2.80

INTRODUCTION

Prostate cancer (CaP) is the most common male malignancy in the United Kingdom with an incidence of 134 per 100000 in 2010[1]. It is the second most common male cancer worldwide[2] and confers significant morbidity and mortality. With rising incidence it is a tremendous health economic burden, with annual expenditure in the United Kingdom of £94.2 million and in the United States of $11.5 billion in 2010 alone[3].

Diagnosis of CaP is based on clinical examination of the prostate, serum prostate specific antigen (PSA) levels and histological Gleason assessment International Society of Urological Pathology consensus[4]. Correlation between these factors and subsequent cancer outcomes has led to the development of well validated risk stratification tools[5] that broadly classify newly diagnosed patients into low (47%), intermediate (38%) and high (15%) risk groups[6,7]. These tools, and meticulously populated nomograms[8,9], continue to inform clinical decision making during the investigation, management and follow up of CaP[10].

However it is increasingly apparent that these tools alone are not sufficient to determine an individual's likelihood of being affected by clinically significant disease, particularly in the large "intermediate" risk group. Some patients require radical treatment but in others their disease is likely to remain indolent, having no demonstrable effect on their quality of life, or indeed life expectancy.

The factors that determine this variation in cancer aggression between patients are not fully elucidated. In particular, cellular response to androgen ablation and subsequent paracrine/autocrine adaptation is poorly understood and despite best therapies, median survival in castrate resistant patients is only approximately 35 mo[11].

CaP is an extremely heterogeneous disease process and further work is required to characterise its complex molecular biological mechanisms and genetic aberrations. This heterogeneity presents obstacles and opportunities for identifying and developing more accurate diagnostic and prognostic tests and new therapeutic avenues. There is now a realisation that CaP has an intricate relationship with its stromal microenvironment[12,13] and it may develop from different progenitor cells resulting in cancers with basal and luminal lineages, leading to divergent disease pathways[14].

One way of approaching this is to look for correlates in other comparable malignancies, such as breast cancer, where at least 4 distinct gene clusters coding for 4 different phenotypic subtypes were identified. These comprise luminal oestrogen receptor (ER) positive, basal [cytokeratin 5/14 positive, ER and human epidermal growth factor receptor 2 (HER2) negative], HER2/neu2 positive, and a "normal-like" phenotype[15]. These phenotypes reflect the tumour cell of origin and cell signalling pathways involved in disease progression and are generally characterised by differing patient outcomes[16-18]. But the biggest impact on survivorship has arguably resulted from advances in targeted adjuvant therapy and use of the humanised antibody, trastuzumab, to inhibit growth and metastasis in patients with cancers expressing HER2[19].

There are similarities in the treatment approach used for CaP, but the repertoire of therapeutic options is more restricted. The mainstay curative treatments for localised CaP are surgical prostatectomy alone or radiotherapy combined with a period of chemical castration involving hormonal-based androgen deprivation therapy (ADT) whose primary purpose is to prevent testosterone-responsive growth in any residual viable tumour cells[20]. However 20%-30% of patients treated for localised CaP will fail therapy and require long term ADT[21]. Unfortunately castrate-refractory disease is essentially inevitable at some point along the disease pathway, associated with poor prognosis due to metastasis formation. Therefore there remains an unmet need to inhibit metastasis formation, possibly resulting from circulating tumour cells[22] or the activation of dormant disseminated tumour cells (DTCs) present at the time of diagnosis[23]. Crucially, it has been proposed that the biology of DTCs is fundamentally different to the primary tumour supporting the need for characterisation of DTCs so that appropriate therapeutic approaches can be designed to successfully neutralise the threat posed by DTCs[24]. Novel combinative strategies that targets the primary and DTCs may be required to achieve significant improvement in treatment success.

The ability to identify those patients at significant risk of disease progression is required to tailor personalised therapy. This review examines the current evidence for biomarkers and their use for assessing disease detection, risk of progression, and prognosis. Moreover, we assess parallels in the biology and treatment approach between breast and CaP, and consider the feasibility of patients with CaP being stratified into different molecular classes that could be used to complement PSA and histological grading for clinical decision making.

PROSTATE EPITHELIAL CELL LINEAGE

Anatomically the prostate has a lobular structure, with

lateral and anterior lobes. However, seminal work by McNeil described a zonal architecture, with each zone demonstrating different characteristics and propensity to develop cancers. Secretory glandular tissue is arranged in ill-defined lobules forming the peripheral and inner periurethral zones. Glands have a papillary architecture and contain three main cellular populations comprising tall luminal columnar epithelial cells that line the approximately 30 prostatic ducts, the smaller basal epithelial cells on which the luminal cells rest and small numbers of neuroendocrine cells within the basal layer[25,26]. In addition, anteriorly is a mixture of smooth muscle and fibrous tissue, the fibromuscular stroma. Maintenance of prostatic epithelium is hormone (testosterone) dependent and in its absence the columnar cells change to a more squat cuboidal form accompanied by a reduction in secretory function.

There is accumulating evidence that malignant potential, disease aggression and prognosis may be determined by the subset of cells the cancer is derived from. The majority of malignancies are thought to develop in epithelial cells located in the peripheral zone, whereas the majority of benign prostatic hyperplasia develops in the transitional zone.

There has been considerable debate as to the cell lineage pathways of prostate epithelium. It is becoming apparent that the basal compartment contains a pool of multipotent stem cells[27-30] that are capable of differentiation into basal and secretory luminal epithelium. These different cellular subtypes can be identified through discrete expression patterns of certain cell surface proteins. For example luminal cells commonly express cytokines (CKs) 8 and 18, whereas basal cells express CK 5 and 14[26]. However, further work has demonstrated an "intermediate" cell type that co-express these markers along with others such as CD24[31]. This intermediate population is believed to represent a transition or amplification stage in the progression from multipotent stem cells to more differentiated basal and luminal epithelium[31].

Further work has shown that human basal cells *in vivo* can be triggered to develop CaP when exposed to common gene mutations[32]. This evidence fits with a hypothesis that stem cells are highly likely to be the origin of CaP as they have an inherent ability to self-renew, and their subsequent longevity provides sufficient time for repeated genetic mutations to finally trigger carcinogenesis.

However, the question remains at which point in the cellular differentiation pathway CaP is initiated. Evidence is growing that there are also populations of luminal cells that retain some stem-cell like qualities, perhaps because they are still "early" in the differentiation phase[33], or because they derive from an entirely separate stem cell population[34,35]. The lineage of prostate epithelial cell development has certainly not yet been fully mapped, and as a result the exact cell, or cells, of origin of CaP remain uncertain. Another unanswered question is whether the cell of origin determines tumour aggression, metastatic potential and likelihood of developing castrate resistance as it has recently been proposed that selective clonal stem cell expansion is associated with CaP aggressiveness[36].

Three clinical stages of CaP progression have been proposed[37]: (1) Low stage/endocrine-driven phase involving androgen receptor (AR) activation by testosterone derived dihydrotestosterone (DHT); (2) Progression stage/paracrine driven phase where AR signalling pathways are still important but different mechanisms are involved to endocrine induced activation. Increased expression of oncogenes (PI3K/Akt) and loss of tumour suppressor (*PTEN*) genes are detected and this stage represents a pathway terminating in metastasis and resistance to ADT (castrate resistance); and (3) Tumour cell autonomy. Here the cancer has adapted to its new environment, e.*g.,* bone tissue, and tumour cell proliferation is independent of AR mediated cell signalling. At this stage, tumours have neuroendocrine features with an acinar to small cell histology phenotype, and show *TMPRSS-ERG* gene fusion[38].

Late stage disease in breast and CaP is characterised by altered ER and AR activity, involving loss of dependence on their natural ligands estrogen and testosterone respectively.

In vitro single cancer cell line models cannot replicate the multi-stage dynamic process involved in cancer cell progression through to metastasis. To overcome this deficiency, models have been refined by the use of co-cultured cell techniques, cancer cell/matrix techniques, or the use of *in vivo* animal models. With the first two approaches, surrogate functional markers of used to assess metastasis potential, comprising cell proliferation and migration.

MOLECULAR CLASSIFICATION OF BREAST CANCER AND THE PARALLELS TO CAP

CaP and breast cancer share a number of characteristics including common genetic, biochemical and growth factors[39]. They are both hormonally manipulated, the stromal microenvironment plays an integral role in each and they are more common in the presence of certain gene mutations such as BRCA1 and BRCA2[40,41]. Clearly, it is important to review the evidence for the existence of different molecular phenotypes in CaP to assess if classification could lead to similar risk profiling and specific targeted therapies utilised in breast cancer.

It is recognised that breast cancer has multiple genetic phenotypes that were initially identified by gene expression profiling (GEP)[15] and hierarchical clustering models to define four molecular classes: Normal breast, luminal (ER positive), basal-like and HER2 (epithelial growth factor receptor 2; ERBB2 gene/neu).

Subsequent work demonstrated further subtypes such as luminal A and B and claudin-low[42].

An important aspect of this work was the association between molecular subtype and cancer specific survival, allowing the development of risk assessment and personalised targeted therapy based on gene/protein expression profiling.

Luminal-like CaP

Similar to breast cancer, over the last decade many studies concluded that CaP derives mainly from terminally differentiated luminal cells, based on the observation that the majority of cancer specimens stained negative for basal cell markers and the cell surface protein p63[43,44]. However, other studies suggest that CaP is by no means a homogenous entity. While the absence of P63 is used as an adjunct in the histological classification of CaP[45] it is however occasionally expressed in CaP tissue, with elevated expression in tissue with higher Gleason scores[44].

AR signalling is critical in the development of normal prostate tissue. Like the estrogen receptor (ER) in breast cancer the AR plays a key role in mediating the various stages of CaP and subsequent castrate resistance. AR "promiscuity" is likely to contribute to this process by triggering transcriptional activation in response to antiandrogens or other endogenous hormones[46].

Development of castrate resistance in advanced CaP is associated with poor clinical outcome. Identifying which patients will succumb is currently a key research objective to aid clinical management and identify novel targets for therapy. The AR receptor and related genes are implicated in the durability of ADT treatment. Fujimura et *al*[47] proposed two panels of gene expression markers for determining clinical failure (defined by PSA recurrence) and cancer specific survival in treatment naïve CaP patients with bone metastasis. They found expression of *Sox2, Her2* and *CRP* in cancer cells to be predictive of clinical failure; panels comprising *Oct1, TRIM36, Sox2 and c-Myc AR*, *Klf4* and *ERα* were found to be prognostic of survival in cancer and stromal cells respectively.

Basal-like CaP

In breast cancer, the basal phenotype has been shown to be associated with more aggressive disease, poor patient outcomes and as yet has no specific targeted treatment[48,49]. The basal phenotype is commonly defined by a lack of expression of ER, progesterone receptor and HER2 and for this reason is referred to as the "triple negative" phenotype. Although the two terms are frequently used interchangeably the basal and triple negative types may actually be 2 distinct groups, albeit with similar poor clinical outcomes[50,51]. In CaP the steroid nuclear AR is expressed in luminal, basal and stromal cells but importantly its regulatory function varies with each cell population. It enhances cell survival in luminal cells, stimulates proliferation and metastases in stromal cells and suppresses proliferation and metastasis in basal cells respectively[52].

There is strong evidence demonstrating the basal phenotype as a cell of origin for some CaPs. Recent work has suggested that genetic signatures commonly associated with embryonic stem cells (ESCs) are up regulated in the tumours of patients with more poorly differentiated CaPs[53,54]. Markert et *al*[53] proposed three stem cell genotypes: (1) ESC; (2) Induced pluripotent stem cells (IPSC); and (3) Polycomb repressive complex-2 (PRC2). Interestingly the same characteristic ESC signature, identified in 13% CaP patients, has been found in high grade breast cancers, particularly the basal subtype[55]. ESC+ CaPs have been associated with loss of p53 and PTEN function, TMPRSS-ERG gene fusion, higher Gleason scores (8-10) and poorer prognosis. An IPSC signature (30% patients) is represented across all Gleason scores, whereas a PRC2 signature (44% patients) was frequently found in patients with a low Gleason cancer. Moreover, the population of phenotypically positive prostate stem cells appears increased in metastatic bone cancer compared to the primary CaP[56]. Colombel et *al*[57] suggest using the putative stem cell markers integrin alpha-2 or -6 in combination with c-met and a 5% cutoff threshold to predict reduced survival associated with bone metastasis. Interestingly, these markers appear to be confined to stem cells localised in the basal cell layer of normal and benign prostate hyperplasia tissue[57].

But contradicting the existence of a pure basal class of CaP is the observation that basal CaP cells tend to lose their basal-defining cell marker characteristics and transform into a more luminal phenotype. However, although appearing histologically homogenous, CaPs still maintain lineage-specific genetic signatures. In contrast to basal-like breast cancer, CaPs retaining a basal phenotype appear to be a rarer event and may actually have a better prognosis than their luminal cell derived counterparts[14]. But, identifying the legacy of basal-transformed cells presents difficulties and limits its clinical usefulness.

HE

HER2 CaPs

Given the similarities between hormonally mediated prostate and breast cancer it is unsurprising that the HER2 oncogene has demonstrated an association with outcome in CaP. HER2 overexpression has been found in approximately 20% of localised, untreated CaPs, and this rises to over 60% in metastatic disease and those cancers treated with ADT, although there is significant variation between studies, based on definition of "overexpression" and also the assay used[58]. Increased expression of HER2 in CaP has been associated with higher Gleason grade, cancer stage and rate of proliferation (as demonstrated by the Ki67 index)[59] and also poorer outcome[60]. However, anti HER2 antibodies such as trastuzumab (Herceptin) that have proven extremely effective in HER2-positive breast cancer has

Table 1 A summary of some of the key similarities between breast and prostate cancer

CaP	Breast cancer
Incidence - 134 per 100000/yr (United Kingdom)	Incidence - 164 per 100000/yr (United Kingdom)
Risks - Increasing age, ethnicity (Black African and Black Caribbean men have highest risk), family history, obesity	Risks - Increasing age, family history, smoking, obesity
AR - Prostate epithelial cells are primarily androgen dependent and AR mutation, promiscuity and hypersensitivity are key stages in cancer progression	AR - Certain subgroups of triple negative breast cancers express the AR. These patients have been shown to have worse prognosis than AR - ve groups
BRCA1 and *BRCA2* - Epidemiological studies have demonstrated a link between breast and CaP within families. However only a small proportion of CaPs can be linked to these gene mutations	*BRACA1* and *BRACA2* - Extremely important genes involved in cell cycle regulation. Responsible for many breast cancers - particularly in younger patients
ESCs - Genetic signatures associated with ESCs have been linked to poorly differentiated CaP. Loss of action of PTEN and P53 and TMPRSS-ERG fusions are frequently observed in these cells	ESC - The ESC signature has recently been demonstrated to be present in some high grade breast cancers
HER2 - The *HER2* oncogene is expressed in 20% of localised CaP. This rises to 60% of metastatic CaP. It has been associated with increased cell proliferation and poorer outcomes in some studies, however the use of anti HER2 antibodies has not demonstrated improved patient outcomes	*HER2* - *HER2* expression has been clearly demonstrated to define a molecular sub group of breast cancer with characteristic survival. An example of early success in the development of "targeted therapy" anti-HER2 antibodies such as trastuzumab (Herceptin) have revolutionised HER2 positive breast cancer treatment

CaP: Prostate cancer; AR: Androgen receptor; BRACA: Breast cancer; ESC: Embryonic stem cell; HER2: Human epidermal growth factor receptor 2.

not shown any clinical efficacy in CaP. Interestingly trastuzumab is most effective in breast cancers in which HER2 overexpression is mediated by gene amplification. In CaP, while HER2 expression is upregulated, gene amplification is uncommon, and thus the target may not be as important in this disease[61].

In summary, breast and CaPs share many common features (see Table 1 for a brief summary of key similarities). Stratification of CaP based on similar principles to that used for the molecular classification of breast cancer may be conceptually possible for the luminal and basal classes but they do not represent the full heterogeneity seen in progressive CaP disease. Based on current academic knowledge and the development of breast cancer therapy, future clinical management of CaP is going to require an individualised approach built on assessment of cell signalling biomarkers that inform about cell functional activity. These will be briefly reviewed.

BIOMARKERS WITH PREDICTIVE AND PROGNOSTIC CAPABILITY

The development and progression of CaP is an extremely complex process involving a varying combination of genetic abnormalities, oxidative stress, cellular inflammation, altered epithelial - stromal interaction and androgen receptor signalling. Previous studies have failed to determine the critical time point when metastasis occurs during carcinogenesis. This could be addressed by prospectively collecting blood samples in patient cohorts pre- and post-diagnosis for CaP to determine the window of opportunity for tumour containment needed for metastasis prevention. Isolation of circulating CaP cells has been shown to be prognostic of survival[22,62], and predictive of disease dissemination[63]. Also, the activation of dormant DTCs and consequential metastasis involves a balance between three opposing processes: Cellular dormancy (mitotic arrest); angiogenic dormancy (vascular-delivered nutrient restriction); and immune-mediated dormancy resulting from immune system cytoxicity[64]. Procedures exist for the isolation of DTCs[65] and biomarkers have been proposed for assessing their functional state.

In breast cancer, early stratification studies of patients using GEP revealed an association between tumour biology genotype, tumour behaviour and response to targeted therapy[15]. This approach has been refined and it is the case that whilst a single biomarker can inform about likely response to targeted therapy (theranostics, e.*g.,* ER status and candidature for tamoxifen treatment), panels of biomarkers are needed to inform about individualised risk of disease progression and survival. Risk assessment can be used to assist chemotherapy decision-making. For example, a 21 multi-gene PCR-based assay (Oncotype DX Breast Cancer Test) was developed for predicting tumour recurrence in tamoxifen treated, node negative, ER expressing breast cancer[66].

The Oncotype DX CaP Test is a multigene PCR-based assay that assesses risk of disease progression in patients with apparent low risk disease. This 17 gene profile assesses 4 distinct biological process targets: The androgen pathway, cellular organisation, proliferation and stromal response[67]. This assay gives a "genomic prostate score" that predicts the likelihood of high grade or high stage disease at diagnosis[68]. This array, like its competitors "Prolaris" and "Decipher" are not yet widely used and a recent systematic review concluded that they have yet to clearly demonstrate any significant advantage over more established predictive nomograms as a general clinical application[62].

Single biomarkers are currently used for diagnostic and predictive assessment of CaP. The most widely used and evidence-based is PSA, a 34 kD serine protease encoded by a gene on chromosome 19 and uniquely

produced by prostate epithelial cells. A raised PSA level can indicate an increased risk of CaP, although presence of other factors such as urinary tract infection and significant lower urinary tract symptoms can cause similar rises. There is no absolute value above which CaP is present, but studies have shown that a PSA of 4 ng/mL confers approximately a 25% risk of cancer[69]. PSA is particularly useful in monitoring response to treatment in CaP because a rise in PSA in a patient who has undergone radical treatment is an early indicator of disease recurrence. Another marker, less widely used and mainly as a diagnostic adjunct, is CaP antigen-3 (PCA3). It is a non-coding segment of mRNA produced by prostate epithelial cells approximately 60 to 100 times more in CaP than benign tissue. The most common assay is marketed as Progensa[70]. Samples for analysis are collected in the urine after prostatic massage and a ratio of PCA3 to PSA mRNA is calculated and a CaP risk is determined.

Assessment of cell proliferation in CaP has received much attention because proliferation is a key requirement for tumour growth and disease progression but is not readily assessed in prostate patients. Unregulated cell turnover occur as a result of genetic abnormalities at all stages of tumour development and can broadly be grouped by where in this pathway they occur. For example, alterations to genes such as[71] ER-1B[72] and NKX3-1[73,74] have been linked to disregulated cell proliferation. Loss or mutation of genes such as HPC1 (codes for the tumour suppressor protein RNaseL) are thought to lead to altered apoptotic processes in response to cellular stress[75,76].

The immunohistochemical Ki67 marker applied to histological tumour sections can be used to detect CaP cells undergoing proliferation (G1, S, G2, and mitosis phase) in conservatively treated patients. Using a cutoff of > 5% cancer nuclei positively stained, Ki67 is prognostic of cancer specific death in tissues derived by trans-urethral resection of prostate[71]. Similar findings were obtained using a 10% nuclei cutoff in diagnostic biopsies[77]. A recent investigation found high (> 6.2%) levels of histologically detected Ki67 were prognostic of disease specific death, metastasis and biochemical failure (rising PSA) in low to intermediate (PSA < 20 ng/mL) patients treated with a combination of short term ADT and radiotherapy[78]. Ki67 is also a component of the cell cycle progression signature proposed by the transatlantic prostate group for independently predicting CaP specific death[79]. We can confirm that immunohistochemical analysis of Ki67 has the potential for providing a cost-effective and robust laboratory technique applicable to routinely processed pathology samples (manuscript submitted: Green et *al,* 2015).

Further important genes implicated in CaP include downregulation of the tumour suppressor gene p53 and deletions/mutations of PTEN (phosphatase and tensin homologue), which acts as a cell cycle regulator. PTEN deletions have been demonstrated in 5% of localised CaP but over 30% of metastatic CaP[80], suggesting it may be an important target in the molecular transition between organ confined and widespread disease.

Transforming growth factor beta (TGF-β) is a protein involved in proliferation and cellular differentiation in many cells and its dysregulation plays an integral part in the development and propagation of CaP. The distal-less homeobox (*DLX)* gene family has been implicated in triggering this dysregulation. The DLX family is a group of six genes that are involved in embryonic development, tissue homeostasis, lymphocyte development, cell cycle and apoptosis. A recent study showed that DLX2 is involved in shifting TGF-β from a tumour suppressor to a tumour promoting function by repressing TGF-βRII and the cell cycle inhibitor p21CIP1, and simultaneously increasing the mitogenic transcription factor c-Myc and epidermal growth factor[81]. The impact of this has been shown to increase tumour growth and metastasis formation in melanoma and lung cancer and work is ongoing to further elucidate the role of DLX2 in CaP[82]. Another key genetic abnormality in CaP is TMPRSS2-ERG fusion, which is found to occur in at least 50% of CaP patients[83]. It has been shown to promote cancer invasion and metastasis and some groups have linked TMPRSS2-ERG fusion to poorer overall prognosis, particularly in those patients in a "watchful waiting" cohort[84]. However, in patients undergoing surgery for their CaP no clear difference in cancer specific survival caused by this gene fusion has yet been demonstrated[85].

Further work employing hierarchical clustering techniques has identified expression of the gene product of Hey2 as being an independent predictor of biochemical failure, local recurrence and distant metastasis in CaP[86]. The same group has demonstrated another gene (CYP4Z1) is an independent predictor of indolent disease.

CONCLUSION

There is a need for more accurate markers of disease outcome in CaP. Currently many patients undergo highly invasive and expensive treatments that carry significant side effects and may have been unnecessary, as their disease would never have become clinically apparent or life threatening. Others will initially be stratified as low or intermediate risk but will subsequently develop highly aggressive disease.

Understanding the cell lineage of CaP and applying the highly successful techniques used in breast cancer research has led to the development of gene signature arrays that reveal different molecular classifications in CaP. Emerging evidence suggests that molecular phenotyping is possible in CaP and identification of distinct subtypes may allow personalised risk stratification way beyond that currently available. This approach needs supporting with the identification and development of treatment regimens directed at theranostic targets, especially in patients assessed as high risk for castrate resistant disease.

While initial results are promising, further work is required to define a robust panel of predictive markers

in CaP; this may involve selection of predictive/prognostic biomarkers that inform about the potential biological behaviour of circulating and DTCs in addition to those detected in the primary organ (prostate). The use of gene expression arrays coupled with bioinformatic techniques has led to the identification of clinically useful multigene PCR assays and protein-based biomarkers. The former are generally more complex and require specialised tissue processing. Protein based assays are mostly applied to routinely processed histological based samples or liquid samples. Currently, all could be used in-conjunction with nomograms and risk algorithms employed by clinicians managing patients with CaP.

REFERENCES

1 **Office for National Statistics**. Cancer Statistics Registrations, England (Series MB1) [Internet] 2013. [accessed 2015 May 3]. Available from: URL: http://www.ons.gov.uk/ons/rel/vsob1/cancer-statistics-registrations--england--series-mb1-/no--42--2011/index.html

2 **Howlader N**, Noone AM, Krapcho M, Garshell J, Miller D, Altekruse SF, Kosary CL, Yu M, Ruhl J, Tatalovich Z,Mariotto A, Lewis DR, Chen HS, Feuer EJ, Cronin KA (eds). SEER Cancer Statistics Review, 1975-2011. Bethesda, MD: National Cancer Institute, 2014

3 **Roehrborn CG**, Black LK. The economic burden of prostate cancer. *BJU Int* 2011; **108**: 806-813 [PMID: 21884356 DOI: 10.1111/j.1464-410X.2011.10365.x]

4 **Epstein JI**, Allsbrook WC, Amin MB, Egevad LL. The 2005 International Society of Urological Pathology (ISUP) Consensus Conference on Gleason Grading of Prostatic Carcinoma. *Am J Surg Pathol* 2005; **29**: 1228-1242 [PMID: 16096414]

5 **D'Amico AV**, Whittington R, Malkowicz SB, Schultz D, Blank K, Broderick GA, Tomaszewski JE, Renshaw AA, Kaplan I, Beard CJ, Wein A. Biochemical outcome after radical prostatectomy, external beam radiation therapy, or interstitial radiation therapy for clinically localized prostate cancer. *JAMA* 1998; **280**: 969-974 [PMID: 9749478]

6 **Korets R**, Motamedinia P, Yeshchina O, Desai M, McKiernan JM. Accuracy of the Kattan nomogram across prostate cancer risk-groups. *BJU Int* 2011; **108**: 56-60 [PMID: 21062396 DOI: 10.1111/j.1464-410X.2010.09838.x]

7 **Cooperberg MR**, Lubeck DP, Mehta SS, Carroll PR. Time trends in clinical risk stratification for prostate cancer: implications for outcomes (data from CaPSURE). *J Urol* 2003; **170**: S21-S25; discussion S21-S25 [PMID: 14610406 DOI: 10.1097/01.ju.0000095025.03331.c6]

8 **Eifler JB**, Feng Z, Lin BM, Partin MT, Humphreys EB, Han M, Epstein JI, Walsh PC, Trock BJ, Partin AW. An updated prostate cancer staging nomogram (Partin tables) based on cases from 2006 to 2011. *BJU Int* 2013; **111**: 22-29 [PMID: 22834909 DOI: 10.1111/j.1464-410X.2012.11324.x]

9 **van Vugt HA**, Roobol MJ, Kranse R, Määttänen L, Finne P, Hugosson J, Bangma CH, Schröder FH, Steyerberg EW. Prediction of prostate cancer in unscreened men: external validation of a risk calculator. *Eur J Cancer* 2011; **47**: 903-909 [PMID: 21163642 DOI: 10.1016/j.ejca.2010.11.012]

10 **Hernandez DJ**, Nielsen ME, Han M, Partin AW. Contemporary evaluation of the D'amico risk classification of prostate cancer. *Urology* 2007; **70**: 931-935 [PMID: 18068450 DOI: 10.1016/j.urology.2007.08.055]

11 **Nakabayashi M**, Hayes J, Taplin ME, Lefebvre P, Lafeuille MH, Pomerantz M, Sweeney C, Duh MS, Kantoff PW. Clinical predictors of survival in men with castration-resistant prostate cancer: evidence that Gleason score 6 cancer can evolve to lethal disease. *Cancer* 2013; **119**: 2990-2998 [PMID: 23719969 DOI: 10.1002/cncr.28102]

12 **Cunha GR**, Hayward SW, Wang YZ, Ricke WA. Role of the stromal microenvironment in carcinogenesis of the prostate. *Int J Cancer* 2003; **107**: 1-10 [PMID: 12925950 DOI: 10.1002/ijc.11335]

13 **Gravina GL**, Mancini A, Ranieri G, Di Pasquale B, Marampon F, Di Clemente L, Ricevuto E, Festuccia C. Phenotypic characterization of human prostatic stromal cells in primary cultures derived from human tissue samples. *Int J Oncol* 2013; **42**: 2116-2122 [PMID: 23589051 DOI: 10.3892/ijo.2013.1892]

14 **Wang ZA**, Mitrofanova A, Bergren SK, Abate-Shen C, Cardiff RD, Califano A, Shen MM. Lineage analysis of basal epithelial cells reveals their unexpected plasticity and supports a cell-of-origin model for prostate cancer heterogeneity. *Nat Cell Biol* 2013; **15**: 274-283 [PMID: 23434823 DOI: 10.1038/ncb2697]

15 **Perou CM**, Sørlie T, Eisen MB, van de Rijn M, Jeffrey SS, Rees CA, Pollack JR, Ross DT, Johnsen H, Akslen LA, Fluge O, Pergamenschikov A, Williams C, Zhu SX, Lønning PE, Børresen-Dale AL, Brown PO, Botstein D. Molecular portraits of human breast tumours. *Nature* 2000; **406**: 747-752 [PMID: 10963602 DOI: 10.1038/35021093]

16 **Perreard L**, Fan C, Quackenbush JF, Mullins M, Gauthier NP, Nelson E, Mone M, Hansen H, Buys SS, Rasmussen K, Orrico AR, Dreher D, Walters R, Parker J, Hu Z, He X, Palazzo JP, Olopade OI, Szabo A, Perou CM, Bernard PS. Classification and risk stratification of invasive breast carcinomas using a real-time quantitative RT-PCR assay. *Breast Cancer Res* 2006; **8**: R23 [PMID: 16626501 DOI: 10.1186/bcr1399]

17 **Romond EH**, Perez EA, Bryant J, Suman VJ, Geyer CE, Davidson NE, Tan-Chiu E, Martino S, Paik S, Kaufman PA, Swain SM, Pisansky TM, Fehrenbacher L, Kutteh LA, Vogel VG, Visscher DW, Yothers G, Jenkins RB, Brown AM, Dakhil SR, Mamounas EP, Lingle WL, Klein PM, Ingle JN, Wolmark N. Trastuzumab plus adjuvant chemotherapy for operable HER2-positive breast cancer. *N Engl J Med* 2005; **353**: 1673-1684 [PMID: 16236738 DOI: 10.1056/NEJMoa052122]

18 **Davies C**, Pan H, Godwin J, Gray R, Arriagada R, Raina V, Abraham M, Medeiros Alencar VH, Badran A, Bonfill X, Bradbury J, Clarke M, Collins R, Davis SR, Delmestri A, Forbes JF, Haddad P, Hou MF, Inbar M, Khaled H, Kielanowska J, Kwan WH, Mathew BS, Mittra I, Müller B, Nicolucci A, Peralta O, Pernas F, Petruzelka L, Pienkowski T, Radhika R, Rajan B, Rubach MT, Tort S, Urrútia G, Valentini M, Wang Y, Peto R. Long-term effects of continuing adjuvant tamoxifen to 10 years versus stopping at 5 years after diagnosis of oestrogen receptor-positive breast cancer: ATLAS, a randomised trial. *Lancet* 2013; **381**: 805-816 [PMID: 23219286 DOI: 10.1016/S0140-6736(12)61963-1]

19 **Dent S**, Oyan B, Honig A, Mano M, Howell S. HER2-targeted therapy in breast cancer: a systematic review of neoadjuvant trials. *Cancer Treat Rev* 2013; **39**: 622-631 [PMID: 23434074 DOI: 10.1016/j.ctrv.2013.01.002]

20 **Heidenreich A**, Bastian PJ, Bellmunt J, Bolla M, Joniau S, van der Kwast T, Mason M, Matveev V, Wiegel T, Zattoni F, Mottet N. EAU guidelines on prostate cancer. part 1: screening, diagnosis, and local treatment with curative intent-update 2013. *Eur Urol* 2014; **65**: 124-137 [PMID: 24207135 DOI: 10.1016/j.eururo.2013.09.046]

21 **Shore ND**, Karsh L, Gomella LG, Keane TE, Concepcion RS, Crawford ED. Avoiding obsolescence in advanced prostate cancer management: a guide for urologists. *BJU Int* 2015; **115**: 188-197 [PMID: 25756134]

22 **Doyen J**, Alix-Panabières C, Hofman P, Parks SK, Chamorey E, Naman H, Hannoun-Lévi JM. Circulating tumor cells in prostate cancer: a potential surrogate marker of survival. *Crit Rev Oncol Hematol* 2012; **81**: 241-256 [PMID: 21680196 DOI: 10.1016/j.critrevonc.2011.05.004]

23 **Sosa MS**, Bragado P, Aguirre-Ghiso JA. Mechanisms of disseminated cancer cell dormancy: an awakening field. *Nat Rev Cancer* 2014; **14**: 611-622 [PMID: 25118602 DOI: 10.1038/nrc3793]

24 **Klein CA**. Selection and adaptation during metastatic cancer progression. *Nature* 2013; **501**: 365-372 [PMID: 24048069 DOI: 10.1038/nature12628]

25 **Ousset M**, Van Keymeulen A, Bouvencourt G, Sharma N, Achouri Y, Simons BD, Blanpain C. Multipotent and unipotent progenitors contribute to prostate postnatal development. *Nat Cell Biol* 2012; **14**: 1131-1138 [PMID: 23064263 DOI: 10.1038/ncb2600]

26 **Shen MM**, Abate-Shen C. Molecular genetics of prostate cancer: new prospects for old challenges. *Genes Dev* 2010; **24**: 1967-2000 [PMID: 20844012 DOI: 10.1101/gad.1965810]

27 **Robinson EJ**, Neal DE, Collins AT. Basal cells are progenitors of luminal cells in primary cultures of differentiating human prostatic epithelium. *Prostate* 1998; **37**: 149-160 [PMID: 9792132]

28 **English HF**, Santen RJ, Isaacs JT. Response of glandular versus basal rat ventral prostatic epithelial cells to androgen withdrawal and replacement. *Prostate* 1987; **11**: 229-242 [PMID: 3684783]

29 **Zhou J**, Feigenbaum L, Yee C, Song H, Yates C. Mouse prostate epithelial luminal cells lineage originate in the basal layer where the primitive stem/early progenitor cells reside: implications for identifying prostate cancer stem cells. *Biomed Res Int* 2013; **2013**: 913179 [PMID: 23819124 DOI: 10.1155/2013/913179]

30 **Blackwood JK**, Williamson SC, Greaves LC, Wilson L, Rigas AC, Sandher R, Pickard RS, Robson CN, Turnbull DM, Taylor RW, Heer R. In situ lineage tracking of human prostatic epithelial stem cell fate reveals a common clonal origin for basal and luminal cells. *J Pathol* 2011; **225**: 181-188 [PMID: 21898876 DOI: 10.1002/path.2965]

31 **Petkova N**, Hennenlotter J, Sobiesiak M, Todenhöfer T, Scharpf M, Stenzl A, Bühring HJ, Schwentner C. Surface CD24 distinguishes between low differentiated and transit-amplifying cells in the basal layer of human prostate. *Prostate* 2013; **73**: 1576-1590 [PMID: 23836489 DOI: 10.1002/pros.22708]

32 **Mulholland DJ**, Xin L, Morim A, Lawson D, Witte O, Wu H. Lin-Sca-1+CD49fhigh stem/progenitors are tumor-initiating cells in the Pten-null prostate cancer model. *Cancer Res* 2009; **69**: 8555-8562 [PMID: 19887604 DOI: 10.1158/0008-5472.CAN-08-4673]

33 **Tsujimura A**, Koikawa Y, Salm S, Takao T, Coetzee S, Moscatelli D, Shapiro E, Lepor H, Sun TT, Wilson EL. Proximal location of mouse prostate epithelial stem cells: a model of prostatic homeostasis. *J Cell Biol* 2002; **157**: 1257-1265 [PMID: 12082083 DOI: 10.1083/jcb.200202067]

34 **Wang X**, Kruithof-de Julio M, Economides KD, Walker D, Yu H, Halili MV, Hu YP, Price SM, Abate-Shen C, Shen MM. A luminal epithelial stem cell that is a cell of origin for prostate cancer. *Nature* 2009; **461**: 495-500 [PMID: 19741607 DOI: 10.1038/nature08361]

35 **Liu J**, Pascal LE, Isharwal S, Metzger D, Ramos Garcia R, Pilch J, Kasper S, Williams K, Basse PH, Nelson JB, Chambon P, Wang Z. Regenerated luminal epithelial cells are derived from preexisting luminal epithelial cells in adult mouse prostate. *Mol Endocrinol* 2011; **25**: 1849-1857 [PMID: 21940754 DOI: 10.1210/me.2011-1081]

36 **Ju X**, Casimiro MC, Gormley M, Meng H, Jiao X, Katiyar S, Crosariol M, Chen K, Wang M, Quong AA, Lisanti MP, Ertel A, Pestell RG. Identification of a cyclin D1 network in prostate cancer that antagonizes epithelial-mesenchymal restraint. *Cancer Res* 2014; **74**: 508-519 [PMID: 24282282 DOI: 10.1158/0008-5472.CAN-13-1313]

37 **Logothetis CJ**, Gallick GE, Maity SN, Kim J, Aparicio A, Efstathiou E, Lin SH. Molecular classification of prostate cancer progression: foundation for marker-driven treatment of prostate cancer. *Cancer Discov* 2013; **3**: 849-861 [PMID: 23811619 DOI: 10.1158/2159-8290.CD-12-0460]

38 **Guo CC**, Wang Y, Xiao L, Troncoso P, Czerniak BA. The relationship of TMPRSS2-ERG gene fusion between primary and metastatic prostate cancers. *Hum Pathol* 2012; **43**: 644-649 [PMID: 21937078 DOI: 10.1016/j.humpath.2011.06.018]

39 **López-Otín C**, Diamandis EP. Breast and prostate cancer: an analysis of common epidemiological, genetic, and biochemical features. *Endocr Rev* 1998; **19**: 365-396 [PMID: 9715372 DOI: 10.1210/edrv.19.4.0337]

40 **Sigurdsson S**, Thorlacius S, Tomasson J, Tryggvadottir L, Benediktsdottir K, Eyfjörd JE, Jonsson E. BRCA2 mutation in Icelandic prostate cancer patients. *J Mol Med* (Berl) 1997; **75**: 758-761 [PMID: 9383000]

41 **Castro E**, Eeles R. The role of BRCA1 and BRCA2 in prostate cancer. *Asian J Androl* 2012; **14**: 409-414 [PMID: 22522501 DOI: 10.1038/aja.2011.150]

42 **Eroles P**, Bosch A, Pérez-Fidalgo JA, Lluch A. Molecular biology in breast cancer: intrinsic subtypes and signaling pathways. *Cancer Treat Rev* 2012; **38**: 698-707 [PMID: 22178455 DOI: 10.1016/j.ctrv.2011.11.005]

43 **Goldstein AS**, Huang J, Guo C, Garraway IP, Witte ON. Identification of a cell of origin for human prostate cancer. *Science* 2010; **329**: 568-571 [PMID: 20671189 DOI: 10.1126/science.1189992]

44 **Parsons JK**, Gage WR, Nelson WG, De Marzo AM. p63 protein expression is rare in prostate adenocarcinoma: implications for cancer diagnosis and carcinogenesis. *Urology* 2001; **58**: 619-624 [PMID: 11597556]

45 **Dabir PD**, Ottosen P, Høyer S, Hamilton-Dutoit S. Comparative analysis of three- and two-antibody cocktails to AMACR and basal cell markers for the immunohistochemical diagnosis of prostate carcinoma. *Diagn Pathol* 2012; **7**: 81 [PMID: 22800084 DOI: 10.1186/1746-1596-7-81]

46 **Heinlein CA**, Chang C. Androgen receptor in prostate cancer. *Endocr Rev* 2004; **25**: 276-308 [PMID: 15082523 DOI: 10.1210/er.2002-0032]

47 **Fujimura T**, Takahashi S, Urano T, Takayama K, Sugihara T, Obinata D, Yamada Y, Kumagai J, Kume H, Ouchi Y, Inoue S, Homma Y. Expression of androgen and estrogen signaling components and stem cell markers to predict cancer progression and cancer-specific survival in patients with metastatic prostate cancer. *Clin Cancer Res* 2014; **20**: 4625-4635 [PMID: 24987058 DOI: 10.1158/1078-0432.CCR-13-1105]

48 **Park S**, Koo JS, Kim MS, Park HS, Lee JS, Lee JS, Kim SI, Park BW. Characteristics and outcomes according to molecular subtypes of breast cancer as classified by a panel of four biomarkers using immunohistochemistry. *Breast* 2012; **21**: 50-57 [PMID: 21865043 DOI: 10.1016/j.breast.2011.07.008]

49 **Banerjee S**, Reis-Filho JS, Ashley S, Steele D, Ashworth A, Lakhani SR, Smith IE. Basal-like breast carcinomas: clinical outcome and response to chemotherapy. *J Clin Pathol* 2006; **59**: 729-735 [PMID: 16556664 DOI: 10.1136/jcp.2005.033043]

50 **Kreike B**, van Kouwenhove M, Horlings H, Weigelt B, Peterse H, Bartelink H, van de Vijver MJ. Gene expression profiling and histopathological characterization of triple-negative/basal-like breast carcinomas. *Breast Cancer Res* 2007; **9**: R65 [PMID: 17910759 DOI: 10.1186/bcr1771]

51 **Rao C**, Shetty J, Prasad KH. Immunohistochemical profile and morphology in triple - negative breast cancers. *J Clin Diagn Res* 2013; **7**: 1361-1365 [PMID: 23998066 DOI: 10.7860/JCDR/2013/5823.3129]

52 **Niu Y**, Chang TM, Yeh S, Ma WL, Wang YZ, Chang C. Differential androgen receptor signals in different cells explain why androgen-deprivation therapy of prostate cancer fails. *Oncogene* 2010; **29**: 3593-3604 [PMID: 20440270 DOI: 10.1038/onc.2010.121]

53 **Markert EK**, Mizuno H, Vazquez A, Levine AJ. Molecular classification of prostate cancer using curated expression signatures. *Proc Natl Acad Sci USA* 2011; **108**: 21276-21281 [PMID: 22123976 DOI: 10.1073/pnas.1117029108]

54 **Rye MB**, Bertilsson H, Drabløs F, Angelsen A, Bathen TF, Tessem MB. Gene signatures ESC, MYC and ERG-fusion are early markers of a potentially dangerous subtype of prostate cancer. *BMC Med Genomics* 2014; **7**: 50 [PMID: 25115192 DOI: 10.1186/1755-8794-7-50]

55 **Ben-Porath I**, Thomson MW, Carey VJ, Ge R, Bell GW, Regev A, Weinberg RA. An embryonic stem cell-like gene expression signature in poorly differentiated aggressive human tumors. *Nat Genet* 2008; **40**: 499-507 [PMID: 18443585 DOI: 10.1038/ng.127]

56 **Eaton CL**, Colombel M, van der Pluijm G, Cecchini M, Wetterwald A, Lippitt J, Rehman I, Hamdy F, Thalman G. Evaluation of the frequency of putative prostate cancer stem cells in primary and metastatic prostate cancer. *Prostate* 2010; **70**: 875-882 [PMID: 20127735 DOI: 10.1002/pros.21121]

57 **Colombel M**, Eaton CL, Hamdy F, Ricci E, van der Pluijm G,

Cecchini M, Mege-Lechevallier F, Clezardin P, Thalmann G. Increased expression of putative cancer stem cell markers in primary prostate cancer is associated with progression of bone metastases. *Prostate* 2012; **72**: 713-720 [PMID: 21882211 DOI: 10.1002/pros.21473]

58 **Scher HI**. HER2 in prostate cancer--a viable target or innocent bystander? *J Natl Cancer Inst* 2000; **92**: 1866-1868 [PMID: 11106669]

59 **Minner S**, Jessen B, Stiedenroth L, Burandt E, Köllermann J, Mirlacher M, Erbersdobler A, Eichelberg C, Fisch M, Brümmendorf TH, Bokemeyer C, Simon R, Steuber T, Graefen M, Huland H, Sauter G, Schlomm T. Low level HER2 overexpression is associated with rapid tumor cell proliferation and poor prognosis in prostate cancer. *Clin Cancer Res* 2010; **16**: 1553-1560 [PMID: 20179235 DOI: 10.1158/1078-0432.CCR-09-2546]

60 **Ahmad I**, Patel R, Singh LB, Nixon C, Seywright M, Barnetson RJ, Brunton VG, Muller WJ, Edwards J, Sansom OJ, Leung HY. HER2 overcomes PTEN (loss)-induced senescence to cause aggressive prostate cancer. *Proc Natl Acad Sci USA* 2011; **108**: 16392-16397 [PMID: 21930937 DOI: 10.1073/pnas.1101263108]

61 **Solit DB**, Rosen N. Targeting HER2 in prostate cancer: where to next? *J Clin Oncol* 2007; **25**: 241-243 [PMID: 17235040 DOI: 10.1200/JCO.2006.08.8187]

62 **Boström PJ**, Bjartell AS, Catto JWF, Eggener SE, Lilja H, Loeb S, Schalken J, Schlomm T, Cooperberg MR. Genomic Predictors of Outcome in Prostate Cancer. *Eur Urol* 2015; **68**: 1033-1044 [PMID: 25913390 DOI: 10.1016/j.eururo.2015.04.008]

63 **Amato RJ**, Melnikova V, Zhang Y, Liu W, Saxena S, Shah PK, Jensen BT, Torres KE, Davis DW. Epithelial cell adhesion molecule-positive circulating tumor cells as predictive biomarker in patients with prostate cancer. *Urology* 2013; **81**: 1303-1307 [PMID: 23622774 DOI: 10.1016/j.urology.2012.10.041]

64 **Aguirre-Ghiso JA**. Models, mechanisms and clinical evidence for cancer dormancy. *Nat Rev Cancer* 2007; **7**: 834-846 [PMID: 17957189 DOI: 10.1038/nrc2256]

65 **Stott SL**, Lee RJ, Nagrath S, Yu M, Miyamoto DT, Ulkus L, Inserra EJ, Ulman M, Springer S, Nakamura Z, Moore AL, Tsukrov DI, Kempner ME, Dahl DM, Wu CL, Iafrate AJ, Smith MR, Tompkins RG, Sequist LV, Toner M, Haber DA, Maheswaran S. Isolation and characterization of circulating tumor cells from patients with localized and metastatic prostate cancer. *Sci Transl Med* 2010; **2**: 25ra23 [PMID: 20424012 DOI: 10.1126/scitranslmed.3000403]

66 **Paik S**, Shak S, Tang G, Kim C, Baker J, Cronin M, Baehner FL, Walker MG, Watson D, Park T, Hiller W, Fisher ER, Wickerham DL, Bryant J, Wolmark N. A multigene assay to predict recurrence of tamoxifen-treated, node-negative breast cancer. *N Engl J Med* 2004; **351**: 2817-2826 [PMID: 15591335 DOI: 10.1056/NEJMoa041588]

67 **Knezevic D**, Goddard AD, Natraj N, Cherbavaz DB, Clark-Langone KM, Snable J, Watson D, Falzarano SM, Magi-Galluzzi C, Klein EA, Quale C. Analytical validation of the Oncotype DX prostate cancer assay - a clinical RT-PCR assay optimized for prostate needle biopsies. *BMC Genomics* 2013; **14**: 690 [PMID: 24103217 DOI: 10.1186/1471-2164-14-690]

68 **Klein EA**, Cooperberg MR, Magi-Galluzzi C, Simko JP, Falzarano SM, Maddala T, Chan JM, Li J, Cowan JE, Tsiatis AC, Cherbavaz DB, Pelham RJ, Tenggara-Hunter I, Baehner FL, Knezevic D, Febbo PG, Shak S, Kattan MW, Lee M, Carroll PR. A 17-gene assay to predict prostate cancer aggressiveness in the context of Gleason grade heterogeneity, tumor multifocality, and biopsy undersampling. *Eur Urol* 2014; **66**: 550-560 [PMID: 24836057 DOI: 10.1016/j.eururo.2014.05.004]

69 **Thompson IM**, Pauler DK, Goodman PJ, Tangen CM, Lucia MS, Parnes HL, Minasian LM, Ford LG, Lippman SM, Crawford ED, Crowley JJ, Coltman CA. Prevalence of prostate cancer among men with a prostate-specific antigen level & lt; or =4.0 ng per milliliter. *N Engl J Med* 2004; **350**: 2239-2246 [PMID: 15163773 DOI: 10.1056/NEJMoa031918]

70 **de la Taille A**. Progensa PCA3 test for prostate cancer detection. *Expert Rev Mol Diagn* 2007; **7**: 491-497 [PMID: 17892357 DOI: 10.1586/14737159.7.5.491]

71 **Berney DM**, Gopalan A, Kudahetti S, Fisher G, Ambroisine L, Foster CS, Reuter V, Eastham J, Moller H, Kattan MW, Gerald W, Cooper C, Scardino P, Cuzick J. Ki-67 and outcome in clinically localised prostate cancer: analysis of conservatively treated prostate cancer patients from the Trans-Atlantic Prostate Group study. *Br J Cancer* 2009; **100**: 888-893 [PMID: 19293807 DOI: 10.1038/sj.bjc.6604951]

72 **Dey P**, Jonsson P, Hartman J, Williams C, Ström A, Gustafsson JÅ. Estrogen receptors β1 and β2 have opposing roles in regulating proliferation and bone metastasis genes in the prostate cancer cell line PC3. *Mol Endocrinol* 2012; **26**: 1991-2003 [PMID: 23028063 DOI: 10.1210/me.2012.1227]

73 **Ren S**, Kang MR, Wang J, Huang V, Place RF, Sun Y, Li LC. Targeted induction of endogenous NKX3-1 by small activating RNA inhibits prostate tumor growth. *Prostate* 2013; **73**: 1591-1601 [PMID: 23836514 DOI: 10.1002/pros.22709]

74 **Wang P**, Ma Q, Luo J, Liu B, Tan F, Zhang Z, Chen Z. Nkx3.1 and p27(KIP1) cooperate in proliferation inhibition and apoptosis induction in human androgen-independent prostate cancer cells. *Cancer Invest* 2009; **27**: 369-375 [PMID: 19266349 DOI: 10.1080/07357900802232749]

75 **Shand RL**, Gelmann EP. Molecular biology of prostate-cancer pathogenesis. *Curr Opin Urol* 2006; **16**: 123-131 [PMID: 16679847 DOI: 10.1097/01.mou.0000193384.39351.64]

76 **Malathi K**, Paranjape JM, Ganapathi R, Silverman RH. HPC1/RNASEL mediates apoptosis of prostate cancer cells treated with 2',5'-oligoadenylates, topoisomerase I inhibitors, and tumor necrosis factor-related apoptosis-inducing ligand. *Cancer Res* 2004; **64**: 9144-9151 [PMID: 15604285 DOI: 10.1158/0008-5472.CAN-04-2226]

77 **Fisher G**, Yang ZH, Kudahetti S, Møller H, Scardino P, Cuzick J, Berney DM. Prognostic value of Ki-67 for prostate cancer death in a conservatively managed cohort. *Br J Cancer* 2013; **108**: 271-277 [PMID: 23329234 DOI: 10.1038/bjc.2012.598]

78 **Verhoven B**, Yan Y, Ritter M, Khor LY, Hammond E, Jones C, Amin M, Bahary JP, Zeitzer K, Pollack A. Ki-67 is an independent predictor of metastasis and cause-specific mortality for prostate cancer patients treated on Radiation Therapy Oncology Group (RTOG) 94-08. *Int J Radiat Oncol Biol Phys* 2013; **86**: 317-323 [PMID: 23474109 DOI: 10.1016/j.ijrobp.2013.01.016]

79 **Cuzick J**, Berney DM, Fisher G, Mesher D, Møller H, Reid JE, Perry M, Park J, Younus A, Gutin A, Foster CS, Scardino P, Lanchbury JS, Stone S. Prognostic value of a cell cycle progression signature for prostate cancer death in a conservatively managed needle biopsy cohort. *Br J Cancer* 2012; **106**: 1095-1099 [PMID: 22361632 DOI: 10.1038/bjc.2012.39]

80 **Karayi MK**, Markham AF. Molecular biology of prostate cancer. *Prostate Cancer Prostatic Dis* 2004; **7**: 6-20 [PMID: 14999233 DOI: 10.1038/sj.pcan.4500697]

81 **Yilmaz M**, Maass D, Tiwari N, Waldmeier L, Schmidt P, Lehembre F, Christofori G. Transcription factor Dlx2 protects from TGFβ-induced cell-cycle arrest and apoptosis. *EMBO J* 2011; **30**: 4489-4499 [PMID: 21897365 DOI: 10.1038/emboj.2011.319]

82 **Buczek ME**, Miles AK, Green W, Johnson C, Boocock DJ, Pockley AG, Rees RC, Hulman G, van Schalkwyk G, Parkinson R, Hulman J, Powe DG, Regad T. Cytoplasmic PML promotes TGF-β-associated epithelial-mesenchymal transition and invasion in prostate cancer. *Oncogene* 2016; **35**: 3465-3475 [PMID: 26549027 DOI: 10.1038/onc.2015.409]

83 **Tomlins SA**, Rhodes DR, Perner S, Dhanasekaran SM, Mehra R, Sun XW, Varambally S, Cao X, Tchinda J, Kuefer R, Lee C, Montie JE, Shah RB, Pienta KJ, Rubin MA, Chinnaiyan AM. Recurrent fusion of TMPRSS2 and ETS transcription factor genes in prostate cancer. *Science* 2005; **310**: 644-648 [PMID: 16254181 DOI: 10.1126/science.1117679]

84 **Demichelis F**, Fall K, Perner S, Andrén O, Schmidt F, Setlur SR, Hoshida Y, Mosquera JM, Pawitan Y, Lee C, Adami HO, Mucci LA, Kantoff PW, Andersson SO, Chinnaiyan AM, Johansson JE, Rubin MA. TMPRSS2: ERG gene fusion associated with lethal prostate cancer in a watchful waiting cohort. *Oncogene* 2007; **26**: 4596-4599 [PMID: 17237811 DOI: 10.1038/sj.onc.1210237]

85 **Rubio-Briones J**, Fernández-Serra A, Calatrava A, García-Casado Z, Rubio L, Bonillo MA, Iborra I, Solsona E, López-Guerrero JA. Clinical implications of TMPRSS2-ERG gene fusion expression in patients with prostate cancer treated with radical prostatectomy. *J Urol* 2010; **183**: 2054-2061 [PMID: 20303538 DOI: 10.1016/j.juro.2009.12.096]

86 **Tradonsky A**, Rubin T, Beck R, Ring B, Seitz R, Mair S. A search for reliable molecular markers of prognosis in prostate cancer: a study of 240 cases. *Am J Clin Pathol* 2012; **137**: 918-930 [PMID: 22586051 DOI: 10.1309/AJCPF3QWIG8FWXIH]

P- **Reviewer:** Cihan YB, Ghatak S, Huang SP, Shao R S- **Editor:** Ji FF
L- **Editor:** A E- **Editor:** Wu HL

Published by **Baishideng Publishing Group Inc**
8226 Regency Drive, Pleasanton, CA 94588, USA
Telephone: +1-925-223-8242
Fax: +1-925-223-8243
E-mail: bpgoffice@wjgnet.com
Help Desk: http://www.wjgnet.com/esps/helpdesk.aspx
http://www.wjgnet.com

© 2016 Baishideng Publishing Group Inc. All rights reserved.

ISSN 2219-2816 (online)

World Journal of *Clinical Urology*

World J Clin Urol 2016 November 24; 5(3): 90-96

Published by Baishideng Publishing Group Inc

WJCU World Journal of Clinical Urology

A peer-reviewed, online, open-access journal of clinical urology

Editorial Board

2016-2019

The *World Journal of Clinical Urology* Editorial Board consists of 201 members, representing a team of worldwide experts in urology. They are from 32 countries, including Australia (2), Austria (1), Belgium (2), Brazil (4), Canada (2), Chile (1), China (19) , Czech Republic (1), Egypt (7), France (3), Germany (7), Greece (7), Hungary (1), India (3), Iran (1), Israel (4), Italy (20), Japan (8), Malaysia (1), Mexico (1), Netherlands (2), Pakistan (3), Portugal (1), Romania (1), Saudi Arabia (3), South Korea (4), Spain (2), Switzerland (1), Thailand (2), Turkey (12), United Kingdom (7), and United States (68).

EDITOR-IN-CHIEF
Makoto Ohori, *Tokyo*

ASSOCIATE EDITOR
Riccardo Schiavina, *Bologna*

GUEST EDITORIAL BOARD MEMBERS
Yen-Ching Chen, *Taipei*
How-Ran Guo, *Tainan*
Kuo-How Huang, *Taipei*
Hung-Hsiang Liou, *Taipei*
Shing-Hwa Lu, *Taipei*
Shih-Bin Su, *Tainan*
Ya-Chung Tian, *Linkou*

MEMBERS OF THE EDITORIAL BOARD

Australia
Nathan Lawrentschuk, *Heidelberg*
Henry H Woo, *Sydney*

Austria
Paul F Engelhardt, *Baden*

Belgium
Dirk PJ Michielsen, *Brussels*
Koenraad Van Renterghem, *Hasselt*

Brazil
Fernando Korkes, *Sao Paulo*
Sonia M Oliani, *Sao Paulo*
Ernani L Rhoden, *Porto Alegre*
Nestor Schor, *Sao Paulo*

Canada
Ben H Chew, *Vancouver*
Fernand Labrie, *Quebec*

Chile
Juan P Valdevenito, *Santiago*

China
Jiang-Hua Chen, *Hangzhou*
Xiang-Mei Chen, *Beijing*
Xue-Zhong Gong, *Shanghai*
Willmann Liang, *Hong Kong*
Xiu-Juan Liu, *Nanchang*
Chi-Fai Ng, *Hong Kong*
Gao Song, *Yangzhou*
Chi-Wai Tang, *Hong Kong*
Yan-Qing Tong, *Changchun*
Gao-Si Xu, Nanchang
Gao-Zhong Xu, Changchun
Yue-Min Xu, Shanghai

Czech Republic
Jiri Sedy, *Prague*

Egypt
Bedeir Ali-El-Dein, *Mansoura*
Sanaa Eissa Mohamed Hamed, *Cairo*
Ahmed MA El-Assmy, *Mansoura*
Ahmed I El-Sakka, *Ismailia*
Ihab A Hekal, *Mansoura*
Salwa I Mohammed, *Cairo*
Hassan S Shaker, *Cairo*

France
Alexandre de la Taille, *Creteil*
Stephane Larre, *Reims Cedex*
Stéphane Oudard, *Paris*

Germany
Michael Froehner, *Dresden*
Oliver W Hakenberg, *Rostock*
Thomas RW Herrmann, *Hanover*
Florian Lang, *Tuebingen*
Daniela Marschall-Kehrel, *Frankfurt*
Axel S Merseburger, *Lübeck*
Hossein Tezval, *Hannover*

Greece
George A Barbalias, *Melissia*
Dimitrios A Kirmizis, *Thessaloniki*
Evangelos N Liatsikos, *Rio Patras*
Aikaterini Papagianni, *Thessaloniki*
Athanasios G Papatsoris, *Athens*
Panagiotis Peitsidis, *Athens*
Giorgos K Sakkas, *Thessaly*

Hungary
Peter Tenke, *Budapest*

India
John Samuel Banerji, *Vellore*
Manisha Sahay, *Hyderabad*
Pratap B Singh, *Delhi*

Iran
Ahmad R Dehpour, *Tehran*

Israel
Juza Chen, *Tel-Aviv*
Ofer N Gofrit, *Jerusalem*
Inna Sinuani, *Zerifin*
Ofer Yossepowitch, *Petah Tiqwa*

Italy
Giuseppe Brisinda, *Rome*
Tommaso Cai, *Trento*
Alessandro Calisti, *Rome*
Stefano Ciatto, *Valeggio sul Mincio*
Elisabetta Costantini, *Perugia*
Paolo Cravedi, *Ranica Bergamo*
Massimiliano Creta, *Naples*
Vassilos Fanos, *Cagliari*
Mariaconsiglia Ferriero, *Rome*
Mauro Gacci, *Firenze*
Fabrizio Gallo, *Savona*
Luigi Mearini, *Perugia*
Angelo Naselli, *Castellanza*
Richard Naspro, *Bergamo*
Antonio L Pastore, *Rome*
Daniele Porru, *Pavia*
Matteo A Russo, *Rome*
Giuseppe Simone, *Rome*
Marco Zaffanello, *Verona*

Japan
Shin Egawa, *Tokyo*
Ryuji Inoue, *Fukuoka*
Yoshinori Marunaka, *Kyoto*
Kaijun Niu, *Sendai*
Hitoshi Oh-oka, *Hyogo*
Sunao Shoji, *Tokyo*
Xiuxian Wu, *Kagawa*

Malaysia
Hatta B Sidi, *Kuala*

Mexico
Rubén GC Patiño, *Mexico City*

Netherlands
Tom PVM de Jong, *Utrecht*
Paul J van Diest, *Utrecht*

Pakistan
Ali AA Lanewala, *Karachi*
Muhammed Mubarak, *Karachi*
Abdul M Rana, *Karachi*

Portugal
Paula A Videira, *Lisbon*

Romania
Cristian P Ilie, *Bucharest*

Saudi Arabia
Khalid A Fouda, *Riyadh*
Khaled Madbouly, *Riyadh*
Mohamed M Sayed-Ahmed, *Riyadh*

South Korea
Young B Jeong, *Jeonju*
Kyu-Sung Lee, *Seoul*
Jae-Seung Paick, *Seoul*
Jong H Park, *Seoul*

Spain
Eduardo García-Cruz, *Barcelona*
Federico Soria, *Caceres*

Switzerland
Martin Spahn, *Bern*

Thailand
Ammarin Thakkinstian, *Bangkok*
Viroj Wiwanitkit, *Bangkok*

Turkey
Ismail C Acar, *Denizli*
Mustafa Arici, *Ankara*
Ugur Boylu, *Istanbul*
Gulgun Engin, *Istanbul*
Saadettin Eskicorapci, *Istanbul*
Ates Kadioglu, *Istanbul*
Cevde Kaya, *Istanbul*
Uner Kayabas, *Malatya*
Mehmet Kilinc, *Konya*
Mustafa Sofikerim, *Kayseri*
Ahmet H Tefekli, *Istanbul*
Faruk H Turgut, *Ankara*

United Kingdom
Hashim U Ahmed, *London*
Linda Cardozo, *London*
Ivo I Donkov, *London*
Nilamadhab Kar, *Wolverhampton*
Evangelos Mazaris, *Huntingdon*
Adrien M Peters, *Brighton*
Prasanna Sooriakumaran, *Oxford*

United States
May Abdel-Wahab, *Coral Gables*
Ashok Agarwal, *Tuscaloosa*
Hossam M Ashour, *Detroit*
Kazem Azadzoi, *Boston*
Jennifer Beebe-Dimmer, *Detroit*
Kailash C Chadha, *Buffalo*
James CM Chan, *Portland*
Yan-Hua Chen, *Greenville*
Shih-Chieh J Chueh, *Cleveland*
Christos E Constantinou, *Stanford*
Eva Corey, *Seattle*
Charles J Diskin, *Opelika*
Roger R Dmochowski, *Nashville*
Michael L Eisenberg, *Houston*
Ahmed R El-Nahas, *Mansoura*
Khurshid R Ghani, *Detroit*
Erik T Goluboff, *New York*
Michael P Goodman, *Davis*
Sanjay Gupta, *Cleveland*
Thomas J Guzzo, *Philadelphia*
Samy L Habib, *San Antonio*
Khaled S Hafez, *Ann Arbor*
Guy Hidas, *Orange*
Pleasant F Hooper, *New Orleans*
Michael H Hsieh, *Stanford*
Mitchell R Humphreys, *Phoenix*
Frank P Hurst, *Washington*
Syed A Imam, *Pasadena*
Debra E Irwin, *Chapel Hill*
James Ji, *Tyler*
Robert P Kauffman, *Amarillo*
Hyung L Kim, *Los Angeles*
Shahriar Koochekpour, *New Orleans*
Adam W Levinson, *New York*
Benyi Li, *Kansas City*
Ruisheng Liu, *Jackson*
Deepak K Malhotra, *Toledo*
Michele Meschia, *Memphis*
Arthur Mourtzinos, *Burlington*
Thomas Nelius, *Lubbock*
George J Netto, *Baltimore*
Macaulay Onuigbo, *Eau Claire*
Robert M Perkins, *Danville*
Michael Perrotti, *New York*
Georgi V Petkov, *Columbia*
Selvarangan Ponnazhagan, *Birmingham*
Raj S Pruthi, *Chapel Hill*
Jules B Puschett, *Temple*
Qi Qian, *Rochester*
Sepehr Salem, *Cleveland*

Jack A Schalken, *Nijmegen*
Joseph I Shapiro, *Toledo*
Shahrokh F Shariat, *New York*
James D Stockand, *San Antonio*
Xin Su, *Minneapolis*
Kevin S Thorneloe, *King of Prussia*
Pradeep Tyagi, *Pittsburgh*
Ulka Vaishampayan, *Detroit*
Robert P Woroniecki, *Bronx*
Paul B Yoo, *Durham*
James J Yoo, *Winston-Salem*
Philip G Zager, *Los Alamos*
Stanley Zaslau, *Morgantown*
Bin-Xian Zhang, *San Antonio*
Jiandong Zhang, *Durham*
Jianjun Zhang, *Indianapolis*
Xin-Jin Zhou, *Dallas*
Shougang Zhuang, *Providence*

WJCU World Journal of Clinical Urology

Contents

Four-monthly Volume 5 Number 3 November 24, 2016

EDITORIAL

90 Enuresis and sleep disordered breathing: An old and new link

Zaffanello M

CASE REPORT

93 Splenunculi mimicking metastases in a patient with locally advanced prostate cancer

Foreman D, Plagakis SA

World Journal of Clinical Urology
Volume 5 Number 3 November 24, 2016

Contents

ABOUT COVER

Editorial Board Member of *World Journal of Clinical Urology*, Ruisheng Liu, MD, PhD, Associate Professor, Director, Department of Physiology and Biophysics, University of Mississippi Medical Center, Jackson, MS 39216, United States

AIM AND SCOPE

World Journal of Clinical Urology (*World J Clin Urol*, *WJCU*, online ISSN 2219-2816, DOI: 10.5410) is a peer-reviewed open access academic journal that aims to guide clinical practice and improve diagnostic and therapeutic skills of clinicians.

WJCU covers a variety of clinical medical topics, including genital diseases, urogenital, urogenital abnormalities, urogenital neoplasms, urologic diseases, urogenital surgical procedures, diagnostic imaging, endoscopy, andrology, benign prostatic hyperplasia, urodynamics and urinary dysfunction, incontinence, urinary tract stones, minimally invasive therapy, renal transplantation, urinary reconstruction, evidence-based medicine, and epidemiology.

We encourage authors to submit their manuscripts to *WJCU*. We will give priority to manuscripts that are supported by major national and international foundations and those that are of great clinical significance.

INDEXING/ABSTRACTING

World Journal of Clinical Urology is now indexed in China National Knowledge Infrastructure (CNKI).

FLYLEAF

I-III Editorial Board

EDITORS FOR THIS ISSUE

Responsible Assistant Editor: *Xiang Li*
Responsible Electronic Editor: *Dan Li*
Proofing Editor-in-Chief: *Lian-Sheng Ma*
Responsible Science Editor: *Shui Qiu*
Proofing Editorial Office Director: *Xiu-Xia Song*

NAME OF JOURNAL
World Journal of Clinical Urology

ISSN
ISSN 2219-2816 (online)

LAUNCH DATE
December 28, 2011

FREQUENCY
Four-monthly

EDITOR-IN-CHIEF
Makoto Ohori, MD, Professor, Department of Urology, Tokyo Medical University, 6-7-1 Nishi-shinjuku, Shinjuku-ku, Tokyo 160-0023, Japan

EDITORIAL BOARD MEMBERS
All editorial board members resources online at http://www.wjgnet.com/2219-2816/editorialboard.htm

EDITORIAL OFFICE
Xiu-Xia Song, Director
Fang-Fang Ji, Vice Director
World Journal of Clinical Urology
Baishideng Publishing Group Inc
8226 Regency Drive, Pleasanton, CA 94588, USA
Telephone: +1-925-2238242
Fax: +1-925-2238243
E-mail: editorialoffice@wjgnet.com
Help Desk: http://www.wjgnet.com/esps/helpdesk.aspx
http://www.wjgnet.com

PUBLISHER
Baishideng Publishing Group Inc
8226 Regency Drive,
Pleasanton, CA 94588, USA
Telephone: +1-925-2238242
Fax: +1-925-2238243
E-mail: bpgoffice@wjgnet.com
Help Desk: http://www.wjgnet.com/esps/helpdesk.aspx
http://www.wjgnet.com

PUBLICATION DATE
November 24, 2016

COPYRIGHT
© 2016 Baishideng Publishing Group Inc. Articles published by this Open Access journal are distributed under the terms of the Creative Commons Attribution Non-commercial License, which permits use, distribution, and reproduction in any medium, provided the original work is properly cited, the use is non commercial and is otherwise in compliance with the license.

SPECIAL STATEMENT
All articles published in journals owned by the Baishideng Publishing Group (BPG) represent the views and opinions of their authors, and not the views, opinions or policies of the BPG, except where otherwise explicitly indicated.

INSTRUCTIONS TO AUTHORS
http://www.wjgnet.com/bpg/gerinfo/204

ONLINE SUBMISSION
http://www.wjgnet.com/esps/

World Journal of Clinical Urology

Submit a Manuscript: http://www.wjgnet.com/esps/
Help Desk: http://www.wjgnet.com/esps/helpdesk.aspx
DOI: 10.5410/wjcu.v5.i3.90

World J Clin Urol 2016 November 24; 5(3): 90-92
ISSN 2219-2816 (online)
© 2016 Baishideng Publishing Group Inc. All rights reserved.

EDITORIAL

Enuresis and sleep disordered breathing: An old and new link

Marco Zaffanello

Marco Zaffanello, Department of Surgical Sciences, Dentistry, Gynecology and Pediatrics, Division of Pediatric, University of Verona, 37134 Verona, Italy

Author contributions: Zaffanello M solely finished this manuscript.

Conflict-of-interest statement: None declared.

Open-Access: This article is an open-access article which was selected by an in-house editor and fully peer-reviewed by external reviewers. It is distributed in accordance with the Creative Commons Attribution Non Commercial (CC BY-NC 4.0) license, which permits others to distribute, remix, adapt, build upon this work non-commercially, and license their derivative works on different terms, provided the original work is properly cited and the use is non-commercial. See: http://creativecommons.org/licenses/by-nc/4.0/

Manuscript source: Invited manuscript

Correspondence to: Marco Zaffanello, MD, Department of Surgical Sciences, Dentistry, Gynecology and Pediatrics, Division of Pediatric, University of Verona, Piazzale L.A. Scuro, 10, 37134 Verona, Italy. marco.zaffanello@univr.it
Telephone: +39-45-8124381
Fax: +39-45-8124790

Received: April 5, 2016
Peer-review started: April 8, 2016
First decision: May 19, 2106
Revised: July 30, 2016
Accepted: August 30, 2016
Article in press: August 31, 2016
Published online: November 24, 2016

Abstract

The causes of nocturnal enuresis (NE) are likely multifactorial. It has been related to several (urological-nephrological-hormonal) reasons but clear and univocal pathogenesis remains mostly undetermined. Sleep disordered breathing (SDB) is a syndrome of upper airway dysfunction that occurs during sleep and is characterized by snoring and/or increased respiratory effort secondary to increased upper airway resistance and pharyngeal collapsibility. Adenotonsillar hypertrophy is the main cause of SDB in children. To date, several studies have associated childhood NE with coexistent SDB. Adenotonsillectomy was successful for both SDB and NE in about half of patients. Unfortunately, practical consensus guidelines for the management of primary NE do not mention, or marginally concern, SDB in these children, particularly in those who have treatment resistance and comorbidities. The concerns regard the concomitant presence of two relatively frequent sleep disorders, raising the question whether they are really coincidental problems of childhood.

Key words: Children; Sleep disordered breathing; Enuresis

© The Author(s) 2016. Published by Baishideng Publishing Group Inc. All rights reserved.

Core tip: Several studies have pointed out the high frequency of sleep disordered breathing (SDB) in children with nocturnal enuresis (NE), particularly refractory (medication resistant) or secondary. Practical consensus guidelines for NE, corroborated by recent investigation of the topics, need to be revisited considering the high recurrence of SDB in childhood NE and a high success rate of intervention for it.

Zaffanello M. Enuresis and sleep disordered breathing: An old and new link. *World J Clin Urol* 2016; 5(3): 90-92 Available from: URL: http://www.wjgnet.com/2219-2816/full/v5/i3/90.htm
DOI: http://dx.doi.org/10.5410/wjcu.v5.i3.90

INTRODUCTION

Nocturnal enuresis (NE) is a frequent problem in pediatrics. The age related prevalence is between 2%-15%[1,2]. NE is characterized by intermittent incontinence that

occurs exclusively during sleep in children who are at least 5 years old[1,3]. There are two subtypes, monosymptomatic NE and nonmonosymptomatic NE, according to the absence or presence of lower urinary tract and bladder dysfunction[1]. Furthermore, primary NE (PNE) and secondary NE applies to children who have not achieved a previous dry period or who have had a previous dry period of almost 6 mo, respectively[3].

NE has been related to several (urological-nephrological-hormonal) conditions[4], but clear and univocal pathogenesis remains mostly undetermined[5].

Sleep disordered breathing (SDB) is a syndrome of upper airway dysfunction occurring during sleep and characterized by snoring and/or increased respiratory effort secondary to increased upper airway resistance and pharyngeal collapsibility. About 40 years ago, Guilleminault *et al*[6] included NE among various symptoms of adulthood SDB. The same authors observed that in completely toilet trained children, bedwetting reappeared contemporary to the development of obstructive sleep apnea syndrome (OSAS), similar to that seen in adults[6]. OSAS is characterized by witnessed apnea, unrefreshing sleep and excessive daytime sleepiness[7]. The prevalence of OSAS in childhood is approximately 0.7%-3%[8,9]. Adenotonsillar hypertrophy is the main cause of SDB in children[10].

To date, several studies have associated childhood NE with coexistent SDB[11,12]. In investigations for an association between asthma and SDB, enuretic children were 5.34 times more prone to have apnea reported by parents[13]. By using a subjective instrument, enuretic children showed a high comorbidity with other sleep disturbances, like SDB and parasomnias[14]. Moreover, among 87 patients with MNE, a family history of NE was diagnosed in 91% and constipation in 89%. Interestingly, mild/moderate apnea was found in 41% and severe sleep apnea in 7%[15]. NE and SDB[16,17] are urological and respiratory conditions, respectively associated with sleep. Increased brain natriuretic peptide (BNP) levels may account for the increased prevalence of enuresis in the context of SDB[18].

NE has been reported in 8%-47% of children with SDB, mainly attributable to adenotonsillar hypertrophy[18,19]. Complete resolution of NE has been reported in 31%-76% of OSAS children within months of adenotonsillectomy[20,21]. Adenotonsillectomy was successful in both NE and SDB in about half of patients[22]. Recently, Park *et al*[23] reported that there was a strong association between NE and obstructive SDB, and adenotonsillectomy markedly improved NE in the majority of children. Accordingly, plasma antidiuretic hormone and BNP normalized post intervention[24]. Moreover, resolution has been reported successfully after rapid maxillary expansion in 50% of patients after 1 mo of treatment[25], and after nasal budesonide in two patients[26].

The causes of NE are likely multifactorial[15]. Unfortunately, practical consensus guidelines for the management of PNE do not mention[27], or marginally concern, SDB in children with NE, particularly in those who have treatment resistance and comorbidities[28]. The concerns regard the concomitant presence of two relatively frequent sleep disorders, raising the question whether they are really incidental problems of childhood. Hormonal normalization after surgery highlights the suspicions that they might be linked. Furthermore, various studies reported a success rate of surgical intervention in several bedwetting patients. The question is whether spontaneous resolution of NE is concerned in some OSAS patients, when a not-early resolution is observed post treatment.

In children with NE, validated questionnaires are important tools to screen for SDB, although with weak predictive value[29,30]; urologist/general practitioner may detect the problem and refer the patients to otolaryngology or sleep medicine evaluation.

In conclusion, several studies have pointed out the high frequency of SDB in children with NE raising the questions whether: (1) children with NE without clinical evidence of SDB can be firstly treated with standard treatment for NE; (2) children with NE and clinical evidence of SDB need to be investigated and treated firstly for OSAS; (3) children with refractory (medication resistant) and secondary NE need to be investigated for underlying and subclinical sleep respiratory problems; and (4) polysomnography should be included for a more comprehensive evaluation of bedwetting children included in point 2 and 3.

REFERENCES

1 **Nevéus T**, von Gontard A, Hoebeke P, Hjälmås K, Bauer S, Bower W, Jørgensen TM, Rittig S, Walle JV, Yeung CK, Djurhuus JC. The standardization of terminology of lower urinary tract function in children and adolescents: report from the Standardisation Committee of the International Children's Continence Society. *J Urol* 2006; **176**: 314-324 [PMID: 16753432 DOI: 10.1016/S0022-5347(06)00305-3]

2 **Hjalmas K**, Arnold T, Bower W, Caione P, Chiozza LM, von Gontard A, Han SW, Husman DA, Kawauchi A, LAckgren G, Lottmann H, Mark S, Rittig S, Robson L, Walle JV, Yeung CK. Nocturnal enuresis: an international evidence based management strategy. *J Urol* 2004; **171**: 2545-2561 [PMID: 15118418 DOI: 10.1097/01.ju.0000111504.85822.b2]

3 **Austin PF**, Bauer SB, Bower W, Chase J, Franco I, Hoebeke P, Rittig S, Vande Walle J, von Gontard A, Wright A, Yang SS, Nevéus T. The standardization of terminology of lower urinary tract function in children and adolescents: update report from the Standardization Committee of the International Children's Continence Society. *J Urol* 2014; **191**: 1863-1865.e13 [PMID: 24508614 DOI: 10.1016/j.juro.2014.01.110]

4 **Nevéus T**. Diagnosis and management of nocturnal enuresis. *Curr Opin Pediatr* 2009; **21**: 199-202 [PMID: 19307899 DOI: 10.1097/MOP.0b013e3283229b12]

5 **Robson WL**. Clinical practice. Evaluation and management of enuresis. *N Engl J Med* 2009; **360**: 1429-1436 [PMID: 19339722 DOI: 10.1056/NEJMcp0808009]

6 **Guilleminault C**, Eldridge FL, Tilkian A, Simmons FB, Dement WC. Sleep apnea syndrome due to upper airway obstruction: a review of 25 cases. *Arch Intern Med* 1977; **137**: 296-300 [PMID: 557314 DOI: 10.1001/archinte.137.3.296]

7 **Kaditis AG**, Alonso Alvarez ML, Boudewyns A, Alexopoulos EI, Ersu R, Joosten K, Larramona H, Miano S, Narang I, Trang H, Tsaoussoglou M, Vandenbussche N, Villa MP, Van Waardenburg D, Weber S, Verhulst S. Obstructive sleep disordered breathing in

2- to 18-year-old children: diagnosis and management. *Eur Respir J* 2016; **47**: 69-94 [PMID: 26541535 DOI: 10.1183/13993003.00385-2015]

8 **Lumeng JC**, Chervin RD. Epidemiology of pediatric obstructive sleep apnea. *Proc Am Thorac Soc* 2008; **5**: 242-252 [PMID: 18250218 DOI: 10.1513/pats.200708-135MG]

9 **Montgomery-Downs HE**, O'Brien LM, Holbrook CR, Gozal D. Snoring and sleep-disordered breathing in young children: subjective and objective correlates. *Sleep* 2004; **27**: 87-94 [PMID: 14998242]

10 **Burg CJ**, Friedman NR. Diagnosis and treatment of sleep apnea in adolescents. *Adolesc Med State Art Rev* 2010; **21**: 457-479, viii [PMID: 21302855]

11 **Goodwin JL**, Kaemingk KL, Fregosi RF, Rosen GM, Morgan WJ, Smith T, Quan SF. Parasomnias and sleep disordered breathing in Caucasian and Hispanic children - the Tucson children's assessment of sleep apnea study. *BMC Med* 2004; **2**: 14 [PMID: 15115546 DOI: 10.1186/1741-7015-2-14]

12 **Brooks LJ**. Enuresis and sleep apnea. *Pediatrics* 2005; **116**: 799-800; author reply 800 [PMID: 16140728 DOI: 10.1542/peds.2005-1261]

13 **Dahan P**, de Bessa J, de Oliveira DM, Gomes CC, Cardoso JC, Macedo IT, de Almeida Belo M, de Figueiredo AA, Netto JM. Association between Asthma and Primary Nocturnal Enuresis in Children. *J Urol* 2016; **195**: 1221-1226 [PMID: 26926555 DOI: 10.1016/j.juro.2015.10.081]

14 **Azevedo Soster L**, Alves R, Fagundes SN, Koch VH, Bruni O. Sleep disturbances associated with sleep enuresis: A questionnaire study. *Eur J Paediatr Neurol* 2016; **20**: 282-285 [PMID: 26732069 DOI: 10.1016/j.ejpn.2015.11.014]

15 **Nascimento Fagundes S**, Azevedo Soster L, Lebl AS, Rodrigues Pereira RP, Tanaka C, Pereira RF, Ferreira de Mattos Silvares E, Koch VH. Impact of a multidisciplinary evaluation in pediatric patients with nocturnal monosymptomatic enuresis. *Pediatr Nephrol* 2016; **31**: 1295-1303 [PMID: 26913724 DOI: 10.1007/s00467-016-3316-6]

16 **Cohen-Zrubavel V**, Kushnir B, Kushnir J, Sadeh A. Sleep and sleepiness in children with nocturnal enuresis. *Sleep* 2011; **34**: 191-194 [PMID: 21286252]

17 **Tauman R**, O'Brien LM, Holbrook CR, Gozal D. Sleep pressure score: a new index of sleep disruption in snoring children. *Sleep* 2004; **27**: 274-278 [PMID: 15124722]

18 **Stone J**, Malone PS, Atwill D, McGrigor V, Hill CM. Symptoms of sleep-disordered breathing in children with nocturnal enuresis. *J Pediatr Urol* 2008; **4**: 197-202 [PMID: 18631925 DOI: 10.1016/j.jpurol.2007.11.011]

19 **Basha S**, Bialowas C, Ende K, Szeremeta W. Effectiveness of adenotonsillectomy in the resolution of nocturnal enuresis secondary to obstructive sleep apnea. *Laryngoscope* 2005; **115**: 1101-1103 [PMID: 15933530 DOI: 10.1097/01.MLG.0000163762.13870.83]

20 **Firoozi F**, Batniji R, Aslan AR, Longhurst PA, Kogan BA. Resolution of diurnal incontinence and nocturnal enuresis after adenotonsillectomy in children. *J Urol* 2006; **175**: 1885-1888; discussion 1888 [PMID: 16600788 DOI: 10.1016/S0022-5347(05)00935-3]

21 **Leiberman A**, Stiller-Timor L, Tarasiuk A, Tal A. The effect of adenotonsillectomy on children suffering from obstructive sleep apnea syndrome (OSAS): the Negev perspective. *Int J Pediatr Otorhinolaryngol* 2006; **70**: 1675-1682 [PMID: 16854471 DOI: 10.1016/j.ijporl.2006.06.002]

22 **Kovacevic L**, Wolfe-Christensen C, Lu H, Toton M, Mirkovic J, Thottam PJ, Abdulhamid I, Madgy D, Lakshmanan Y. Why does adenotonsillectomy not correct enuresis in all children with sleep disordered breathing? *J Urol* 2014; **191**: 1592-1596 [PMID: 24679871 DOI: 10.1016/j.juro.2013.10.032]

23 **Park S**, Lee JM, Sim CS, Kim JG, Nam JG, Lee TH, Han MW, Kwon JK, Lee JC. Impact of adenotonsillectomy on nocturnal enuresis in children with sleep-disordered breathing: A prospective study. *Laryngoscope* 2016; **126**: 1241-1245 [PMID: 26928519 DOI: 10.1002/lary.25934]

24 **Kovacevic L**, Lu H, Wolfe-Christensen C, Abdulhamid I, Thottam PJ, Lulgjuraj M, Madgy DN, Lakshmanan Y. Adenotonsillectomy Normalizes Hormones and Urinary Electrolytes in Children With Nocturnal Enuresis and Sleep-Disordered Breathing. *Urology* 2015; **86**: 158-161 [PMID: 26142600 DOI: 10.1016/j.urology.2015.04.011]

25 **Schütz-Fransson U**, Kurol J. Rapid maxillary expansion effects on nocturnal enuresis in children: a follow-up study. *Angle Orthod* 2008; **78**: 201-208 [PMID: 18251602 DOI: 10.2319/021407-71.1]

26 **Alexopoulos EI**, Kaditis AG, Kostadima E, Gourgoulianis K. Resolution of nocturnal enuresis in snoring children after treatment with nasal budesonide. *Urology* 2005; **66**: 194 [PMID: 15961142 DOI: 10.1016/j.urology.2005.01.021]

27 **Vande Walle J**, Rittig S, Bauer S, Eggert P, Marschall-Kehrel D, Tekgul S. Practical consensus guidelines for the management of enuresis. *Eur J Pediatr* 2012; **171**: 971-983 [PMID: 22362256 DOI: 10.1007/s00431-012-1687-7]

28 **Marcus CL**, Brooks LJ, Draper KA, Gozal D, Halbower AC, Jones J, Schechter MS, Sheldon SH, Spruyt K, Ward SD, Lehmann C, Shiffman RN. Diagnosis and management of childhood obstructive sleep apnea syndrome. *Pediatrics* 2012; **130**: 576-584 [PMID: 22926173 DOI: 10.1542/peds.2012-1671]

29 **Walter LM**, Biggs SN, Cikor N, Rowe K, Davey MJ, Horne RS, Nixon GM. The efficacy of the OSA-18 as a waiting list triage tool for OSA in children. *Sleep Breath* 2016; **20**: 837-844 [PMID: 26669876 DOI: 10.1007/s11325-015-1289-5]

30 **Rosen CL**, Wang R, Taylor HG, Marcus CL, Katz ES, Paruthi S, Arens R, Muzumdar H, Garetz SL, Mitchell RB, Jones D, Weng J, Ellenberg S, Redline S, Chervin RD. Utility of symptoms to predict treatment outcomes in obstructive sleep apnea syndrome. *Pediatrics* 2015; **135**: e662-e671 [PMID: 25667240 DOI: 10.1542/peds.2014-3099]

P- Reviewer: Azadzoi K, Metcalfe PD, Sakkas G **S- Editor**: Kong JX
L- Editor: A **E- Editor**: Li D

World Journal of Clinical Urology

Submit a Manuscript: http://www.wjgnet.com/esps/
Help Desk: http://www.wjgnet.com/esps/helpdesk.aspx
DOI: 10.5410/wjcu.v5.i3.93

World J Clin Urol 2016 November 24; 5(3): 93-96
ISSN 2219-2816 (online)
© 2016 Baishideng Publishing Group Inc. All rights reserved.

CASE REPORT

Splenunculi mimicking metastases in a patient with locally advanced prostate cancer

Darren Foreman, Sophie A Plagakis

Darren Foreman, Department of Urology, Flinders Medical Centre, Flinders University, Adelaide, SA 5042, Australia

Darren Foreman, Discipline of Surgery, Adelaide University, Adelaide, SA 5000, Australia

Sophie A Plagakis, Department of Urology, Royal Adelaide Hospital, Adelaide, SA 5000, Australia

Author contributions: This manuscript was drafted by both Foreman D and Plagakis SA, with the final revisions being made by Plagakis SA.

Institutional review board statement: This case report was exempt from the Institutional Review Board standards at Flinders University.

Informed consent statement: The patient gave informed verbal consent for the use of his medical details in this publication.

Conflict-of-interest statement: There were no conflicts of interest in this study.

Open-Access: This article is an open-access article which was selected by an in-house editor and fully peer-reviewed by external reviewers. It is distributed in accordance with the Creative Commons Attribution Non Commercial (CC BY-NC 4.0) license, which permits others to distribute, remix, adapt, build upon this work non-commercially, and license their derivative works on different terms, provided the original work is properly cited and the use is non-commercial. See: http://creativecommons.org/licenses/by-nc/4.0/

Manuscript source: Invited manuscript

Correspondence to: Darren Foreman, Consultant Urologist, Department of Urology, Flinders Medical Centre, Flinders University, Flinders Drive, Bedford Park, Adelaide, SA 5042, Australia. dforeman@sturology.com.au
Telephone: +61-08-82045511
Fax: +61-08-82045450

Received: July 19, 2016
Peer-review started: July 21, 2016
First decision: September 5, 2016
Revised: September 21, 2016
Accepted: October 22, 2016
Article in press: October 24, 2016
Published online: November 24, 2016

Abstract

A 61-year-old man with locally advanced prostate cancer was found to have multiple solid intra-abdominal solid lesions during staging investigations. While some were in the pelvis, they were not located in the common landing sites for prostate cancer metastases, and his prostate specific antigen was not significantly elevated to suggest a high burden of metastatic disease. He reported a history of a blunt abdominal trauma due to a motor vehicle accident more than forty years ago which had been conservatively managed. His staging imaging revealed a lack of a discrete spleen in his left upper abdomen and this raised the suspicion that these solid lesions may represent ectopic splenic tissue. Imaging with nuclear medicine scintigraphy confirmed the lesions in his upper abdomen and pelvis to be splenunculi. He proceeded with a combination of androgen deprivation therapy and external beam radiotherapy for locally advanced, non-metastatic prostate cancer. Although it has been described in patients with low risk prostate cancer, this is the first case report of splenunculi mimicking metastases in a patient with locally advanced prostate cancer.

Key words: Prostate cancer; Splenosis; Metastasis; Locally advanced; Splenunculus

© The Author(s) 2016. Published by Baishideng Publishing Group Inc. All rights reserved.

Core tip: The appearance of ectopic splenic tissue in the abdomen and other body cavities can mimic that of solid tissue tumours and metastases. Splenosis may occur following blunt abdominal trauma during which a splenic

injury may or may not have been identified and is rarely symptomatic. Being aware of this unusual differential diagnosis may avoid anxiety for patients and allow early diagnosis. Nuclear medicine scintigraphy with Tc-99m is the imaging modality of choice to confirm splenunculi.

Foreman D, Plagakis SA. Splenunculi mimicking metastases in a patient with locally advanced prostate cancer. *World J Clin Urol* 2016; 5(3): 93-96 Available from: URL: http://www.wjgnet.com/2219-2816/full/v5/i3/93.htm DOI: http://dx.doi.org/10.5410/wjcu.v5.i3.93

INTRODUCTION

Splenosis is the autotransplantation of splenic tissue and formation of scattered tissue deposits secondary to abdominal trauma or splenectomy. It is a benign condition that is generally asymptomatic with a reported incidence of up to 67% of people who have sustained an abdominal injury[1,2]. Due to increasing rates of abdominal imaging, these cases are now seen more often and the unexpected findings have been mistaken for metastatic disease and hepatoma, as reported in the literature.

CASE REPORT

We present a case of a 61-year-old man with newly diagnosed locally advanced, high risk prostate cancer, with multiple intra-abdominal masses initially mistaken for metastatic disease. This patient was referred to a Urologist with a prostate specific antigen (PSA) of 6.6 ng/mL. He had no significant medical or family history, apart from being involved in a motor vehicle accident at 18 years of age. The accident involved side impact, and he spent three days in hospital for observation but did not undergo surgery. There was no imaging available from that previous admission.

Digital rectal examination found a generally firm and suspicious feeling prostate gland, and trans-rectal ultrasound (TRUS) showed no hypoechoic lesions. TRUS guided prostate biopsy was performed and revealed a large volume of Gleason 4 + 3 = 7 disease occupying 80%-90% of all cores. The specimen from the right base showed extra-prostatic extension of disease, confirming pathological staging as T3.

Staging investigations included a computed tomography (CT) scan of the abdomen and pelvis, whole body bone scan (WBBS) and magnetic resonance imaging (MRI) of the pelvis. WBBS did not reveal any bony abnormalities or metastases. CT showed a 2.4 cm lesion between the liver and right kidney and a 3.4 cm lesion between the bladder and rectum, just superior to the seminal vesicles (Figure 1). The lesions were solid and enhanced with intravenous contrast. There was no discrete spleen in the left upper quadrant, however multiple small lesions lay in this region measuring up to 2 cm in diameter each (Figure 2). There was no pelvic or para-aortic lymphadenopathy present. MRI demonstrated disease within the prostate and no gross extraprostatic extension was present. The MRI clearly displayed the pelvic lesion superior to the seminal vesicles, which was not attached to surrounding structures.

Due to suspicion of ectopic splenic tissue, a heat-damaged radioisotope-labelled red cell scan (99mTc) was performed. All of the lesions seen on CT demonstrated intense tracer uptake and confirmed the presence of multiple intra-abdominal splenunculi (Figure 3), and excluded abdominal metastatic disease.

Following discussion of treatment options for locally advanced, high risk, non metastatic prostate, the patient elected to undergo external beam radiotherapy in combination with 24 mo of androgen deprivation therapy (ADT).

A PSA rise occurred 21 mo after ADT finished, and the patient required intermittent ADT since then. It has been 8 years since diagnosis and the patient is currently off ADT with no metastatic disease on cross sectional imaging and has a PSA of 0.8 ng/mL.

DISCUSSION

Splenosis is believed to result from the spillage of cells from the splenic pulp during surgical manipulation or following splenic injury. It is reported to develop over an average of 10 years following the insult, and is more common following trauma than iatrogenic causes[3].

The cells can implant in any other location and take their blood supply from surrounding structures; splenosis has been reported as intrathoracic where there is a concomitant diaphragmatic injury or intra-hepatic following an emergency splenectomy for trauma[4,5]. The pathogenesis is generally accepted to be mechanical implantation of cells, however there are case reports of intracranial splenic deposits from purported haematological spread[6].

Whilst it is assumed to be functional splenic tissue, splenosis usually does not have the histological appearance of normal spleen, nor does it form a hilum or a mature capsule. Patients are rarely symptomatic and the condition is most often discovered incidentally on abdominal imaging.

This is distinct from an accessory spleen which is congenital and arises from the left side of the dorsal mesogastrium. These deposits are usually found in the region of the gastosplenic ligament or splenopancreatic ligaments, commonly solitary, and if multiple hardly ever exceed six. They are histologically and functionally normal splenic tissue and usually have their own blood supply derived from the splenic artery. They are also usually asymptomatic, but there have been reports of torted accessory spleens and migratory deposits on long vascular pedicles.

The most useful imaging modality by far for investigation of splenosis is nuclear medicine scintigraphy. This can be performed using the agents Technichium-99 sulphur colloid, Technichium-99 heat-damaged erythrocytes

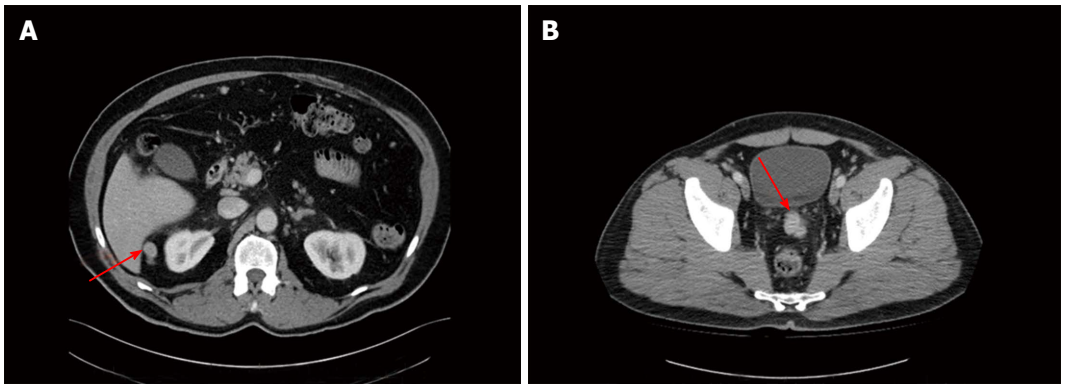

Figure 1 Axial computed tomography image of the abdomen. A: Red arrow pointing to soft tissue mass in between liver and right kidney; B: Red arrow pointing to soft tissue mass between bladder and rectum.

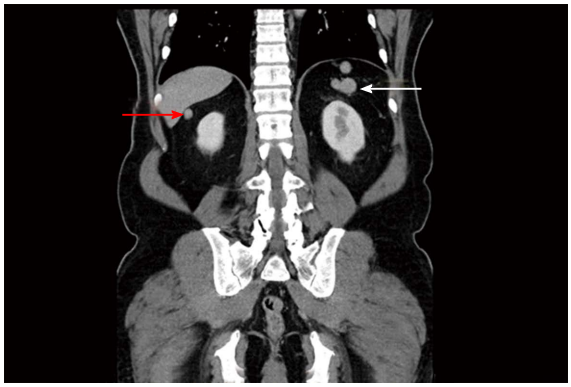

Figure 2 Coronal computed tomography image of the pelvis. White arrow pointing to nodular soft tissue mass in left upper quadrant, where discrete spleen was not visualised; red arrow pointing to soft tissue mass beneath liver.

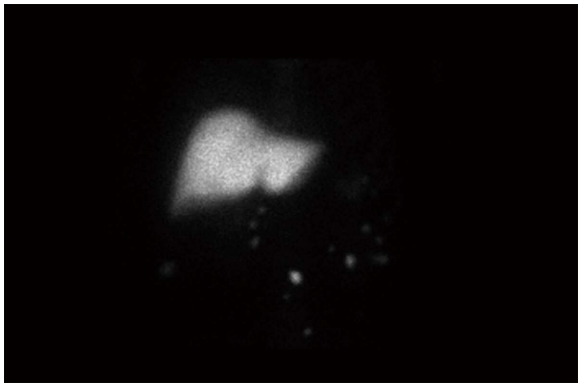

Figure 3 Nuclear scintigraphy image of this patient demonstrating uptake in the ectopic tissue seen in the pelvis and beneath the liver on the computed tomography images, confirming they are ectopic splenic tissue. Liver shows normal tracer uptake.

or Indium-111 labelled platelets. These agents are widely distributed in the reticuloendothelial system including the liver, bone marrow and spleen. Tc-99m and In-111 labelled platelets are the most sensitive and specific agents for the detection of ectopic splenic tissue[7,8]. If nuclear scintigraphy is not available or conclusive, the option of percutaneous biopsy of the masses can be pursued but this is often challenging given the varying size and location of the masses.

Multiple published case reports describe the initial misdiagnosis of splenosis as solid tumours, metastases or recurrences for breast, renal, colorectal and hepatocellular cancers, to name a few[9-12].

Prostate cancer has been reported once in the literature in this context, in a patient with low grade disease that should not have undergone further imaging according to staging guidelines[13]. This is the first report of splenosis in a patient with high risk prostate cancer.

The presence of splenosis following blunt abdominal trauma is under-recognised and, due to its indolent clinical nature, is usually discovered incidentally years later when it is mistaken for malignant disease. This is the first case report of it appearing in the context of high risk, locally advanced prostate cancer. A heat labelled red cell scan is a sensitive and definitive imaging modality for diagnosis. Early consideration of splenosis and diagnostic confirmation is essential to ensuring appropriate care is instituted in each clinical scenario.

COMMENTS

Case characteristics

Soft tissue masses in the context of newly diagnosed prostate cancer.

Clinical diagnosis

Splenunculi.

Differential diagnosis

Metastatic prostate cancer.

Laboratory diagnosis

Routine bloods only, no biopsy was required.

Imaging diagnosis

Technetium-99 scan confirmed splenunculi.

Pathological diagnosis

Ectopic splenic tissue.

Related reports

Multiple other case reports have indicated this differential diagnosis in the staging of many other cancers, but not locally advanced prostate cancer.

Term explanation

Splenosis is the condition related to ectopic splenic tissue formed as a result of trauma. Accessory spleen is a congenital condition.

Experiences and lessons

One must consider the differential of ectopic splenic tissue in a patient post abdominal trauma, with no discernible spleen, if their soft tissue masses are out of keeping with their expected cancer staging. Technetium-99 scans are the most accurate for assessment of splenic tissue.

Peer-review

This is the first case report of splenunculi mimicking metastases in a patient with locally advanced prostate cancer presented by Foreman D and Plagakis SA. Overall, the case report is quite interesting, well organized and written according to the journal's style. The language is satisfactory and the figures quite interesting.

REFERENCES

1 **De Vuysere S**, Van Steenbergen W, Aerts R, Van Hauwaert H, Van Beckevoort D, Van Hoe L. Intrahepatic splenosis: imaging features. *Abdom Imaging* 2000; **25**: 187-189 [PMID: 10675464 DOI: 10.1007/s002619910042]

2 Case records of the Massachusetts General Hospital. Weekly clinicopathological exercises. Case 29-1995. A 65-year-old man with mediastinal Hodgkin's disease and a pelvic mass. *N Engl J Med* 1995; **333**: 784-791 [PMID: 7643887 DOI: 10.1056/NEJM199509213331208]

3 **Fleming CR**, Dickson ER, Harrison EG. Splenosis: autotransplantation of splenic tissue. *Am J Med* 1976; **61**: 414-419 [PMID: 961705 DOI: 10.1016/0002-9343(76)90380-6]

4 **Normand JP**, Rioux M, Dumont M, Bouchard G, Letourneau L. Thoracic splenosis after blunt trauma: frequency and imaging findings. *AJR Am J Roentgenol* 1993; **161**: 739-741 [PMID: 8372748 DOI: 10.2214/ajr.161.4.8372748]

5 **Abu Hilal M**, Harb A, Zeidan B, Steadman B, Primrose JN, Pearce NW. Hepatic splenosis mimicking HCC in a patient with hepatitis C liver cirrhosis and mildly raised alpha feto protein; the important role of explorative laparoscopy. *World J Surg Oncol* 2009; **7**: 1 [PMID: 19123935 DOI: 10.1186/1477-7819-7-1]

6 **Rickert CH**, Maasjosthusmann U, Probst-Cousin S, August C, Gullotta F. A unique case of cerebral spleen. *Am J Surg Pathol* 1998; **22**: 894-896 [PMID: 9669351 DOI: 10.1097/00000478-199807000-00011]

7 **Tsitouridis I**, Michaelides M, Sotiriadis C, Arvaniti M. CT and MRI of intraperitoneal splenosis. *Diagn Interv Radiol* 2010; **16**: 145-149 [PMID: 19838993 DOI: 10.4261/1305-3825.DIR.1855-08.1]

8 **Dokal IS**, Deenmamode M, Lewis SM. Detection and functional assessment of accessory splenic tissue (splenunculi) with radiolabelled heat damaged autologous erythrocytes. *Clin Lab Haematol* 1990; **12**: 387-393 [PMID: 2081379 DOI: 10.1111/j.1365-2257.1990.tb00350.x]

9 **Froehner M**, Leike S, Manseck A, Haase M, Wirth MP. Splenunculus mimicking late local recurrence of renal cell carcinoma. *Scand J Urol Nephrol* 1998; **32**: 418-419 [PMID: 9925009 DOI: 10.1080/003655998750015232]

10 **Basu S**, Ray AK, Banerjee S. Splenunculus masquerading as colonic malignancy. *Int Surg* 2003; **88**: 181-183 [PMID: 14717521]

11 **Foroudi F**, Ahern V, Peduto A. Splenosis mimicking metastases from breast carcinoma. *Clin Oncol* (R Coll Radiol) 1999; **11**: 190-192 [PMID: 10465475 DOI: 10.1053/clon.1999.9040]

12 **Liu Y**, Ji B, Wang G, Wang Y. Abdominal multiple splenosis mimicking liver and colon tumors: a case report and review of the literature. *Int J Med Sci* 2012; **9**: 174-177 [PMID: 22359484 DOI: 10.7150/ijms.3983]

13 **Li H**, Snow-Lisy D, Klein EA. Hepatic splenosis diagnosed after inappropriate metastatic evaluation in patient with low-risk prostate cancer. *Urology* 2012; **79**: e73-e74 [PMID: 22119260 DOI: 10.1016/j.urology.2011.09.041]

P- Reviewer: Gofrit ON, Goluboff ET, Koukourakis GV
S- Editor: Ji FF **L- Editor**: A **E- Editor**: Li D

Published by **Baishideng Publishing Group Inc**
8226 Regency Drive, Pleasanton, CA 94588, USA
Telephone: +1-925-223-8242
Fax: +1-925-223-8243
E-mail: bpgoffice@wjgnet.com
Help Desk: http://www.wjgnet.com/esps/helpdesk.aspx
http://www.wjgnet.com

© 2016 Baishideng Publishing Group Inc. All rights reserved.