ISSN 2219-2808 (online)

World Journal of *Clinical Pediatrics*

World J Clin Pediatr 2015 February 8; 4(1): 1-12

Published by Baishideng Publishing Group Inc

WJCP World Journal of Clinical Pediatrics

A peer-reviewed, online, open-access journal of clinical pediatrics

Editorial Board

2012-2016

The *World Journal of Clinical Pediatrics* Editorial Board consists of 247 members, representing a team of worldwide experts in pediatrics. They are from 43 countries, including Argentina (1), Australia (7), Austria (4), Belgium (2), Brazil (4), Canada (7), Chile (2), China (22), Denmark (2), Egypt (10), Finland (1), France (5), Germany (4), Greece (8), India (14), Iran (5), Israel (7), Italy (22), Japan (6), Mexico (2), Netherlands (2), New Zealand (1), Nigeria (3), Norway (1), Pakistan (2), Poland (2), Portugal (1), Russia (2), Saudi Arabia (2), Serbia (2), Singapore (3), Slovenia (1), South Africa (2), South Korea (2), Spain (5), Sweden (4), Switzerland (1), Thailand (2), Tunisia (1), Turkey (18), United Arab Emirates (1), United Kingdom (11), United States (43).

EDITOR-IN-CHIEF
Eduardo H Garin, *Gainesville*

GUEST EDITORIAL BOARD MEMBERS
Hsiao-Wen Chen, *Taipei*
Ming-Ren Chen, *Taipei*
Mu-Kuan Chen, *Changhua*
Ching-Chi Chi, *Chiayi*
Hung-Chih Lin, *Taichung*

MEMBERS OF THE EDITORIAL BOARD

Argentina

Alcides Richard Troncoso, *Buenos Aires*

Australia

Garry Inglis, *Herston*
Jagat Kanwar, *Victoria*
Katherine Kedzierska, *Parkville*
Eline Suzanne Klaassens, *Brisbane*
Sam S Mehr, *Sydney*
Jing Sun, *Brisbane*
Cuong Duy Tran, *Adelaide*

Austria

Gerhard Cvirn, *Graz*
Claudia Elisabeth Gundacker, *Vienna*
Bernhard Resch, *Graz*
Amulya K Saxena, *Graz*

Belgium

Karel Allegaert, *Leuven*
Yvan Vandenplas, *Brussels*

Brazil

Rejane Correa Marques, *Rio de Janeiro*
Priscila Krauss Pereira, *Rio de Janeiro*
Maria L Seidl-de-Moura, *Rio de Janeiro*
Sandra Elisabete Vieira, *São Paulo*

Canada

Helen SL Chan, *Toronto*
Ediriweera Desapriya, *Vancouver*
Eleftherios P Diamandis, *Toronto*
Ran D Goldman, *Vancouver*
Manjula Gowrishankar, *Edmonton*
Prakesh S Shah, *Toronto*
Pia Wintermark, *Montreal*

Chile

René Mauricio Barría, *Valdivia*
Irene Morales Bozo, *Santiago*

China

Yu-Zuo Bai, *Shenyang*
Xiao-Ming Ben, *Nanjing*
Kwong-Leung Chan, *Hong Kong*
Xian-Hui He, *Guangzhou*
Jian Hu, *Harbin*
Xi-Tai Huang, *Tianjin*
Huang-Xian Ju, *Nanjing*
Ren Lai, *Kunming*
Li Liu, *Xi'an*
Xue-Qun Luo, *Guangzhou*
Ai-Guo Ren, *Beijing*
Chiu-Lai Shan, *Hong Kong*
Yuk Him Tam, *Hong Kong*
Jin-Xing Wang, *Jinan*
Jun-Jun Wang, *Beijing*
Long-Jiang Zhang, *Nanjing*
Yi-Hua Zhou, *Nanjing*

Denmark

Jesper Bo Nielsen, *Odense*
Ole D Wolthers, *Randers*

Egypt

Mosaad Abdel-Aziz, *Cairo*
Hesham E Abdel-Hady, *Mansoura*
Mohammed Al-Biltagi, *Tanta*
Mohammad MS Al-Haggar, *Mansoura*
Ashraf MAB Bakr, *Mansoura*
Badr Eldin Mostafa, *Cairo*
Rania Refaat, *Cairo*
Omar Mamdouh Shaaban, *Assiut*
Maysaa El Sayed Zaki, *Mansoura*
Magdy Mohamed Zedan, *Mansoura*

Finland

Bright Ibeabughichi Nwaru, *Tampere*

France

Philippe Georgel, *Strasbourg*
Grill Jacques, *Villejuif*

Manuel Lopez, *Saint Etienne*
Georgios Stamatas, *Issy-les-Moulineaux*
Didier Vieau, *Villeneuve d'Ascq*

Germany

Yeong-Hoon Choi, *Cologne*
Carl Friedrich Classen, *Rostock*
Stephan Immenschuh, *Hannover*
Ales Janda, *Freiburg im Breisgau*

Greece

Michael B Anthracopoulos, *Rion-Patras*
Savas Grigoriadis, *Thessaloniki*
Vasiliki-Maria Iliadou, *Thessaloniki*
Theofilos M Kolettis, *Ioannina*
Ariadne Malamitsi-Puchner, *Athens*
Dimitrios Papandreou, *Thessaloniki*
Kostas N Priftis, *Athens*
Ioannis Michael Vlastos, *Heraklion*

India

Amit Agrawal, *Ambala*
Sameer Bakhshi, *New Delhi*
Atmaram H Bandivdekar, *Mumbai*
Sandeep Bansal, *Chandigarh*
Sriparna Basu, *Varanasi*
Ashu Seith Bhalla, *New Delhi*
Sushil Kumar Kabra, *New Delhi*
Praveen Kumar, *New Delhi*
Kaushal Kishor Prasad, *Chandigarh*
Yogesh Kumar Sarin, *New Delhi*
Kushaljit Singh Sodhi, *Chandigarh*
Raveenthiran V Venkatachalam, *Tamilnadu*
B Viswanatha, *Bangalore*
Syed Ahmed Zaki, *Mumbai*

Iran

Mehdi Bakhshaee, *Mashhad*
Maria Cheraghi, *Ahvaz*
Mehran Karimi, *Shiraz*
Samileh Noorbakhsh, *Tehran*
Firoozeh Sajedi, *Tehran*

Israel

Shraga Aviner, *Ashkelon*
Aviva Fattal-Valevski, *Ramat Aviv*
Rafael Gorodischer, *Omer*
Gil Klinger, *Petah Tikva*
Asher Ornoy, *Jerusalem*
Giora Pillar, *Haifa*
Yehuda Shoenfeld, *Tel-Hashomer*

Italy

Roberto Antonucci, *Cagliari*
CarloV Bellieni, *Siena*
Silvana Cicala, *Naples*
Sandro Contini, *Parma*
Enrico Stefano Corazziari, *Rome*
Vincenzo Cuomo, *Rome*
Vassilios Fanos, *Cagliari*
Filippo Festini, *Florence*
Irene Figa-Talamanca, *Rome*
Dario Galante, *Foggia*
Fabio Grizzi, *Milan*
Alessandro Inserra, *Rome*
Achille Iolascon, *Naples*
Cantinotti Massimiliano, *Pietrsanta*
Ornella Milanesi, *Padova*
Giovanni Nigro, *L'Aquila*
Giuseppe Rizzo, *Rome*
Claudio Romano, *Messina*
Mario Santinami, *Milano*
Gianluca Terrin, *Rome*
Alberto Tommasini, *Trieste*
Giovanni Vento, *Rome*

Japan

Ryo Aeba, *Tokyo*
Kazunari Kaneko, *Osaka*
Hideaki Senzaki, *Saitama*
Kohichiro Tsuji, *Tokyo*
Toru Watanabe, *Niigata*
Takayuki Yamamoto, *Yokkaichi*

Mexico

Fernando Guerrero-Romero, *Durango*
Mara Medeiros, *Mexico*

Netherlands

Jacobus Burggraaf, *Leiden*
Paul Eduard Sijens, *Groningen*

New Zealand

Simon James Thornley, *Auckland*

Nigeria

Akeem Olawale Lasisi, *Ibadan*
Tinuade Adetutu Ogunlesi, *Sagamu*
Joseph Ubini Ese Onakewhor, *Benin*

Norway

Lars T Fadnes, *Bergen*

Pakistan

Niloufer Sultan Ali, *Karachi*
Shakila Zaman, *Lahore*

Poland

Piotr Czauderna, *Gdansk*
Joseph Prandota, *Wroclaw*

Portugal

Alexandre M Carmo, *Porto*

Russia

Perepelitsa S Alexandrovna, *Kaliningrad*
Vorsanova Svetlana, *Moscow*

Saudi Arabia

Naser Labib Rezk, *Riyadh*
Amna Rehana Siddiqui, *Riyadh*

Serbia

Bjelakovic Borisav Bojko, *Nis*
Mirela Erić, *Novi Sad*

Singapore

Quak Seng Hock, *Singapore*
Anselm CW Lee, *Singapore*
Alvin Soon Tiong Lim, *Singapore*

Slovenia

Rok Orel, *Ljubljana*

South Africa

David Kenneth Stones, *Free State*
Eric Oghenerioborue Udjo, *Pretoria*

South Korea

Byung-Ho Choe, *Daegu*
Dong-Hee Lee, *Seoul*

Spain

Pilar Codoñer-Franch, *Valencia*
Claudio Golffier, *Barcelona*
Pablo Menendez, *Andalucía*
Juan F Martínez-Lage Sánchez, *Murcia*
Juan Antonio Tovar, *Madrid*

Sweden

Moustapha Hassan, *Stockholm*
Maria Christina Jenmalm, *Linköping*
Sandra Kleinau, *Uppsala*
Birgitta Lindberg, *Luleå*

Switzerland

Ulf Kessler, *Bern*

Thailand

Surasak Sangkhathat, *Hat Yai*
Viroj Wiwanitkit, *Bangkok*

Tunisia

John C Anyanwu, *Tunis Belvedere*

Turkey

Sinem Akgül, *Ankara*
Ayse Tuba Altug, *Ankara*
Suna Asilsoy, *Seyhan-Adana*
Ozgu Aydogdu, *Izmir*
Kadir Babaoglu, *Kocaeli*
Aksoy Berna, *Kocaeli*
Murat Biteker, *Istanbul*
Merih Çetinkaya, *Istanbul*
Aynur Emine Cicekcibasi, *Konya*
Elvan Caglar Citak, *Mersin*
Cem Dane, *Istanbul*
Mintaze Kerem Günel, *Ankara*
Ahmet Güzel, *Samsun*
Salih Kavukcu, *Izmir*
Fethullah Kenar, *Denizli*
Selim Kurtoglu, *Kayseri*
Turker Ozyigit, *Istanbul*
Yalçın Tüzün, *Istanbul*

United Arab Emirates

Iradj Amirlak, *Al Ain*

United Kingdom

Keith Collard, *Plymouth*
ASahib El-Radhi, *London*
Edzard Ernst, *Exeter*
Mohammad K Hajihosseini, *Norwich*
Tain-Yen Hsia, *London*
Claudio Nicoletti, *Norwich*
Cordula Margaret Stover, *Leicester*
Alastair Gordon Sutcliffe, *London*
Adrian Graham Thomas, *Manchester*
Richard Trompeter, *London*
Petros V Vlastarakos, *Stevenage*

United States

Stephen C Aronoff, *Philadelphia*
Hossam M Ashour, *Detroit*
Paul Ashwood, *Sacramento*
David C Bellinger, *Boston*
Vineet Bhandari, *New Haven*
FR Breijo-Marquez, *Boston*
Itzhak Brook, *Washington*
Patrick D Brophy, *Iowa*
Lavjay Butani, *Sacramento*
Archana Chatterjee, *Omaha*
Lisa M Cleveland, *San Antonio*
Shri R Deshpande, *Atlanta*
Michael Morgan Dowling, *Dallas*
Abdulrahman M El-Sayed, *New York*
Donald N Forthal, *Irvine*
Gregory Kane Friedman, *Birmingham*
Kenneth William Gow, *Seattle*
Dorothy I Bulas, *Washington*
Christopher L Coe, *Madison*
Elias Jabbour, *Houston*
Michael Van Doren Johnston, *Baltimore*
Ram V Kalpatthi, *Gainesville*
Stephen S Kim, *Annandale*
Edward Yungjae Lee, *Annandale*
Jing Lin, *New York*
Jorge Lopez, *Gainesville*
Aurelia Meloni-Ehrig, *Gainesville*
Murielle Mimeault, *Omaha*
Natan Noviski, *Omaha*
Michael David Seckeler, *Charlottesville*
Chetan Chandulal Shah, *Little Rock*
Mohamed Tarek M Shata, *Cincinnati*
Tsz-Yin So, *Greensboro*
Dennis Charles Stevens, *Sioux Falls*
Ru-Jeng Teng, *Milwaukee*
Rajan Wadhawan, *St Petersburg*
Hongjun Wang, *St Charleston*
Marie Wang, *Menlo Park*
Richard Wang, *Atlanta*
Wladimir Wertelecki, *Annandale*
Shu Wu, *Miami*
Fadi Xu, *Albuquerque*

WJCP World Journal of Clinical Pediatrics

Contents

Quarterly Volume 4 Number 1 February 8, 2015

REVIEW

1 Spectrum of complicated migraine in children: A common profile in aid to clinical diagnosis

Gupta SN, Gupta VS, Fields DM

World Journal of Clinical Pediatrics
Volume 4 Number 1 February 8, 2015

Contents

ABOUT COVER Editorial Board Member of *World Journal of Clinical Pediatrics*, Claudio Romano, Assistant Professor, Pediatric Department, University of Messina, Via Osservatorio 1, 98122 Messina, Italy

AIM AND SCOPE *World Journal of Clinical Pediatrics* (*World J Clin Pediatr*, *WJCP*, online ISSN 2219-2808, DOI: 10.5409) is a peer-reviewed open access academic journal that aims to guide clinical practice and improve diagnostic and therapeutic skills of clinicians.

WJCP covers a variety of clinical medical topics, including fetal diseases, inborn, newborn diseases, infant diseases, genetic diseases, diagnostic imaging, endoscopy, and evidence-based medicine and epidemiology. Priority publication will be given to articles concerning diagnosis and treatment of pediatric diseases. The following aspects are covered: Clinical diagnosis, laboratory diagnosis, differential diagnosis, imaging tests, pathological diagnosis, molecular biological diagnosis, immunological diagnosis, genetic diagnosis, functional diagnostics, and physical diagnosis; and comprehensive therapy, drug therapy, surgical therapy, interventional treatment, minimally invasive therapy, and robot-assisted therapy.

We encourage authors to submit their manuscripts to *WJCP*. We will give priority to manuscripts that are supported by major national and international foundations and those that are of great clinical significance.

INDEXING/ABSTRACTING *World Journal of Clinical Pediatrics* is now indexed in PubMed Central, PubMed and Digital Object Identifier.

FLYLEAF **I-III** Editorial Board

EDITORS FOR THIS ISSUE

Responsible Assistant Editor: *Xiang Li*
Responsible Electronic Editor: *Ya-Jing Lu*
Proofing Editor-in-Chief: *Lian-Sheng Ma*
Responsible Science Editor: *Xue-Mei Gong*
Proofing Editorial Office Director: *Xiu-Xia Song*

NAME OF JOURNAL
World Journal of Clinical Pediatrics

ISSN
ISSN 2219-2808 (online)

LAUNCH DATE
June 8, 2012

FREQUENCY
Quarterly

EDITOR-IN-CHIEF
Eduardo H Garin, MD, Professor, Department of Pediatrics, University of Florida, 1600 SW Archer Road. HD214, Gainesville, FL 32610, United States

EDITORIAL OFFICE
Jin-Lei Wang, Director
Xiu-Xia Song, Vice Director
World Journal of Clinical Pediatrics
Room 903, Building D, Ocean International Center, No. 62 Dongsihuan Zhonglu, Chaoyang District, Beijing 100025, China
Telephone: +86-10-85381891
Fax: +86-10-85381893
E-mail: editorialoffice@wjgnet.com
Help Desk: http://www.wjgnet.com/esps/helpdesk.aspx
http://www.wjgnet.com

PUBLISHER
Baishideng Publishing Group Inc
8226 Regency Drive,
Pleasanton, CA 94588, USA
Telephone: +1-925-223-8242
Fax: +1-925-223-8243
E-mail: bpgoffice@wjgnet.com
Help Desk: http://www.wjgnet.com/esps/helpdesk.aspx
http://www.wjgnet.com

PUBLICATION DATE
February 8, 2015

COPYRIGHT
© 2015 Baishideng Publishing Group Inc. Articles published by this Open-Access journal are distributed under the terms of the Creative Commons Attribution Non-commercial License, which permits use, distribution, and reproduction in any medium, provided the original work is properly cited, the use is non commercial and is otherwise in compliance with the license.

SPECIAL STATEMENT
All articles published in journals owned by the Baishideng Publishing Group (BPG) represent the views and opinions of their authors, and not the views, opinions or policies of the BPG, except where otherwise explicitly indicated.

INSTRUCTIONS TO AUTHORS
Full instructions are available online at http://www.wjgnet.com/2219-2808/g_info_20100722180909.htm.

ONLINE SUBMISSION
http://www.wjgnet.com/esps/

World Journal of Clinical Pediatrics

Submit a Manuscript: http://www.wjgnet.com/esps/
Help Desk: http://www.wjgnet.com/esps/helpdesk.aspx
DOI: 10.5409/wjcp.v4.i1.1

World J Clin Pediatr 2015 February 8; 4(1): 1-12
ISSN 2219-2808 (online)
© 2015 Baishideng Publishing Group Inc. All rights reserved.

REVIEW

Spectrum of complicated migraine in children: A common profile in aid to clinical diagnosis

Surya N Gupta, Vikash S Gupta, Dawn M Fields

Surya N Gupta, Dawn M Fields, Pediatric Neurology, CAMC, Charleston, WV 25301, United States
Surya N Gupta, Section Child Neurology, Women's and Children's Hospital, Charleston Area Medical Center, Charleston, WV 25301, United States
Vikash S Gupta, Texila American University, Georgetown 05924, Guyana
Author contributions: Gupta VS searched and prepared initial version of the draft; Fields DM provided the clinical information regarding individual syndromes of complicated migraine; Gupta SN initiated, supervised, coordinated, proposed the common profile, and contributed in discussion of complicated migraine; all the authors approved the final version of this manuscript.
Conflict-of-interest: None.
Open-Access: This article is an open-access article which was selected by an in-house editor and fully peer-reviewed by external reviewers. It is distributed in accordance with the Creative Commons Attribution Non Commercial (CC BY-NC 4.0) license, which permits others to distribute, remix, adapt, build upon this work non-commercially, and license their derivative works on different terms, provided the original work is properly cited and the use is non-commercial. See: http://creativecommons.org/licenses/by-nc/4.0/
Correspondence to: Surya N Gupta, MD, Associate Professor, Pediatric Neurology, CAMC, 415 Morris Street, Suite 300, Charleston, WV 25301,
United States. suryangupta@rediffmail.com
Telephone: +1-304-3886441
Fax: +1-304-3886445
Received: November 4, 2014
Peer-review started: November 4, 2014
First decision: November 21, 2014
Revised: December 6, 2014
Accepted: December 16, 2014
Article in press: December 17, 2014
Published online: February 8, 2015

Abstract

Complicated migraine encompasses several individual clinical syndromes of migraine. Such a syndrome in children frequently presents with various neurological symptoms in the Emergency Department. An acute presentation in the absence of headache presents a diagnostic challenge. A delay in diagnosis and treatment may have medicolegal implication. To date, there are no reports of a common clinical profile proposed in making a clinical diagnosis for the complicated migraine. In this clinical review, we propose and describe: (1) A common clinical profile in aid to clinical diagnosis for spectrum of complicated migraine; (2) How it can be used in differentiating complicated migraine from migraine without aura, migraine with aura, and seizure; (3) We discuss the status of complicated migraine in the International Headache Society classification 2013; and (4) In addition, a common treatment strategy for the spectrum of migraine has been described. To diagnose complicated migraine clinically, it is imperative to adhere with the proposed profile. This will optimize the use of investigation and will also avoid a legal implication of delay in their management. The proposed common clinical profile is incongruent with the International Headache Society 2013. Future classification should minimize the dissociation from clinically encountered syndromes and coin a single word to address collectively this subtype of migraine with an acute presentation of a common clinical profile.

Key words: Electroencephalography; Seizure; Seizure like activity; Complicated migraine; Stroke; Magnetic resonance imaging

© The Author(s) 2015. Published by Baishideng Publishing Group Inc. All rights reserved.

Core tip: Complicated migraine in pediatric neurology practice is a frequent cause for an Emergency Department visit. Their clinical presentations are variable. They mimic several clinical syndromes but they can be diagnosed clinically by following proposed common clinical profile closely in the absence of any identifiable etiology.

Gupta SN, Gupta VS, Fields DM. Spectrum of complicated

migraine in children: A common profile in aid to clinical diagnosis. *World J Clin Pediatr* 2015; 4(1): 1-12 Available from: URL: http://www.wjgnet.com/2219-2808/full/v4/i1/1.htm DOI: http://dx.doi.org/10.5409/wjcp.v4.i1.1

INTRODUCTION

Most practicing clinicians have acquired knowledge in making a clinical diagnosis of migraine with and without aura. Unlike adults, migraines in children are common in Emergency and Ambulatory Care-Settings. When children present with an acute onset neurologic symptom other than headache, hesitancy to diagnose migraine may arise. This is primarily due to lack of realization of a full spectrum of migraines which include migraine without aura, migraine with aura, and complicated migraine. Secondarily, this is due to lack of appreciation that complicated migraine is a "fragmented" presentation of the migraine attack profile. Unlike migraine without aura, complicated migraine is not a single entity. It includes a variety of individual syndromes. In pediatric neurology practice, complicated migraines are the most common cause after seizures for Emergency Department visits. These syndromes are named after their presenting symptoms with an exception to basilar type migraine which defies this rule. Multiple manifestations of basilar type migraine represent its neuroanatomical evolvement.

Migraines are self-limiting dysfunctions of grey matter. It is primarily a neuronal sensory dysfunction which secondarily involves the vascular systems. Involvement of the sensory nerve fibers within meningeal blood vessels gives rise to head pain[1,2].

The diagnosis of complicated migraine is basically clinical. The common differential diagnosis includes seizure, transient ischemic attack, and migraine like syndromes. Their relationships are complex. Migraine and seizure are common conditions and they may coexist in the same patient[3].

In this clinical review, we discuss the status of complicated migraine in the International Headache Society classification, the third Edition 2013. We propose a common clinical profile in making the clinical diagnosis of complicated migraine. We describe clinical characteristics of the proposed profile and how they can be used in differentiating complicated migraine from migraine without aura, migraine with aura, and seizure. In addition, a common treatment strategy for the spectrum of migraine is described.

TERMINOLOGY

Multiple terms, complicated migraine, complex migraine, migraine accompanies acephalgic migraine, uncommon migraines, or migraine variants have been used. Some of these, complicated or complex migraine, or migraine accompanies are considered obsolete. However, in clinical practice, as an umbrella-term, the complicated migraine remains useful indicating a common clinical profile for a wide variety of acute neurologic syndromes of unknown etiology.

In this review, we have used the term complicated migraine collectively to express a subgroup of individual clinical syndromes which are distinct from migraine with and without aura.

CLASSIFICATION

The individual syndrome of "complicated migraine" is classified by the International Headache Society (IHS) 2013 under the first three out of eleven subheadings of migraine Table 1[4]. This is primarily designed to provide for migraine the diagnostic codes for policymaking or for research. "Complications of the migraine" listed in the IHS classification 2013 should not be confused with complicated migraine. Status migrainosus is a complication of migraine with and without aura. They have their own distinct clinical profiles. Unlike complicated migraine, headache in migraine with and without aura is a prominent and persistent symptom, lasting for over 72 h. Therefore, status migrainosus should not be classified as complicated migraine.

The dissociation of IHS classification from commonly encountered conditions has continued with the 2013 beta version of the classification. Some commonly encountered conditions such as the migraine associated blackout or fainting, seizure like activity, chest pain, or vestibular symptoms as a manifestation of the migraine are conspicuously absent from the classification. Additionally, it is not unusual in children with migraine to present with isolated leg, body (corpalgia), or lower back pain, and nose bleed[5,6].

Although complicated migraine and migraine variants are used interchangeably. The question arises that how should migraine variants be classified? Based upon proposed common clinical profile, migraine variants remain as a subdivision of the complicated migraine. However, their subgrouping as migraine variants still remains clinically useful to indicate that these conditions have potential to develop in a full blown migraine in adult life.

It is important to realize that children with migraines may have episodes of a variety of isolated and independent self-limiting symptoms other than headache which may or may not coincide with migraine attack. Physicians should be aware of both the classification and the full clinical spectrum of the migraine.

INCIDENCE

Incidence of complicated migraine individually or collectively is unknown. Obviously, the incidence

Table 1 Represents the very first 3 out of 11 sections of the International Headache Society Classification, the third Edition, 2013[4]

1 Migraine
- 1.1 Migraine without aura
- 1.2 Migraine with aura
  - 1.2.1 Migraine with typical aura
    - 1.2.1.1 Typical aura with headache
    - 1.2.1.2 Typical aura without headache
  - 1.2.2 Migraine with brainstem aura
  - 1.2.3 Hemiplegic migraine
    - 1.2.3.1 Familial hemiplegic migraine
      - 1.2.3.1.1 Familial hemiplegic migraine type 1
      - 1.2.3.1.2 Familial hemiplegic migraine type 2
      - 1.2.3.1.3 Familial hemiplegic migraine type 3
      - 1.2.3.1.4 Familial hemiplegic migraine, other loci
    - 1.2.3.2 Sporadic hemiplegic migraine
  - 1.2.4 Retinal migraine
- 1.3 Chronic migraine
- 1.4 Complications of migraine
  - 1.4.1 Status migrainosus
  - 1.4.2 Persistent aura without infarction
  - 1.4.3 Migrainous infarction
  - 1.4.4 Migraine aura-triggered seizure
- 1.5 Probable migraine
  - 1.5.1 Probable migraine without aura
  - 1.5.2 Probable migraine with aura
- 1.6 Episodic syndromes that may be associated with migraine
  - 1.6.1 Recurrent gastrointestinal disturbance
    - 1.6.1.1 Cyclical vomiting syndrome
    - 1.6.1.2 Abdominal migraine
  - 1.6.2 Benign paroxysmal vertigo
  - 1.6.3 Benign paroxysmal torticollis

With an exception of 9/27 classified conditions, migraine without aura (1.1), migraine with aura (1.2), migraine with typical aura (1.2.1), and typical aura with headache (1.2.1.1), chronic migraine (1.3), status migrainosus (1.4.1), probable migraine (1.5), probable migraine without aura (1.5.1), probable migraine with aura (1.5.2), the rest of the condition 18/27 can be seen, but not limited to, as a subgroup of clinical "complicated migraine". "Complications of the migraine" listed in the IHS classification should not be confused with complicated migraine.

will also vary depending upon what is considered complicated migraine. However, in pediatric neurology they are the second most common condition after seizures requiring hospitalization. The frequency of the complicated migraine reported in select studies is shown in Table 2[7-9].

PATHOPHYSIOLOGY

Pathophysiology of migraine has evolved over the last century through the vascular theory (1938), identification of intracranial pain-sensitive structures (1941), cortical spreading depression of Leão (1944), neurotransmitter (1959), spreading oligemia in migraine with aura (1981), neurogenic inflammation theory (1987), the discovery of sumatriptan (1988), calcitonin gene-related peptide (1990), the brainstem "migraine generator" (1995), migraine as a channelopathy and the genetic perspective (1996), and central sensitization and allodynia (1996)[10]. The exact mechanism of the central nervous system pathophysiologic dysfunction in migraine is unclear. It is generally accepted that spreading of neuronal depression, neurogenic inflammation, and the activation of trigeminovascular system are involved.

PATHOPHYSIOLOGICALLY BASED CLINICAL DIFFERENTIATION OF MIGRAINE AND SEIZURE

Migraine and epilepsy share a common pathophysiologic mechanism. Thus, it is not a surprise that both are quite similar in almost all aspects of their clinical manifestations and treatment strategies. Both events are triggered by an altered neocortical excitability. In migraine it is secondary to cortical spreading depression. The cortical spreading depression is a self-propagating wave of neuronal and glial depolarization that spreads across the cerebral cortex. The neocortical spreading provokes the expression of c-fos protein-like immunoreactivity within trigeminal nucleus caudalis *via* trigeminovascular mechanisms[11,12]. In contrast, the seizure is secondary to hypersynchronous neuronal activity[13]. This neurophysiologic difference, their relative speed of spread, are the basis for a clinical differentiation between migraine and seizure. Migraine evolves slowly and seizure onset is sudden and fast. Most ictal periods in seizure last less than 3 min while migraine episode evolves over and beyond 10 min[14].

This clinical distinction of onset and progression is lost when seizure lasts longer than 3 min like in complex partial seizure or when migraine becomes shorter as in complicated migraine. This can be explained partially based upon Piccinelli *et al*[15], who studied the clinical and neurophysiologic link between migraine and epilepsy. By studying 137 children with tension-type headache and migraine with and without aura, they concluded that there is a possible clinical continuum between migraine with aura and epileptic syndrome.

Variability in the presenting symptoms and context, both characterize migraine in contrast to the seizure. Acute confusional migraine is a rare migraine variant which manifests with a wide diversity of cortical dysfunctions such as speech difficulties, increased alertness, agitation, and amnesia. The exact pathophysiology remains unclear. However, the occipital cortical spreading depression may also extend to the temporal, parietal or frontal cortex causing transient hypoperfusion and dysfunction of the affected lobes[16].

It should be noted that clinical manifestations, sensory, psychosomatic, autonomic, and motor dysfunctions, are the same in both migraine and seizure. But sensory symptoms predominate in migraine while seizure is characterized by motor activity.

Table 2 Lists the frequency of the individual syndromes of complicated migraine reported by the select retrospective studies[7-9]

Study type	Ref.	No. of patients	Frequency of the individual syndromes of complicated migraine reported
Retrospective	[7]	111	Migraine variants 24.3%, basilar type migraine 6.3%, benign paroxysmal vertigo (5.4%), hemiplegic migraine (3.6%), acute confusional migraine (2.7%), benign paroxysmal torticollis (2.7%), typical aura without headache (1.8%), abdominal migraine (1.8%), Alice in Wonderland syndrome (0.9%), ophthalmoplegic migraine (0.9%), and cyclical vomiting (0.9%)
Retrospective	[8]	674	Migraine variants 5.6%, abdominal migraine 39%, benign paroxysmal vertigo 38%, confusional migraine 13%, aura without migraine 9%, paroxysmal torticollis 5%, and a single child with cyclic vomiting
Retrospective, adults in Hyperacute Stroke Units	[9]	375	Conditions other than stroke 31%, which included 22% migraine, 14% functional neurological disorder, 12% syncope, and 6% seizure. In contrast to stroke patients, they tend to be younger, likely to have a brain MRI performed, and had a shorter length of hospital stay

This should be noted that no alternating hemiplegia of childhood and retinal migraine were reported in these studies. MRI: Magnetic resonance imaging.

Table 3 Lists the common clinical characteristics of complicated migraine

	Clinical characteristics
Presenting feature	Any neurologic sign or symptom other than headache
Age	Commonly, but not limited to, occurs during infancy and childhood
Sex	Boys dominate in migraine variants and girls dominate in the rest of the complicated migraine other than migraine variants
Onset	Acute or sudden but relatively slower than seizure
The context	Patients may have past episode of similar or different symptomatology suggesting migraine attack
Modifying factor	Unlike migraine, none
Family history	Unlike common migraine, in complicated migraine a family history of migraine is almost always present
Course	Transient, may occur once in lifetime or may become episodic but always reversible with the exception to alternating hemiplegia
Examination	With few exceptions, particularly between the episodes, neurologic examination is almost always normal
Differential diagnosis: common/rare	Partial seizures, seizure like activity, transient ischemic attack/migraine like syndrome[1] and acute stroke
Investigation	Usually normal including neuroimaging and electroencephalography
Diagnosis	A short course of the presenting symptom between seizure and common migraine defines the complicated migraine

[1]Migraine like syndrome includes aseptic meningitis, pseudotumor cerebri, subarachnoid hemorrhage, sinus venous thrombosis, arteriovenous malformation, mitochondrial encephalomyopathy, lactic acidosis, and stroke-like episodes, and rarely brain tumor. Complicated migraine is not a single entity. It includes a variety of individual clinical syndromes. The propose common clinical profile in add to clinical diagnosis of complicated migraine is quite distinct from other conditions like migraine with and without aura, seizure, and migraine like syndromes. To represent collectively such a large subgroup of the individual syndromes, the term complicated migraine has been used in this review.

COMMON CLINICAL PROFILE

The reviews of the literature in regards to complicated migraine revealed a common clinical profile (Table 3).

Age and sex

Migraine variants are common during infancy and early childhood in males by Teixeira *et al*[8]. On the other hand, complicated migraines other than migraine variants are common in young females. Martens *et al*, studied 209 children presenting with headache and reported a mean age of 11.3 years, female 56.5%, unclassified headache: 23.4%; probable migraine 17.2%, migraine without aura 13.4%, complicated migraine 12.4%, migraine with aura 1.0%; tension-type 15.3%, and cluster headaches 0.5%, and secondary headaches 16.7%.

Presenting feature

Because complicated migraines manifest as an acute cerebral dysfunction other than headache, considering the diagnosis of migraine as a subgroup may present hesitancy and its vividity and unfamiliarity provoke anxiety which results in an extensive work up[17].

In practice, most complicated migraine presents with the isolated sign or symptom. The isolated manifestation may occur independently, together, or in the midst of the migraine attack[18]. However, some may present with more than one neurologic or medical manifestation. Such patients should be screened for concomitant use of daily analgesic, contraceptive pill, and elevated body mass index. The headache is not a presenting symptom of complicated migraine. However, headaches often coexist with attack of complicated migraine.

Psychosomatic and autonomic presenting symptoms in migraines are commonly encountered but they are infrequently realized. These include palpitations, chest pain, depression, anxiety and panic disorders, and mood disorder. Young children may present with episodic behavioral problems such as

being inattentive, poor impulse control, irritable, and/or socially withdrawn. Rarely, hypomania has been reported[19]. In such situations, commonly alternative diagnoses other than migraine or no diagnosis is made.

Onset and course

Onset of complicated migraines is acute but it is relatively slower than seizure. The time course of complicated migraine lies between seizure and migraine without aura. They may occur once in lifetime. However, a frequent self-limiting course is not unusual.

Context

In making a clinical diagnosis, the context in which the patient's problem is manifested is as important as the presenting symptom. Like presenting symptoms, the context is also variable in complicated migraine. Migraines are characterized by the variability of the symptoms. Additionally, the presence of migrainous symptoms in the background provide a clue for the diagnosis. If the context is not sought actively the clinical diagnosis of complicated migraine can be difficult.

Precipitating and relieving factors: Unlike common migraine, complicated migraine has no known provoking or relieving factors. However, like migraine complicated migraine resolves spontaneously.

Examination

At onset of complicated migraine, medical and neurologic examinations are normal. Medical examination may reveal lower than normal heart rate, hypotension, and facial pallor. With acute onset, occasionally eyelid swelling, joint pain without swelling, isolated dysarthria, incomplete or complete hemiparesis, or ocular motor deficit may be present.

Clinical diagnosis

Adherence to the presented clinical profile, normal neurologic examination, and the normal results of the select tests make the diagnosis of complicated migraine. The accuracy of clinical diagnosis can be increased substantially by a careful consideration of the presenting symptom, its course timeline, relationship with other symptoms, and actively seeking the etiology.

Conditions like acute confusional migraine, seizure like activity, and non-epileptic seizure as a manifestation of the migraine are likely to mimic seizure. Migraine precipitated seizure like activity usually occurs in the background of prolonged migrainous symptoms[20]. It is interesting to note that migraine does not only mimic but it can cause seizure, transient ischemic attack, or even stroke[21].

Differential diagnosis

Differential diagnosis of complicated migraines in children includes partial seizures, transient ischemic attack, and migraine like syndromes.

A sequential history of the event and its clinical characteristics are essential in making the clinical diagnosis of epileptic seizure. The best indicators of a seizure are the rapid and self-limiting time-course, the post-event confusion, and if present, a puncture wound on the lateral border of tongue[22]. An abnormal EEG supports the diagnosis. However, a normal EEG does not exclude a clinical diagnosis of seizure.

Transient ischemic attack, although considered frequently, is a rare occurrence in a healthy child. However, this should be considered in children with blood and cardiac disorders.

A large body of literature supports an association between migraine with aura and ischemic stroke. This is observed particularly in women who use contraceptives and smoke cigarettes. Because the absolute risk of stroke is considerably low in patients with migraine, the vast majority of migraine patients will not experience a stroke event because of the migraine[23].

Migraine like syndrome

A presentation simulating migraine occurs in the patient with and without migraine. Migraine is precipitated by stress which may be external or internal[24]. Onset of a second condition, as in internal stress in migraine patient, is likely to trigger or change the previous migraine attack profile. This has been reported in infections[25,26] and in Sturge Weber syndrome[27]. The differential diagnosis of migraine like syndromes, their presenting symptoms, and the confirmatory laboratory tests are listed in Table 4.

The clinical and neuroimaging profile of migraine like syndromes are rather unique and different from each other. It is also very different from complicated migraine. Like migraine without aura, headache is an initial and prominent symptom of migraine like syndromes except sinus venous thrombosis and subarachnoid hemorrhage. Their initial manifestation may be waxing and waning level of consciousness before developing loss of consciousness in sinus venous thrombosis and seizure in subarachnoid hemorrhage.

Laboratory investigation

In the context of complicated migraine a complete blood count, comprehensive metabolic panel, and thyroid function tests are justifiable. However, CSF study, EEG, and the neuroimaging study should be considered based on the clinical impression[28,29]. The results of the performed tests are almost always normal. They are performed primarily to exclude migraine like syndrome including bacterial or aseptic meningitis. In most cases of complicated migraine based on clinical assessment and the tests may not be indicated. But it plays a pivotal role in quelling

Table 4 Lists the diffrential diagnosis of migraine like syndromes, their presenting symptoms, and the confirmatory laboratory tests

Migraine like syndrome	Presenting symptom	Confirmed by
Aseptic meningitis	Infants and children age < 5 yr presenting with constitutional symptoms together with meningeal signs	Cerebrospinal fluid study molecular testing by polymerase chain reaction[28]
Pseudotumor cerebri	Persistent headache with prominent visual symptoms and head tilt	An increased intracranial opening pressure measured in calm patient with straight leg position
Subarachnoid hemorrhage	Waxing and waning levels of consciousness, apnea, bradycardia before seizure	Brain computerized tomography and/or presence of blood or xanthochromic cerebrospinal fluid
Sinus venous thrombosis	Altered mentation with no obvious etiology or no seizures	Brain computerized tomography with and without contrast or MRV
Arteriovenous malformation	Sensory cutaneous aura with or without seizure or headache	MRA and MRV or computerized tomographic angiography
MELAS	Early symptoms, muscle weakness and pain, recurrent headaches, loss of appetite, vomiting, and seizures	MRI of the brain mimicking acute migrainous stroke but differs by having no respect to a specific cerebral arterial vascular territory
Brain tumor	Progressively worsening headache with onset of focal neurologic sign or seizure	Computerized tomography with contrast or MRI of the brain with and without contrast

The headache recurrent or persistent may be the presenting sign of migraine like syndromes except sinus venous thrombosis and subarachnoid hemorrhage. Their initial presentation is waxing and waning level of consciousness. MRV: Magnetic resonance venography; MRA: Magnetic resonance angiography; MELAS: Mitochondrial encephalomyopathy, lactic acidosis, and stroke-like episodes; MRI: Magnetic resonance imaging.

the parental anxiety.

CEREBROSPINAL FLUID

CSF abnormalities have been reported infrequently in patients with migraine. It is not clear whether or not all complicated migraine syndromes are associated with CSF abnormality. Normal CSF or CSF with both polymorphonuclear or lymphocytic pleocytosis[30,31], a raised intracranial pressure, an increased CSF sodium concentration[32], all are found during migraine with and without aura. Total protein content was significantly lower in migraine patients than the controls.

In the absence of any other detectable cause, the CSF changes were attributed to the effects of the migrainous process on meningeal vascular permeability[33]. Rossi *et al* studied four children with complicated migraine. On the basis of 23 previously reported cases along with their four cases, they concluded that pleocytosis is a secondary phenomenon.

In this respect, there are no common CSF characteristic which characterizes the complicated migraine. Select reports of biochemical changes distinguishing bacterial meningitis, aseptic meningitis, and migraine attack are shown in Table 5[34-39].

NEUROIMAGING

The data on neuroimaging during an episode of complicated migraine is limited. Most data comes from the isolated or series of the reported cases. Indication to perform an MRI and MRA of the brain are migraine with aura, hemiplegic migraine, or when an alternative diagnosis such as migraine like syndrome is being considered.

In general, conventional neuroimaging in complicated migraine is normal or likely to reveal incidental findings. Martens *et al*[40] retrospectively evaluated the role of cerebral MRI and EEG in 209 children presenting with headache. The study revealed signs of sinus disease (7.2%), pineal cysts (2.4%), arachnoidial cyst (1.9%) and Chiari malformation (1.9%), unspecified signal enhancement (1.0%) and pituitary enlargement, inflammatory lesion, angioma, cerebral ischemia, and intra-cerebral cyst, each 0.5%[40]. Such a spectrum of neuroradiologic findings is likely to unveil during the assessment of headache, seizure, developmental delay, or during an investigation of an acute brain insult. Common sources for these incidental findings on brain MRI might relate to a delayed developmental status rather than other neurologic diagnoses[41]. Nonetheless, MRI of the brain should be performed in a situation when clinical diagnosis of complicated migraine is uncertain or when the parents are concerned. This will provide acceptance of the diagnosis and treatment. Routinely performed brain CT in Emergency Department, unless an intracranial hemorrhage is suspected, is not a cost effective way of entertaining the diagnosis of complicated migraine.

The use of newer MRI sequences in the evaluation of complicated migraine has revealed pathophysiology. The select multimodality neuroimaging and their results are provided in Table 6[42-45].

Transcranial magnetic stimulation is another non-invasive tool to investigate the central nervous system abnormality. There is compelling evidence that cortical excitability is modified in migraine patients even between attacks[46].

Rarely occurring migrainous infarction mostly occurs in the posterior cerebral circulation in younger women with migraine with aura. Acute ischemic

Table 5 Shows select cerebrospinal fluid biochemical changes which help to distinguish between bacterial meningitis, aseptic meningitis, and migraine attacks[34-39]

Increased level in cerebrospinal fluid	Comments
Lactate	> 3.5 mmol/L is a good predictor of bacterial meningitis[34]
Procalcitonin	> 0.5 ng/mL is a good predictor of bacterial meningitis[35]
Ferritin	106.39 +/- 86.96 ng/ dL (n = 24) was considerably higher than the viral meningitis group (10.17 +/- 14.09, P < 0.001)[36]
Cytokines	Children with mumps meningitis (n = 19), echovirus 30 meningitis (n = 22), with comparison to children without meningitis (n = 21)[37]
Glutamic acid	An excess of neuroexcitatory amino acids during migraine attacks supports a state of neuronal hyperexcitability[38]
5-hydroxyindoleacetic acid	Level was higher in migraine than the controls[39]

Cerebrospinal fluid and systemic biochemical changes in migraine are complex, contradictory, and often unreplicated. Generally accepted CSF changes are as follows: (1) Changes in neuroexcitatory amino acids and magnesium; (2) Changes of vasoactive peptides in trigemino-vascular system; (3) Catecholaminergic changes suggesting sympathetic over activity; (4) Alterations in methionine-encephalin levels; and (5) Systemic changes include derangement of 5-Hydroxytryptophan metabolism hormonal fluctuations in female to precipitate migraine attack[40]. CSF: Cerebrospinal fluid.

Table 6 List the select reports of the use of multimodaility and their results primarily in children with prolonged hemiplegic migraine[42-45]

Neuroimaging type and the clinical conditions	Study revealed
Multimodality neuroimaging in a single familial hemiplegic migraine[42]	Cytotoxic edema along with evidence of hypometabolism but no evidence of hypoperfusion of the affected cerebral hemisphere
Perfusion- and susceptibility-weighted imaging in a 13-year-old-female 3 h after the right hemiplegia[43]	Hypoperfusion in the left cerebral hemisphere and a matching prominent hypotensity, respectively. Diffusion tensor imaging sequences were normal. These abnormalities completely resolved 24 h after the attack onset
Perfusion- and diffusion-weighted MRI during visual auras in four migraineurs[44]	Cerebral blood flow and volume, both decreased by 16%-53% and 6%-33%, respectively. Mean transit time in the affected occipital cortex was increased by 10%-54%. No changes in the diffusion coefficient were observed during and after the resolution of the visual aura
Brain MRI in six population and 13 clinic-based meta-analysis studies in migraines with and without aura[45]	White matter abnormalities, silent infarct-like lesions, and volumetric changes in both gray and white matter regions were more common in migraineurs than in control groups. These data suggest that migraine may be a risk factor for structural changes in the brain

Some of these conflicting reports support the clinically observed variability in the manifestation of the migraine. MRI: Magnetic resonance imaging.

lesions are often multiple and located in distinct arterial territories[47].

NEUROPHYSIOLOGIC STUDIES

In complicated migraine, the role of neurophysiologic studies, EEG, and visual evoked potential (VEP) are very limited. But it has increased our understanding regarding the physiologic dysfunction of the spectrum of migraine.

Electroencephalography

An EEG is not recommended in the management of headache or migraine. Data on the role of EEG in diagnosis of complicated migraines is limited. However, it plays a supportive role when performed in the context of seizure or seizure like activity precipitated by migraine and when a non epileptic seizure is being considered.

Nejad Biglari *et al*[48] study revealed EEG abnormality in 20% of patients with migraine. Distribution of the migraine type included migraine without aura 63%, migraine with aura 23%, migraine variant 8%, and epileptic syndromes 5%. Comparing the EEG abnormalities with the type of migraine revealed a significant association with migraine with aura (P = 0.03).

Manifestation of visual symptoms together with postictal headache during occipital seizure can be mistaken for migraine with visual aura. In such situations, the EEG monitoring is crucial for reaching the correct diagnosis[49].

Visual Evoked Potential

Visual Evoked Potential (VEP) findings in migraine support the theory of neuronal sensory excitability of the occipital cortices. The central nervous dysfunction specific to migraine can be detected during headache and headache free period. The evoked potential amplitude is a quantitative index of the neuronal population activated by certain sensory inputs. It tends to decrease progressively as a normal response during repetitive sensory stimulation which is known as habituation. The habituation occurs to a lesser degree when brain is more excitable or central nervous systems that regulate habituation are less

active.

A reduced habituation of visual evoked potential has been reported. Spreafico *et al*[50] studied VEPs in 53 migraineurs, 21 with preventive therapy and 32 with no preventive therapy, and 20 healthy controls. In comparison to healthy controls, P100 latencies in no therapy group were lower and in therapy group were same. They speculated that the different responsiveness of the visual system in migraineurs is probably due to a dysmodulation of sensor input leading to facilitation of visual processing.

Bjørk *et al*[51], recorded steady state visual evoked potential and EEG-responses for specific flash stimuli from 33 migraineurs without aura, 8 migraineurs with aura, and 32 healthy controls. Before attack, driving power of 12 Hz. was increased. Attacks trigger light sensitivity, photophobia, and pain intensity. Between attacks, driving responses to 18 Hz. and 24 Hz. were attenuated in migraineurs without aura. They concluded that abnormal photic driving may be related to the pathophysiology of clinical sensory hypersensitivity.

How far should one investigate?

It is important to decide how far one should investigate? Continued investigation without a clinical explanation, when the results of the tests are normal, may further enhance an already anxious parent. In fact, it may delay the diagnosis of complicated migraine. Viticchi *et al*[52], analyzed 400 consecutive patients with migraine without aura to evaluate whether EEG performance negatively influences the time necessary in obtaining a correct diagnosis. Delay was defined as a time to diagnosis greater than 1-year. It was associated with a significant risk of diagnostic delay (OR = 1.66, 95%CI: 1.65-1.66, $P < 0.001$) EEG represented the most often (20%) performed non-radiologic examination.

THERAPEUTIC MANAGEMENT

No clinical treatment trials are available in children with complicated migraine. Thus, the treatment is based on empirical data, often extrapolated from adults, and most importantly from the personal experience of the treating physician. In the case of complicated migraine, once the diagnosis is made the treatment strategy is similar to migraine with disability or when the patient's daily routine is interrupted.

In Emergency Department, the primary goal for evaluation of the children with complicated migraine is to identify those who have a treatable condition or a disorder associated with high morbidity or mortality (Table 4). The initial management should focus on vital signs and signs of increased intracranial pressure[53], and on providing the symptomatic and supportive treatments.

Symptomatic or supportive care is the backbone of the clinical management. Its prompt implementation even in lack of a definitive diagnosis leads to the best possible outcome. Urgent medical interventions include hydration with intravenous fluid and symptomatic treatment for the associated symptoms. Symptomatic treatments for nausea, vomiting, abdominal pain, and headache should be administered selectively. This is all that is needed in most patients with complicated migraine. A sleeping aid which is the best known conservative abortive therapy for migraine should be considered[54,55].

Richer *et al*[56] from their randomized controlled trial of treatment expectation and intravenous fluid in the Emergency Department, concluded that intravenous fluid hydration has a clinically meaningful response in 17.8% children with migraine. The overall decrease in pain was insignificant at 30 min. Recurrence of headache was common in 33% children after the Emergency Department discharge.

In Pediatric Emergency Department when the combination of standard intravenous therapy (n = 87) was compared with non-standardized therapy (n = 165), the standardized combination therapy was effective in reducing head pain scores (decrease of 5.3 *vs* 6.9, $P < 0.001$), length of emergency department stay (5.3 *vs* 4.4 h, $P = 0.008$), and hospital admission rates (32% *vs* 3%, $P < 0.001$). The standardized therapy included a normal saline fluid bolus, ketorolac, prochlorperazine, and diphenhydramine. Metoclopramide was occasionally substituted during prochlorperazine shortages[56].

In the presence of nausea, vomiting, and a reduced gastric emptying known to occur during migraine attack[57,58], medications should be administered intravenously. This intervention is particularly important if the overuse of oral analgesics is suspected.

Abortive therapy

Due to the transient self-limiting nature of complicated migraine, abortive therapy with triptan is usually not needed in complicated migraine. However, the triptan is useful in those patients who have infrequent attacks with disability. Due to vasoconstrictive side effect triptans are contraindicated in patients with hemiplegic migraine. In such a situation, the use of verapamil antimigrainous preventing future attacks is recommended[59].

If admitted, inpatient management goal is to reaffirm the initial diagnosis and to identify those children who will need a daily drug prophylaxis. What will be the best drug in a particular patient with complicated migraine? Author's (SG) personal preference is to provide assurance, institute a regular lifestyle, and initiate an antimigrainous therapy, if needed. These elements also alleviate the future need for triptan use.

Assurance to the parents in an acute setting is a basic and an essential part for calming down the parental anxiety. It encourages their active participation and increases parental acceptance for the drug's compliance. Assurance begins with the very first encounter long before making the diagnosis. Based upon an existing problem and a potential unfolding new complication, the clinical diagnosis should be presented with confidence. An upfront plan for realistic expectations and a timely intervention should be discussed.

Antimigrainous preventive therapy

Rarely, new onset vivid or prolonged symptom such as hemiparesis, vision loss, or seizure like activity as a manifestation of the migraine may demand the initiation of a preventive therapy[60]. However, if the symptoms become episodic or child has missed school days secondary to migraine, a daily antimigrainous drug therapy to prevent future attacks is indicated.

Before starting antimigrainous drug therapy, it is equally important if not more important to instruct the patient to simultaneously institute three elements, to sleep on time, eat on time, and take analgesic at the first onset of a migraine symptom. It is important to realize that it is not the type or dosage of an analgesic rather it is the timing when analgesic is taken that is an effective intervention. The first two have a preventive role like the preventive drug in decreasing the frequency and severity of the migraines. The analgesic use lessens the severity of the ongoing episode. The regular lifestyle and analgesic use are not a substitute rather they have a complementary role in providing an optimum antimigrainous benefit in majority of children with migraine with disability.

Many preventive agents are safe but none are currently FDA-approved for children. Controlled clinical trials investigating the use of both abortive and preventive medications have high placebo response rates. Furthermore, the shorter duration of headaches and other unusual features seen in children make designing of randomized controlled trials problematic. As a result the majority of children who present to doctor's office with migraine's disability do not receive prophylactic therapy. As such due to lack of evidence-based guidelines the antimigrainous prophylactic therapy practices vary widely even among pediatric neurologists[61].

The goal of antimigrainous prophylactic drug therapy is to prevent future migraine attack rather than merely headache. This requires a comprehensive approach and prophylactic therapy works best in conjunction with above described three elements of conservative therapy. In lack of their reenforcement the drug therapy alone is likely to have less than optimum results.

Antimigrainous drug: Selection and dosage

Amongst a large number and different classes of medication, cyproheptadine (antihistaminic), propranolol (beta blocker), topiramate (antiepileptic), amitriptyline (antidepressant), and verapamil (calcium channel blocker) are a short list of drugs to manage the majority of the children with migraine. Which drug should be used in a particular patient? That should be selected based on the presence of the second common symptom which is bothersome for the patient.

Drug's side effect should be taken advantage of in the management. For example, for an associated poor appetite in young children cyproheptadine; for an increased sympathetic symptom in young adult such as anxiety, irritability, tremor, or palpitation, propranolol; and in the presence of an increased body mass index, migraine precipitated seizure, or pseudotumor cerebri, topiramate should be considered. The physician should familiarize themselves with at least three drugs and their dosages, cyproheptadine, proponolol, and topiramate. The parental concern of side effects can be minimized by starting a small dose of the selected drug and setting an individualized preventive goal for the drug therapy.

NEUROLOGICAL OUTCOME

In the absence of any other identifiable etiology children with complicated migraine have a full clinical recovery. With an exception of a rarely occurring alternating hemiplegia, complicated migraines are non-progressive. However, the migraine variants are likely to evolve to a full blown migraine in adult life.

The long-term course of migraine with aura has been explored. A study of an 11-year follow-up natural history of 77 children with migraine with aura revealed 23.4% headache-free, 44.1% still had migraine with aura. And 32.5% children with migraine with aura transformed to other types of headache. Children with basilar type migraine showed the highest (38.5%) headache remission rate. The remission of aura occurred in 54.1% of the children. A lower rate of remission occurred in those with visual, sensory, or aphasic aura[62].

MEDICOLEGAL IMPLICATION

Multiple clinical situations in complicated migraine may lead to the medical legal issues. The physician is likely to be implicated in a delay in making or making an incorrect diagnosis. A wide spectrum and the fragmented presentation in time and space may result in medicolegal issues. Unawareness of these syndromes may be anxiety provoking leading to extensive investigations causing delay in a clinically based diagnosis. On the other hand, a casual diagnosis may fall too short in making a correct diagnosis. To add to the perplexity, CSF examination may reveal pleocytosis. The presence of fever, vomiting, or other constitutional symptoms early in the course of the illness should direct physician to a

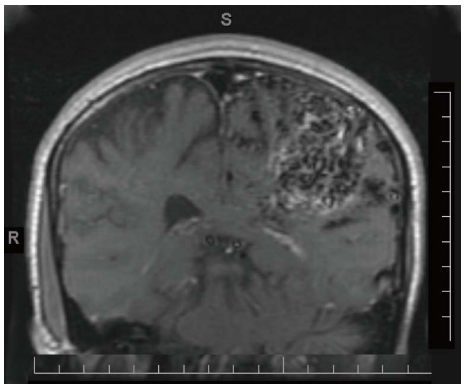

Figure 1 Coronal fluid-attenuated inversion recovery weighted image in a 15-year-old male with previous diagnosis of migraine with aura revealed the left parietal lobe arteriovenous malformations. This was suspected based upon a history of slowly evolving prolonged right hemisensory cutaneous aura. Onset of a new condition in migraine simulates the previous migraine attack. Implication of missing or delay in diagnosis of the second condition can be prevented by differential thinking regarding mixed sympotomatology of both conditions.

correct diagnosis[63].

Second condition in migraine

Children with migraine at onset of a new condition, such as acute infection, arteriovenous malformation, or brain tumor, may simulate like the previous migraine attack profile. They are likely to present with a mixed symptomatology of migraine and of the second condition. In such a situation, the diagnosis of a new condition is easily overlooked. This can be prevented by a differential thinking regarding both conditions. An MRI of the brain of a 15-year-old male with previous diagnosis of migraine with aura revealed the left parietal arteriovenous malformation (Figure 1). This was suspected based upon a history of slowly evolving prolonged right hemisensory cutaneous aura.

Medicolegal implication can be avoided by closely following the described common clinical profiles for the complicated migraine, migraine without aura, and being attentive to the clinical characteristics of the migraine like syndromes (Table 4). The clinicians should get acquainted with a fragmented presentation of migraines in avoidance of the medicolegal implications.

Future

Progressively increasing health cost demands a direct critical and differential thinking of the presenting symptoms in the diagnosis of complicated migraine.

What is the status of migraine variant in the IHS classification? How to express collectively about two dozens of conditions with a common clinical profile, and how to distinguish complicated migraine from complication of migraine? The future classification system should clarify these questions.

The neurophysiologic studies with evoked potential and functional neuroimaging are likely to play an important role in future understanding of pathophysiology and to explore the novel therapeutic strategies for complicated migraine. Metabolic changes of the cortex and subcortical structures in complicated migraine should be assessed by transcranial magnetic stimulation or near-infrared spectroscopy[64].

CONCLUSION

This is the first report of a common profile in aid to the clinical diagnosis of complicated migraine. Both groups of children, well-described or not yet described individual syndromes of complicated migraine, can be diagnosed clinically by their common clinical profile; an acute onset and a relatively short and self-limiting course of the neurologic manifestations other than headache of unidentifiable etiology.

Complicated migraine does not only mimic conditions like seizure, non-epileptic event, transient ischemic attack, or stroke but it can also cause them. At times, normal results incite further anxiety and thus, more testing and as a result delay in diagnosis. For these reasons, the clinicians should be aware of this very much concerning the common neurological conditions presenting in the Emergency Department.

Adherence to the proposed common clinical profile will improve the accuracy of clinical diagnosis. It will optimize the use of laboratory tests. Once the complicated migraine is considered, they do not impose a diagnostic difficulty. This systematic approach in a timely manner is essential in avoidance of a medicolegal implication. In addition, we provided a common preventive treatment strategy for the treatment of the migraines.

Future classification should minimize the separation of the clinically encountered syndromes and should coin a single word to address collectively this subtype of acute migraine with a common clinical profile. Future clinical review should evaluate the applicability of the proposed clinical profile in making the diagnosis of the individual syndromes of complicated migraine.

ACKNOWLEDGMENTS

The authors acknowledge our sincere thanks to Aziez Ahmed, MD and Susan R Medalie, OMS-IV for their critical review of this manuscript.

REFERENCES

1 **Hargreaves RJ**, Shepheard SL. Pathophysiology of migraine--new insights. *Can J Neurol Sci* 1999; **26** Suppl 3: S12-S19 [PMID: 10563228]

2 **Silberstein SD.** Advances in understanding the pathophysiology of headache. *Neurology* 1992; **42** Suppl 2: 6-10

3 Classification and diagnostic criteria for headache disorders, cranial neuralgias and facial pain. Headache Classification Committee of the International Headache Society. *Cephalalgia* 1988; **8** Suppl 7: 1-96 [PMID: 3048700]

4 **Headache Classification Committee of the International**

Headache Society (IHS). The International Classification of Headache Disorders, 3rd ed (beta version). *Cephalalgia* 2013; **33**: 629-808 [PMID: 23771276 DOI: 10.1177/0333102413485658]

5 **Kakisaka Y**, Ohara T, Katayama S, Suzuki T, Hino-Fukuyo N, Uematsu M, Kure S. Lower back pain as a symptom of migrainous corpalgia. *J Child Neurol* 2013; **28**: 676-677 [PMID: 23446803 DOI: 10.1177/0883073813478170]

6 **Durán-Ferreras E**, Viguera J, Patrignani G, Martínez-Parra C. Epistaxis accompanying migraine attacks. *Cephalalgia* 2007; **27**: 958-959 [PMID: 17661869 DOI: 10.1111/j.1468-2982.2007.01370.x]

7 **Pacheva IH**, Ivanov IS. Migraine variants--occurrence in pediatric neurology practice. *Clin Neurol Neurosurg* 2013; **115**: 1775-1783 [PMID: 23688445 DOI: 10.1016/j.clineuro.2013.04.012]

8 **Teixeira KC**, Montenegro MA, Guerreiro MM. Migraine equivalents in childhood. *J Child Neurol* 2014; **29**: 1366-1369 [PMID: 24092892 DOI: 10.1177/0883073813504459]

9 **Reid JM**, Currie Y, Baird T. Non-stroke admissions to a hyperacute stroke unit. *Scott Med J* 2012; **57**: 209-211 [PMID: 23002155 DOI: 10.1258/smj.2012.012119]

10 **Tfelt-Hansen PC**, Koehler PJ. One hundred years of migraine research: major clinical and scientific observations from 1910 to 2010. *Headache* 2011; **51**: 752-778 [PMID: 21521208 DOI: 10.1111/j.1526-4610.2011.01892.x]

11 **Baimaj V**. Chromosomal polymorphisms of constitutive heterochromatin and inversions in Drosophila. *Genetics* 1977; **85**: 85-93 [PMID: 838273]

12 **Gursoy-Ozdemir Y**, Qiu J, Matsuoka N, Bolay H, Bermpohl D, Jin H, Wang X, Rosenberg GA, Lo EH, Moskowitz MA. Cortical spreading depression activates and upregulates MMP-9. *J Clin Invest* 2004; **113**: 1447-1455 [PMID: 15146242 DOI: 10.1172/JCI200421227]

13 **Ayata C**. Cortical spreading depression triggers migraine attack: pro. *Headache* 2010; **50**: 725-730 [PMID: 20456160 DOI: 10.1111/j.1526-4610.2010.01647.x]

14 **Rogawski MA**. Common pathophysiologic mechanisms in migraine and epilepsy. *Arch Neurol* 2008; **65**: 709-714 [PMID: 18541791 DOI: 10.1001/archneur.65.6.709]

15 **Piccinelli P**, Borgatti R, Nicoli F, Calcagno P, Bassi MT, Quadrelli M, Rossi G, Lanzi G, Balottin U. Relationship between migraine and epilepsy in pediatric age. *Headache* 2006; **46**: 413-421 [PMID: 16618257 DOI: 10.1111/j.1526-4610.2006.00373.x]

16 **Schipper S**, Riederer F, Sándor PS, Gantenbein AR. Acute confusional migraine: our knowledge to date. *Expert Rev Neurother* 2012; **12**: 307-314 [PMID: 22364329 DOI: 10.1586/ern.12.4]

17 **Naeije G,** Gaspard N, Legros B, Mavroudakis N, Pandolfo M. Transient CNS deficits and migrainous auras in individuals without a history of headache. *Headache* 2014; **54**: 493-499 [PMID: 24673438 DOI: 10.1111/head.12307]

18 **Pacheva I**, Ivanov I. Acute confusional migraine: is it a distinct form of migraine? *Int J Clin Pract* 2013; **67**: 250-256 [PMID: 23409692 DOI: 10.1111/ijcp.12094]

19 **Datta SS**, Kumar S. Hypomania as an aura in migraine. *Neurol India* 2006; **54**: 205-206 [PMID: 16804272]

20 **Verrotti A**, Coppola G, Di Fonzo A, Tozzi E, Spalice A, Aloisi P, Bruschi R, Iannetti P, Villa MP, Parisi P. Should "migralepsy" be considered an obsolete concept? A multicenter retrospective clinical/EEG study and review of the literature. *Epilepsy Behav* 2011; **21**: 52-59 [PMID: 21497557]

21 **Laurell K**, Lundström E. Migrainous infarction: aspects on risk factors and therapy. *Curr Pain Headache Rep* 2012; **16**: 255-260 [PMID: 22527790 DOI: 10.1007/s11916-012-0262-2]

22 **Gupta SN,** Gupta VS. Bilateral Tongue Bite during Epileptic Seizure: Nomenclature and Mechanism. *Austin J Neurol Disord Epilepsy* 2014; **1**: 2

23 **Kurth T**. The association of migraine with ischemic stroke. *Curr Neurol Neurosci Rep* 2010; **10**: 133-139 [PMID: 20425238 DOI: 10.1007/s11910-010-0098-2]

24 **Noseda R,** Kainz V, Borsook D, Burstein R. Neurochemical pathways that converge on thalamic trigeminovascular neurons: potential substrate for modulation of migraine by sleep, food intake, stress and anxiety. *PLoS One* 2014; **9**: 103929 [PMID: 25090640 DOI: 10.1371/journal.pone.0103929]

25 **Verma R**, Lalla R. Increased frequency of headache and change in visual aura due to occipital cysticercus granuloma. *BMJ Case Rep* 2012; **2012**: bcr2012006919 [PMID: 22962401]

26 **Sartor H**, Thoden U. [Migraine with aura as early symptom of neurosyphilis]. *Schmerz* 1999; **13**: 48-50 [PMID: 12799949 DOI: 10.1007/s004820050183]

27 **Nomura S**, Shimakawa S, Fukui M, Tanabe T, Tamai H. Lamotrigine for intractable migraine-like headaches in Sturge-Weber syndrome. *Brain Dev* 2014; **36**: 399-401 [PMID: 23877022 DOI: 10.1016/j.braindev.2013.06.009]

28 **Dawood N**, Desjobert E, Lumley J, Webster D, Jacobs M. Confirmed viral meningitis with normal CSF findings. *BMJ Case Rep* 2014; **2014**: bcr2014203733 [PMID: 25035443]

29 **Pavone P**, Conti I, Le Pira A, Pavone L, Verrotti A, Ruggieri M. Primary headache: role of investigations in a cohort of young children and adolescents. *Pediatr Int* 2011; **53**: 964-967 [PMID: 22010801 DOI: 10.1111/j.1442-200X.2011.03493.x]

30 **Negrini B**, Kelleher KJ, Wald ER. Cerebrospinal fluid findings in aseptic versus bacterial meningitis. *Pediatrics* 2000; **105**: 316-319 [PMID: 10654948 DOI: 10.1542/peds.105.2.316]

31 **Seehusen DA**, Reeves MM, Fomin DA. Cerebrospinal fluid analysis. *Am Fam Physician* 2003; **68**: 1103-1108 [PMID: 14524396]

32 **Harrington MG**, Fonteh AN, Cowan RP, Perrine K, Pogoda JM, Biringer RG, Hühmer AF. Cerebrospinal fluid sodium increases in migraine. *Headache* 2006; **46**: 1128-1135 [PMID: 16866716 DOI: 10.1111/j.1526-4610.2006.00445.x]

33 **Day TJ**, Knezevic W. Cerebrospinal-fluid abnormalities associated with migraine. *Med J Aust* 1984; **141**: 459-461 [PMID: 6472188]

34 **Mekitarian Filho E**, Horita SM, Gilio AE, Nigrovic LE. Cerebrospinal fluid lactate level as a diagnostic biomarker for bacterial meningitis in children. *Int J Emerg Med* 2014; **7**: 14 [PMID: 24576334 DOI: 10.1186/1865-1380-7-14]

35 **Konstantinidis T,** Cassimos D, Gioka T, Tsigalou C, Parasidis T, Alexandropoulou I, Nikolaidis C, Kampouromiti G, Constantinidis T, Chatzimichael A, Panopoulou M. Can Procalcitonin in Cerebrospinal Fluid be a Diagnostic Tool for Meningitis? *J Clin Lab Anal* 2014 May 5; Epub ahead of print [PMID: 24797775 DOI: 10.1002/jcla.21746]

36 **Rezaei M**, Mamishi S, Mahmoudi S, Pourakbari B, Khotaei G, Daneshjou K, Hashemi N. Cerebrospinal fluid ferritin in children with viral and bacterial meningitis. *Br J Biomed Sci* 2013; **70**: 101-103 [PMID: 24273895]

37 **Sulik A,** Kroten A, Wojtkowska M, Oldak E. Increased levels of cytokines in cerebrospinal fluid of children with aseptic meningitis caused by mumps virus and echovirus. *Scand J Immunol* 2014; **79**: 68-72 [PMID: 24313836 DOI: 10.1111/sji.12131]

38 **Martínez F**, Castillo J, Rodríguez JR, Leira R, Noya M. Neuroexcitatory amino acid levels in plasma and cerebrospinal fluid during migraine attacks. *Cephalalgia* 1993; **13**: 89-93 [PMID: 8098663 DOI: 10.1046/j.1468-2982.1993.1302089.x]

39 **Kovács K**, Bors L, Tóthfalusi L, Jelencsik I, Bozsik G, Kerényi L, Komoly S. Cerebrospinal fluid (CSF) investigations in migraine. *Cephalalgia* 1989; **9**: 53-57 [PMID: 2468418 DOI: 10.1046/j.1468-2982.1989.901053.x]

40 **Martens D**, Oster I, Gottschlling S, Papanagiotou P, Ziegler K, Eymann R, Ong MF, Gortner L, Meyer S. Cerebral MRI and EEG studies in the initial management of pediatric headaches. *Swiss Med Wkly* 2012; **142**: w13625 [PMID: 22782255]

41 **Gupta S**, Kanamalla U, Gupta V. Are incidental findings on brain magnetic resonance images in children merely incidental? *J Child Neurol* 2010; **25**: 1511-1516 [PMID: 20558674 DOI: 10.1177/0883073810370622]

42 **Kumar G**, Topper L, Maytal J. Familial hemiplegic migraine with prolonged aura and multimodality imaging: a case report. *Headache* 2009; **49**: 139-142 [PMID: 18624711 DOI: 10.1111/j.1526-4610.2008.01180.x]

43 **Bosemani T**, Burton VJ, Felling RJ, Leigh R, Oakley C, Poretti A,

Huisman TA. Pediatric hemiplegic migraine: role of multiple MRI techniques in evaluation of reversible hypoperfusion. *Cephalalgia* 2014; **34**: 311-315 [PMID: 24142848]
44 **Cutrer FM**, Sorensen AG, Weisskoff RM, Ostergaard L, Sanchez del Rio M, Lee EJ, Rosen BR, Moskowitz MA. Perfusion-weighted imaging defects during spontaneous migrainous aura. *Ann Neurol* 1998; **43**: 25-31 [PMID: 9450765 DOI: 10.1002/ana.410430108]
45 **Bashir A**, Lipton RB, Ashina S, Ashina M. Migraine and structural changes in the brain: a systematic review and meta-analysis. *Neurology* 2013; **81**: 1260-1268 [PMID: 23986301 DOI: 10.1212/WNL.0b013e3182a6cb32]
46 **Fumal A**, Bohotin V, Vandenheede M, Schoenen J. Transcranial magnetic stimulation in migraine: a review of facts and controversies. *Acta Neurol Belg* 2003; **103**: 144-154 [PMID: 14626694]
47 **Wolf ME**, Szabo K, Griebe M, Förster A, Gass A, Hennerici MG, Kern R. Clinical and MRI characteristics of acute migrainous infarction. *Neurology* 2011; **76**: 1911-1917 [PMID: 21624990 DOI: 10.1212/WNL.0b013e31821d74d5]
48 **Nejad Biglari H**, Rezayi A, Nejad Biglari H, Alizadeh M, Ahmadabadi F. Relationship between migraine and abnormal EEG findings in children. *Iran J Child Neurol* 2012; **6**: 21-24 [PMID: 24665268]
49 **Italiano D**, Grugno R, Calabrò RS, Bramanti P, Di Maria F, Ferlazzo E. Recurrent occipital seizures misdiagnosed as status migrainosus. *Epileptic Disord* 2011; **13**: 197-201 [PMID: 21636355]
50 **Spreafico C**, Frigerio R, Santoro P, Ferrarese C, Agostoni E. Visual evoked potentials in migraine. *Neurol Sci* 2004; **25** Suppl 3: S288-S290 [PMID: 15549564 DOI: 10.1007/s10072-004-0313-5]
51 **Bjørk M**, Hagen K, Stovner Lj, Sand T. Photic EEG-driving responses related to ictal phases and trigger sensitivity in migraine: a longitudinal, controlled study. *Cephalalgia* 2011; **31**: 444-455 [PMID: 21098109 DOI: 10.1177/0333102410385582]
52 **Viticchi G**, Falsetti L, Silvestrini M, Luzzi S, Provinciali L, Bartolini M. The real usefulness and indication for migraine diagnosis of neurophysiologic evaluation. *Neurol Sci* 2012; **33** Suppl 1: S161-S163 [PMID: 22644194 DOI: 10.1007/s10072-012-1074-1]
53 **Nallasamy K**, Singhi SC, Singhi P. Approach to headache in emergency department. *Indian J Pediatr* 2012; **79**: 376-380 [PMID: 22012137 DOI: 10.1007/s12098-011-0570-2]
54 **Guidetti V**, Dosi C, Bruni O. The relationship between sleep and headache in children: implications for treatment. *Cephalalgia* 2014; **34**: 767-776 [PMID: 24973419 DOI: 10.1177/0333102414541817]
55 **Singh NN**, Sahota P. Sleep-related headache and its management. *Curr Treat Options Neurol* 2013; **15**: 704-722 [PMID: 24132786 DOI: 10.1007/s11940-013-0258-1]
56 **Richer L**, Craig W, Rowe B. Randomized controlled trial of treatment expectation and intravenous fluid in pediatric migraine. *Headache* 2014; **54**: 1496-1505 [PMID: 25168404 DOI: 10.1111/head.12443]
57 **Leung S**, Bulloch B, Young C, Yonker M, Hostetler M. Effectiveness of standardized combination therapy for migraine treatment in the pediatric emergency department. *Headache* 2013; **53**: 491-497 [PMID: 23406529 DOI: 10.1111/head.12042]
58 **Yalcin H**, Okuyucu EE, Ucar E, Duman T, Yilmazer S. Changes in liquid emptying in migraine patients: diagnosed with liquid phase gastric emptying scintigraphy. *Intern Med J* 2012; **42**: 455-459 [PMID: 22498119 DOI: 10.1111/j.1445-5994.2012.02741.x]
59 **Chu ER**, Lee AW, Chen CS. Resolution of visual field constriction with verapamil in a patient with bilateral optic neuropathy, migraine and Raynaud's phenomenon. *Intern Med J* 2009; **39**: 851-853 [PMID: 20233249 DOI: 10.1111/j.1445-5994.2009.02080.x]
60 **Pelzer N**, Stam AH, Haan J, Ferrari MD, Terwindt GM. Familial and sporadic hemiplegic migraine: diagnosis and treatment. *Curr Treat Options Neurol* 2013; **15**: 13-27 [PMID: 23203776 DOI: 10.1007/s11940-012-0208-3]
61 **Kacperski J**, Hershey AD. Preventive drugs in childhood and adolescent migraine. *Curr Pain Headache Rep* 2014; **18**: 422 [PMID: 24760491 DOI: 10.1007/s11916-014-0422-7]
62 **Termine C**, Ferri M, Livetti G, Beghi E, Salini S, Mongelli A, Blangiardo R, Luoni C, Lanzi G, Balottin U. Migraine with aura with onset in childhood and adolescence: long-term natural history and prognostic factors. *Cephalalgia* 2010; **30**: 674-681 [PMID: 20511205 DOI: 10.1177/0333102409351803]
63 **Rossi LN**, Vassella F, Bajc O, Tönz O, Lütschg J, Mumenthaler M. Benign migraine-like syndrome with CSF pleocytosis in children. *Dev Med Child Neurol* 1985; **27**: 192-198 [PMID: 3996776 DOI: 10.1111/j.1469-8749.1985.tb03769.x]
64 **Obrig H**. NIRS in clinical neurology - a 'promising' tool? *Neuroimage* 2014; **85** Pt 1: 535-546 [PMID: 23558099]

P- Reviewer: Al-Haggar M, Classen CF, Romano C
S- Editor: Tian YL **L- Editor**: A **E- Editor**: Lu YJ

Published by **Baishideng Publishing Group Inc**
8226 Regency Drive, Pleasanton, CA 94588, USA
Telephone: +1-925-223-8242
Fax: +1-925-223-8243
E-mail: bpgoffice@wjgnet.com
Help Desk: http://www.wjgnet.com/esps/helpdesk.aspx
http://www.wjgnet.com

© 2015 Baishideng Publishing Group Inc. All rights reserved.

ISSN 2219-2808 (online)

World Journal of *Clinical Pediatrics*

World J Clin Pediatr 2015 May 8; 4(2): 13-34

Published by Baishideng Publishing Group Inc

WJCP World Journal of Clinical Pediatrics

A peer-reviewed, online, open-access journal of clinical pediatrics

Editorial Board

2012-2016

The *World Journal of Clinical Pediatrics* Editorial Board consists of 247 members, representing a team of worldwide experts in pediatrics. They are from 43 countries, including Argentina (1), Australia (7), Austria (4), Belgium (2), Brazil (4), Canada (7), Chile (2), China (22), Denmark (2), Egypt (10), Finland (1), France (5), Germany (4), Greece (8), India (14), Iran (5), Israel (7), Italy (22), Japan (6), Mexico (2), Netherlands (2), New Zealand (1), Nigeria (3), Norway (1), Pakistan (2), Poland (2), Portugal (1), Russia (2), Saudi Arabia (2), Serbia (2), Singapore (3), Slovenia (1), South Africa (2), South Korea (2), Spain (5), Sweden (4), Switzerland (1), Thailand (2), Tunisia (1), Turkey (18), United Arab Emirates (1), United Kingdom (11), United States (43).

EDITOR-IN-CHIEF
Eduardo H Garin, *Gainesville*

GUEST EDITORIAL BOARD MEMBERS
Hsiao-Wen Chen, *Taipei*
Ming-Ren Chen, *Taipei*
Mu-Kuan Chen, *Changhua*
Ching-Chi Chi, *Chiayi*
Hung-Chih Lin, *Taichung*

MEMBERS OF THE EDITORIAL BOARD

Argentina

Alcides Richard Troncoso, *Buenos Aires*

Australia

Garry Inglis, *Herston*
Jagat Kanwar, *Victoria*
Katherine Kedzierska, *Parkville*
Eline Suzanne Klaassens, *Brisbane*
Sam S Mehr, *Sydney*
Jing Sun, *Brisbane*
Cuong Duy Tran, *Adelaide*

Austria

Gerhard Cvirn, *Graz*
Claudia Elisabeth Gundacker, *Vienna*
Bernhard Resch, *Graz*
Amulya K Saxena, *Graz*

Belgium

Karel Allegaert, *Leuven*
Yvan Vandenplas, *Brussels*

Brazil

Rejane Correa Marques, *Rio de Janeiro*
Priscila Krauss Pereira, *Rio de Janeiro*
Maria L Seidl-de-Moura, *Rio de Janeiro*
Sandra Elisabete Vieira, *São Paulo*

Canada

Helen SL Chan, *Toronto*
Ediriweera Desapriya, *Vancouver*
Eleftherios P Diamandis, *Toronto*
Ran D Goldman, *Vancouver*
Manjula Gowrishankar, *Edmonton*
Prakesh S Shah, *Toronto*
Pia Wintermark, *Montreal*

Chile

René Mauricio Barría, *Valdivia*
Irene Morales Bozo, *Santiago*

China

Yu-Zuo Bai, *Shenyang*
Xiao-Ming Ben, *Nanjing*
Kwong-Leung Chan, *Hong Kong*
Xian-Hui He, *Guangzhou*
Jian Hu, *Harbin*
Xi-Tai Huang, *Tianjin*
Huang-Xian Ju, *Nanjing*
Ren Lai, *Kunming*
Li Liu, *Xi'an*
Xue-Qun Luo, *Guangzhou*
Ai-Guo Ren, *Beijing*
Chiu-Lai Shan, *Hong Kong*
Yuk Him Tam, *Hong Kong*
Jin-Xing Wang, *Jinan*
Jun-Jun Wang, *Beijing*
Long-Jiang Zhang, *Nanjing*
Yi-Hua Zhou, *Nanjing*

Denmark

Jesper Bo Nielsen, *Odense*
Ole D Wolthers, *Randers*

Egypt

Mosaad Abdel-Aziz, *Cairo*
Hesham E Abdel-Hady, *Mansoura*
Mohammed Al-Biltagi, *Tanta*
Mohammad MS Al-Haggar, *Mansoura*
Ashraf MAB Bakr, *Mansoura*
Badr Eldin Mostafa, *Cairo*
Rania Refaat, *Cairo*
Omar Mamdouh Shaaban, *Assiut*
Maysaa El Sayed Zaki, *Mansoura*
Magdy Mohamed Zedan, *Mansoura*

Finland

Bright Ibeabughichi Nwaru, *Tampere*

France

Philippe Georgel, *Strasbourg*
Grill Jacques, *Villejuif*

Manuel Lopez, *Saint Etienne*
Georgios Stamatas, *Issy-les-Moulineaux*
Didier Vieau, *Villeneuve d'Ascq*

Germany

Yeong-Hoon Choi, *Cologne*
Carl Friedrich Classen, *Rostock*
Stephan Immenschuh, *Hannover*
Ales Janda, *Freiburg im Breisgau*

Greece

Michael B Anthracopoulos, *Rion-Patras*
Savas Grigoriadis, *Thessaloniki*
Vasiliki-Maria Iliadou, *Thessaloniki*
Theofilos M Kolettis, *Ioannina*
Ariadne Malamitsi-Puchner, *Athens*
Dimitrios Papandreou, *Thessaloniki*
Kostas N Priftis, *Athens*
Ioannis Michael Vlastos, *Heraklion*

India

Amit Agrawal, *Ambala*
Sameer Bakhshi, *New Delhi*
Atmaram H Bandivdekar, *Mumbai*
Sandeep Bansal, *Chandigarh*
Sriparna Basu, *Varanasi*
Ashu Seith Bhalla, *New Delhi*
Sushil Kumar Kabra, *New Delhi*
Praveen Kumar, *New Delhi*
Kaushal Kishor Prasad, *Chandigarh*
Yogesh Kumar Sarin, *New Delhi*
Kushaljit Singh Sodhi, *Chandigarh*
Raveenthiran V Venkatachalam, *Tamilnadu*
B Viswanatha, *Bangalore*
Syed Ahmed Zaki, *Mumbai*

Iran

Mehdi Bakhshaee, *Mashhad*
Maria Cheraghi, *Ahvaz*
Mehran Karimi, *Shiraz*
Samileh Noorbakhsh, *Tehran*
Firoozeh Sajedi, *Tehran*

Israel

Shraga Aviner, *Ashkelon*
Aviva Fattal-Valevski, *Ramat Aviv*
Rafael Gorodischer, *Omer*
Gil Klinger, *Petah Tikva*
Asher Ornoy, *Jerusalem*
Giora Pillar, *Haifa*
Yehuda Shoenfeld, *Tel-Hashomer*

Italy

Roberto Antonucci, *Cagliari*
CarloV Bellieni, *Siena*
Silvana Cicala, *Naples*
Sandro Contini, *Parma*
Enrico Stefano Corazziari, *Rome*
Vincenzo Cuomo, *Rome*
Vassilios Fanos, *Cagliari*
Filippo Festini, *Florence*
Irene Figa-Talamanca, *Rome*
Dario Galante, *Foggia*
Fabio Grizzi, *Milan*
Alessandro Inserra, *Rome*
Achille Iolascon, *Naples*
Cantinotti Massimiliano, *Pietrsanta*
Ornella Milanesi, *Padova*
Giovanni Nigro, *L'Aquila*
Giuseppe Rizzo, *Rome*
Claudio Romano, *Messina*
Mario Santinami, *Milano*
Gianluca Terrin, *Rome*
Alberto Tommasini, *Trieste*
Giovanni Vento, *Rome*

Japan

Ryo Aeba, *Tokyo*
Kazunari Kaneko, *Osaka*
Hideaki Senzaki, *Saitama*
Kohichiro Tsuji, *Tokyo*
Toru Watanabe, *Niigata*
Takayuki Yamamoto, *Yokkaichi*

Mexico

Fernando Guerrero-Romero, *Durango*
Mara Medeiros, *Mexico*

Netherlands

Jacobus Burggraaf, *Leiden*
Paul Eduard Sijens, *Groningen*

New Zealand

Simon James Thornley, *Auckland*

Nigeria

Akeem Olawale Lasisi, *Ibadan*
Tinuade Adetutu Ogunlesi, *Sagamu*
Joseph Ubini Ese Onakewhor, *Benin*

Norway

Lars T Fadnes, *Bergen*

Pakistan

Niloufer Sultan Ali, *Karachi*
Shakila Zaman, *Lahore*

Poland

Piotr Czauderna, *Gdansk*
Joseph Prandota, *Wroclaw*

Portugal

Alexandre M Carmo, *Porto*

Russia

Perepelitsa S Alexandrovna, *Kaliningrad*
Vorsanova Svetlana, *Moscow*

Saudi Arabia

Naser Labib Rezk, *Riyadh*
Amna Rehana Siddiqui, *Riyadh*

Serbia

Bjelakovic Borisav Bojko, *Nis*
Mirela Erić, *Novi Sad*

Singapore

Quak Seng Hock, *Singapore*
Anselm CW Lee, *Singapore*
Alvin Soon Tiong Lim, *Singapore*

Slovenia

Rok Orel, *Ljubljana*

South Africa

David Kenneth Stones, *Free State*
Eric Oghenerioborue Udjo, *Pretoria*

South Korea

Byung-Ho Choe, *Daegu*
Dong-Hee Lee, *Seoul*

Spain

Pilar Codoñer-Franch, *Valencia*
Claudio Golffier, *Barcelona*
Pablo Menendez, *Andalucía*
Juan F Martínez-Lage Sánchez, *Murcia*
Juan Antonio Tovar, *Madrid*

Sweden

Moustapha Hassan, *Stockholm*
Maria Christina Jenmalm, *Linköping*
Sandra Kleinau, *Uppsala*
Birgitta Lindberg, *Luleå*

Switzerland

Ulf Kessler, *Bern*

Thailand

Surasak Sangkhathat, *Hat Yai*
Viroj Wiwanitkit, *Bangkok*

Tunisia

John C Anyanwu, *Tunis Belvedere*

Turkey

Sinem Akgül, *Ankara*
Ayse Tuba Altug, *Ankara*
Suna Asilsoy, *Seyhan-Adana*
Ozgu Aydogdu, *Izmir*
Kadir Babaoglu, *Kocaeli*
Aksoy Berna, *Kocaeli*
Murat Biteker, *Istanbul*
Merih Çetinkaya, *Istanbul*
Aynur Emine Cicekcibasi, *Konya*
Elvan Caglar Citak, *Mersin*
Cem Dane, *Istanbul*
Mintaze Kerem Günel, *Ankara*
Ahmet Güzel, *Samsun*
Salih Kavukcu, *Izmir*
Fethullah Kenar, *Denizli*
Selim Kurtoglu, *Kayseri*
Turker Ozyigit, *Istanbul*
Yalçın Tüzün, *Istanbul*

United Arab Emirates

Iradj Amirlak, *Al Ain*

United Kingdom

Keith Collard, *Plymouth*
ASahib El-Radhi, *London*
Edzard Ernst, *Exeter*
Mohammad K Hajihosseini, *Norwich*
Tain-Yen Hsia, *London*
Claudio Nicoletti, *Norwich*
Cordula Margaret Stover, *Leicester*
Alastair Gordon Sutcliffe, *London*
Adrian Graham Thomas, *Manchester*
Richard Trompeter, *London*
Petros V Vlastarakos, *Stevenage*

United States

Stephen C Aronoff, *Philadelphia*
Hossam M Ashour, *Detroit*
Paul Ashwood, *Sacramento*
David C Bellinger, *Boston*
Vineet Bhandari, *New Haven*
FR Breijo-Marquez, *Boston*
Itzhak Brook, *Washington*
Patrick D Brophy, *Iowa*
Lavjay Butani, *Sacramento*
Archana Chatterjee, *Omaha*
Lisa M Cleveland, *San Antonio*
Shri R Deshpande, *Atlanta*
Michael Morgan Dowling, *Dallas*
Abdulrahman M El-Sayed, *New York*
Donald N Forthal, *Irvine*
Gregory Kane Friedman, *Birmingham*
Kenneth William Gow, *Seattle*
Dorothy I Bulas, *Washington*
Christopher L Coe, *Madison*
Elias Jabbour, *Houston*
Michael Van Doren Johnston, *Baltimore*
Ram V Kalpatthi, *Gainesville*
Stephen S Kim, *Annandale*
Edward Yungjae Lee, *Annandale*
Jing Lin, *New York*
Jorge Lopez, *Gainesville*
Aurelia Meloni-Ehrig, *Gainesville*
Murielle Mimeault, *Omaha*
Natan Noviski, *Omaha*
Michael David Seckeler, *Charlottesville*
Chetan Chandulal Shah, *Little Rock*
Mohamed Tarek M Shata, *Cincinnati*
Tsz-Yin So, *Greensboro*
Dennis Charles Stevens, *Sioux Falls*
Ru-Jeng Teng, *Milwaukee*
Rajan Wadhawan, *St Petersburg*
Hongjun Wang, *St Charleston*
Marie Wang, *Menlo Park*
Richard Wang, *Atlanta*
Wladimir Wertelecki, *Annandale*
Shu Wu, *Miami*
Fadi Xu, *Albuquerque*

WJCP World Journal of Clinical Pediatrics

Contents

Quarterly Volume 4 Number 2 May 8, 2015

EDITORAL

13 Clinical asthma phenotyping: A trial for bridging gaps in asthma management
Zedan MM, Laimon WN, Osman AM, Zedan MM

MINIREVIEWS

19 Appendicitis in children less than five years old: A challenge for the general practitioner
Marzuillo P, Germani C, Krauss BS, Barbi E

25 Pyuria in patients with Kawasaki disease
Watanabe T

CASE REPORT

30 Endobronchial tumor in children: Unusual finding in recurrent pneumonia, report of three cases
Madafferi S, Catania VD, Accinni A, Boldrini R, Inserra A

World Journal of Clinical Pediatrics
Volume 4 Number 2 May 8, 2015

Contents

ABOUT COVER Editorial Board Member of *World Journal of Clinical Pediatrics*, Toru Watanabe, MD, PhD, Department of Pediatrics, Niigata city General Hospital, 463-7 Shumoku, Chuo-ku, Niigata 950-1197, Japan

AIM AND SCOPE *World Journal of Clinical Pediatrics* (*World J Clin Pediatr*, *WJCP*, online ISSN 2219-2808, DOI: 10.5409) is a peer-reviewed open access academic journal that aims to guide clinical practice and improve diagnostic and therapeutic skills of clinicians.

WJCP covers a variety of clinical medical topics, including fetal diseases, inborn, newborn diseases, infant diseases, genetic diseases, diagnostic imaging, endoscopy, and evidence-based medicine and epidemiology. Priority publication will be given to articles concerning diagnosis and treatment of pediatric diseases. The following aspects are covered: Clinical diagnosis, laboratory diagnosis, differential diagnosis, imaging tests, pathological diagnosis, molecular biological diagnosis, immunological diagnosis, genetic diagnosis, functional diagnostics, and physical diagnosis; and comprehensive therapy, drug therapy, surgical therapy, interventional treatment, minimally invasive therapy, and robot-assisted therapy.

We encourage authors to submit their manuscripts to *WJCP*. We will give priority to manuscripts that are supported by major national and international foundations and those that are of great clinical significance.

INDEXING/ABSTRACTING *World Journal of Clinical Pediatrics* is now indexed in PubMed Central, PubMed and Digital Object Identifier.

FLYLEAF **I-III** Editorial Board

EDITORS FOR THIS ISSUE

Responsible Assistant Editor: *Xiang Li*
Responsible Electronic Editor: *Huan-Liang Wu*
Proofing Editor-in-Chief: *Lian-Sheng Ma*
Responsible Science Editor: *Fang-Fang Ji*
Proofing Editorial Office Director: *Xiu-Xia Song*

NAME OF JOURNAL
World Journal of Clinical Pediatrics

ISSN
ISSN 2219-2808 (online)

LAUNCH DATE
June 8, 2012

FREQUENCY
Quarterly

EDITOR-IN-CHIEF
Eduardo H Garin, MD, Professor, Department of Pediatrics, University of Florida, 1600 SW Archer Road. HD214, Gainesville, FL 32610, United States

EDITORIAL OFFICE
Jin-Lei Wang, Director
Xiu-Xia Song, Vice Director
World Journal of Clinical Pediatrics
Room 903, Building D, Ocean International Center, No. 62 Dongsihuan Zhonglu, Chaoyang District, Beijing 100025, China
Telephone: +86-10-85381891
Fax: +86-10-85381893
E-mail: editorialoffice@wjgnet.com
Help Desk: http://www.wjgnet.com/esps/helpdesk.aspx
http://www.wjgnet.com

PUBLISHER
Baishideng Publishing Group Inc
8226 Regency Drive,
Pleasanton, CA 94588, USA
Telephone: +1-925-223-8242
Fax: +1-925-223-8243
E-mail: bpgoffice@wjgnet.com
Help Desk: http://www.wjgnet.com/esps/helpdesk.aspx
http://www.wjgnet.com

PUBLICATION DATE
May 8, 2015

COPYRIGHT
© 2015 Baishideng Publishing Group Inc. Articles published by this Open-Access journal are distributed under the terms of the Creative Commons Attribution Non-commercial License, which permits use, distribution, and reproduction in any medium, provided the original work is properly cited, the use is non commercial and is otherwise in compliance with the license.

SPECIAL STATEMENT
All articles published in journals owned by the Baishideng Publishing Group (BPG) represent the views and opinions of their authors, and not the views, opinions or policies of the BPG, except where otherwise explicitly indicated.

INSTRUCTIONS TO AUTHORS
Full instructions are available online at http://www.wjgnet.com/2219-2808/g_info_20100722180909.htm.

ONLINE SUBMISSION
http://www.wjgnet.com/esps/

World Journal of Clinical Pediatrics

Submit a Manuscript: http://www.wjgnet.com/esps/
Help Desk: http://www.wjgnet.com/esps/helpdesk.aspx
DOI: 10.5409/wjcp.v4.i2.13

World J Clin Pediatr 2015 May 8; 4(2): 13-18
ISSN 2219-2808 (online)
© 2015 Baishideng Publishing Group Inc. All rights reserved.

EDITORIAL

Clinical asthma phenotyping: A trial for bridging gaps in asthma management

Magdy Mohamed Zedan, Wafaa Nabil Laimon, Amal Mohamed Osman, Mohamed Magdy Zedan

Magdy Mohamed Zedan, Wafaa Nabil Laimon, Amal Mohamed Osman, Mohamed Magdy Zedan, Department of Asthma, Allergy and Immunology, Mansoura Faculty of Medicine, Mansoura University, Mansoura 35516, Egypt
Author contributions: Zedan MM designed the research; Zedan MM and Laimon NW performed the research; Zedan MM, Laimon NW, Osman MA and Zedan MM wrote the paper.
Conflict-of-interest: None.
Open-Access: This article is an open-access article which was selected by an in-house editor and fully peer-reviewed by external reviewers. It is distributed in accordance with the Creative Commons Attribution Non Commercial (CC BY-NC 4.0) license, which permits others to distribute, remix, adapt, build upon this work non-commercially, and license their derivative works on different terms, provided the original work is properly cited and the use is non-commercial. See: http://creativecommons.org/licenses/by-nc/4.0/
Correspondence to: Magdy Mohamed Zedan, MD, Department of Asthma, Allergy and Immunology, Mansoura Faculty of Medicine, Mansoura University, Mansoura 35516, Egypt. magdyzedan@mans.edu.eg
Telephone: +20-50-2242526
Fax: +20-50-2234092
Received: January 28, 2015
Peer-review started: January 29, 2015
First decision: March 6, 2015
Revised: March 19, 2015
Accepted: April 16, 2015
Article in press: April 20, 2015
Published online: May 8, 2015

Abstract

Asthma is a common disease affecting millions of people worldwide and exerting an enormous strain on health resources in many countries. Evidence is increasing that asthma is unlikely to be a single disease but rather a series of complex, overlapping individual diseases or phenotypes, each defined by its unique interaction between genetic and environmental factors. Asthma phenotypes were initially focused on combinations of clinical characteristics, but they are now evolving to link pathophysiological mechanism to subtypes of asthma. Better characterization of those phenotypes is expected to be most useful for allocating asthma therapies. This article reviews different published researches in terms of unbiased approaches to phenotype asthma and emphasizes how the phenotyping exercise is an important step towards proper asthma treatment. It is structured into three sections; the heterogeneity of asthma, the impact of asthma heterogeneity on asthma management and different trials for phenotyping asthma.

Key words: Asthma phenotypes; Asthma heterogenity; Endotypes; Asthma subtypes; Asthma syndrome

© The Author(s) 2015. Published by Baishideng Publishing Group Inc. All rights reserved.

Core tip: Although asthma diagnosis is based mainly on clinical basis using history taking and physical examination, treatment options are not tailored according to the clinical phenotype. We still do not have a way to work up a given patient with asthma and to easily delineate the specific pathobiology that leads to her or his airway dysfunction. We can recognize the clinical syndromes, but we cannot spell out the steps that lead from genetic or biochemical defects to disease presentation. Thus we are left with a paradox in the study of asthma; we have effective treatments that are not biologically informative, and we have informative treatments that are less effective.

Zedan MM, Laimon WN, Osman AM, Zedan MM. Clinical asthma phenotyping: A trial for bridging gaps in asthma management. *World J Clin Pediatr* 2015; 4(2): 13-18 Available from: URL: http://www.wjgnet.com/2219-2808/full/v4/i2/13.htm
DOI: http://dx.doi.org/10.5409/wjcp.v4.i2.13

INTRODUCTION

Asthma is a chronic inflammatory airway disease characterized by episodic reversible airway obstruction that variably presents with cough, wheezing, shortness of breath, or chest tightness[1,2].

Asthma affects nearly 300 million people worldwide. Moreover, western countries have shown rising prevalence over the past three decades[2]. The prevalence of bronchial asthma in the Nile Delta region of Egypt was found to be 7.7%[3].

Asthma is a heterogeneous and genetically determined disease with different presentation, disease progression, and response to therapy. However, despite this recognition, the treatment approaches for asthma have been uniformly applied irrespective of its "subtype"[4]. Guidelines advocate a universal stepwise approach in which medications are initially prescribed based on patient age and asthma severity, and then the number, frequency, and dose of medications are titrated upward when asthma control is inadequate.

The fact that there are some asthmatic patients with variable presentations who do not respond to commonly used medications and classified as severe asthma[5,6], has driven the urgent need to phenotype the disease using unbiased approaches, and depending mainly on essential clinical and physiologic features for better treatment approaches.

Different researches have tried to shape asthma phenotypes through their clinical, physiologic and cellular parameters. A phenotype was defined as "observable characteristics" of subtypes of asthma ranging from clinical presentation, triggering factors to therapeutic responses. While, the fact of asthma pathogenesis is far beyond that as these different asthma phenotypes are based on different underlying biologic processes in each patient[7].

For better understanding of this heterogeneity and the complexity of clinical and research results, the term "endotype" was evolved reflecting a specific pathogenic mechanism. Endotype was defined according to molecular pathogenesis or therapeutic responses. Thus, accurate identification of those asthma endotypes could help in tailoring of asthma therapy[2].

ASTHMA AS A HETEROGENEOUS DISEASE

Heterogeneity of asthma reflects different clinical presentations with different responses to asthma medicines. This makes a challenge for the appropriate choice of asthma treatment. Thus, a better understanding of this heterogeneity could be of great help. Asthma heterogeneity could be explained at four levels: clinical, biological, therapeutic and molecular levels (Table 1).

Clinical level

Different studies suggest phenotypic classification of asthma depending on clinical basis. These phenotypes include allergic and non allergic asthma. Other phenotypes defined by clinical or physiological categories (*i.e.,* severity, age at onset, and chronic airway obstruction), by asthma triggers (*i.e.,* viral, exercise, occupational allergens, or irritants), or their course (*i.e.,* early transient/persistent/late onset wheeze) have also been proposed[8]. Other asthma phenotypes include cough variant asthma and obese asthma phenotype. Cough variant asthma was recognized as an asthma phenotype that solely presents with coughing[9]. This asthma phenotype was defined by the presence of atopic features, milder eosinophilic airway inflammation and airway remodeling[10].

Obese asthma phenotype is assumed to be non T helper type 2 (Th2) mediated in which low fractional exhaled nitric oxide, eosinophils and IgE levels were observed[11,12]. Preliminary studies have suggested that in late onset obese asthma, there is increased asymmetric dimethylarginine which inhibits inducible nitric oxide synthetase leading to superoxide generation increasing the oxidative stress in such patients[13].

Biological level

The heterogeneity of asthma as an inflammatory disorder is well established. Simpson *et al*[14] have detected specific inflammatory endotypes in sputum samples consistent with cytokine profiles in asthmatic patients forming different endotypes that ranged from: eosinophilic, neutrophilic, mixed, and paucigranuloctic subtypes[15]. Severe asthma was found to be a different disease entity dating since birth with a specific underlying biology[16,17]. Thus, it should be viewed like this rather than the end result of airway remodeling. Recently, Zedan *et al*[18] correlated clinical asthma phenotypes with the underlying cytokine and genetic pattern. Serum cytokines levels were found to be a reflection of cytokine gene polymorphisms *via* affecting the transcriptional regulation. The clinical asthma phenotypes showed statistically significant differences in cytokine profile and genotyping distribution of IL4RA-175V and IL4C-590T. Further a different genotyping was noticed when dealing with asthma as a group and after its clinical phenotyping.

Therapeutic level

In spite of asthma heterogeneity, the prescribed medications for asthma management are similar involving B2 agonists, leukotriene receptors antagonists and inhaled corticosteroids. These asthma medicines were found to control the symptoms in the majority of patients and failed in others. Several researches tried to explain this variable response to asthma therapy in different patients.

The polymorphism of β2 receptors could adversely affect the response to regular short-acting drugs[19]. On the other aspect, 15% of asthmatics show a reasonable response to leukotriene modifiers. However, polymorphism in 5 lipoxygenase (ALOX) and the

Table 1 Examples of proposed clinical phenotypes

	Clinical level	Clinical characteristics	Biological level	Molecular level	Therapeutic level
Xie *et al*[2]	Exercise induced asthma	Mild asthma and reactive bronchospasm in response to sustained exercise	Mast-cell activation; Th2 cytokines; cysteinyl leukotrienes		Responsive to cysteinyl leukotriene modifiers, beta agonists and antibody to IL-9
	Obesity asthma phenotype	Adult onset Mostly females Severe symptoms	Lack of Th2 biomarkers; oxidative stress ADMA		Responsive to weight loss, antioxidants and possibly to hormonal therapy
	Early-onset Allergic asthma	> 3 episodes per year Mild, moderate, or severe Family history of asthma	Specific IgE; Th2 cytokines; thick SBM	17q12; Th2-related genes	Corticosteroid-responsive; Th2-targeted
	Late-onset Eosinophic asthma	Adult onset Often severe Sinus disease	Increased both peripheral eosinophils and IL-5		Responsive to antibody to IL-5 and cysteinyl leukotriene modifiers; corticosteroid-refractory
Zedan *et al*[8]	Shortness of breath phenotype	> 10 yr No sex predominance Longer disease duration Negative family history of asthma	Increased total serum IgE	Higher prevalence of TT genotype of SNP IL-4C 590T (Zedan *et al*[18])	Responsive to fluticasone alone
	Cough phenotype	< 10 yr Female predominance Shorter disease duration Positive family history of asthma	Increased both peripheral eosinophis and sECP		Responsive to montelukast alone
	Wheezy phenotype		Increase in peripheral eosinophilis and sECP		Responsive to both fluticasone and montelukast

ADMA: Asymmetric dimethyl arginine; SBM: Subepithelial basement membrane; SNP: Single nucleotide polymorphism; sECP: Serum eosinophilic cationic protein; IL: Interleukin; Th2: T helper type 2.

receptor (CYSLTR2) were found to affect the drug response[20,21].

Further, differences in corticosteroid responsiveness may be caused by complex genetic variations as more than 100 genes were found to be involved in allergic asthma, but these genetics variations are influenced by environmental exposures. Moreover, in many cases, it has been difficult to establish clear linkage because of disease heterogeneity and poorly stratified populations[22].

By stratifying patients according to phenotype, future studies may be better able to identify the genes or other biomarkers associated with various aspects of asthma. Currently, the use of specific biomarkers to diagnose and monitor asthma is in its infancy but is being evaluated in clinical trials[23].

Molecular level

Despite the importance of Th2 cytokines in atopic asthma, recent data in both adults and children has challenged the concept of a Th1/Th2 imbalance and has showed an evidence of Th1 profile.

Th2 imprint was present in only 50% of the mild asthmatics and those patients were characterized by lung eosinophils, mast cells, higher IgE levels, hyperreactive airway, higher tissue expression of Th2 cytokines and thicker subepithelial basement membrane[24,25]. In addition, they showed a good response to inhaled corticosteroids in contrast to those without the type-2 cytokine profile.

IMPACT OF ASTHMA HETEROGENEITY ON ASTHMA MANAGEMENT

Asthma therapy can markedly improve quality of life, morbidity, and mortality of asthma patients and decrease health care costs if applied to the right patient at the right time[26]. The choice of controller medications should be based on clinical efficacy, patient phenotype, previous responses to treatment, patient's compliance, side effects, and drug safety[27].

Although asthma diagnosis is based mainly on clinical basis using history taking and physical examination[28], treatment options are not tailored according to the clinical phenotype. We still do not have a way to work up a given patient with asthma and to easily delineate the specific pathobiology that leads to her or his airway dysfunction. We can recognize the clinical syndromes, but we cannot spell out the steps that lead from genetic or biochemical defects to disease presentation. Thus we are challenged by a paradox in the management of asthma; we have effective treatments that are not biologically informative, and we have informative treatments that are less effective[29].

Recently, the new emerging cytokine based therapies flare the importance of asthma phenotyping. Effective application of these new therapies to certain patients depends on the development of biomarkers of

molecular heterogeneity in asthma[30].

DIFFERENT TRIALS FOR ASTHMA PHENOTYPING

A phenotype is defined as the "observable properties of an organism that are produced by the interactions of the genotype and the environment"[31]. Multiple approaches have been proposed for asthma phenotyping, none has been widely agreed upon. Many of those approaches have been biased; depends mainly on clinical characteristics without obvious inflammatory biomarkers. Also, the selection of a single dominant characteristic to categorize a given patient is mostly inaccurate as it ignores the overlap between groups[32]. These include categorization of patients based upon atopic state, symptomatic trigger, disease severity, and pattern of airflow obstruction. In addition, pathological classifications, despite being important for clarifying disease pathogenesis, they are extremely invasive clinically.

Several studies have approached asthma phenotyping in a less biased and more statistically based manner[31] as a result of lacking of specific biomarkers for each asthma phenotype. Three large clinically oriented analyses performed in Europe[33,34] and the United States[35,36] developed clusters based upon age of onset of asthma, gender, allergic features, asthma symptoms, and lung function as well as other factors that varied between the three studies. The resulting phenotypes include early-onset mild allergic asthma, later-onset asthma associated with obesity, and severe non-atopic asthma with frequent exacerbations.

Four clusters were identified based upon asthma duration, the number of asthma controller medications, baseline Forced Expiratory Volume in 1 s, skin test, and total serum IgE. All of them were strongly associated with histories of atopic dermatitis and atopy, although the degree of atopy as measured by number of positive allergy skin tests and total serum IgE did differ significantly between groups[34]. However, these studies lacked the accurate pathological and immunological definition of asthma phenotypes[31].

Asthma has a strong genetic component[37]. Most of genetic association studies have dealed with asthma as a one disease[38] and only few studies[39] delineated specific asthma phenotypes. Asthma subtypes cannot be termed phenotypes without linking the observable characteristics to the genetic signature of the patients[40]. Woodruff *et al*[41] began to identify molecular phenotypes of asthma. They analyzed airway epithelial brushings and they identified "TH2 high" and "TH2 low" individuals.

Zedan *et al*[27] proposed three clinical asthma phenotypes based on symptomatology after validation of these symptoms[42,43]. The study tried to characterize three clinical phenotypes [shortness of breath (SOB), cough, and wheeze] by specific inflammatory biomarkers and their response to asthma medications. They found that children who had SOB had older age, and longer disease duration, higher levels of total serum IgE, and responded to fluticasone alone. While cough group was found to have younger age, shorter disease duration, higher levels of eosinophilic% and serum Eosinophilic Cationic Protein, and responded to montelukast alone. Moreover, wheezy group showed mixed pattern and responded to both medications[27].

Two single nucleotide polymorphisms (SNPs) in IL-4 and IL4RA were studied in Egyptian asthmatics with different clinical phenotypes[18]. They found that asthma as a group had AG heterozygosity genotype, whereas cough with SOB group showed AA and GG homozygosity genotype. In addition, cough group and SOB group revealed significant increase in serum levels of IL-17 among patients with CC homozygote variant of IL-4C 590T compared to patients with CT heterozygote variant. In turn, phenotyping based on symptomatology makes a sense in endotyping of asthma, which may have a reflection on heterogeneity in response to asthma medications[18].

The previously mentioned clinical asthma phenotypes were found to express a significant value in detection of specific cytokine and genotype profiles for asthma; hence this may help in prediction and diagnosis of clinical asthma phenotypes which might have a potential value in tailoring asthma therapies.

The concept of personalized medicine, however, gained most traction from the application of genetics to patients with disease. Polymorphisms in genes (both single nucleotide polymorphisms, SNPs, and other more substantive coding variations) are associated with therapeutic responses to short-acting beta2 agonists, leukotriene inhibitors, corticosteroids, and several others; other polymorphisms confer risk of developing diseases: asthma, atopy, bronchial hyperresponsiveness, *etc*[44].

CONCLUSION

Asthma is a complex disease with evidenced heterogeneity at different levels. Despite this heterogeneous nature, the same treatment approaches are still applied for different patients with variable responses. Phenotyping/endotyping dilemma is the only roadmap to bridge the gap between this variable disease and the single approach of management. A key obstacle in this field is a lack of "gold standard" phenotypes with underlying identifiable biomarkers, genetic, or molecular profiles. A novel conceptual framework to link the clinical signature of every patient to her/his inflammatory phenotype is very essential to meet the challenges of tailoring the right medications for to the right patient at the right time.

REFERENCES

1 **Zedan M**, Settin A, Farag MK, El-Bayoumi M, El Regal ME, El

Baz R, Osman E. Gene polymorphisms of tumor necrosis factor alpha-308 and interleukin-10-1082 among asthmatic Egyptian children. *Allergy Asthma Proc* 2008; **29**: 268-273 [PMID: 18534084 DOI: 10.2500/aap.2008.29.3123]

2 **Xie M**, Wenzel SE. A global perspective in asthma: from phenotype to endotype. *Chin Med J* (Engl) 2013; **126**: 166-174 [PMID: 23286496]

3 **Zedan M**, Settin A, Farag M, Ezz-Elregal M, Osman E. Prevalence of Bronchial asthma among Egyptian school children. *Egypt J Bronchol* 2009; **3**: 124-130

4 **Anderson GP**. Endotyping asthma: new insights into key pathogenic mechanisms in a complex, heterogeneous disease. *Lancet* 2008; **372**: 1107-1119 [PMID: 18805339 DOI: 10.1016/S0140-6736(08)61452-X]

5 **Chung KF**, Godard P, Adelroth E, Ayres J, Barnes N, Barnes P, Bel E, Burney P, Chanez P, Connett G, Corrigan C, de Blic J, Fabbri L, Holgate ST, Ind P, Joos G, Kerstjens H, Leuenberger P, Lofdahl CG, McKenzie S, Magnussen H, Postma D, Saetta M, Salmeron S, Sterk P. Difficult/therapy-resistant asthma: the need for an integrated approach to define clinical phenotypes, evaluate risk factors, understand pathophysiology and find novel therapies. ERS Task Force on Difficult/Therapy-Resistant Asthma. European Respiratory Society. *Eur Respir J* 1999; **13**: 1198-1208 [PMID: 10414427]

6 Proceedings of the ATS workshop on refractory asthma: current understanding, recommendations, and unanswered questions. American Thoracic Society. *Am J Respir Crit Care Med* 2000; **162**: 2341-2351 [PMID: 11112161]

7 **Wenzel SE**. Asthma: defining of the persistent adult phenotypes. *Lancet* 2006; **368**: 804-813 [PMID: 16935691]

8 **Zedan M**, Attia G, Zedan MM, Osman A, Abo-Elkheir N, Maysara N, Barakat T, Gamil N. Clinical asthma phenotypes and therapeutic responses. *ISRN Pediatr* 2013; **2013**: 824781 [PMID: 23606983 DOI: 10.1155/2013/824781]

9 **Niimi A**. Cough, asthma, and cysteinyl-leukotrienes. *Pulm Pharmacol Ther* 2013; **26**: 514-519 [PMID: 23774534 DOI: 10.1016/j.pupt.2013.06.003]

10 **Ioan I**, Poussel M, Coutier L, Plevkova J, Poliacek I, Bolser DC, Davenport PW, Derelle J, Hanacek J, Tatar M, Marchal F, Schweitzer C, Fontana G, Varechova S. What is chronic cough in children? *Front Physiol* 2014; **5**: 322 [PMID: 25221517 DOI: 10.3389/fphys.2014.00322]

11 **Amelink M**, de Nijs SB, de Groot JC, van Tilburg PM, van Spiegel PI, Krouwels FH, Lutter R, Zwinderman AH, Weersink EJ, ten Brinke A, Sterk PJ, Bel EH. Three phenotypes of adult-onset asthma. *Allergy* 2013; **68**: 674-680 [PMID: 23590217 DOI: 10.1111/all.12136]

12 **Holguin F**, Bleecker ER, Busse WW, Calhoun WJ, Castro M, Erzurum SC, Fitzpatrick AM, Gaston B, Israel E, Jarjour NN, Moore WC, Peters SP, Yonas M, Teague WG, Wenzel SE. Obesity and asthma: an association modified by age of asthma onset. *J Allergy Clin Immunol* 2011; **127**: 1486-93.e2 [PMID: 21624618 DOI: 10.1016/j.jaci.2011.03.036]

13 **Holguin F**, Comhair SA, Hazen SL, Powers RW, Khatri SS, Bleecker ER, Busse WW, Calhoun WJ, Castro M, Fitzpatrick AM, Gaston B, Israel E, Jarjour NN, Moore WC, Peters SP, Teague WG, Chung KF, Erzurum SC, Wenzel SE. An association between L-arginine/asymmetric dimethyl arginine balance, obesity, and the age of asthma onset phenotype. *Am J Respir Crit Care Med* 2013; **187**: 153-159 [PMID: 23204252 DOI: 10.1164/rccm.201207-1270OC]

14 **Simpson JL**, Scott R, Boyle MJ, Gibson PG. Inflammatory subtypes in asthma: assessment and identification using induced sputum. *Respirology* 2006; **11**: 54-61 [PMID: 16423202 DOI: 10.1111/j.1440-1843.2006.00784.x]

15 **Brasier AR**, Victor S, Boetticher G, Ju H, Lee C, Bleecker ER, Castro M, Busse WW, Calhoun WJ. Molecular phenotyping of severe asthma using pattern recognition of bronchoalveolar lavage-derived cytokines. *J Allergy Clin Immunol* 2008; **121**: 30-37.e6 [PMID: 18206505 DOI: 10.1016/j.jaci.2007.10.015]

16 **Chanez P**, Wenzel SE, Anderson GP, Anto JM, Bel EH, Boulet LP, Brightling CE, Busse WW, Castro M, Dahlen B, Dahlen SE, Fabbri LM, Holgate ST, Humbert M, Gaga M, Joos GF, Levy B, Rabe KF, Sterk PJ, Wilson SJ, Vachier I. Severe asthma in adults: what are the important questions? *J Allergy Clin Immunol* 2007; **119**: 1337-1348 [PMID: 17416409 DOI: 10.1016/j.jaci.2006.11.702]

17 **Phelan PD**, Robertson CF, Olinsky A. The Melbourne Asthma Study: 1964-1999. *J Allergy Clin Immunol* 2002; **109**: 189-194 [PMID: 11842286]

18 **Zedan M**, Bakr A, Shouman B, Zaghloul H, Al-Haggar M, Zedan M, Osman A. Single Nucleotide Polymorphism of IL4C-590T and IL4RA 175V and Immunological Parameters in Egyptian Asthmatics with Different Clinical Phenotypes. *J Allergy Ther* 2014; **5**: 1-7

19 **Hawkins GA**, Weiss ST, Bleecker ER. Clinical consequences of ADRbeta2 polymorphisms. *Pharmacogenomics* 2008; **9**: 349-358 [PMID: 18303970 DOI: 10.2217/14622416.9.3.349]

20 **Klotsman M**, York TP, Pillai SG, Vargas-Irwin C, Sharma SS, van den Oord EJ, Anderson WH. Pharmacogenetics of the 5-lipoxygenase biosynthetic pathway and variable clinical response to montelukast. *Pharmacogenet Genomics* 2007; **17**: 189-196 [PMID: 17460547 DOI: 10.1097/FPC.0b013e3280120043]

21 **Pillai SG**, Cousens DJ, Barnes AA, Buckley PT, Chiano MN, Hosking LK, Cameron LA, Fling ME, Foley JJ, Green A, Sarau HM, Schmidt DB, Sprankle CS, Blumenthal MN, Vestbo J, Kennedy-Wilson K, Wixted WE, Wagner MJ, Anderson WH, Ignar DM. A coding polymorphism in the CYSLT2 receptor with reduced affinity to LTD4 is associated with asthma. *Pharmacogenetics* 2004; **14**: 627-633 [PMID: 15475736 DOI: 10.1097/00008571-200409000-00007]

22 **Szefler SJ**, Martin RJ, King TS, Boushey HA, Cherniack RM, Chinchilli VM, Craig TJ, Dolovich M, Drazen JM, Fagan JK, Fahy JV, Fish JE, Ford JG, Israel E, Kiley J, Kraft M, Lazarus SC, Lemanske RF, Mauger E, Peters SP, Sorkness CA. Significant variability in response to inhaled corticosteroids for persistent asthma. *J Allergy Clin Immunol* 2002; **109**: 410-418 [PMID: 11897984 DOI: 10.1067/mai.2002.122635]

23 **National Asthma Education and Prevention Program.** Expert Panel Report 3 (EPR-3): Guidelines for the Diagnosis and Management of Asthma-Summary Report 2007. *J Allergy Clin Immunol* 2007; **120**: S94-S138 [PMID: 17983880 DOI: 10.1016/j.jaci.2007.09.029]

24 **Dougherty RH**, Sidhu SS, Raman K, Solon M, Solberg OD, Caughey GH, Woodruff PG, Fahy JV. Accumulation of intraepithelial mast cells with a unique protease phenotype in T(H)2-high asthma. *J Allergy Clin Immunol* 2010; **125**: 1046-1053.e8 [PMID: 20451039 DOI: 10.1016/j.jaci.2010.03.003]

25 **Woodruff PG**, Modrek B, Choy DF, Jia G, Abbas AR, Ellwanger A, Koth LL, Arron JR, Fahy JV. T-helper type 2-driven inflammation defines major subphenotypes of asthma. *Am J Respir Crit Care Med* 2009; **180**: 388-395 [PMID: 19483109 DOI: 10.1164/rccm.200903-0392OC]

26 **Weiss ST**. New approaches to personalized medicine for asthma: where are we? *J Allergy Clin Immunol* 2012; **129**: 327-334 [PMID: 22284929 DOI: 10.1016/j.jaci.2011.12.971.Review]

27 **Zedan M**, Gamil N, El-Chennawi F, Maysara N, Hafeez HA, Nasef N, Fouda A. Evaluation of Different Asthma Phenotype Responses to Montelukast Versus Fluticasone Treatment. *Pediatric Asthma, Allergy & Immunology* 2009; **22**: 63-68 [DOI: 10.1089/pai.2008.0517]

28 **Global Initiative for Asthma**. Global strategy for asthma management and prevention [Accessed May 5 2012]. Available from: URL: http://www.ginasthma.org/

29 **Drazen JM**. Asthma: the paradox of heterogeneity. *J Allergy Clin Immunol* 2012; **129**: 1200-1201 [PMID: 22541360 DOI: 10.1016/j.jaci.2012.03.026]

30 **Bhakta NR**, Woodruff PG. Human asthma phenotypes: from the clinic, to cytokines, and back again. *Immunol Rev* 2011; **242**: 220-232 [PMID: 21682748]

31 **Wenzel SE**. Asthma phenotypes: the evolution from clinical to molecular approaches. *Nat Med* 2012; **18**: 716-725 [PMID: 22561835 DOI: 10.1038/nm.2678]

32 **Corren J**, Lemanske RF, Hanania NA, Korenblat PE, Parsey MV, Arron JR, Harris JM, Scheerens H, Wu LC, Su Z, Mosesova S, Eisner MD, Bohen SP, Matthews JG. Lebrikizumab treatment in adults with asthma. *N Engl J Med* 2011; **365**: 1088-1098 [PMID: 21812663 DOI: 10.1056/NEJMoa1106469]

33 **Haldar P**, Pavord ID, Shaw DE, Berry MA, Thomas M, Brightling CE, Wardlaw AJ, Green RH. Cluster analysis and clinical asthma phenotypes. *Am J Respir Crit Care Med* 2008; **178**: 218-224 [PMID: 18480428 DOI: 10.1164/rccm.200711-1754OC]

34 **Siroux V**, Basagaña X, Boudier A, Pin I, Garcia-Aymerich J, Vesin A, Slama R, Jarvis D, Anto JM, Kauffmann F, Sunyer J. Identifying adult asthma phenotypes using a clustering approach. *Eur Respir J* 2011; **38**: 310-317 [PMID: 21233270 DOI: 10.1183/09031936.00120810]

35 **Moore WC**, Meyers DA, Wenzel SE, Teague WG, Li H, Li X, D' Agostino R, Castro M, Curran-Everett D, Fitzpatrick AM, Gaston B, Jarjour NN, Sorkness R, Calhoun WJ, Chung KF, Comhair SA, Dweik RA, Israel E, Peters SP, Busse WW, Erzurum SC, Bleecker ER. Identification of asthma phenotypes using cluster analysis in the Severe Asthma Research Program. *Am J Respir Crit Care Med* 2010; **181**: 315-323 [PMID: 19892860 DOI: 10.1164/rccm.200906-0896OC]

36 **Fitzpatrick AM**, Teague WG, Meyers DA, Peters SP, Li X, Li H, Wenzel SE, Aujla S, Castro M, Bacharier LB, Gaston BM, Bleecker ER, Moore WC. Heterogeneity of severe asthma in childhood: confirmation by cluster analysis of children in the National Institutes of Health/National Heart, Lung, and Blood Institute Severe Asthma Research Program. *J Allergy Clin Immunol* 2011; **127**: 382-389. e1-13 [PMID: 21195471 DOI: 10.1016/j.jaci.2010.11.015]

37 **Martinez FD**, Vercelli D. Asthma. *Lancet* 2013; **382**: 1360-1372 [PMID: 24041942]

38 **Ober C**, Hoffjan S. Asthma genetics 2006: the long and winding road to gene discovery. *Genes Immun* 2006; **7**: 95-100 [PMID: 16395390]

39 **Bel EH**. Clinical phenotypes of asthma. *Curr Opin Pulm Med* 2004; **10**: 44-50 [PMID: 14749605]

40 **Wenzel SE**. Phenotypes in asthma: useful guides for therapy, distinct biological processes, or both? *Am J Respir Crit Care Med* 2004; **170**: 579-580 [PMID: 15355868 DOI: 10.1164/rccm.2407005]

41 **Woodruff PG**, Khashayar R, Lazarus SC, Janson S, Avila P, Boushey HA, Segal M, Fahy JV. Relationship between airway inflammation, hyperresponsiveness, and obstruction in asthma. *J Allergy Clin Immunol* 2001; **108**: 753-758 [PMID: 11692100 DOI: 10.1067/mai.2001.119411]

42 **ISAAC Coordinating Committee.** Manual for the International Study of Asthma and Allergies in Childhood (ISAAC) Bochum and Auckland: ISAAC Coordinating Committee, 1992

43 **Zedan M**, Settin A, Farag M, EL-Bayoumi M, Ezz-Elregal M, Abd-Elkader A, Osman E, Fouda A. How do Egyptian children describe asthma symptoms? *Egyptian J of Bronchology* 2009; **3**: 74-80

44 **Calhoun WJ**, Brassier AR. Conclusions and Future Directions. In: Brasier AR, editor. Heterogeneity in Asthma. Heidelberg, Dordrecht London: Springer New York, 2014: 340-342

P- Reviewer: Al-Biltagi M, Classen CF **S- Editor**: Tian YL
L- Editor: A **E- Editor**: Wu HL

World Journal of Clinical Pediatrics

Submit a Manuscript: http://www.wjgnet.com/esps/
Help Desk: http://www.wjgnet.com/esps/helpdesk.aspx
DOI: 10.5409/wjcp.v4.i2.19

World J Clin Pediatr 2015 May 8; 4(2): 19-24
ISSN 2219-2808 (online)
© 2015 Baishideng Publishing Group Inc. All rights reserved.

MINIREVIEWS

Appendicitis in children less than five years old: A challenge for the general practitioner

Pierluigi Marzuillo, Claudio Germani, Baruch S Krauss, Egidio Barbi

Pierluigi Marzuillo, Department of Women and Children and General and Specialized Surgery, Seconda Università degli Studi di Napoli, 80138 Naples, Italy
Claudio Germani, Egidio Barbi, Institute for Maternal and Child Health IRCCS Burlo Garofolo, 34137 Trieste, Italy
Baruch S Krauss, Boston Childrens Hospital, Boston, MA 02130, United States
Author contributions: Marzuillo P wrote the manuscript; Germani C supervised the manuscript drafting; Krauss BS critically revised and contributed to conceptually improve the manuscript; Barbi E conceived the manuscript.
Conflict-of-interest: Nothing to declare.
Open-Access: This article is an open-access article which was selected by an in-house editor and fully peer-reviewed by external reviewers. It is distributed in accordance with the Creative Commons Attribution Non Commercial (CC BY-NC 4.0) license, which permits others to distribute, remix, adapt, build upon this work non-commercially, and license their derivative works on different terms, provided the original work is properly cited and the use is non-commercial. See: http://creativecommons.org/licenses/by-nc/4.0/
Correspondence to: Pierluigi Marzuillo, MD, Department of Women and Children and General and Specialized Surgery, Seconda Università degli Studi di Napoli, Via L. De Crecchio 2, 80138 Naples, Italy. pierluigi.marzuillo@gmail.com
Telephone: +39-389-4873353
Fax: +39-040-3785727
Received: November 2, 2014
Peer-review started: November 4, 2014
First decision: November 27, 2014
Revised: February 12, 2015
Accepted: March 5, 2015
Article in press: March 9, 2015
Published online: May 8, 2015

Abstract

Acute appendicitis is one of the most common indications for abdominal surgery in pediatrics with peak incidence in the second decade of life. Acute appendicitis in the first years of life is an uncommon event. The clinical presentation is often varied and the diagnosis may be overshadowed by other medical conditions. Gastroenteritis is the most common misdiagnosis, with a history of diarrhea present in 33% to 41% of patients. Pain is the most common presenting symptom in children less than 5 years old, followed by vomiting, fever, anorexia and diarrhea. The most common physical sign is focal tenderness (61% of the patients) followed by guarding (55%), diffuse tenderness (39%), rebound (32%), and mass (6%). Neonatal appendicitis is a very rare disease with high mortality; presenting symptoms are nonspecific with abdominal distension representing the main clinical presentation. The younger the patient, the earlier perforation occurs: 70% of patients less than 3 years develop a perforation within 48 h of onset of symptoms. A timely diagnosis reduces the risk of complications. We highlight the epidemiology, pathophysiology, clinical signs and laboratory clues of appendicitis in young children and suggest an algorithm for early diagnosis.

Key words: Appendicitis; Children; Early diagnosis; Newborn; Appendicitis complications

© The Author(s) 2015. Published by Baishideng Publishing Group Inc. All rights reserved.

Core tip: Acute appendicitis in the first years of life is an uncommon event but with a high incidence of early perforation the younger the patient. We highlight the epidemiology, pathophysiology, clinical signs, and laboratory clues of appendicitis in young children. The challenge for the practitioner is to perform a timely diagnosis of acute appendicitis in first years of life before complications occur.

Marzuillo P, Germani C, Krauss BS, Barbi E. Appendicitis in children less than five years old: A challenge for the general practitioner. *World J Clin Pediatr* 2015; 4(2): 19-24 Available from: URL: http://www.wjgnet.com/2219-2808/full/v4/i2/19.htm
DOI: http://dx.doi.org/10.5409/wjcp.v4.i2.19

INTRODUCTION

Acute appendicitis has the highest incidence during the second decade of life[1], and represents a frequent indication for abdominal surgery in pediatrics[2]. It is more common in males than in females (ratio 1.4:1)[2]. While up to 33% of affected children may present not distinct abdominal pain with consecutive pain localization in the right lower quadrant, nausea and vomiting, young children could show atypical or delayed symptoms presentation[3-5]. When the diagnosis is performed, perforation could be already present in 30%-75% of children, with young children being at higher risk[6]. Perforated appendicitis increases the morbidity with intra-abdominal abscess being an important complication[7]. In young children, appendicitis is an uncommon event with a varied presentation and complications that can develop rapidly[8,9]. A timely diagnosis although necessary can be difficult, representing a challenge for the physician.

EPIDEMIOLOGY

In a study over a 12-year period, 1836 pediatric appendectomies were reviewed. Three hundred and twenty (17%) patients were under 5 years of age, 103 (5%) were less than 3 years, with only 7 patients (0.38%) younger than 1 year[7]. Perforation was more frequent in young children (the perforation rate was 86% in children less than 1 year of age, 74% between 1 and 1.9 years, 60% between 2 and 2.9 years, 64% between 3 and 3.9 years, and 49% between 4 and 4.9 years), while the rate in older patients was 5%[7]. Seven patients under 1 year of age were included so that the statistical relevance of the differences in the perforation rate of the different age groups would be limited[7]. Moreover, male patients present more risk of perforation than female patients also if the symptoms have a similar duration[10].

A single pediatric center study over a 28-year period reported a similar rate of appendicitis in patients under 1 year of age (0.34%) and 2.3% in patients under 3 years[11].

Andersen *et al*[9], in a cohort of Danish children, reported an annual incidence of 2.22/10000 among boys less than 4 years and 1.82/10000 among girls less than 4 years with a perforation rate of 0.64 and 0.62, respectively. The annual incidence among 10-19 years old boys and girls was 22/10000 and 18/10000 respectively, with a perforation rate of one third the rate of young children[9].

The risk of perforation increases with diagnostic delay. In children 5-12 years old, if the diagnosis is made in less than 24 h from the outbreak of symptoms, the reported perforation rate is 7%, if between 24-48 h 38%, and if more than 48 h 98%[8]. In patients < 3 years, the perforation rate is high (70%), even if the time to diagnosis is less than 48 h[4].

A timely diagnosis is more difficult in toddlers because of presentation to emergency department delayed since the outbreak of symptoms of 1.6 d for patients less than 5 years[7], and 3 d in patients less than 3 years[11].

ANATOMIC AND PATHOPHYSIOLOGIC ELEMENTS

Differences in the appendicitis clinical presentation could be explained by age-related variations in appendiceal anatomy and development. In the neonatal period, the appendix is 4.5 cm long reaching the length of 9.5 cm in adults[12]. Acute appendicitis is rare in neonates because they present a funnel-shaped appendix[13,14], have liquid diet, supine posture, low frequency of gastrointestinal and upper respiratory tract infections[15]. Furthermore, there is evidence that breast-feeding could reduce the risk of appendicitis[16].

Between 1-2 years of age, the appendix becomes similar to that of an adult and the susceptibility to inflammation increases. Lymphoid follicle hyperplasia and follicular size gradually increase with the major expression during adolescence, corresponding to the period of the highest rate of appendicitis[1]. Young children have an undeveloped omentum that is not able to limit the purulent material effusion from a perforation[17]. For this reason, diffuse peritonitis following a perforation is more likely in young children[18]. The mobility of fetal and infant appendices is accentuated and the probability of appendix to be fixed by mesenteric connections to the cecum, ascending colon, or abdominal wall is lower[19]. This could explain why the incidence of localized abscesses in young children is infrequent.

HISTORY AND CLINICAL EXAMINATION

In preverbal toddlers and preschoolers, the anamnesis about the pain is difficult to examine[20]. In preverbal children, clinicians need to relay on the physical examination and on detecting contingent signs of pathology evaluating how children eat, move around, play, sleep, and defecate[20]. Many children, in particular young children, can be easily influenced. Even though their conflicting significances, questions such as "Does it hurt here?" and "This feels fine, right?" may lead to the same positive answer[20]. Abdominal pain usually begins as vague mid-abdominal or periumbilical pain migrating to the right lower quadrant during an interval of hours to days, and many school-aged children can accurately report and localize their pain movement. However, young children may not be able to describe accurately their symptoms, and the clinicians could locate the pain exclusively asking the children to show the painful abdominal point[20].

Pain is the most frequent presenting symptom in children less than 5 years old. In a cohort of 120 patients less than 5 years, 94% presented with pain,

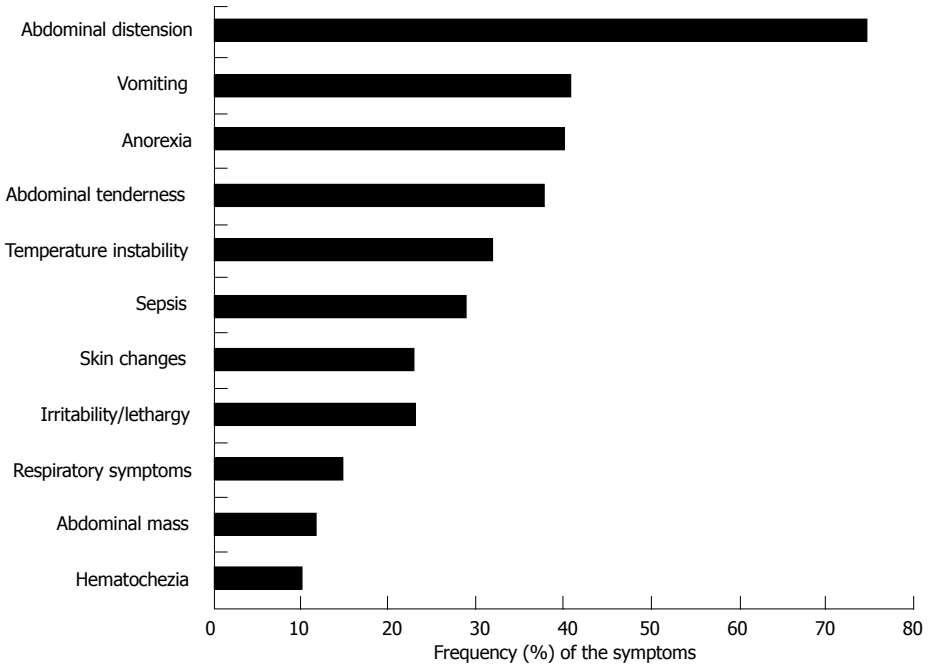

Figure 1 Neonatal appendicitis: frequency of symptoms at presentation (modified from ref.[24]).

83% with vomiting, 80% with fever, 74% with refusal to eat, and 32% with diarrhea[21]. When the data was restricted to children less than 3 years, vomiting, fever and diarrhea were more frequent[11]. If the appendicitis is non-perforated the most common physical sign is localized tenderness (61%) followed by guarding (55%), diffuse tenderness (39%), rebound (32%), and mass (6%)[21]. If the appendicitis is perforated, the most frequent sign is the guarding (79%) followed by diffuse tenderness (62%), rebound (39%), localized tenderness (33%), mass (9%), and rigidity (7%)[21].

In the neonatal period, the signs and symptoms are nonspecific with irritability or lethargy (22%), abdominal distension (60%-90%), and vomiting (59%)[15,22]. Other symptoms include a palpable mass (20%-40%)[15], abdominal wall cellulitis (12%-16%), hypotension, hypothermia, and respiratory distress[22-25]. The most common clinical presenting signs and symptoms are reported in Figure 1[24].

LABORATORY EVALUATION

White blood cell count (WBC) and C-reactive protein (CRP) are commonly used when an acute appendicitis is suspected. Conventional WBC count presents both low sensitivity and specificity, in fact it could increase in 70% of the patients presenting abdominal pain for causes different from appendicitis[26]. A high WBC count or a left shift (represented by higher than 80% polymorphonuclear cells along with bands) has good sensitivity (79%), while the coexistence of both positive WBC count and left shift present the greatest specificity (94%)[27]. The sensitivity and specificity of WBC counts range from 70%-80% and 60%-68%, respectively[28]. Up to 20% of children with pathologically proven appendicitis present a WBC in the normal range[29], while the leukocyte response declines in children younger than 5 years old with appendicitis[30].

CRP is more specific than WBC count, even if in the early stage of acute appendicitis the sensitivity is lower[26,31]. The reported sensitivity and specificity are of 57% and 87% respectively[28]. CRP presents higher sensitivity in discovering appendiceal perforation and abscess formation[26,31]. Recently, it has been demonstrated that the use of both WBC count and CRP may lead to enhanced negative predictive value[6,32]. Yokoyama *et al*[33] showed as indicative of surgical intervention a CRP cut-off value of 4.95 mg/dL (sensitivity 84% and specificity 76%). Procalcitonin is not helpful in the acute appendicitis diagnosis presenting a diagnostic accuracy lower than CRP and WBC[31]. When a complicated appendicitis is present the pooled procalcitonin sensitivity and specificity are 62% and 94%, respectively[31].

RADIOLOGICAL EVALUATION

Computed tomography (CT) has been considered the radiological gold standard to confirm clinical suspicion of appendicitis with high sensitivity and specificity[34,35]. Repeated CT carries an established risk of increased incidence of cancer in children and its use should therefore be limited to clear indications with a well-defined risk to benefit ratio[36]. Less operator dependence, easier visualization of retrocecal appendix, less interference of bowel gas, obesity, or patient pain and tenderness with image quality are included among CT advantages. For these reasons, CT remains the most common primary imaging method before

Table 1 Conditions mimicking childhood and neonatal appendicitis (modified from ref.[8])

Condition	Diagnostic clues
Gastroenteritis	Continuous abdominal pain
	Poor clinical condition with mild or no dehydration, continuous, focal abdominal pain, and lack of movement in infants and young children distinguishes appendicitis from gastroenteritis
	Acute appendicitis is more common during viral epidemics and bacterial gastroenteritis[44]
Upper respiratory tract infection[1]	The presence of concomitant signs of upper respiratory infection are common in toddlers and does not rule out the possibility of appendicitis
Pneumonia	Basal pneumonia may mimic appendicitis pain[45]
	Simultaneous pneumococcal pneumonia and appendicitis is well reported in the literature[46]
Sepsis	An acute appendicitis should be suspected and ruled out in any case of sepsis associated with abdominal pain and or abdominal tenderness[47]
Urinary tract infection	Peritoneal inflammation may cause voiding disturbances and bladder symptoms[48]
Blunt abdominal trauma	Acute appendicitis may be associated with blunt abdominal trauma[49-51]
Intussception	Abdominal US is highly operator dependent
	In presence of fever, localized pain and guarding in infants and young children, appendicitis should be ruled out[52]
NEC	With a history of NEC outside prematurity and signs of abdominal cellulitis, neonatal appendicitis should be ruled out[53]

[1]Includes diagnoses of otitis media, sinusitis, pharyngitis and upper respiratory tract infection. US: Ultrasonography; NEC: Necrotizing enterocolitis.

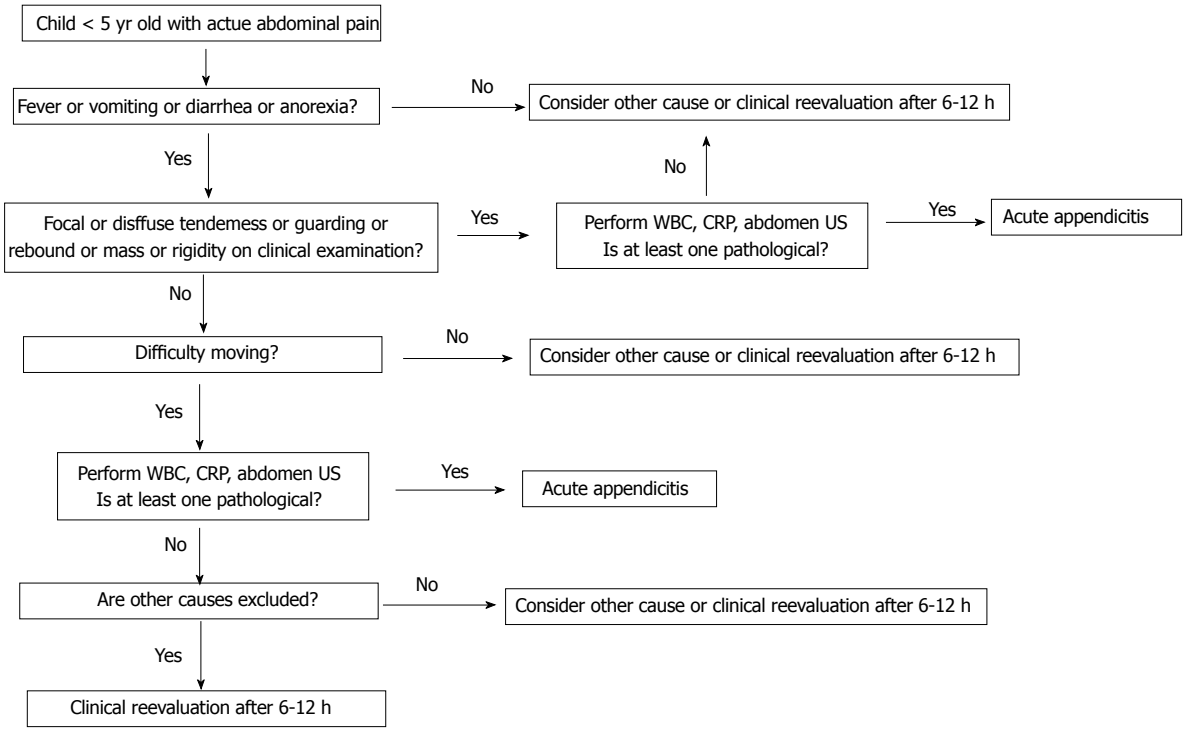

Figure 2 Diagnostic algorithm to assess acute appendicitis in young children. WBC: White blood cell count; CRP: C-reactive protein; US: Ultrasonography.

appendectomy in children[25,37]. To increase sensitivity of diagnosis but decrease radiation exposure, CT used in conjunction with equivocal ultrasonography (US) has been recommended as the most judicious diagnostic imaging pathway[38].

Using US for the acute appendicitis diagnosis is convenient and safe, but is highly operator dependent with a wide reported sensitivity range (44%-100%)[34,36,39]. There is evidence that the diagnostic accuracy can be improved[40] using specific US criteria and using repeated scans[41].

Magnetic resonance imaging (MRI) may also be used in young children[42]. Diagnostic imaging with US selectively followed by MRI is possible and comparable to CT, without differences in time to antibiotic administration and appendectomy, negative appendectomy and perforation rate, or length of stay[43]. Aspelund *et al*[43] showed an high US-MRI pathway specificity (99%) with a sensibility of 100%.

DIFFERENTIAL DIAGNOSIS

Appendicitis in young children is a diagnostic challenge. In a case series of 27 children less than 3 years, 67% had been visited by one or more clinicians without the diagnosis of acute appendicitis had been performed[11].

At this age the diagnosis of appendicitis may be hided by other medical conditions (Table 1). Gastroenteritis is the most common misdiagnosis (possible red flags to suspect appendicitis mimicking a gastroenteritis are shown in Table 1), in fact diarrhea may be present in 33%-41% of patients[4,26]. Importantly, as prior infective diseases may play a role in the physiopathology of acute appendicitis[54], diagnosis of a gastrointestinal, respiratory or urinary infection, should not rule out concomitant acute appendicitis[55].

CONCLUSION

A timely diagnosis of acute appendicitis in young children is a challenge due to the rarity of the disease, the varied presentation, and the rapid development of complications. A high level of suspicion and the knowledge of specific red flags can increase diagnostic skill. We present a diagnostic algorithm (Figure 2) that could be used to assess acute appendicitis in young children, optimizing diagnostic sources and limiting the CT use.

REFERENCES

1 **Addiss DG**, Shaffer N, Fowler BS, Tauxe RV. The epidemiology of appendicitis and appendectomy in the United States. *Am J Epidemiol* 1990; **132**: 910-925 [PMID: 2239906]

2 **Hall MJ**, DeFrances CJ, Williams SN, Golosinskiy A, Schwartzman A. National Hospital Discharge Survey: 2007 summary. *Natl Health Stat Report* 2010; **(29)**: 1-20, 24 [PMID: 21086860]

3 **Davenport M**. Acute abdominal pain in children. *BMJ* 1996; **312**: 498-501 [PMID: 8597689 DOI: 10.1136/bmj.312.7029.498]

4 **Horwitz JR**, Gursoy M, Jaksic T, Lally KP. Importance of diarrhea as a presenting symptom of appendicitis in very young children. *Am J Surg* 1997; **173**: 80-82 [PMID: 9074368 DOI: 10.1016/S0002-9610(96)00417-5]

5 **Irish MS**, Pearl RH, Caty MG, Glick PL. The approach to common abdominal diagnosis in infants and children. *Pediatr Clin North Am* 1998; **45**: 729-772 [PMID: 9728184 DOI: 10.1016/S0031-3955(05)70043-2]

6 **Stefanutti G**, Ghirardo V, Gamba P. Inflammatory markers for acute appendicitis in children: are they helpful? *J Pediatr Surg* 2007; **42**: 773-776 [PMID: 17502181 DOI: 10.1016/j.jpedsurg.2006.12.028]

7 **Bansal S**, Banever GT, Karrer FM, Partrick DA. Appendicitis in children less than 5 years old: influence of age on presentation and outcome. *Am J Surg* 2012; **204**: 1031-1035; discussion 1035 [PMID: 23231939 DOI: 10.1016/j.amjsurg.2012.10.003]

8 **Rothrock SG**, Pagane J. Acute appendicitis in children: emergency department diagnosis and management. *Ann Emerg Med* 2000; **36**: 39-51 [PMID: 10874234 DOI: 10.1067/mem.2000.105658]

9 **Andersen SB**, Paerregaard A, Larsen K. Changes in the epidemiology of acute appendicitis and appendectomy in Danish children 1996-2004. *Eur J Pediatr Surg* 2009; **19**: 286-289 [PMID: 19548193 DOI: 10.1055/s-0029-1224199]

10 **Augustin T**, Cagir B, Vandermeer TJ. Characteristics of perforated appendicitis: effect of delay is confounded by age and gender. *J Gastrointest Surg* 2011; **15**: 1223-1231 [PMID: 21557019 DOI: 10.1007/s11605-011-1486-x]

11 **Alloo J**, Gerstle T, Shilyansky J, Ein SH. Appendicitis in children less than 3 years of age: a 28-year review. *Pediatr Surg Int* 2004; **19**: 777-779 [PMID: 14730382 DOI: 10.1007/s00383-002-0775-6]

12 **Buschard K**, Kjaeldgaard A. Investigation and analysis of the position, fixation, length and embryology of the vermiform appendix. *Acta Chir Scand* 1973; **139**: 293-298 [PMID: 4698491]

13 **Collins DC**. 71,000 human appendix specimens. a final report, summarizing forty years' study. *Am J Proctol* 1963; **14**: 265-281 [PMID: 14098730]

14 **Karaman A**, Cavuşoğlu YH, Karaman I, Cakmak O. Seven cases of neonatal appendicitis with a review of the English language literature of the last century. *Pediatr Surg Int* 2003; **19**: 707-709 [PMID: 14689209 DOI: 10.1007/s00383-003-1030-5]

15 **Schorlemmer GR**, Herbst CA. Perforated neonatal appendicitis. *South Med J* 1983; **76**: 536-537 [PMID: 6340217 DOI: 10.1097/00007611-198304000-00039]

16 **Alves JG**, Figueiroa JN, Barros I. Does breast feeding provide protection against acute appendicitis? A case-control study. *Trop Doct* 2008; **38**: 235-236 [PMID: 18820196 DOI: 10.1258/td.2008.070404]

17 **Rasmussen OO**, Hoffmann J. Assessment of the reliability of the symptoms and signs of acute appendicitis. *J R Coll Surg Edinb* 1991; **36**: 372-377 [PMID: 1774704]

18 **Gilbert SR**, Emmens RW, Putnam TC. Appendicitis in children. *Surg Gynecol Obstet* 1985; **161**: 261-265 [PMID: 4035541]

19 **Maisel H**. The position of the human vermiform appendix in fetal and adult age groups. *Anat Rec* 1960; **136**: 385-389 [DOI: 10.1002/ar.1091360305]

20 **Bundy DG**, Byerley JS, Liles EA, Perrin EM, Katznelson J, Rice HE. Does this child have appendicitis? *JAMA* 2007; **298**: 438-451 [PMID: 17652298 DOI: 10.1001/jama.298.4.438]

21 **Nance ML**, Adamson WT, Hedrick HL. Appendicitis in the young child: a continuing diagnostic challenge. *Pediatr Emerg Care* 2000; **16**: 160-162 [PMID: 10888451 DOI: 10.1097/00006565-200006000-00005]

22 **Buntain WL**, Krempe RE, Kraft JW. Neonatal appendicitis. *Ala J Med Sci* 1984; **21**: 295-299 [PMID: 6476293]

23 **Bryant LR**, Trinkle JK, Noonan JA, Nighbert EJ. Appendicitis and appendiceal perforation in neonates. *Am Surg* 1970; **36**: 523-525 [PMID: 5457878]

24 **Schwartz KL**, Gilad E, Sigalet D, Yu W, Wong AL. Neonatal acute appendicitis: a proposed algorithm for timely diagnosis. *J Pediatr Surg* 2011; **46**: 2060-2064 [PMID: 22075333 DOI: 10.1016/j.jpedsurg.2011.07.018]

25 **Saito JM**, Yan Y, Evashwick TW, Warner BW, Tarr PI. Use and accuracy of diagnostic imaging by hospital type in pediatric appendicitis. *Pediatrics* 2013; **131**: e37-e44 [PMID: 23266930 DOI: 10.1542/peds.2012-1665]

26 **Andersson RE**. Meta-analysis of the clinical and laboratory diagnosis of appendicitis. *Br J Surg* 2004; **91**: 28-37 [PMID: 14716790 DOI: 10.1002/bjs.4464]

27 **Wang LT**, Prentiss KA, Simon JZ, Doody DP, Ryan DP. The use of white blood cell count and left shift in the diagnosis of appendicitis in children. *Pediatr Emerg Care* 2007; **23**: 69-76 [PMID: 17351404 DOI: 10.1097/PEC.0b013e31802d1716]

28 **Bates MF**, Khander A, Steigman SA, Tracy TF, Luks FI. Use of white blood cell count and negative appendectomy rate. *Pediatrics* 2014; **133**: e39-e44 [PMID: 24379236 DOI: 10.1542/peds.2013-2418]

29 **Grönroos JM**. Do normal leucocyte count and C-reactive protein value exclude acute appendicitis in children? *Acta Paediatr* 2001; **90**: 649-651 [PMID: 11440098 DOI: 10.1080/080352501750258711]

30 **Paajanen H**, Mansikka A, Laato M, Kettunen J, Kostiainen S. Are serum inflammatory markers age dependent in acute appendicitis? *J Am Coll Surg* 1997; **184**: 303-308 [PMID: 9060929]

31 **Yu CW**, Juan LI, Wu MH, Shen CJ, Wu JY, Lee CC. Systematic review and meta-analysis of the diagnostic accuracy of procalcitonin, C-reactive protein and white blood cell count for suspected acute appendicitis. *Br J Surg* 2013; **100**: 322-329 [PMID: 23203918 DOI: 10.1002/bjs.9008]

32 **Sack U**, Biereder B, Elouahidi T, Bauer K, Keller T, Tröbs RB. Diagnostic value of blood inflammatory markers for detection of acute appendicitis in children. *BMC Surg* 2006; **6**: 15 [PMID: 17132173 DOI: 10.1186/1471-2482-6-15]

33 **Yokoyama S**, Takifuji K, Hotta T, Matsuda K, Nasu T, Nakamori M, Hirabayashi N, Kinoshita H, Yamaue H. C-Reactive protein is an independent surgical indication marker for appendicitis:

a retrospective study. *World J Emerg Surg* 2009; **4**: 36 [PMID: 19878592 DOI: 10.1186/1749-7922-4-36]

34 **Garcia Peña BM**, Mandl KD, Kraus SJ, Fischer AC, Fleisher GR, Lund DP, Taylor GA. Ultrasonography and limited computed tomography in the diagnosis and management of appendicitis in children. *JAMA* 1999; **282**: 1041-1046 [PMID: 10493202 DOI: 10.1001/jama.282.11.1041]

35 **Hernanz-Schulman M**. CT and US in the diagnosis of appendicitis: an argument for CT. *Radiology* 2010; **255**: 3-7 [PMID: 20308436 DOI: 10.1148/radiol.09091211]

36 **Doria AS**, Moineddin R, Kellenberger CJ, Epelman M, Beyene J, Schuh S, Babyn PS, Dick PT. US or CT for Diagnosis of Appendicitis in Children and Adults? A Meta-Analysis. *Radiology* 2006; **241**: 83-94 [PMID: 16928974 DOI: 10.1148/radiol.2411050913]

37 **Raval MV**, Deans KJ, Rangel SJ, Kelleher KJ, Moss RL. Factors associated with imaging modality choice in children with appendicitis. *J Surg Res* 2012; **177**: 131-136 [PMID: 22507689 DOI: 10.1016/j.jss.2012.03.044]

38 **Krishnamoorthi R**, Ramarajan N, Wang NE, Newman B, Rubesova E, Mueller CM, Barth RA. Effectiveness of a staged US and CT protocol for the diagnosis of pediatric appendicitis: reducing radiation exposure in the age of ALARA. *Radiology* 2011; **259**: 231-239 [PMID: 21324843 DOI: 10.1148/radiol.10100984]

39 **Lowe LH**, Penney MW, Stein SM, Heller RM, Neblett WW, Shyr Y, Hernanz-Schulman M. Unenhanced limited CT of the abdomen in the diagnosis of appendicitis in children: comparison with sonography. *AJR Am J Roentgenol* 2001; **176**: 31-35 [PMID: 11133533 DOI: 10.2214/ajr.176.1.1760031]

40 **Goldin AB**, Khanna P, Thapa M, McBroom JA, Garrison MM, Parisi MT. Revised ultrasound criteria for appendicitis in children improve diagnostic accuracy. *Pediatr Radiol* 2011; **41**: 993-999 [PMID: 21409546 DOI: 10.1007/s00247-011-2018-2]

41 **Dilley A**, Wesson D, Munden M, Hicks J, Brandt M, Minifee P, Nuchtern J. The impact of ultrasound examinations on the management of children with suspected appendicitis: a 3-year analysis. *J Pediatr Surg* 2001; **36**: 303-308 [PMID: 11172421 DOI: 10.1053/jpsu.2001.20702]

42 **Cobben L**, Groot I, Kingma L, Coerkamp E, Puylaert J, Blickman J. A simple MRI protocol in patients with clinically suspected appendicitis: results in 138 patients and effect on outcome of appendectomy. *Eur Radiol* 2009; **19**: 1175-1183 [PMID: 19137303 DOI: 10.1007/s00330-008-1270-9]

43 **Aspelund G**, Fingeret A, Gross E, Kessler D, Keung C, Thirumoorthi A, Oh PS, Behr G, Chen S, Lampl B, Middlesworth W, Kandel J, Ruzal-Shapiro C. Ultrasonography/MRI versus CT for diagnosing appendicitis. *Pediatrics* 2014; **133**: 586-593 [PMID: 24590746 DOI: 10.1542/peds.2013-2128]

44 **Larner AJ**. The aetiology of appendicitis. *Br J Hosp Med* 1988; **39**: 540-542 [PMID: 2840156]

45 **Vendargon S**, Wong PS, Tan KK. Pneumonia presenting as acute abdomen in children: a report of three cases. *Med J Malaysia* 2000; **55**: 520-523 [PMID: 11221169]

46 **Dursun I**, Kiziltan MY, Bozkaya D, Aygün A, Gücüyener K. Pneumococcal pneumonia preceding appendicitis in a child. *Eur J Pediatr* 2004; **163**: 500 [PMID: 15168113 DOI: 10.1007/s00431-004-1479-9]

47 **Crocco S**, Pederiva F, Zanelli E, Scarpa M, Barbi E, Ventura A. Stump appendicitis seven years after appendectomy. *APSP J Case Rep* 2013; **4**: 33 [PMID: 24040611]

48 **Place RC**. Acute urinary retention in a 9-year-old child: an atypical presentation of acute appendicitis. *J Emerg Med* 2006; **31**: 173-175 [PMID: 17044580]

49 **Toumi Z**, Chan A, Hadfield MB, Hulton NR. Systematic review of blunt abdominal trauma as a cause of acute appendicitis. *Ann R Coll Surg Engl* 2010; **92**: 477-482 [PMID: 20513274 DOI: 10.1308/003588410X12664192075936]

50 **Amir A**, Amir L, Waisman Y. Acute appendicitis after a blunt perineal trauma: an illustrative case. *Pediatr Emerg Care* 2009; **25**: 184-185 [PMID: 19287277 DOI: 10.1097/PEC.0b013e31819a8a66]

51 **Ahmed ST**, Ranjan R, Saha SB, Singh B. Traumatic appendicitis misdiagnosed as a case of haemoperitoneum. *BMJ Case Rep* 2014; **pii:** bcr2013202082 [PMID: 24759158 DOI: 10.1136/bcr-2013-202082]

52 **Blevrakis E**, Tampakaki Z, Dimopoulou A, Bakantaki A, Blevrakis E, Sakellaris G. Small bowel intussusception with pelvic plastron secondary to acute appendicitis in child. *J Pediatr Surg* 2010; **45**: E5-E7 [PMID: 20223306 DOI: 10.1016/j.jpedsurg.2009.12.010]

53 **Stiefel D**, Stallmach T, Sacher P. Acute appendicitis in neonates: complication or morbus sui generis? *Pediatr Surg Int* 1998; **14**: 122-123 [PMID: 9880719 DOI: 10.1007/s003830050457]

54 **Singer JI**, Losek JD. Grunting respirations: chest or abdominal pathology? *Pediatr Emerg Care* 1992; **8**: 354-358 [PMID: 1454646 DOI: 10.1097/00006565-199212000-00013]

55 **Paul SP**, Banks T, Fitz-John L. Abdominal pain in children with pneumonia. *Nurs Times* 2012; **108**: 21 [PMID: 22662527]

P- Reviewer: Ince V, Kapischke M, Radojcic BS
S- Editor: Gong XM **L- Editor**: A **E- Editor**: Wu HL

World Journal of Clinical Pediatrics

Submit a Manuscript: http://www.wjgnet.com/esps/
Help Desk: http://www.wjgnet.com/esps/helpdesk.aspx
DOI: 10.5409/wjcp.v4.i2.25

World J Clin Pediatr 2015 May 8; 4(2): 25-29
ISSN 2219-2808 (online)
© 2015 Baishideng Publishing Group Inc. All rights reserved.

MINIREVIEWS

Pyuria in patients with Kawasaki disease

Toru Watanabe

Toru Watanabe, Department of Pediatrics, Niigata City General Hospital, Chuo-ku, Niigata City 950-1197, Japan
Author contributions: Watanabe T solely contributed to this paper.
Conflict-of-interest: The author has no conflict of interest.
Open-Access: This article is an open-access article which was selected by an in-house editor and fully peer-reviewed by external reviewers. It is distributed in accordance with the Creative Commons Attribution Non Commercial (CC BY-NC 4.0) license, which permits others to distribute, remix, adapt, build upon this work non-commercially, and license their derivative works on different terms, provided the original work is properly cited and the use is non-commercial. See: http://creativecommons.org/licenses/by-nc/4.0/
Correspondence to: Toru Watanabe, MD, PhD, Department of Pediatrics, Niigata City General Hospital, 463-7 Shumoku, Chuo-ku, Niigata City 950-1197,
Japan. twata@hosp.niigata.niigata.jp
Telephone: +81-25-2815151
Fax: +81-25-2815169
Received: November 19, 2014
Peer-review started: November 20, 2014
First decision: December 26, 2014
Revised: January 8, 2015
Accepted: February 4, 2015
Article in press: February 9, 2015
Published online: May 8, 2015

Abstract

Kawasaki disease (KD) is an acute, febrile vasculitis that predominantly develops in children ≤ 5 years of age and can lead to multiple organ injuries including the kidneys. Of these injuries, pyuria is a common feature of patients with KD, occurring in 30%-80% of patients. Sterile pyuria is most common in KD patients ≤ 1 year of age. KD patients with sterile pyuria exhibit more severe inflammatory reactions and may have sub-clinical renal injuries. Sterile pyuria in KD is associated with mononuclear cells (not neutrophils) in the urine. Although sterile pyuria in KD was at one time thought to be due to urethritis caused by a non-specific vasculitis of the urethra, recent studies suggest that sterile pyuria in KD originates from the urethra, the kidney as a result of mild and sub-clinical renal injuries, and/or the bladder due to cystitis. Pyuria is not always sterile in KD, but can result from a urinary tract infection (UTI). As causative pathogens, *Escherichia coli* and *Klebsiella oxytoca* have been reported. The clinical phenotypes do not differ between those with or without UTI. Because some KD patients with UTIs have urinary tract abnormalities such as vesicoureteral reflux, a complete UTI workup including renal ultrasound, voiding cystourethrogram and/or dimercaptosuccinic acid renal scan recommended in KD patients with UTIs.

Key words: Sterile pyuria; Kidney involvement; Urinary tract infection; Kawasaki disease; Vasculitis

© The Author(s) 2015. Published by Baishideng Publishing Group Inc. All rights reserved.

Core tip: Pyuria is a common feature of patients with Kawasaki disease (KD), occurring in 30%-80% of patients. KD patients with pyuria exhibit more severe inflammatory reactions and may have sub-clinical renal injuries. Pyuria in KD originates from the urethra, the kidney as a result of mild and sub-clinical renal injuries, and/or the bladder due to cystitis. Pyuria is not always sterile in KD, but can result from a urinary tract infection (UTI). Because some KD patients with UTIs have urinary tract abnormalities, a complete UTI workup including renal ultrasound, voiding cystourethrogram and/or dimercaptosuccinic acid renal scan is recommended in KD patients with UTIs.

Watanabe T. Pyuria in patients with Kawasaki disease. *World J Clin Pediatr* 2015; 4(2): 25-29 Available from: URL: http://www.wjgnet.com/2219-2808/full/v4/i2/25.htm DOI: http://dx.doi.org/10.5409/wjcp.v4.i2.25

INTRODUCTION

Kawasaki disease (KD) is an acute, febrile vasculitis that predominantly develops in children ≤ 5 years

of age[1]. KD affects medium-sized arteries, with a striking predilection for the coronary arteries[1,2]. Children with KD have an acute onset of fever, followed by signs of mucosal inflammation and vasodilation that evolve during the first week of the illness[1]. Laboratory examinations revealed a marked systemic inflammatory response[3]. The cause of KD remains unknown, but it is thought that the immune system is activated by infectious or environmental triggers in genetically-susceptible hosts[2,3].

Because KD is a systemic vasculitis, KD can involve multiple organs and tissues[2], including the coronary arteries, heart, joints, liver, central nervous system[4], muscle[5], and kidney[6,7].

Renal manifestations in KD includes pyuria, pre-renal acute kidney injury (AKI), renal AKI caused by tubulointerstitial nephritis, hemolytic uremic syndrome, immune-complex-mediated nephropathy, renal AKI-associated with KD shock syndrome, acute nephritic syndrome, nephrotic syndrome, and renal tubular abnormalities[7]. Of these renal manifestations of KD, pyuria is the most common abnormal finding[7]. Some KD patients with pyuria have been misdiagnosed with acute pyelonephritis[8], especially in cases of patients with incomplete KD[9,10], defined as patients with fever ⩾ 5 d but only 2 or 3 of the other KD criteria[2]. The following is a review of the prevalence, clinical and laboratory characteristics, and origin of pyuria in patients with KD.

PREVALENCE OF STERILE PYURIA IN PATIENTS WITH KD

No patients had pyuria according to the first report of KD, as described by Kawasaki[11] in 1967. Yamamoto *et al*[12] first described sterile pyuria in Japanese patients with KD in 1968. Yamamoto *et al*[12] reported that 8 of 23 (34.8%) patients with KD exhibited pyuria. Subsequently, Kawasaki *et al*[13] reported an increase in urine sediment leukocytes as a significant finding of KD in 1974. Thereafter, several studies regarding pyuria in KD have been reported. Melish *et al*[14] reported that 10 of 16 (62.5%) American patients with KD exhibited sterile pyuria. Barone *et al*[15] indicated that 13 of 27 (48.1%) American patients with classic KD and 4 of 11 (36.4%) patients with atypical KD had pyuria. Wirojanan *et al*[16] found that 23 of 70 (33%) Thai patients with KD had sterile pyuria. We also reported that 10 of 23 (43.5%) Japanese patients with KD had sterile pyuria[17]. Perrin *et al*[18] showed that pyuria was present in 45.3% of French patients with complete KD and in 30.8% of patients with incomplete KD. Recent studies by Shike *et al*[19], Sepahi *et al*[20], Liu *et al*[21], Choi *et al*[22], and Soleimani *et al*[23] have described sterile pyuria in 106 of 135 (79.8%), 32 of 47 (68%), 44 of 145 (30.3%), 40 of 133 (30%), and 17 of 47 (36.2%) patients with KD, respectively. Taken together, 30%-80% of patients with KD had pyuria (Table 1).

Table 1 The prevalence of pyuria in patients with Kawasaki disease

Ref.	No. of patients with pyuria /No. of total patients	The percent of patients with pyuria
Yamamoto *et al*[12]	8/23	34.8
Melish *et al*[14]	10/16	62.5
Barone *et al*[15]	13/27	48.1
Wirojanan *et al*[16]	23/70	33
Watanabe *et al*[17]	10/23	43.5
Perrin *et al*[18]		45.4
Shike *et al*[19]	106/135	79.8
Sepahi *et al*[20]	32/47	68.1
Liu *et al*[21]	44/145	30.3
Choi *et al*[22]	40/133	30
Soleimani *et al*[23]	17/47	36.2

In contrast, Turner *et al*[24] reported that 43% of febrile children without urinary tract infection had moderate pyuria (10-100 cells/high-power field) with only 9% of febrile children having definite pyuria (> 100 cells/high-power field). This finding indicated that pyuria might be a non-specific feature of fever in acute childhood illness. Shike *et al*[19] also reported that 79% of KD patients and 54% of febrile control subjects had sterile pyuria; however, they showed that the median urine white blood cell count was significantly higher in patients with KD than in febrile control subjects. Our study also showed that one-third of patients with KD exhibited definite pyuria[17]; thus, pyuria is a common feature of KD.

CLINICAL AND LABORATORY CHARACTERISTICS OF KD PATIENTS WITH STERILE PYURIA

Pyuria is defined as > 5 leukocytes/high-power field[25] or > 10 leukocytes/μL[26]. Sterile pyuria is defined as pyuria with a negative urine culture[26]. Sterile pyuria can occur in various infectious or noninfectious disorders (Table 2)[25,27]. Although pyuria can occur in patients with KD of all ages, pyuria is more common in patients ⩽ 1 year of age. Wirojanan *et al*[16] reported that 10 of 13 (77%) KD patients ⩽ 1 year of age had pyuria, although only 13 of 57 (22%) KD patients ⩾ 1 year exhibited pyuria. Liu *et al*[21] also reported that pyuria was present in 28 of 75 (40%) and 16 of 80 (20%) KD patients ⩽ 1 and ⩾ 1 year of age, respectively.

We studied the laboratory data of patients with KD divided into three groups: patients without pyuria, patients with pyuria in both voided urine and bladder urine obtained by transurethral catheterization (bladder pyuria), and patients with pyuria only in voided urine (urethral pyuria) and reported that the urinary protein level was higher in patients with pyuria than patients without pyuria, and the urinary β2-

Table 2 Causes of sterile pyuria in children

Causes
Infectious causes
Partially treated bacterial UTI
UTI in the presence of urinary obstruction
Renal tuberculosis
Renal abscess
Renal tuberculosis
Inflammation near the ureter or bladder (appendicitis, Crohn disease)
Febrile disorders other than UTI
Noninfectious causes
Nephrolithiasis
Kidney and urinary tract anomalies
Glomerulonephritis
Interstitial nephritis
Systemic lupus erythematosus
Interstitial cystitis
Kawasaki disease

UTI: Urinary tract infection.

microglobulin (β2MG), serum blood urea nitrogen (BUN) and creatinine levels were higher in patients with bladder pyuria than in patients with urethral pyuria or in patients without pyuria[17]. Choi *et al*[22] reported that the erythrocyte sedimentation rate, C-reactive protein level and serum concentrations of alanine aminotransferase and BUN were significantly higher in patients with pyuria than in patients without pyuria. These studies suggest that KD patients with pyuria exhibit more severe inflammatory reactions and may have sub-clinical renal injuries.

ORIGIN OF PYURIA IN PATIENTS WITH KD

Sterile pyuria in KD is associated with mononuclear cells (not neutrophils) in the urine[28,29]. A previous study demonstrated mononuclear cells with intracytoplasmic inclusions in the urinary sediment of a patient with KD, which might be derived from mononuclear phagocytic cells[30].

Sterile pyuria in KD was thought to be due to urethritis caused by a non-specific vasculitis of the urethra[29]. Melish *et al*[14] performed bladder taps on 4 KD patients with pyuria in voided urine specimens and reported bladder urine to be free of white blood cells, suggesting that urethral inflammation was the source of pyuria in patients with KD; however, we reported that 5 of 10 KD patients with sterile pyuria in voided urine samples also had leukocytes in bladder urine, suggesting that some patients with KD develop sterile pyuria that originates from the urethra and/or the kidney as a result of mild and sub-clinical renal injuries[17]. Renal injuries in patients with KD have been reported using imaging studies and/or urinary cytokines analysis. Ohta *et al*[28] reported that increased levels of urinary interleukin-6 (IL-6), β2MG and N-acetyl-β-D-glucosaminidase in most patients with KD. Wang *et al*[31] performed dimercaptosuccinic acid (DMSA) renal SPECT on 50 patients with KD, and reported that 26 of these patients (52%) had renal inflammatory foci. Wu *et al*[32] performed DMSA renal SPECT and renal Doppler ultrasonography to measure the pulsatility index (PI), and analyzed urinary IL-6 levels in 50 patients with KD. They showed that 10 of 24 (42%) patients had renal inflammatory foci, that patients with renal inflammatory foci had significantly higher levels of urinary IL-6 and PI values than patients without renal inflammatory foci, and that there was a significant correlation between urinary IL-6 levels and PI values. These studies suggest the presence of renal parenchymal inflammatory lesions during the acute phase of KD, which can result in sterile pyuria.

In addition, we recently reported a case of acute cystitis in a patient with KD. This case suggested that sterile pyuria in KD may originate from the bladder due to cystitis[33].

KD ASSOCIATED WITH URINARY TRACT INFECTION

Pyuria is not always sterile in KD. Ooto *et al*[34] first reported a KD patient with urinary tract infection (UTI) due to Klebsiella oxytoca and left vesicoureteral reflux (VUR). Shiono *et al*[35] reported a KD patient with acute pyelonephritis due to *Escherihia coli* (*E. coli*) and left VUR. Horikawa *et al*[36] and Husain *et al*[37] individually reported KD patients with UTIs caused by *E. coli* and without any urinary tract abnormalities.

Benseler *et al*[38] reviewed the clinical, laboratory and microbiological data of 129 patients with KD and reported that 33% of patients with KD had concurrent infections at the time of KD diagnosis, 4 patients with KD developed UTIs due to *E. coli* (3 patients) or Klebsiella (1 patient), and concurrent infections at the time of diagnosis of KD did not affect the patient response to treatment with intravenous immunoglobulin. Wu *et al*[39] retrospectively reviewed the clinical and laboratory data of 75 patients with KD who underwent urinalysis and urine bacterial cultures, and reported that 34 (45.3%) patients had sterile pyuria, 8 (10.7%) had bacterial pyuria and 2 (2.7%) had UTIs without pyuria, 6 of 10 (60%) patients with UTIs were ≤ 12 mo of age, and there were no significant differences in clinical presentations, laboratory data, and response to treatment between those with and without UTI.

Taken together, pyuria is not always sterile. The clinical phenotypes do not differ between those with or without UTIs. Because some KD patients with UTIs have urinary tract abnormalities such as VUR, a complete UTI workup including renal ultrasound, voiding cystourethrogram and/or dimercaptosuccinic acid renal scan is recommended[39].

CONCLUSION

Pyuria is a common feature of patients with KD, occurring in 30%-80% of patients. KD patients with pyuria are more likely to be ≤ 1 year of age, exhibit more severe inflammatory reactions, and may have sub-clinical renal injuries. Sterile pyuria in KD patients originates from the urethra, the kidney as a result of mild and sub-clinical renal injuries, and/or the bladder due to cystitis. Pyuria is not always sterile in KD and results from UTI. Because some KD patients with UTIs have urinary tract abnormalities, a complete UTI workup is recommended.

REFERENCES

1 **Burns JC**, Glodé MP. Kawasaki syndrome. *Lancet* 2004; **364**: 533-544 [PMID: 15302199]

2 **Scuccimarri R**. Kawasaki disease. *Pediatr Clin North Am* 2012; **59**: 425-445 [PMID: 22560578 DOI: 10.1016/j.pcl.2012.03.009]

3 **Sundel RP**, Petty RE. Kawasaki disease. In: Classidy JT, Laxer RM, Petty RE, Lindsley CB. Textbook of pediatric rheumatology. Philadelphia: Saunders, 2011: 505-520

4 **Tizard EJ**. Complications of Kawasaki disease. *Curr Pediatr* 2005; **15**: 62-68 [DOI: 10.1016/j.cupe.2004.09.002]

5 **Watanabe T**, Iwabuchi H, Abe T. Rhabdomyolysis in a patient with Kawasaki disease. *Eur J Pediatr* 2003; **162**: 891-892 [PMID: 14569397]

6 **Watanabe T**, Abe Y, Sato S, Uehara Y, Ikeno K, Abe T. Hyponatremia in Kawasaki disease. *Pediatr Nephrol* 2006; **21**: 778-781 [PMID: 16565868]

7 **Watanabe T**. Kidney and urinary tract involvement in kawasaki disease. *Int J Pediatr* 2013; **2013**: 831834 [PMID: 24288547 DOI: 10.1155/2013/831834]

8 **Ristoska-Bojkovska N**, Stavric K, Tasic V. Kawasaki disease misdiagnosed as acute pyelonephritis. *Pediatr Nephrol* 2003; **18**: 851-852 [PMID: 12811649]

9 **Wu CY**, Hsieh KS, Chiou YH, Wang RS, Huang IF, Lee WY, Chiou CC. Prolonged fever and pyuria: a urinary tract infection presentation of incomplete Kawasaki disease. *Acta Paediatr* 2005; **94**: 375-377 [PMID: 16028661]

10 **Cotugno N**, Aquilani A, Manno EC, Salfa I, Castelluzzo MA, Finocchi A, Palma P. A 2-month-old male with pyuria and persistent fever. *Pediatr Ann* 2012; **41**: 405-407 [PMID: 23052143 DOI: 10.3928/00904481-20120924-06]

11 **Kawasaki T**. Pediatric acute febrile mucocutaneous lymph node syndrome: clinical observation of 50 cases. *Arerugi* 1967; **16**: 178-222

12 **Yamamoto T**, Ohya T, Watanabe A, Iwatsubo T, Kin H, Ishii A, et al. Clinical characterization of acute febrile mucocutaneous lymph node syndrome. *Shonika Rinshou* 1968; **21**: 291-297

13 **Kawasaki T**, Kosaki F, Okawa S, Shigematsu I, Yanagawa H. A new infantile acute febrile mucocutaneous lymph node syndrome (MLNS) prevailing in Japan. *Pediatrics* 1974; **54**: 271-276 [PMID: 4153258]

14 **Melish ME**, Hicks RM, Larson EJ. Mucocutaneous lymph node syndrome in the United States. *Am J Dis Child* 1976; **130**: 599-607 [PMID: 7134]

15 **Barone SR**, Pontrelli LR, Krilov LR. The differentiation of classic Kawasaki disease, atypical Kawasaki disease, and acute adenoviral infection: use of clinical features and a rapid direct fluorescent antigen test. *Arch Pediatr Adolesc Med* 2000; **154**: 453-456 [PMID: 10807294]

16 **Wirojanan J**, Sopontammarak S, Vachvanichsanong P. Sterile pyuria in Kawasaki disease. *Pediatr Nephrol* 2004; **19**: 363 [PMID: 14745638]

17 **Watanabe T**, Abe Y, Sato S, Uehara Y, Ikeno K, Abe T. Sterile pyuria in patients with Kawasaki disease originates from both the urethra and the kidney. *Pediatr Nephrol* 2007; **22**: 987-991 [PMID: 17323086]

18 **Perrin L**, Letierce A, Guitton C, Tran TA, Lambert V, Koné-Paut I. Comparative study of complete versus incomplete Kawasaki disease in 59 pediatric patients. *Joint Bone Spine* 2009; **76**: 481-485 [PMID: 19811939 DOI: 10.1016/j.jbspin.2008.11.015]

19 **Shike H**, Kanegaye JT, Best BM, Pancheri J, Burns JC. Pyuria associated with acute Kawasaki disease and fever from other causes. *Pediatr Infect Dis J* 2009; **28**: 440-443 [PMID: 19319019 DOI: 10.1097/INF.0b013e318193ec8e]

20 **Sepahi MA**, Miri R, Ahmadi HT. Association of sterile pyuria and coronary artery aneurysm in Kawasaki syndrome. *Acta Med Iran* 2011; **49**: 606-611 [PMID: 22052144]

21 **Liu HC**, Lo CW, Hwang B, Lee PC. Clinical manifestations vary with different age spectrums in infants with Kawasaki disease. *ScientificWorldJournal* 2012; **2012**: 210382 [PMID: 22454602 DOI: 10.1100/2012/210382]

22 **Choi JY**, Park SY, Choi KH, Park YH, Lee YH. Clinical characteristics of Kawasaki disease with sterile pyuria. *Korean J Pediatr* 2013; **56**: 13-18 [PMID: 23390440 DOI: 10.3345/kjp.2013.56.1.13]

23 **Soleimani G**, Bojd SS, Tajik M, Shahri ES, Rashidi S. Paraclinical evolutions regarding liver and renal abnormalities of Kawasaki disease in the Southeast of Iran. *J Compr Pediatr* 2014; **5**: e15777

24 **Turner GM**, Coulthard MG. Fever can cause pyuria in children. *BMJ* 1995; **311**: 924 [PMID: 7580553]

25 **Hooker JB**, Mold JW, Kumar S. Sterile pyuria in patients admitted to the hospital with infections outside of the urinary tract. *J Am Board Fam Med* 2014; **27**: 97-103 [PMID: 24390891 DOI: 10.3122/jabfm.2014.01.130084]

26 **Hoberman A**, Wald ER, Reynolds EA, Penchansky L, Charron M. Pyuria and bacteriuria in urine specimens obtained by catheter from young children with fever. *J Pediatr* 1994; **124**: 513-519 [PMID: 8151463]

27 **Elder JS**. Urinary tract infections. In: Kliegman RM, Stanton BF, St Geme JW, Schor NF, Behrman RE. Nelson textbook of pediatrics. 19th ed. Philadelphia: Elsevier Saunders, 2011: 1829-1834

28 **Ohta K**, Seno A, Shintani N, Kato E, Yachie A, Seki H, Miyawaki T, Taniguchi N. Increased levels of urinary interleukin-6 in Kawasaki disease. *Eur J Pediatr* 1993; **152**: 647-649 [PMID: 8404968]

29 **Burns JC**. Kawasaki disease. *Adv Pediatr* 2001; **48**: 157-177 [PMID: 11480756]

30 **Kobayashi TK**, Sugimoto T, Nishida K, Sawaragi I. Intracytoplasmic inclusions in urinary sediment cells from a patient with mucocutaneous lymph node syndrome (Kawasaki disease). A case report. *Acta Cytol* 1984; **28**: 687-690 [PMID: 6209879]

31 **Wang JN**, Chiou YY, Chiu NT, Chen MJ, Lee BF, Wu JM. Renal scarring sequelae in childhood Kawasaki disease. *Pediatr Nephrol* 2007; **22**: 684-689 [PMID: 17151872]

32 **Wu JM**, Chiou YY, Hung WP, Chiu NT, Chen MJ, Wang JN. Urinary cytokines and renal Doppler study in Kawasaki disease. *J Pediatr* 2010; **156**: 792-797 [PMID: 20171655 DOI: 10.1016/j.jpeds.2009.11.046]

33 **Watanabe T**. Acute cystitis in a patient with Kawasaki disease. *Int J Clin Pediatr* 2013; **2**: 37-39 [DOI: 10.4021/ijcp102w]

34 **Ooto H**, Shimizu K, Kawabe K, Ishiguro A, Takeoka M, Matsui E. A case of Kawasaki disease with upper urinary tract infection due to Klebsiella oxytoca. *Shonika Rinshou* 1999; **52**: 209-212

35 **Shiono N**, Koga Y, Ito H, Egawa K, Ono S, Itami N. Really sterile pyuria with Kawasaki disease? *Pediatr Nephrol* 2004; **19**: 124 [PMID: 14648336]

36 **Horikawa M**, Oana S, Sakai H. Kawasaki disease with bacteriologically confirmed significant pyuria. *Shonika Rinshou* 2011; **64**: 955-961

37 **Husain EH**, Al-Rashid M. Kawasaki disease in association with urinary tract infection. *Indian Pediatr* 2011; **48**: 808-809 [PMID: 22080685]

38 **Benseler SM**, McCrindle BW, Silverman ED, Tyrrell PN, Wong

J, Yeung RS. Infections and Kawasaki disease: implications for coronary artery outcome. *Pediatrics* 2005; **116**: e760-e766 [PMID: 16322132]

39 **Wu MC**, Jan SL, Lin MC, Fu YC, Lin SJ. Is pyuria with Kawasaki disease always sterile? *Pediatr Infect Dis J* 2008; **27**: 1121 [PMID: 18978511 DOI: 10.1097/INF.0b013e31818b0e0c]

P- Reviewer: Al-Biltagi M, Bianchetti MG, Wang R **S- Editor**: Ji FF
L- Editor: A **E- Editor**: Wu HL

World Journal of Clinical Pediatrics

Submit a Manuscript: http://www.wjgnet.com/esps/
Help Desk: http://www.wjgnet.com/esps/helpdesk.aspx
DOI: 10.5409/wjcp.v4.i2.30

World J Clin Pediatr 2015 May 8; 4(2): 30-34
ISSN 2219-2808 (online)
© 2015 Baishideng Publishing Group Inc. All rights reserved.

CASE REPORT

Endobronchial tumor in children: Unusual finding in recurrent pneumonia, report of three cases

Silvia Madafferi, Vincenzo D Catania, Antonella Accinni, Renata Boldrini, Alessandro Inserra

Silvia Madafferi, Vincenzo D Catania, Antonella Accinni, Alessandro Inserra, Department of General and Thoracic Surgery, Bambino Gesù Children Hospital-Resarch Institute, 00152 Rome, Italy
Renata Boldrini, Department of Pathology, Bambino Gesù Children Hospital-Resarch Institute, 00152 Rome, Italy
Author contributions: Madafferi S, Accinni A and Inserra A designed the report; Boldrini R performed the histopatological analyses; Madafferi S and Catania VD collected the patient's clinical data; Madafferi S, Catania VD and Accinni A analyzed the data and wrote the paper; all authors revisited and approved the final manuscript.
Ethics approval: The study was reviewed and approved by the Ospedale Pediatrico Bambino Gesù Institutional Review Board.
Informed consent: All study partecipants, or their legal guardian, provided informed written consent prior to study enrollment.
Conflict-of-interest: No conflicts of interest were declared by the authors.
Open-Access: This article is an open-access article which was selected by an in-house editor and fully peer-reviewed by external reviewers. It is distributed in accordance with the Creative Commons Attribution Non Commercial (CC BY-NC 4.0) license, which permits others to distribute, remix, adapt, build upon this work non-commercially, and license their derivative works on different terms, provided the original work is properly cited and the use is non-commercial. See: http://creativecommons.org/licenses/by-nc/4.0/
Correspondence to: Vincenzo D Catania, MD, Department of General and Thoracic Surgery, Bambino Gesù Children Hospital-Resarch Institute, p.zza Sant'Onofrio, 4, 00152 Rome, Italy. vdcatania1985@gmail.com
Telephone: +39-6-68592555
Fax: +39-6-68592876
Received: November 25, 2014
Peer-review started: November 26, 2014
First decision: January 8, 2015
Revised: January 27, 2015
Accepted: March 30, 2015
Article in press: April 2, 2015
Published online: May 8, 2015

Abstract

We are reporting 3 cases of pediatric endobronchial tumors presented with recurrent pneumonia. The median age of patients, at time of presentation, was 10.6 years. All patients presented with recurrent pneumonia with a mean time to occurrence, after onset of symptoms, of 14 mo. Bronchoscopy was early performed as part of diagnostic work-up and it revealed an endobronchial mass in every case. Complete surgical resection was performed in all cases, with lung preservation in two of them. Neither post-operative chemotherapy nor radiotherapy was required. The mean duration of follow-up was 7 years and all patients are still alive and disease-free. Recurrent pneumonia, in pediatrics, should raise the suspicion of an obstructing lesion, congenital malformation or systemic disease. A systematic approach is useful for organize the clinicians initial workup. Prompt diagnosis allows parenchymal-sparing surgery, which offers the best chance of cure and reduces clinical and functional complications in these patients.

Key words: Recurrent pneumonia; Pediatric; Endobronchial tumor; Mucoepidermoid tumor; Carcinoid tumor

© The Author(s) 2015. Published by Baishideng Publishing Group Inc. All rights reserved.

Core tip: The role of a systematic diagnostic work up in determining the risk of rare conditions in pediatric recurrent pneumonia has been delineated. This case series not only present 3 cases of rare pediatric endobronchial tumors, but also applies early bronchoscopy as a tool to rule out the presence of tumors of the respiratory tree in case of recurrent pneumonia. Prompt diagnosis allows parenchymal-preserving surgery, which offer the best chance of cure and reduce clinical and functional complications in these patients.

Madafferi S, Catania VD, Accinni A, Boldrini R, Inserra A. Endobronchial tumor in children: Unusual finding in recurrent pneumonia, report of three cases. *World J Clin Pediatr* 2015; 4(2):

30-34 Available from: URL: http://www.wjgnet.com/2219-2808/full/v4/i2/30.htm DOI: http://dx.doi.org/10.5409/wjcp.v4.i2.30

INTRODUCTION

Bronchial adenomas account for 5% of all primary pulmonary neoplasms in children and include both carcinoid and mucoepidermoid tumors[1-4]. These are considered as low-grade and slow growing malignant neoplasm and their evolutions are usually favorable after surgery[1,5,6]. Pathologic findings of endobronchial tumors can represent a wide array of symptoms as atelectasis or recurrent pneumonia, as the consequence of bronchial obstruction[3,5,7,8]. We describe 3 pediatric cases of endobronchial adenomas, occurring over a 10-year period at our hospital. All patients had history of recurrent pneumonia meaning more than 1 episode of pneumonia in 1 year or more than 3 episodes in a lifetime. We discuss their diagnostic work-up and clinical outcome. We suggest, for patients with recurrent pneumonia, early referral for bronchoscopic evaluation for accurate differential diagnosis. A delay in diagnosis of endobronchial tumor may lead to local and distant spread and permanent lung damage as consequence of radical surgery.

CASES REPORT

Case 1

A 14-year-old boy presented with a history of recurrent bronchopneumonia, 5 episodes in the last 18 mo, unresponsive to antibiotic therapy. On clinical examination, he showed no breathing sounds on left hemithorax with thump bluntness. A chest X-ray showed a collapsed left lung with tracheal deviation (Figure 1A). A computer tomography (CT) scan showed a left endobronchial mass arising from the main bronchus with omolateral collapse of the lung and consensual pleural effusion (Figure 1B). Bronchoscopy revealed a polypoid, obstructive mass in the left main bronchus. The biopsy yielded positive result for typical endobronchial carcinoid. At surgery, a wide and infiltrating polypoid mass on main left bronchus was found so left pneumonectomy was performed (Figure 1C). The final histologic examination showed a 1.5-cm polypoid mass that was made up of monomorphic cellular proliferation with a low mitotic proliferative rate. Immunohistochemistry was strongly positive for chromogranin and weak for synaptophysin (Figure 1D). The adjacent pulmonary parenchyma was suggestive of consensual pneumonia. Octeotride scintigraphy showed a physiological tracer without metastasis. At 10 years follow up the patient had neither clinical nor radiological evidence of recurrence of the tumor.

Case 2

A 10-year-old girl was admitted for evaluation and treatment of 1-year history of left pneumonia with 3 consecutive episodes. On examination she was afebrile, dullness to percussion and decreased breath sounds over the left upper lobe of the left lung. A chest X-ray showed a left pulmonary collapse with pleural effusion and an image suspected of left bronchial obstruction. CT scan demonstrated solid and lobulated mass with calcification and atelectasis in the posterior segment of the left upper lobe. Bronchoscopy revealed a polypoid tumor in the left main bronchus. Biopsy resulted in low-grade mucoepidermoid carcinoma. A left superior sleeve lobectomy, with end-to-end anastomosis between the main and inferior lobar bronchus, was performed. The post-operative course was uneventful. Follow up at 7 years was good and spirometric assessments showed forced expiratory volume in 1 s and forced vital capacity within normal range.

Case 3

An 8-year-old boy presented with a 1-year history of bronchospasm and recurrent pneumonia, 4 episodes, unresponsive to corticosteroids, bronchodilators and antibiotic therapy. He was afebrile and his chest examination was unremarkable. Chest X-ray and CT revealed left bronchiectasis and left upper lobe consolidation as for pneumonia. Bronchoscopy revealed a polypoid mass arising from the left main bronchus. Histologic examination showed low-grade mucoepidermoid carcinoma (Figure 2). A left bronchial resection, with end-to-end anastomosis of the left main bronchus, was performed. Post-operative course was uneventful. The patient has remained disease-free at 5-year clinical and radiological follow-up.

DISCUSSION

Recurrent pneumonia is defined as more than 1 episode of pneumonia in 1 year or more than 3 episodes in a lifetime, with radiographically documented clearing episodes[4,7,9]. The number of host defects that can predispose to recurrent pneumonia is high, and differential diagnosis is often challenging. The first step is to confirm the diagnosis of recurrent pneumonia; it should be made by chest X-ray (2 projections) that reveals pulmonary consolidation on more than one occasion[7]. The presence of a persistent infiltrate in the same area, in the interval between pneumonias, could represent treatment failure or localized obstruction[7]. In these cases both CT scan and fiber optic bronchoscopy should be performed to make differential diagnosis between congenital lung defects (congenital adenomatoid cystic malformation, pulmonary sequestration, congenital emphysema), external compression of conducting airways, intraluminal foreign bodies or endobronchial masses[3,4,7,9,10]. Primary endobronchial tumors are rarely considered as predisposing factors for recurrent atelectasis or respiratory tract infection[2,3]. The symptoms are related to airway obstruction and

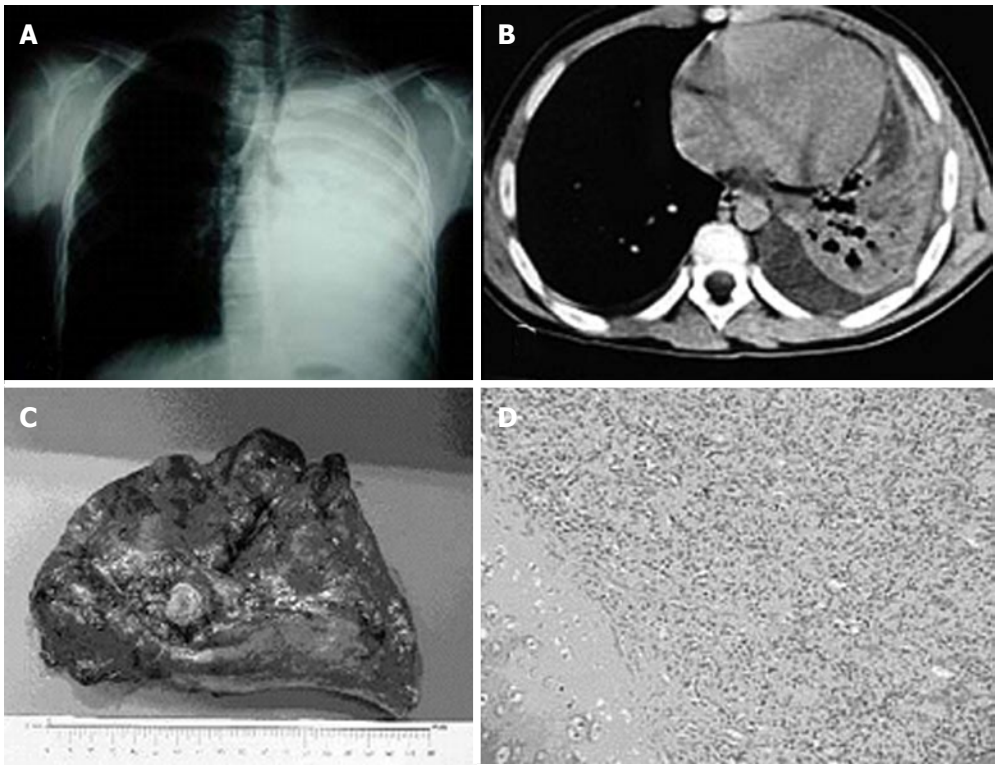

Figure 1 Case 1, endobronchial carcinoid. A: Antero-posterior chest X-ray diagnosed at the onset of the last episode of pneumonia, demonstrating a complete collapse of the left lung with hyperdistension of controlateral one. There is also an aerial bronchogram with a block before the carena; B: Axial computed tomography-scan (CT-scan), performed before operation, demonstrating atelectasis of left lung with pleural effusion; in particular we can observe the obstruction of the left main bronchus; C: Gross findings of the resected left lung, on lateral surface a 1.5 cm polypoid mass obstructing the left main bronchus, firmly adherent to the wall and with a differing consistency from hard to elastic; D: The tumor was pathologically diagnosed as endobronchial carcinoid: on the left the cartilaginous wall and on the right the tumor (HE stain x 20). Monomorphic proliferation with cells forming pseudoacinouses patterns. Absence of atypical cells or abundant mitosis.

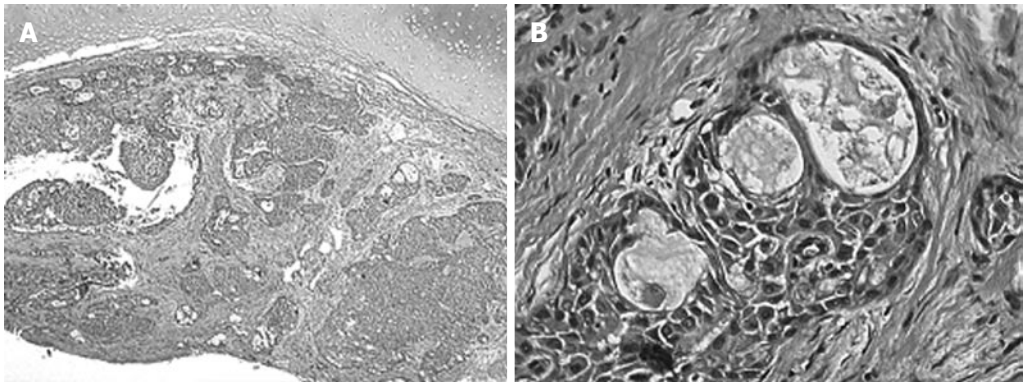

Figure 2 Case 3, mucoepidermoid carcinoma, histological findings. A: The tumor was pathologically diagnosed as mucoepidermoid Carcinoma (HE stain x 5). Neoplastic infiltration of the bronchial submucosa characterized by a mixture of glands, tubules, cysts and solid areas; B: Glandular component of the tumor, lined by columnar mucinous cells and containing mucin, is intimately admixed with solid islands composed of squamous and intermediate cells (HE stain x 63).

include: recurrent pneumonia, persistent cough, sometimes associated with hemoptysis, wheezing and chest pain[1,11]. The lack of specificity of these symptoms may account for a median diagnostic delay of 5.85 ± 5 mo[5]. We describe 3 cases of recurrent pneumonia with mean time to presentation after onset of symptoms of 14 mo. In childhood, the most common primary lung tumors are malignant, with only approximately one-third benign[4]. The rarity of primary lung tumors is emphasized by the findings of an extensive review of the literature, in which the ratio of primary tumors to metastatic tumors to non-neoplastic lesion of the lung is 1:5:60[3,4]. Endobronchial tumors include benign lesions such as hemangiomas, papillomas, inflammatory pseudotumors (plasma cell granulomas), leiomyomas and mucus gland tumors. The malignant ones include: bronchial adenomas (an obvious misnomer), carcinoids, mucoepidermoid carcinomas, and adenoid cystic carcinoma[3,4].

Bronchial carcinoid is the most common primary endobronchial neoplasm; it makes up about 80% of malignant pulmonary neoplasm in children[3,8]. The

tumor arises from the Kulchitsky cell of the respiratory epithelium. Carcinoid tumors can be divided in typical and atypical forms with the latter exhibiting histologically malignant features and aggressive clinical behavior. This histological and clinical distinction is not clear in pediatric population due to the rarity of this pathology[3]. Our case although showed typical histology with benign behavior. In the literature, the median age at diagnosis in children in 10.5 ± 3 years, but we described the case of a patient who came to our attention at 14 years of age[5]. This neoplasm can arise in the lobar bronchi (75%), in the mainstream bronchi (10%), causing atelectasis, or in lung periphery (15%), and the right lung is more often involved then the left one[8,11,12]. These tumors are described as endobronchial polypoid masses with intraluminal, mural and extra bronchial components, which could completely obstruct the bronchus and interfere with distal ventilations giving reason of respiratory symptoms as dyspnea and wheezing or further complications as pneumonia and atelectasis[5,8]. Rarely, patients with tracheobronchial carcinoid tumors present with carcinoid syndrome, such as: Cushing's syndrome, acromegaly, or the inappropriate antidiuretic hormone secretion[12]. Distant metastasis or local recurrences are rarely reported, especially in cases with atypical histology. As in our cases, the chest X-ray may show findings of partial or total bronchial obstruction as atelectasis, although it is reported as normal in about 10% of patients[8,11]. CT scan is the most sensitive noninvasive imaging method for bronchial abnormalities. It allows the best resolutions of a pulmonary mass, defining: the relationship with the tracheobronchial tree, the presence of calcification, reported in 4%-26% of the cases, concomitant lymphadenopathies, and the grade of contrast enhancement[8,11]. However, bronchoscopy is considered as the gold standard for diagnosis and, despite the risk of hemorrhage, endobronchial biopsy has been shown to give the highest yield of positive diagnosis[5]. Sleeve or bronchoplastic resections are preferred to more extensive resection of centrally located carcinoids, even if atypical carcinoid requires a more extensive resection with lymph node dissection[3,8,13]. Our patient underwent pneumonectomy due to the extensive infiltration of the lesion as consequence of late in diagnosis. Techniques for bronchoscopic resection include eletrocautery, NdYAG laser and piecemeal removal with biopsy forceps, but they are considered inadequate and may lead to tumor recurrence[14]. The recurrence rate is estimated at 8.2%, with overall survival of 92% at 10 years[13]. Systematic monitoring after the surgical intervention is recommended with clinical examination and chest X-ray. We followed up our patients for 10 years without evidence of recurrence. Early bronchoscopy should be performed if clinical symptoms, as recurrent pneumonia, and radiological findings are suggestive of tumor recurrence.

Bronchial mucoepidermoid carcinoma is a slow-growing, malignant glandular epithelial neoplasm that origins from excretory duct reserve cells of serous and mucous glands. It, particularly, involve the respiratory mucosa[1,15]. These tumors are rare in children, accounting for 2.5% to 7.3% of endobronchial adenomas and representing 0.1% to 0.2% of primary lung cancers[1,3,16]. Although the age range of patients is extensive, cases involving patients < 10 years old are rarely observed[2]. Our patients had respectively 10 and 8 years of age. The clinical symptoms are mainly related to airway obstruction and include pneumonia or recurrent pneumonias up to 48%[2,11]. Both our patients presented with a clinical history of recurrent pneumonia, respectively 3 and 4 episodes. Common radiological findings, on CT scan, are bronchial nodular mass with or without post-obstructive pneumonia, atelectasis, or a solitary nodule and lymphadenopathies should be always checked[8,15]. Treatment consists of a careful surgical removal of the tumor, the lymphnodes and vascular and perineural infiltration should be evaluated. When technically feasible, a sleeve resection of the involved bronchus is recommended[5]. The prognosis is good in up of 95% of the cases and low and intermediate grade carcinomas, with complete resection, do not require chemotherapy or radiotherapy[1,12]. In the present study lobectomy was performed in one-case and sleeve resections in other one; thus allowed a considerable portion of the lung parenchyma to be preserved. The risk of recurrence justifies a long-term clinical follow-up, indeed bronchoscopy should be performed only in case of severe respiratory symptoms[5]. Our patients had no clinical or radiological evidence of disease recurrence during a 10 and 5 years follow-up period.

Endobronchial tumors are rare in the pediatric population; these tumors most often present with symptoms of recurrent pneumonia or wheezing. In case of respiratory symptoms that do not improve with standard treatment (antibiotics, bronchodilators), further work up with CT scan and bronchoscopy is advisable to rule out the presence of an obstructive process as endobronchial tumors. Early diagnosis may help in determining optimal treatment plan that can increase the possibility of implementing a selective procedure, avoiding the pulmonary functional impairment and chest wall deformity that can result from extensive lung resection and improve outcome.

COMMENTS

Case characteristics

A series of 3 pediatric patients with a median age at presentation of 10.6 years, all presented with recurrent pneumonia, non-responsive to medical standard therapy.

Clinical diagnosis

Case 1: No breathing sounds with thump bluntness and dullness to percussion on left hemithorax; Case 2: Dullness to percussion and decreased breath sounds over the left upper lobe of the left lung; Case 3: No pathological findings on thoracic objective examination.

Differential diagnosis

Cystic congenital adenomatoid malformation, congenital emphysema, lung mass, lung abscess, pneumonia.

Laboratory diagnosis

Blood count cell and metabolic panel tests shows, only, elevated white cells blood count.

Imaging diagnosis

Case 1: An endobronchial mass arising from the left main bronchus with omolateral collapse of the lung and consensual pleural effusion; Case 2: A solid and lobulated mass with internal calcification and atelectasis in the posterior segment of the left upper lobe; Case 3: Left bronchiectasis and left upper lobe consolidation.

Pathological diagnosis

Case 1: Bronchoscopy and biopsy revealed typical endobronchial carcinoid; Case 2: Bronchoscopy and biopsy revealed low-grade mucoepidermoid carcinoma; Case 3: Bronchoscopy and biopsy revealed low-grade mucoepidermoid carcinoma.

Treatment

Case 1: The patient was treated with a left pneumonectomy; Case 2: The patient was treated with a left superior sleeve lobectomy, with end-to-end anastomosis between the main and inferior lobar bronchus; Case 3: The patient was treated with a left bronchial resection, with end-to-end anastomosis of the left main bronchus.

Related reports

Endobronchial tumors are rare in childhood and are not often considered in the differential diagnosis of recurrent pneumonia and bronchoscopy is not usually considered as first diagnostic approach.

Term explanation

Bronchial carcinoid is a tumor that arises from the Kulchitsky cell of the respiratory epithelium. It is divided in typical and atypical forms. Bronchial mucoepidermoid carcinoma is a slow-growing, malignant glandular epithelial neoplasm that origins from excretory duct reserve cells of serous and mucous glands, in particular that find within the submucosal of the respiratory mucosa

Experiences and lessons

This case series not only represents 3 rare cases of pediatric endobronchial tumors, but also underline the need of systematic diagnostic work-up, which should consider bronchoscopy, to prevent delayed diagnosis of potential malignant lesions.

Peer-review

The authors have described three rare cases of pediatric endobronchial tumors that presented with recurrent pneumonia. The article highlights the need of systematic approach to recurrent pneumonia by clinicians to prevent complications due to rare conditions. Prompt diagnosis allows parenchymal-preserving surgery, which offer the best chance of cure and reduce clinical and functional complications in these patients.

REFERENCES

1 **Welsh JH**, Maxson T, Jaksic T, Shahab I, Hicks J. Tracheobronchial mucoepidermoid carcinoma in childhood and adolescence: case report and review of the literature. *Int J Pediatr Otorhinolaryngol* 1998; **45**: 265-273 [PMID: 9865445 DOI: 10.1016/S0165-5876(98)00120-7]

2 **Qian X**, Sun Z, Pan W, Ye Q, Tang J, Cao Z. Childhood bronchial mucoepidermoid tumors: A case report and literature review. *Oncol Lett* 2013; **6**: 1409-1412 [PMID: 24179533]

3 **Al-Qahtani AR**, Di Lorenzo M, Yazbeck S. Endobronchial tumors in children: Institutional experience and literature review. *J Pediatr Surg* 2003; **38**: 733-736 [PMID: 12720182 DOI: 10.1016/jpsu.2003.50195]

4 **Cohen MC**, Kaschula RO. Primary pulmonary tumors in childhood: a review of 31 years' experience and the literature. *Pediatr Pulmonol* 1992; **14**: 222-232 [PMID: 1336597 DOI: 10.1002/ppul.1950140405]

5 **Fauroux B**, Aynie V, Larroquet M, Boccon-Gibod L, Ducou le Pointe H, Tamalet A, Clément A. Carcinoid and mucoepidermoid bronchial tumours in children. *Eur J Pediatr* 2005; **164**: 748-752 [PMID: 16133240 DOI: 10.1007/s00431-005-1740-x]

6 **Roby BB**, Drehner D, Sidman JD. Pediatric tracheal and endobronchial tumors: an institutional experience. *Arch Otolaryngol Head Neck Surg* 2011; **137**: 925-929 [PMID: 21930983 DOI: 10.1001/archoto.2011.153]

7 **Kaplan KA**, Beierle EA, Faro A, Eskin TA, Flotte TR. Recurrent pneumonia in children: a case report and approach to diagnosis. *Clin Pediatr* (Phila) 2006; **45**: 15-22 [PMID: 16429211 DOI: 10.1177/000992280604500103]

8 **Curtis JM**, Lacey D, Smyth R, Carty H. Endobronchial tumours in childhood. *Eur J Radiol* 1998; **29**: 11-20 [PMID: 9934553 DOI: 10.1016/S0720-048X(97)00185-X]

9 **Wald ER**. Recurrent and nonresolving pneumonia in children. *Semin Respir Infect* 1993; **8**: 46-58 [PMID: 8372275]

10 **Andersen JB**, Mortensen J, Damgaard K, Skov M, Sparup J, Petersen BL, Rechnitzer C, Borgwardt L. Fourteen-year-old girl with endobronchial carcinoid tumour presenting with asthma and lobar emphysema. *Clin Respir J* 2010; **4**: 120-124 [PMID: 20565486]

11 **Granata C**, Battistini E, Toma P, Balducci T, Mattioli G, Fregonese B, Gambini C, Rossi GA. Mucoepidermoid carcinoma of the bronchus: a case report and review of the literature. *Pediatr Pulmonol* 1997; **23**: 226-232 [PMID: 9094733 DOI: 10.1002/(SICI)1099-0496(199703)2]

12 **Dewan RK**, Kesieme EB, Ramchandani R. Surgical treatment for tracheobronchial carcinoid tumors: a 16-year experience. *Asian Cardiovasc Thorac Ann* 2012; **20**: 53-57 [PMID: 22371943 DOI: 10.1177/0218492311433775]

13 **Gustafsson BI**, Kidd M, Chan A, Malfertheiner MV, Modlin IM. Bronchopulmonary neuroendocrine tumors. *Cancer* 2008; **113**: 5-21 [PMID: 18473355 DOI: 10.1002/cncr.23542]

14 **Luckraz H**, Amer K, Thomas L, Gibbs A, Butchart EG. Long-term outcome of bronchoscopically resected endobronchial typical carcinoid tumors. *J Thorac Cardiovasc Surg* 2006; **132**: 113-115 [PMID: 16798310 DOI: 10.1016/j.jtcvs.2006.01.061]

15 **Giusti RJ**, Flores RM. Mucoepidermoid carcinoma of the bronchus presenting with a negative chest X-ray and normal pulmonary function in two teenagers: two case reports and review of the literature. *Pediatr Pulmonol* 2004; **37**: 81-84 [PMID: 14679495 DOI: 10.1002/ppul.10390]

16 **Tsuchiya H**, Nagashima K, Ohashi S, Takase Y. Childhood bronchial mucoepidermoid tumors. *J Pediatr Surg* 1997; **32**: 106-109 [PMID: 9021584 DOI: 10.1016/S0022-3468(97)90109-3]

P- Reviewer: Abdel-Aziz M, Aydogdu O **S- Editor**: Tian YL
L- Editor: A **E- Editor**: Wu HL

Published by **Baishideng Publishing Group Inc**
8226 Regency Drive, Pleasanton, CA 94588, USA
Telephone: +1-925-223-8242
Fax: +1-925-223-8243
E-mail: bpgoffice@wjgnet.com
Help Desk: http://www.wjgnet.com/esps/helpdesk.aspx
http://www.wjgnet.com

© 2015 Baishideng Publishing Group Inc. All rights reserved.

ISSN 2219-2808 (online)

World Journal of *Clinical Pediatrics*

World J Clin Pediatr 2015 August 8; 4(3): 35-49

Published by Baishideng Publishing Group Inc

WJCP World Journal of Clinical Pediatrics

A peer-reviewed, online, open-access journal of clinical pediatrics

Editorial Board

2012-2016

The *World Journal of Clinical Pediatrics* Editorial Board consists of 247 members, representing a team of worldwide experts in pediatrics. They are from 43 countries, including Argentina (1), Australia (7), Austria (4), Belgium (2), Brazil (4), Canada (7), Chile (2), China (22), Denmark (2), Egypt (10), Finland (1), France (5), Germany (4), Greece (8), India (14), Iran (5), Israel (7), Italy (22), Japan (6), Mexico (2), Netherlands (2), New Zealand (1), Nigeria (3), Norway (1), Pakistan (2), Poland (2), Portugal (1), Russia (2), Saudi Arabia (2), Serbia (2), Singapore (3), Slovenia (1), South Africa (2), South Korea (2), Spain (5), Sweden (4), Switzerland (1), Thailand (2), Tunisia (1), Turkey (18), United Arab Emirates (1), United Kingdom (11), United States (43).

EDITOR-IN-CHIEF
Eduardo H Garin, *Gainesville*

GUEST EDITORIAL BOARD MEMBERS
Hsiao-Wen Chen, *Taipei*
Ming-Ren Chen, *Taipei*
Mu-Kuan Chen, *Changhua*
Ching-Chi Chi, *Chiayi*
Hung-Chih Lin, *Taichung*

MEMBERS OF THE EDITORIAL BOARD

Argentina

Alcides Richard Troncoso, *Buenos Aires*

Australia

Garry Inglis, *Herston*
Jagat Kanwar, *Victoria*
Katherine Kedzierska, *Parkville*
Eline Suzanne Klaassens, *Brisbane*
Sam S Mehr, *Sydney*
Jing Sun, *Brisbane*
Cuong Duy Tran, *Adelaide*

Austria

Gerhard Cvirn, *Graz*
Claudia Elisabeth Gundacker, *Vienna*
Bernhard Resch, *Graz*
Amulya K Saxena, *Graz*

Belgium

Karel Allegaert, *Leuven*
Yvan Vandenplas, *Brussels*

Brazil

Rejane Correa Marques, *Rio de Janeiro*
Priscila Krauss Pereira, *Rio de Janeiro*
Maria L Seidl-de-Moura, *Rio de Janeiro*
Sandra Elisabete Vieira, *São Paulo*

Canada

Helen SL Chan, *Toronto*
Ediriweera Desapriya, *Vancouver*
Eleftherios P Diamandis, *Toronto*
Ran D Goldman, *Vancouver*
Manjula Gowrishankar, *Edmonton*
Prakesh S Shah, *Toronto*
Pia Wintermark, *Montreal*

Chile

René Mauricio Barría, *Valdivia*
Irene Morales Bozo, *Santiago*

China

Yu-Zuo Bai, *Shenyang*
Xiao-Ming Ben, *Nanjing*
Kwong-Leung Chan, *Hong Kong*
Xian-Hui He, *Guangzhou*
Jian Hu, *Harbin*
Xi-Tai Huang, *Tianjin*
Huang-Xian Ju, *Nanjing*
Ren Lai, *Kunming*
Li Liu, *Xi'an*
Xue-Qun Luo, *Guangzhou*
Ai-Guo Ren, *Beijing*
Chiu-Lai Shan, *Hong Kong*
Yuk Him Tam, *Hong Kong*
Jin-Xing Wang, *Jinan*
Jun-Jun Wang, *Beijing*
Long-Jiang Zhang, *Nanjing*
Yi-Hua Zhou, *Nanjing*

Denmark

Jesper Bo Nielsen, *Odense*
Ole D Wolthers, *Randers*

Egypt

Mosaad Abdel-Aziz, *Cairo*
Hesham E Abdel-Hady, *Mansoura*
Mohammed Al-Biltagi, *Tanta*
Mohammad MS Al-Haggar, *Mansoura*
Ashraf MAB Bakr, *Mansoura*
Badr Eldin Mostafa, *Cairo*
Rania Refaat, *Cairo*
Omar Mamdouh Shaaban, *Assiut*
Maysaa El Sayed Zaki, *Mansoura*
Magdy Mohamed Zedan, *Mansoura*

Finland

Bright Ibeabughichi Nwaru, *Tampere*

France

Philippe Georgel, *Strasbourg*
Grill Jacques, *Villejuif*

Manuel Lopez, *Saint Etienne*
Georgios Stamatas, *Issy-les-Moulineaux*
Didier Vieau, *Villeneuve d'Ascq*

Germany

Yeong-Hoon Choi, *Cologne*
Carl Friedrich Classen, *Rostock*
Stephan Immenschuh, *Hannover*
Ales Janda, *Freiburg im Breisgau*

Greece

Michael B Anthracopoulos, *Rion-Patras*
Savas Grigoriadis, *Thessaloniki*
Vasiliki-Maria Iliadou, *Thessaloniki*
Theofilos M Kolettis, *Ioannina*
Ariadne Malamitsi-Puchner, *Athens*
Dimitrios Papandreou, *Thessaloniki*
Kostas N Priftis, *Athens*
Ioannis Michael Vlastos, *Heraklion*

India

Amit Agrawal, *Ambala*
Sameer Bakhshi, *New Delhi*
Atmaram H Bandivdekar, *Mumbai*
Sandeep Bansal, *Chandigarh*
Sriparna Basu, *Varanasi*
Ashu Seith Bhalla, *New Delhi*
Sushil Kumar Kabra, *New Delhi*
Praveen Kumar, *New Delhi*
Kaushal Kishor Prasad, *Chandigarh*
Yogesh Kumar Sarin, *New Delhi*
Kushaljit Singh Sodhi, *Chandigarh*
Raveenthiran V Venkatachalam, *Tamilnadu*
B Viswanatha, *Bangalore*
Syed Ahmed Zaki, *Mumbai*

Iran

Mehdi Bakhshaee, *Mashhad*
Maria Cheraghi, *Ahvaz*
Mehran Karimi, *Shiraz*
Samileh Noorbakhsh, *Tehran*
Firoozeh Sajedi, *Tehran*

Israel

Shraga Aviner, *Ashkelon*
Aviva Fattal-Valevski, *Ramat Aviv*
Rafael Gorodischer, *Omer*
Gil Klinger, *Petah Tikva*
Asher Ornoy, *Jerusalem*
Giora Pillar, *Haifa*
Yehuda Shoenfeld, *Tel-Hashomer*

Italy

Roberto Antonucci, *Cagliari*
CarloV Bellieni, *Siena*
Silvana Cicala, *Naples*
Sandro Contini, *Parma*
Enrico Stefano Corazziari, *Rome*
Vincenzo Cuomo, *Rome*
Vassilios Fanos, *Cagliari*
Filippo Festini, *Florence*
Irene Figa-Talamanca, *Rome*
Dario Galante, *Foggia*
Fabio Grizzi, *Milan*
Alessandro Inserra, *Rome*
Achille Iolascon, *Naples*
Cantinotti Massimiliano, *Pietrsanta*
Ornella Milanesi, *Padova*
Giovanni Nigro, *L'Aquila*
Giuseppe Rizzo, *Rome*
Claudio Romano, *Messina*
Mario Santinami, *Milano*
Gianluca Terrin, *Rome*
Alberto Tommasini, *Trieste*
Giovanni Vento, *Rome*

Japan

Ryo Aeba, *Tokyo*
Kazunari Kaneko, *Osaka*
Hideaki Senzaki, *Saitama*
Kohichiro Tsuji, *Tokyo*
Toru Watanabe, *Niigata*
Takayuki Yamamoto, *Yokkaichi*

Mexico

Fernando Guerrero-Romero, *Durango*
Mara Medeiros, *Mexico*

Netherlands

Jacobus Burggraaf, *Leiden*
Paul Eduard Sijens, *Groningen*

New Zealand

Simon James Thornley, *Auckland*

Nigeria

Akeem Olawale Lasisi, *Ibadan*
Tinuade Adetutu Ogunlesi, *Sagamu*
Joseph Ubini Ese Onakewhor, *Benin*

Norway

Lars T Fadnes, *Bergen*

Pakistan

Niloufer Sultan Ali, *Karachi*
Shakila Zaman, *Lahore*

Poland

Piotr Czauderna, *Gdansk*
Joseph Prandota, *Wroclaw*

Portugal

Alexandre M Carmo, *Porto*

Russia

Perepelitsa S Alexandrovna, *Kaliningrad*
Vorsanova Svetlana, *Moscow*

Saudi Arabia

Naser Labib Rezk, *Riyadh*
Amna Rehana Siddiqui, *Riyadh*

Serbia

Bjelakovic Borisav Bojko, *Nis*
Mirela Erić, *Novi Sad*

Singapore

Quak Seng Hock, *Singapore*
Anselm CW Lee, *Singapore*
Alvin Soon Tiong Lim, *Singapore*

Slovenia

Rok Orel, *Ljubljana*

South Africa

David Kenneth Stones, *Free State*
Eric Oghenerioborue Udjo, *Pretoria*

South Korea

Byung-Ho Choe, *Daegu*
Dong-Hee Lee, *Seoul*

Spain

Pilar Codoñer-Franch, *Valencia*
Claudio Golffier, *Barcelona*
Pablo Menendez, *Andalucía*
Juan F Martínez-Lage Sánchez, *Murcia*
Juan Antonio Tovar, *Madrid*

Sweden

Moustapha Hassan, *Stockholm*
Maria Christina Jenmalm, *Linköping*
Sandra Kleinau, *Uppsala*
Birgitta Lindberg, *Luleå*

Switzerland

Ulf Kessler, *Bern*

Thailand

Surasak Sangkhathat, *Hat Yai*
Viroj Wiwanitkit, *Bangkok*

Tunisia

John C Anyanwu, *Tunis Belvedere*

Turkey

Sinem Akgül, *Ankara*
Ayse Tuba Altug, *Ankara*
Suna Asilsoy, *Seyhan-Adana*
Ozgu Aydogdu, *Izmir*
Kadir Babaoglu, *Kocaeli*
Aksoy Berna, *Kocaeli*
Murat Biteker, *Istanbul*
Merih Çetinkaya, *Istanbul*
Aynur Emine Cicekcibasi, *Konya*
Elvan Caglar Citak, *Mersin*
Cem Dane, *Istanbul*
Mintaze Kerem Günel, *Ankara*
Ahmet Güzel, *Samsun*
Salih Kavukcu, *Izmir*
Fethullah Kenar, *Denizli*
Selim Kurtoglu, *Kayseri*
Turker Ozyigit, *Istanbul*
Yalçın Tüzün, *Istanbul*

United Arab Emirates

Iradj Amirlak, *Al Ain*

United Kingdom

Keith Collard, *Plymouth*
ASahib El-Radhi, *London*
Edzard Ernst, *Exeter*
Mohammad K Hajihosseini, *Norwich*
Tain-Yen Hsia, *London*
Claudio Nicoletti, *Norwich*
Cordula Margaret Stover, *Leicester*
Alastair Gordon Sutcliffe, *London*
Adrian Graham Thomas, *Manchester*
Richard Trompeter, *London*
Petros V Vlastarakos, *Stevenage*

United States

Stephen C Aronoff, *Philadelphia*
Hossam M Ashour, *Detroit*
Paul Ashwood, *Sacramento*
David C Bellinger, *Boston*
Vineet Bhandari, *New Haven*
FR Breijo-Marquez, *Boston*
Itzhak Brook, *Washington*
Patrick D Brophy, *Iowa*
Lavjay Butani, *Sacramento*
Archana Chatterjee, *Omaha*
Lisa M Cleveland, *San Antonio*
Shri R Deshpande, *Atlanta*
Michael Morgan Dowling, *Dallas*
Abdulrahman M El-Sayed, *New York*
Donald N Forthal, *Irvine*
Gregory Kane Friedman, *Birmingham*
Kenneth William Gow, *Seattle*
Dorothy I Bulas, *Washington*
Christopher L Coe, *Madison*
Elias Jabbour, *Houston*
Michael Van Doren Johnston, *Baltimore*
Ram V Kalpatthi, *Gainesville*
Stephen S Kim, *Annandale*
Edward Yungjae Lee, *Annandale*
Jing Lin, *New York*
Jorge Lopez, *Gainesville*
Aurelia Meloni-Ehrig, *Gainesville*
Murielle Mimeault, *Omaha*
Natan Noviski, *Omaha*
Michael David Seckeler, *Charlottesville*
Chetan Chandulal Shah, *Little Rock*
Mohamed Tarek M Shata, *Cincinnati*
Tsz-Yin So, *Greensboro*
Dennis Charles Stevens, *Sioux Falls*
Ru-Jeng Teng, *Milwaukee*
Rajan Wadhawan, *St Petersburg*
Hongjun Wang, *St Charleston*
Marie Wang, *Menlo Park*
Richard Wang, *Atlanta*
Wladimir Wertelecki, *Annandale*
Shu Wu, *Miami*
Fadi Xu, *Albuquerque*

WJCP World Journal of Clinical Pediatrics

Contents

Quarterly Volume 4 Number 3 August 8, 2015

EDITORAL

35 Limited brain magnetic resonance imaging for evaluation of non-traumatic pediatric head emergencies
Shah CC, Parikh AK

38 Blunted perception of dyspnea in asthmatic children: A potential misleading criterion
Douros K, Boutopoulou B, Priftis KN

41 Prevention of neural tube defects with folic acid: The Chinese experience
Ren AG

ORIGINAL ARTICLE

Observational Study

45 Response of levetiracetam in neonatal seizures
Yau MLY, Fung ELW, Ng PC

World Journal of Clinical Pediatrics
Volume 4 Number 3 August 8, 2015

Contents

ABOUT COVER Editorial Board Member of *World Journal of Clinical Pediatrics*, Fabio Grizzi, PhD, Laboratory of Molecular Gastroenterology, IRCCS Istituto Clinico Humanitas, Via Manzoni 56, 20089 Rozzano, Milan, Italy

AIM AND SCOPE *World Journal of Clinical Pediatrics* (*World J Clin Pediatr*, *WJCP*, online ISSN 2219-2808, DOI: 10.5409) is a peer-reviewed open access academic journal that aims to guide clinical practice and improve diagnostic and therapeutic skills of clinicians.

WJCP covers a variety of clinical medical topics, including fetal diseases, inborn, newborn diseases, infant diseases, genetic diseases, diagnostic imaging, endoscopy, and evidence-based medicine and epidemiology. Priority publication will be given to articles concerning diagnosis and treatment of pediatric diseases. The following aspects are covered: Clinical diagnosis, laboratory diagnosis, differential diagnosis, imaging tests, pathological diagnosis, molecular biological diagnosis, immunological diagnosis, genetic diagnosis, functional diagnostics, and physical diagnosis; and comprehensive therapy, drug therapy, surgical therapy, interventional treatment, minimally invasive therapy, and robot-assisted therapy.

We encourage authors to submit their manuscripts to *WJCP*. We will give priority to manuscripts that are supported by major national and international foundations and those that are of great clinical significance.

INDEXING/ABSTRACTING *World Journal of Clinical Pediatrics* is now indexed in PubMed Central, PubMed and Digital Object Identifier.

FLYLEAF I-III Editorial Board

EDITORS FOR THIS ISSUE

Responsible Assistant Editor: *Xiang Li*
Responsible Electronic Editor: *Su-Qing Liu*
Proofing Editor-in-Chief: *Lian-Sheng Ma*
Responsible Science Editor: *Yue-Li Tian*
Proofing Editorial Office Director: *Xiu-Xia Song*

NAME OF JOURNAL
World Journal of Clinical Pediatrics

ISSN
ISSN 2219-2808 (online)

LAUNCH DATE
June 8, 2012

FREQUENCY
Quarterly

EDITOR-IN-CHIEF
Eduardo H Garin, MD, Professor, Department of Pediatrics, University of Florida, 1600 SW Archer Road. HD214, Gainesville, FL 32610, United States

EDITORIAL OFFICE
Jin-Lei Wang, Director
Xiu-Xia Song, Vice Director
World Journal of Clinical Pediatrics
Room 903, Building D, Ocean International Center, No. 62 Dongsihuan Zhonglu, Chaoyang District, Beijing 100025, China
Telephone: +86-10-85381891
Fax: +86-10-85381893
E-mail: editorialoffice@wjgnet.com
Help Desk: http://www.wjgnet.com/esps/helpdesk.aspx
http://www.wjgnet.com

PUBLISHER
Baishideng Publishing Group Inc
8226 Regency Drive,
Pleasanton, CA 94588, USA
Telephone: +1-925-223-8242
Fax: +1-925-223-8243
E-mail: bpgoffice@wjgnet.com
Help Desk: http://www.wjgnet.com/esps/helpdesk.aspx
http://www.wjgnet.com

PUBLICATION DATE
August 8, 2015

COPYRIGHT
© 2015 Baishideng Publishing Group Inc. Articles published by this Open-Access journal are distributed under the terms of the Creative Commons Attribution Non-commercial License, which permits use, distribution, and reproduction in any medium, provided the original work is properly cited, the use is non commercial and is otherwise in compliance with the license.

SPECIAL STATEMENT
All articles published in journals owned by the Baishideng Publishing Group (BPG) represent the views and opinions of their authors, and not the views, opinions or policies of the BPG, except where otherwise explicitly indicated.

INSTRUCTIONS TO AUTHORS
Full instructions are available online at http://www.wjgnet.com/2219-2808/g_info_20100722180909.htm.

ONLINE SUBMISSION
http://www.wjgnet.com/esps/

World Journal of Clinical Pediatrics

Submit a Manuscript: http://www.wjgnet.com/esps/
Help Desk: http://www.wjgnet.com/esps/helpdesk.aspx
DOI: 10.5409/wjcp.v4.i3.35

World J Clin Pediatr 2015 August 8; 4(3): 35-37
ISSN 2219-2808 (online)
© 2015 Baishideng Publishing Group Inc. All rights reserved.

EDITORIAL

Limited brain magnetic resonance imaging for evaluation of non-traumatic pediatric head emergencies

Chetan Chandulal Shah, Ashishkumar K Parikh

Chetan Chandulal Shah, Ashishkumar K Parikh, Mayo Clinic, Jacksonville, FL 32207, United States

Chetan Chandulal Shah, Wolfson Children Hospital, Jacksonville, FL 32207, United States

Author contributions: Shah CC created the outline of the article and final edits; Parikh AK did the literature search and initial draft of the article.

Conflict-of-interest statement: Authors have no conflict of interests including but not limited to commercial, personal, political, intellectual, or religious interests.

Open-Access: This article is an open-access article which was selected by an in-house editor and fully peer-reviewed by external reviewers. It is distributed in accordance with the Creative Commons Attribution Non Commercial (CC BY-NC 4.0) license, which permits others to distribute, remix, adapt, build upon this work non-commercially, and license their derivative works on different terms, provided the original work is properly cited and the use is non-commercial. See: http://creativecommons.org/licenses/by-nc/4.0/

Correspondence to: Dr. Chetan Chandulal Shah, MD, MBA, Wolfson Children Hospital, 807 Children's Way, Jacksonville, FL 32207, United States. chetan99@hotmail.com
Telephone: +1-904-2028681
Fax: +1-904-2028144

Received: January 28, 2015
Peer-review started: January 31, 2015
First decision: March 6, 2015
Revised: April 1, 2015
Accepted: May 7, 2015
Article in press: May 8, 2015
Published online: August 8, 2015

Abstract

Limited brain magnetic resonance imaging (MRI) consisting of axial fluid attenuated inversion recovery, axial diffusion weighted imaging, coronal single shot fast spin echo (SSFSE) and sagittal SSFSE can be performed in under 5 min of scan time. This approach may provide more information than a non-contrast head computed tomography (CT) in non-traumatic pediatric head emergency, avoid ionizing radiation from CT scan and stratify patients who need more detailed brain MRI. Research studies are required to provide evidence for feasibility of such an approach.

Key words: Magnetic resonance imaging; Head; Brain; Pediatric head emergency; Computed tomography; Pediatric; Emergency

© The Author(s) 2015. Published by Baishideng Publishing Group Inc. All rights reserved.

Core tip: Limited brain magnetic resonance imaging (MRI) consisting of axial fluid attenuated inversion recovery, axial diffusion weighted imaging, coronal single shot fast spin echo (SSFSE) and sagittal SSFSE can be performed in under 5 min of scan time. This approach may provide more information than a non-contrast head computed tomography (CT) in non-traumatic pediatric head emergency, avoid ionizing radiation from CT scan and stratify patients who need more detailed brain MRI. Research studies are required to provide evidence for feasibility of such an approach.

Shah CC, Parikh AK. Limited brain magnetic resonance imaging for evaluation of non-traumatic pediatric head emergencies. *World J Clin Pediatr* 2015; 4(3): 35-37 Available from: URL: http://www.wjgnet.com/2219-2808/full/v4/i3/35.htm DOI: http://dx.doi.org/10.5409/wjcp.v4.i3.35

CURRENT SITUATION

Multitude of various indications exists for non-traumatic head imaging in the emergency department among children, most common of which is headache. Other

common indications include seizures, syncope, ataxia, or a focal neurologic deficit. For many of these reasons, a non-contrast head computed tomography (CT) is often performed. While quite useful in eliminating or diagnosing life-threatening conditions, if negative, CT will not be helpful in providing a specific diagnosis. In contrast, a limited brain magnetic resonance imaging (MRI) may be more efficient, cost-effective, diagnostic and safer alternative to non-contrast head CT in non-traumatic pediatric head emergencies.

Huda *et al*[1] estimated the organ-absorbed dose in head CT ranges from 30 mGy in neonates to 40 mGy in adults. More importantly, the effective dose for a head CT in a neonate was approximately four times higher than in an adult (0.9 mSv).

Pearce *et al*[2] found a correlation between head CT scans and an increased risk, albeit small, for the development of leukemia and brain tumors. In concert with the ALARA principle, it is now ever more prudent to attempt to limit the use of ionizing radiation and if possible, eliminate it altogether.

CHANGING SCENARIO

Previously, accessibility and efficiency have always been touted as being reasons for performing a head CT versus a MRI. However, newer MRI technologies have developed which allow for faster image acquisition. More institutions now employ more MRI scanners running on an around the clock basis allowing for more availability in performing urgent/stat exams.

Even though MRI examinations are faster than they ever have been, they cannot currently match the speed of CT. Because of this, sedation or general anesthesia is often employed in children to obtain quality MRI examinations. In our institution, sedation or general anesthesia is typically given to children after the first few months of life to age 6-8 years. A feed and sleep technique is typically employed for infants under 1 mo of age with a swaddling and sleep method used for infants under 6 mo. Between the ages of 6-8 years, programs that recreate the MR examination in a mock setting can be used to decrease the requirement of sedation/general anesthesia during the actual exam. Children older than 8 years of age are typically able to cooperate and hold still during the MR examination and thus do not require sedation/general anesthesia.

SUGGESTED APPROACH

Limited brain MRI of the head may prove superior to CT in eliminating life-threatening conditions and targeting children who would benefit from a more detailed MRI evaluation. The limited brain MRI that we suggest may consist of axial fluid attenuated inversion recovery (FLAIR) sequence, axial diffusion weighted imaging (DWI) sequence and T2-weighted images using single shot fast spin echo (SSFSE) pulse sequence images in the coronal and sagittal planes. Total MRI scan time would be around 5 min.

Hemorrhage, infarction, hydrocephalus and a large tumor would easily be diagnosed *via* limited brain MR examinations. Such a finding may require a complete detailed MRI. A normal limited brain MRI would not need further imaging, particularly for a common indication such as a headache.

POSSIBLE HURDLES

However, there are few hurdles with a limited brain MR approach to emergent ED head imaging. While accessibility to MR exams is better than ever before, it lags considerably behind CT. This difference is immense among community and rural based hospitals. Further, even if the MR equipment is available, the trained staff available to manage and operate the scanners is very limited, especially after regular working hours.

RECOMMENDATIONS

A retrospective study is required for preliminary evaluation. Such a retrospective study would look at only FLAIR, DWI and T2 sequences of brain MRI done through referral from pediatric emergency. The study design would blind the radiologist from patient identifier and MRI report. Only these few sequences would be provided for review. The blinded researcher report would be then compared with the MRI report generated at the time of examination. Number of cases where clinically important findings would have been missed by this approach would be determined. List of insignificant and significant findings that might have been missed would be generated; If the outcome of the retrospective study suggested above provides support to this suggested approach, similar retrospective studies from multiple centers would be needed; If such multiple retrospective studies provide enough evidence to promote this suggested approach, prospective study will be needed; Cross training CT and MRI technologist may increase the availability of MRI personnel after regular working hours; A separate limited billing code would be required to bill such limited MRI study. Cost of such limited brain MRI without contrast would be comparable to or slightly more than a non-contrast head CT.

CONCLUSION

Limited brain MRI consisting of axial FLAIR, axial DWI, coronal SSFSE and sagittal SSFSE can be performed in under 5 min of scan time. This approach may provide more information than a non-contrast head CT in non-traumatic pediatric head emergency, avoid ionizing radiation from CT scan and stratify patients who need more detailed brain MRI. Research studies suggested above may help provide evidence for feasibility of such an approach.

REFERENCES

1 **Huda W**, Vance A. Patient radiation doses from adult and pediatric CT. *AJR Am J Roentgenol* 2007; **188**: 540-546 [PMID: 17242266]

2 **Pearce MS**, Salotti JA, Little MP, McHugh K, Lee C, Kim KP, Howe NL, Ronckers CM, Rajaraman P, Sir Craft AW, Parker L, Berrington de González A. Radiation exposure from CT scans in childhood and subsequent risk of leukaemia and brain tumours: a retrospective cohort study. *Lancet* 2012; **380**: 499-505 [PMID: 22681860 DOI: 10.1016/S0140-6736(12)60815-0]

P- Reviewer: Gonzalez-Granado LI, Saburi A **S- Editor**: Ji FF
L- Editor: A **E- Editor**: Liu SQ

World Journal of Clinical Pediatrics

Submit a Manuscript: http://www.wjgnet.com/esps/
Help Desk: http://www.wjgnet.com/esps/helpdesk.aspx
DOI: 10.5409/wjcp.v4.i3.38

World J Clin Pediatr 2015 August 8; 4(3): 38-40
ISSN 2219-2808 (online)
© 2015 Baishideng Publishing Group Inc. All rights reserved.

EDITORIAL

Blunted perception of dyspnea in asthmatic children: A potential misleading criterion

Konstantinos Douros, Barbara Boutopoulou, Kostas N Priftis

Konstantinos Douros, Barbara Boutopoulou, Kostas N Priftis, 3rd Department of Pediatrics, "Attikon" Hospital, University of Athens School of Medicine, 12462 Athens, Greece

Author contributions: All authors contributed to this work.

Conflict-of-interest statement: The authors declare no conflicts of interest.

Open-Access: This article is an open-access article which was selected by an in-house editor and fully peer-reviewed by external reviewers. It is distributed in accordance with the Creative Commons Attribution Non Commercial (CC BY-NC 4.0) license, which permits others to distribute, remix, adapt, build upon this work non-commercially, and license their derivative works on different terms, provided the original work is properly cited and the use is non-commercial. See: http://creativecommons.org/licenses/by-nc/4.0/

Correspondence to: Kostas N Priftis, Assistant Professor, 3rd Department of Pediatrics, "Attikon" Hospital, University of Athens School of Medicine, 1 Rimini Str, 12462 Athens, Greece. kpriftis@otenet.gr
Telephone: +30-210-5831299
Fax: +30-210-5832229

Received: March 23, 2015
Peer-review started: March 25, 2015
First decision: April 10, 2015
Revised: May 2, 2015
Accepted: June 15, 2015
Article in press: June 16, 2015
Published online: August 8, 2015

Abstract

Dyspnea (or breathlessness) is a symptom describing a perceived experience of breathing discomfort. Children's awareness of dyspnea is variable and there is only a poor correlation between the objective respiratory distress measurements and the subjectively awareness of dyspnea. Those who do not perceive dyspnea may not be motivated to comply with their daily prophylactic treatment. Since dyspnea is the main symptom of asthma, and disease management is based largely on the description of symptoms between clinic visits, unreliable symptom report may mislead decision-making for long-term treatment of asthma. Thus, therapeutic decisions should not be taken solely on patients' perception and description of dyspnea.

Key words: Breathlessness; Respiratory distress; Tachypnea; Asthma; Symptom

© The Author(s) 2015. Published by Baishideng Publishing Group Inc. All rights reserved.

Core tip: Children's awareness of dyspnea is variable and there is only a poor correlation between the objective respiratory distress measurements and the subjectively awareness of dyspnea. Children with asthma vary in their perception of dyspnea for the same degree of bronchoconstriction. Therapeutic decisions should not be taken solely on patients' perception and description of dyspnea.

Douros K, Boutopoulou B, Priftis KN. Blunted perception of dyspnea in asthmatic children: A potential misleading criterion. *World J Clin Pediatr* 2015; 4(3): 38-40 Available from: URL: http://www.wjgnet.com/2219-2808/full/v4/i3/38.htm DOI: http://dx.doi.org/10.5409/wjcp.v4.i3.38

INTRODUCTION

Dyspnea (or breathlessness) is a symptom describing a perceived experience of breathing discomfort and is considered a warning sign to a critical threat to homeostasis. It urges to adaptive responses intended to minimize the work of breathing, such as resting or taking the necessary medicines[1]. Since dyspnea is a subjectively perceived abnormal sensation it is quite distinct from the objective signs of respiratory

distress, such as tachypnea, retractions and use of accessory muscles. Dyspnea is a common symptom of cardiopulmonary disorders. However, its intensity is not related solely to the severity of the underlying disease but it is also affected from psychological factors[2]. In particular, anxiety in asthmatic children is positively associated with symptom perception during times when children's asthma is mild[3]. In addition, dyspnea may also occur in healthy individuals, *e.g.*, during intense emotional states and heavy labor or exercise[4].

Our knowledge on the pathophysiological pathways underlying dyspnea still remains incomplete. Specific dyspnea receptors have not been found so far and, since a clear beginning of the nervous sensory transduction pathway is missing, it is not yet feasible to clarify the neurophysiology of dyspnea and depict it as a well-defined model, such as the ones that exist for vision, hearing, or pain. However, the general principle of peripheral sensory information from the respiratory system, traveling through an intact afferent pathway and triggering regions of the cerebral cortex to produce the perception of dyspnea, does seem to exist.

DYSPNEA PERCEPTION AND LUNG FUNCTION IN ASTHMATIC CHILDREN

Despite the number of methods that have been developed in order to have accurate quantitative estimates of the degree of dyspnea and reproducible follow-up of patients, the incorporation of a real life method in everyday clinical practice still remains elusive. Among the plenitude of invented dyspnea scales, the most commonly encountered in medical literature, is the Borg scale and its modifications[5]. The majority of dyspnea scales have been extensively used and studied in adults. However, their applicability is often questionable and, simplicity is always prerequisite in order to be used in children. Such scales can be used only on the assumption that the child's ability to organize objects in order - something that it is generally achieved after the age of 7 years - has reached an operational stage[6].

But is the perception of dyspnea so critical as to affect clinical management and outcomes of asthmatic children? Male *et al*[7] tried to investigate the relation of poor perception of breathlessness with severe asthma attacks in children. They retrospectively studied 27 children admitted to hospital with asthma exacerbation all of whom had recordings of breathlessness scores as well as oxygen saturation, clinical score, and FEV_1, at 5, 10, 24, 48, and 72 h after admission. They found that the more severely affected (hypoxic) children had a trend towards feeling less breathless at admission. These children also experienced a smaller decrease in dyspnea score for a similar improvement in FEV_1, than children presenting without hypoxia. van Gent *et al*[8] in a cross sectional study, measured dyspnea in two groups of "diagnosed" and "undiagnosed" asthmatic children. Subjects in the first group were already diagnosed with asthma, whereas in the second group asthma was actually diagnosed during the recruitment phase of the study. All children underwent hypertonic saline testing for bronchial hyperresponsiveness. The authors observed that children with "undiagnosed" asthma had worse perception of dyspnea than children with "diagnosed" asthma. Nuijsink *et al*[9] studied the perception of bronchoconstriction during methacholine bronchoprovocation challenge in children with moderately severe atopic asthma. They demonstrated that the more severe the airway hyperreactivity, the less likely it was for patients to perceive bronchoconstriction. They also observed that children having low baseline FEV_1 values tended to use less beta-agonist bronchodilator as a "rescue medication". Panditi *et al*[10] measured the perception of dyspnea in asthmatic children during exercise challenge testing on treadmill. There was only a weak relation of the children's reported dyspnea measurements following the exercise test with the change in FEV_1 before and after the challenge. Approximately half of the children had a repeat challenge a few weeks later in which the discrepancies from the first visit were so great that no relation could be established between the changes in dyspnea and the spirometric indices between visits. They further compared parents' independent perception of their children's dyspnea with the dyspnea perceived from the children themselves. Parents' perception of their child's dyspnea was not related to any of the lung function measurements.

What the above studies add to our knowledge regarding children's perception of dyspnea? Children's awareness of dyspnea is variable and there is only a poor correlation between the objective respiratory distress measurements and the subjectively awareness of dyspnea. Children with asthma vary in their perception of dyspnea for the same degree of bronchoconstriction. In general, children, especially those with undiagnosed asthma, may become tolerant to a certain degree of bronchoconstriction mainly because of adaptation related to frequent bronchoconstriction[11]. Despite the absence of direct evidence proving correlation between poor perception of dyspnea with either severe persistent asthma or history of severe asthma attacks, the blunted sensation of dyspnea in many children may result in delayed diagnosis and/or under-treatment of the disease, and so puts them at risk of severe and even life threatening asthma attacks. Those who do not perceive dyspnea may not be motivated to comply with their daily prophylactic treatment. Children who underestimate their symptoms tend to seek medical help only at a late stage of their exacerbations. Moreover, poor perception contributes to the considerable number of children without proper diagnosis despite suffering from asthma. In this case, the absence of prophylactic treatment combined with poor alertness may result in the first clear presentation of their disease being a severe and possibly life threatening acute attack[12]. Parents and caregivers appear to be even less accurate in detecting their child's

symptoms.

CONCLUSION

Since dyspnea is the main symptom of asthma, and disease management is based largely on the description of symptoms between clinic visits, unreliable symptom report may mislead decision-making for long-term treatment of asthma. Thus, therapeutic decisions should not be taken solely on patients' perception and description of dyspnea.

REFERENCES

1 **Parshall MB**, Schwartzstein RM, Adams L, Banzett RB, Manning HL, Bourbeau J, Calverley PM, Gift AG, Harver A, Lareau SC, Mahler DA, Meek PM, O'Donnell DE. An official American Thoracic Society statement: update on the mechanisms, assessment, and management of dyspnea. *Am J Respir Crit Care Med* 2012; **185**: 435-452 [PMID: 22336677 DOI: 10.1164/rccm.201111-2042ST]

2 **De Peuter S**, Van Diest I, Lemaigre V, Verleden G, Demedts M, Van den Bergh O. Dyspnea: the role of psychological processes. *Clin Psychol Rev* 2004; **24**: 557-581 [PMID: 15325745 DOI: 10.1016/j.cpr.2004.05.001]

3 **Chen E**, Hermann C, Rodgers D, Oliver-Welker T, Strunk RC. Symptom perception in childhood asthma: the role of anxiety and asthma severity. *Health Psychol* 2006; **25**: 389-395 [PMID: 16719611 DOI: 10.1037/0278-6133.25.3.389]

4 **Rietveld S**, Everaerd W, van Beest I. Excessive breathlessness through emotional imagery in asthma. *Behav Res Ther* 2000; **38**: 1005-1014 [PMID: 11004739 DOI: 10.1016/S0005-7967(99)00134-5]

5 **Borg G**. Perceived exertion as an indicator of somatic stress. *Scand J Rehabil Med* 1970; **2**: 92-98 [PMID: 5523831]

6 **Pianosi PT**, Huebner M, Zhang Z, McGrath PJ. Dalhousie Dyspnea and perceived exertion scales: psychophysical properties in children and adolescents. *Respir Physiol Neurobiol* 2014; **199**: 34-40 [PMID: 24793132 DOI: 10.1016/j.resp.2014.04.003]

7 **Male I**, Richter H, Seddon P. Children's perception of breathlessness in acute asthma. *Arch Dis Child* 2000; **83**: 325-329 [PMID: 10999869 DOI: 10.1136/adc.83.4.325]

8 **van Gent R**, van Essen-Zandvliet LE, Rovers MM, Kimpen JL, de Meer G, van der Ent CK. Poor perception of dyspnoea in children with undiagnosed asthma. *Eur Respir J* 2007; **30**: 887-891 [PMID: 17652315 DOI: 10.1183/09031936.00031407]

9 **Nuijsink M**, Hop WC, Jongste JC, Sterk PJ, Duiverman AE. Perception of bronchoconstriction: a complementary disease marker in children with asthma. *J Asthma* 2013; **50**: 560-564 [PMID: 23672570 DOI: 10.3109/02770903.2013.792347]

10 **Panditi S**, Silverman M. Perception of exercise induced asthma by children and their parents. *Arch Dis Child* 2003; **88**: 807-811 [PMID: 12937106 DOI: 10.1136/adc.88.9.807]

11 **Burdon JG**, Juniper EF, Killian KJ, Hargreave FE, Campbell EJ. The perception of breathlessness in asthma. *Am Rev Respir Dis* 1982; **126**: 825-828 [PMID: 7149447]

12 **Douros K**, Boutopoulou B, Papadopoulos M, Fouzas S. Perception of dyspnea in children with asthma. *Front Biosci* (Elite Ed) 2015; **7**: 469-477 [PMID: 25961425]

P- Reviewer: Kolettis TM, Sijens PE, Teng RJ
S- Editor: Tian YL **L- Editor**: A **E- Editor**: Liu SQ

World Journal of Clinical Pediatrics

Submit a Manuscript: http://www.wjgnet.com/esps/
Help Desk: http://www.wjgnet.com/esps/helpdesk.aspx
DOI: 10.5409/wjcp.v4.i3.41

World J Clin Pediatr 2015 August 8; 4(3): 41-44
ISSN 2219-2808 (online)
© 2015 Baishideng Publishing Group Inc. All rights reserved.

EDITORIAL

Prevention of neural tube defects with folic acid: The Chinese experience

Ai-Guo Ren

Ai-Guo Ren, Institute of Reproductive and Child Health and Ministry of Health Key Laboratory of Reproductive Health, Peking University, Beijing 100191, China

Author contributions: Ren AG solely contributed to this work.

Conflict-of-interest statement: The author declares no competing financial or no-financial conflict of interests.

Open-Access: This article is an open-access article which was selected by an in-house editor and fully peer-reviewed by external reviewers. It is distributed in accordance with the Creative Commons Attribution Non Commercial (CC BY-NC 4.0) license, which permits others to distribute, remix, adapt, build upon this work non-commercially, and license their derivative works on different terms, provided the original work is properly cited and the use is non-commercial. See: http://creativecommons.org/licenses/by-nc/4.0/

Correspondence to: Ai-Guo Ren, MD, PhD, Institute of Reproductive and Child Health and Ministry of Health Key Laboratory of Reproductive Health, Peking University, 38 College Road, Haidian District, Beijing 100191, China. renag@bjmu.edu.cn
Telephone: +86-10-82801140
Fax: +86-10-82801141

Received: March 25, 2015
Peer-review started: March 31, 2015
First decision: May 13, 2015
Revised: May 21, 2015
Accepted: June 18, 2015
Article in press: June 19, 2015
Published online: August 8, 2015

Abstract

Neural tube defects (NTDs) are a group of congenital malformations of the central nervous system that are caused by the closure failure of the embryonic neural tube by the 28th day of conception. Anencephaly and spina bifida are the two major subtypes. Fetuses with anencephaly are often stillborn or electively aborted due to prenatal diagnosis, or they die shortly after birth. Most infants with spina bifida are live-born and, with proper surgical treatment, can survive into adulthood. However, these children often have life-long physical disabilities. China has one of the highest prevalence of NTDs in the world. Inadequate dietary folate intake is believed to be the main cause of the cluster. Unlike many other countries that use staple fortification with folic acid as the public health strategy to prevent NTDs, the Chinese government provides all women who have a rural household registration and who plan to become pregnant with folic acid supplements, free of charge, through a nation-wide program started in 2009. Two to three years after the initiation of the program, the folic acid supplementation rate increased to 85% in the areas of the highest NTD prevalence. The mean plasma folate level of women during early and mid-pregnancy doubled the level before the program was introduced. However, most women began taking folic acid supplements when they knew that they were pregnant. This is too late for the protection of the embryonic neural tube. In a post-program survey of the women who reported folic acid supplementation, less than a quarter of the women began taking supplements prior to pregnancy, indicating that the remaining three quarters of the fetuses remained unprotected during the time of neural tube formation. Therefore, staple food fortification with folic acid should be considered as a priority in the prevention of NTDs.

Key words: Neural tube defects; Folic acid; Folate; Supplementation; Fortification

© The Author(s) 2015. Published by Baishideng Publishing Group Inc. All rights reserved.

Core tip: Neural tube defects are severe congenital malformations of the central nervous system. The prevalence of these defects in China is among the highest in the world. Low intake of dietary folate is to be blamed. The provision of free-of-charge folic

acid supplements to all women who live in rural areas and plan to become pregnant has been implemented since 2009. However, fortification of staple foods with folic acid has not been planned. It is time to consider fortification since many pregnancies are unplanned and therefore it is difficult for a woman to take folic acid supplements from before pregnancy.

Ren AG. Prevention of neural tube defects with folic acid: The Chinese experience. *World J Clin Pediatr* 2015; 4(3): 41-44 Available from: URL: http://www.wjgnet.com/2219-2808/full/v4/i3/41.htm DOI: http://dx.doi.org/10.5409/wjcp.v4.i3.41

EMBRYONIC AND CLINICAL FEATURES OF NEURAL TUBE DEFECTS

Neural tube defects (NTDs) are a group of congenital malformations of the central nervous system that are caused by the failure of the embryonic neural tube to close by the 28th day of conception[1,2]. Anencephaly and spina bifida are the two major subtypes of NTDs. A closure failure that occurs in the cranial region of the neural tube leads to anencephaly, which is characterized by the absence of the cranial vault and absent or markedly reduced cerebral hemispheres. Fetuses with anencephaly are often stillborn or electively aborted due to prenatal diagnosis, or they die shortly after birth. A closure defect occurring in the caudal region of the neural tube is referred to as spina bifida or meningomyelocele. This condition is characterized by bony defects in the spine through which the meninges and/or spinal cord tissue protrude to the body surface. Most infants with spina bifida are live-born and, with proper surgical treatment and management, can survive into adulthood. However, these children often have life-long physical disabilities, including leg paralysis, absence of control of urine and bowel, and learning difficulties. In addition, a large proportion of infants with spina bifida are complicated with hydrocephalus, which may lead to intellectual impairment and even premature death.

PREVALENCE OF NTD

NTDs are the second most common birth defect after congenital heart defects. It has been estimated that every year more than 320000 infants are born with NTDs worldwide[3]. However, the prevalence of infants born with NTDs varies widely between countries and also within countries. In China, NTD epidemiology is characterized by a higher prevalence in the North than in the South and a higher prevalence in rural areas than in cities. A nationwide survey conducted in 1986-1987 showed an overall prevalence of 45.5 per 10000 births in the 15 northern provinces, compared with 11.3 per 10000 births in 12 Southern provinces[4]. Of the northern provinces, Shanxi had the highest prevalence, with 68.5 per 10000 births for males and 144 per 10000 births for females. During the same period, the prevalence of NTDs was 6 per 10000 births in the United States[5]. Ireland is well known for its high prevalence of NTDs. East Ireland had a prevalence rate about 23 per 10000 births in 1986-1987[6]. These data indicate that the prevalence of NTDs in Northern China is among the highest in the world. It has been estimated that around 100000 fetuses are affected annually in China. In recent years, the prevalence of NTDs in China has been declining consistently, but no national data are available to clarify how much of this trend is attributable to fewer NTD occurrences or to avoidance through pregnancy termination after prenatal diagnosis. This is because the national birth defects monitoring system includes only pregnancies of 28 wk' gestation or greater, thus not counting any pregnancies that are terminated before 28 wk' gestation. One study showed that more than two-thirds of NTD-affected pregnancies were terminated before 28 wk of gestation in the Shanxi rural population in early 2000s[7]. This proportion is expected to be over 90% in urban populations. Surveillance data from 5 counties in Shanxi Province show that NTD prevalence declined from a peak of 120 per 10000 births in 2004 to 31.5 per 10000 births in 2014 (unpublished data). The latter remains much higher than the current prevalence of NTDs (5-7 per 10000 births) in the United States[8].

DIETARY FOLATE INTAKE AND BLOOD FOLATE LEVELS OF WOMEN OF REPRODUCTIVE AGE

It has long been known that low blood folate during the periconceptional period is associated with an increased risk that a pregnancy will be affected by an NTD[9]. Folate is the natural form of folic acid contained in food and in the body. Folic acid is the synthetic form that is used in supplements and fortified foods. Folate cannot be synthesized in the body and therefore can only be obtained from food. The typical diet of northern China is characterized by low amounts of fresh vegetables and fruits; this results in low blood folate. An investigation among women in Shanxi's rural population who were planning to become pregnant showed that the mean (± SD) and median (interquartile range) daily folate intake values were 114.3 ± 59.7 μg/d and 102.8 (69.3-146.8) μg/d, respectively. Virtually all (99%) of the women had an intake level below 320 μg/d, the estimated average requirement for non-pregnant women, and only 1% and 7% of the women consumed 75% and 50%, respectively, of the recommended daily folate intake of 400 μg for non-pregnant women[10]. As a result of this low dietary folate intake, people living in the North have less than half the blood folate level of people living in the South. During early to mid-pregnancy, women living in the North had plasma and erythrocyte folate concentrations of 12.2 nmol/L and 440.0 nmol/L, respectively, compared to 33.5 nmol/L and 910.4 nmol/L,

respectively, for women living in the south[11]. Low dietary folate intake and low blood folate concentration lead to a high risk of an NTD-affected pregnancy.

NATIONWIDE FOLIC ACID SUPPLEMENTATION PROGRAM

Although folate may be taken in naturally *via* the diet, folate intake from the diet alone cannot meet the needs of pregnant women and their growing fetuses. Folic acid supplements and consumption of folic acid-fortified cereals or staples are two alternatives to increase folate intake. In the late 1980s, a multicenter randomized controlled trial demonstrated that supplementation with 4 mg of daily folic acid during the periconceptional period could reduce the risk of NTD recurrence (*i.e.,* a subsequent NTD baby) by as much as 83%[12]. A later randomized controlled trial conducted in Hungary showed that periconceptional supplementation with an 0.8 mg folic acid-containing multivitamin every day could prevent the first occurrence of NTDs[13]. In the early 1990s, Peking University conducted a large-scale community interventional trial on the prevention of NTDs with folic acid with 247831 women of reproductive age, in collaboration with the Centers for Disease Control and Prevention of the United States. The results confirmed that periconceptional supplementation with only 0.4 mg of folic acid per day can reduce NTD risk by as much as 81%[14]. However, science discoveries are not easy to translate into public health or clinical practice. For example, between 2002 and 2004, only 15% of pregnant women in Shanxi Province reported that they had ever taken folic acid supplements during the periconceptional period, and only one-third of these women took the supplements prior to pregnancy[15]. To tackle this problem, the Chinese government launched a program that provides folic acid supplements, free of charge, to all women with a rural household registration who plan to become pregnant (estimated total number, 8 million) in 2009. The supplements are procured by provincial governments, but paid in total or in part by the central government. Local maternal health care workers are responsible for the distribution of the supplements. In 2011, the perinatal (28 gestational weeks to 4 wk of life) prevalence of NTDs decreased by 22.4% in rural areas compared to that in 2009[16]. In 2011 and 2012, 2 to 3 years after the initiation of the supplementation program, the folic acid supplementation rate had increased to 85% in the areas of highest NTD prevalence[17]. The mean plasma folate concentration of women during early and mid-pregnancy increased to 33.4 nmol/L (range, 18.7-58.4 nmol/L), double the level before the program was introduced[18]. However, the proportion of women who began taking folic acid prior to pregnancy did not increase. In a post-program survey of the women who reported folic acid supplementation, 23.2% had begun taking supplements prior to pregnancy, compared to 27.3% in the pre-program survey in the high NTD prevalence population[17], indicating that many fetuses/embryos remained unprotected during the time of neural tube formation.

STAPLE FORTIFICATION WITH FOLIC ACID

The provision of folic acid supplements can be costly when manpower and the other logistical efforts involved in its distribution are taken into account. It is estimated that the Chinese central government needs 195 million RMB (about United States dollar 31 million) per year for supplement procurement. More important, many pregnancies are unplanned, meaning that supplementation with folic acid prior to pregnancy is impossible. On the other hand, staple fortification can supply folic acid "passively" to all women of reproductive age (and unintentionally to other segments of a population as well). Currently, about 80 countries have adopted or plan to implement staple fortification with folic acid[19]. Reported NTD prevalence has been reduced by 28% in the United States[8], by 46% in Canada[20], and by 50% in Chile[21] since fortification began. However, China has no plan to fortify staple foods in the foreseeable future. Perceived major barriers to the implementation of staple fortification include[22]: (1) a lack of consensus in the scientific community; (2) the absence of a centralized production and distribution system for staples; (3) a lack of public awareness and acceptance; and (4) a lack of political will. The author hopes that these problems can be solved so that fortified flour and/or rice will become commercially available.

ROLE OF PEDIATRICIANS IN THE PREVENTION OF NTD

Since the recent change in China's family planning policy, more women wish to have a second baby. A proportion of these women are in their 30s or even 40s, meaning that they are at an increased risk of conceiving babies with down syndrome. In addition, advanced age is associated with a greater likelihood of obesity and diabetes, which are confirmed risk factors for NTD-affected pregnancies. This is an imminent challenge for the prevention of birth defects, including NTDs. In the battle to combat NTDs, physicians, including pediatricians, can play a critical role in every clinical encounter with women of reproductive age. For women who plan to have a second baby, pediatricians should advise them to take a 0.4-mg folic acid supplement daily beginning 3 mo prior to pregnancy or when there is a chance they may become pregnant. For women with a previous pregnancy affected by NTDs, it is recommended that they take 5 mg of folic acid daily, beginning from 3 mo before a pregnancy is planned. The ultimate goal is to protect each fetus from NTDs, which are preventable with folic acid.

REFERENCES

1 **Botto LD**, Moore CA, Khoury MJ, Erickson JD. Neural-tube defects. *N Engl J Med* 1999; **341**: 1509-1519 [PMID: 10559453 DOI: 10.1056/NEJM199911113412006]

2 **Wallingford JB**, Niswander LA, Shaw GM, Finnell RH. The continuing challenge of understanding, preventing, and treating neural tube defects. *Science* 2013; **339**: 1222002 [PMID: 23449594 DOI: 10.1126/science.1222002]

3 March of Dimes global report on birth defects: the hidden toll of dying and disabled children. [Accessed May 23, 2014]. Available from: URL: http://www.marchofdimes.org/mission/march-of-dimes-global-report-on-birth-defects.aspx

4 Chinese Birth Defects Monitoring Collaborative Group. Atlas of Birth Defects in China. Chengdu: Chengdu Map Publishing House, 1992

5 **Yen IH**, Khoury MJ, Erickson JD, James LM, Waters GD, Berry RJ. The changing epidemiology of neural tube defects. United States, 1968-1989. *Am J Dis Child* 1992; **146**: 857-861 [PMID: 1496959 DOI: 10.1001/archpedi.1992.02160190089028]

6 **McDonnell RJ**, Johnson Z, Delaney V, Dack P. East Ireland 1980-1994: epidemiology of neural tube defects. *J Epidemiol Community Health* 1999; **53**: 782-788 [PMID: 10656087 DOI: 10.1136/jech.53.12.782]

7 **Li K**, He XB, Zhang L, Li ZW, Ye RW, Liu JM, Zhai RQ, Duan XJ, Ren AG. [Impact of pregnancy terminations before 28 weeks of gestation on the overall prevalence of neural tube defects in two counties of Shanxi province]. *Zhonghua Liuxing Bingxue Zazhi* 2012; **33**: 509-512 [PMID: 22883180]

8 **Williams J**, Mai CT, Mulinare J, Isenburg J, Flood TJ, Ethen M, Frohnert B, Kirby RS. Updated estimates of neural tube defects prevented by mandatory folic Acid fortification - United States, 1995-2011. *MMWR Morb Mortal Wkly Rep* 2015; **64**: 1-5 [PMID: 25590678]

9 **Daly LE**, Kirke PN, Molloy A, Weir DG, Scott JM. Folate levels and neural tube defects. Implications for prevention. *JAMA* 1995; **274**: 1698-1702 [PMID: 7474275]

10 **Meng Q**, Zhang L, Liu J, Li Z, Jin L, Zhang Y, Wang L, Ren A. Dietary folate intake levels in rural women immediately before pregnancy in Northern China. *Birth Defects Res A Clin Mol Teratol* 2015; **103**: 27-36 [PMID: 25066482 DOI: 10.1002/bdra.23280]

11 **Ren A**, Zhang L, Hao L, Li Z, Tian Y, Li Z. Comparison of blood folate levels among pregnant Chinese women in areas with high and low prevalence of neural tube defects. *Public Health Nutr* 2007; **10**: 762-768 [DOI: 10.1017/S1368980007246786]

12 Prevention of neural tube defects: results of the Medical Research Council Vitamin Study. MRC Vitamin Study Research Group. *Lancet* 1991; **338**: 131-137 [PMID: 1677062]

13 **Czeizel AE**, Dudás I. Prevention of the first occurrence of neural-tube defects by periconceptional vitamin supplementation. *N Engl J Med* 1992; **327**: 1832-1835 [PMID: 1307234]

14 **Berry RJ**, Li Z, Erickson JD, Li S, Moore CA, Wang H, Mulinare J, Zhao P, Wong LY, Gindler J, Hong SX, Correa A. Prevention of neural-tube defects with folic acid in China. China-U.S. Collaborative Project for Neural Tube Defect Prevention. *N Engl J Med* 1999; **341**: 1485-1490 [PMID: 10559448 DOI: 10.1056/NEJM199911113412001]

15 **Ren A**, Zhang L, Li Z, Hao L, Tian Y, Li Z. Awareness and use of folic acid, and blood folate concentrations among pregnant women in northern China--an area with a high prevalence of neural tube defects. *Reprod Toxicol* 2006; **22**: 431-436 [PMID: 16549319 DOI: 10.1016/j.reprotox.2006.02.003]

16 **Ministry of Health**. Birth Defects Prevention and Control in China. [Accessed April 18, 2014]. Available from: URL: http://www.gov.cn/gzdt/att/att/site1/20120912/1c6f6506c7f811bacf9301.pdf

17 **Liu J**, Jin L, Meng Q, Gao L, Zhang L, Li Z, Ren A. Changes in folic acid supplementation behaviour among women of reproductive age after the implementation of a massive supplementation programme in China. *Public Health Nutr* 2015; **18**: 582-588 [PMID: 24844654 DOI: 10.1017/S1368980014000950]

18 **Liu J**, Gao L, Zhang Y, Jin L, Li Z, Zhang L, Meng Q, Ye R, Wang L, Ren A. Plasma folate levels in early to mid pregnancy after a nation-wide folic acid supplementation program in areas with high and low prevalence of neural tube defects in china. *Birth Defects Res A Clin Mol Teratol* 2015; **103**: 501-508 [PMID: 25808729 DOI: 10.1002/bdra.23368]

19 Global Progress, 2014. [Accessed March 28, 2014]. Available from: URL: http://www.ffinetwork.org/global_progress/

20 **De Wals P**, Tairou F, Van Allen MI, Uh SH, Lowry RB, Sibbald B, Evans JA, Van den Hof MC, Zimmer P, Crowley M, Fernandez B, Lee NS, Niyonsenga T. Reduction in neural-tube defects after folic acid fortification in Canada. *N Engl J Med* 2007; **357**: 135-142 [PMID: 17625125 DOI: 10.1056/NEJMoa067103]

21 **Cortés F**, Mellado C, Pardo RA, Villarroel LA, Hertrampf E. Wheat flour fortification with folic acid: changes in neural tube defects rates in Chile. *Am J Med Genet A* 2012; **158A**: 1885-1890 [PMID: 22711368 DOI: 10.1002/ajmg.a.35430]

22 **Ren A**. Neural tube defects prevention with folic acid. *Beijing Daxue Xuebao* 2014; **46**: 343-346 [DOI: 10.3969/j.issn.1671-167X.2014.03.002]

P- Reviewer: Classen CF, Sergi CM, Urganci N
S- Editor: Tian YL **L- Editor**: A **E- Editor**: Liu SQ

World Journal of Clinical Pediatrics

Submit a Manuscript: http://www.wjgnet.com/esps/
Help Desk: http://www.wjgnet.com/esps/helpdesk.aspx
DOI: 10.5409/wjcp.v4.i3.45

World J Clin Pediatr 2015 August 8; 4(3): 45-49
ISSN 2219-2808 (online)
© 2015 Baishideng Publishing Group Inc. All rights reserved.

ORIGINAL ARTICLE

Observational Study

Response of levetiracetam in neonatal seizures

Maggie Lo-Yee Yau, Eva Lai-Wah Fung, Pak Cheung Ng

Maggie Lo-Yee Yau, Eva Lai-Wah Fung, Pak Cheung Ng, Department of Paediatrics, the Chinese University of Hong Kong, Hong Kong, China

Author contributions: Yau MLY retrieved the clinical information and prepared the manuscript; Fung ELW performed the literature search and prepared the manuscript; Ng PC supervised the management of the neonates and revised the final manuscript.

Supported by Joint Chinese University of Hong Kong-New Territories East Cluster Clinical Research Ethics Committee (CREC Ref.), No. 2014.072.

Institutional review board statement: The study was reviewed and approved by the Chinese University of Hong Kong Institutional Review Board.

Informed consent statement: Since this is an observational study, no informed consent was obtained from the participants.

Conflict-of-interest statement: All authors declare no conflict of interests associated with the preparation of the manuscript.

Data sharing statement: No additional data available.

Open-Access: This article is an open-access article which was selected by an in-house editor and fully peer-reviewed by external reviewers. It is distributed in accordance with the Creative Commons Attribution Non Commercial (CC BY-NC 4.0) license, which permits others to distribute, remix, adapt, build upon this work non-commercially, and license their derivative works on different terms, provided the original work is properly cited and the use is non-commercial. See: http://creativecommons.org/licenses/by-nc/4.0/

Correspondence to: Eva Lai-Wah Fung, MB, ChB, Department of Paediatrics, the Chinese University of Hong Kong, Rm 84034, 6/F, LCW Clinical Sciences Bldg., Prince of Wales Hospital, Shatin, Hong Kong, China. eva_fung@cuhk.edu.hk
Telephone: +852-26322981
Fax: +852-26360020

Received: April 20, 2015
Peer-review started: April 24, 2015
First decision: May 13, 2015
Revised: May 25, 2015
Accepted: June 15, 2015
Article in press: June 16, 2015
Published online: August 8, 2015

Abstract

AIM: To review the clinical response to levetiracetam (LEV) in neonatal seizure management in intensive care unit.

METHODS: Medical records of neonates who received LEV from January 2009 to August 2014 were reviewed. Their demographic data, clinical characteristics, etiology, seizures, electroencephalograms, response to treatment and outcome were noted. Literature review of use of LEV in neonates were also performed *via* PubMed and EMBASE with keywords - "neonates", "seizures", "epilepsy" and "LEV" up to Sep 2014 and retrieved the publications. The response rate to LEV was compared.

RESULTS: Twelve neonates were identified during the study period. All patients received phenobarbitone loading prior to consideration of LEV. Seven (58%) and nine (75%) achieved seizure freedom 24 h and 72 h after LEV was added, both clinically and electrographically. No serious adverse effects were associated with LEV use. From the literature, there are total 144 neonates reported to have used LEV. The overall results suggested that LEV could control up to 90% of neonatal seizures.

CONCLUSION: LEV was found to be relatively safe and efficacious in treating neonatal seizures, but might not work well in the most severe hypoxic ischemic encephalopathy.

Key words: Levetiracetam; Phenobarbitone; Neonates; Seizures

© **The Author(s) 2015.** Published by Baishideng Publishing

Group Inc. All rights reserved.

Core tip: Neonatal seizures are common, but there is lack of evidence to support use of anticonvulsants in this group of patients. Phenobarbitone remains the first line of treatment despite its limitations. The current study aims to review our experience of using levetiracetam (LEV) in management of neonatal seizures and to compare with the experience reported in the literature. We find that LEV is a relatively safe and feasible treatment option. Difficulties in performing studies were also discussed with the latest report of using bumetanide for treatment of neonatal seizures.

Yau MLY, Fung ELW, Ng PC. Response of levetiracetam in neonatal seizures. *World J Clin Pediatr* 2015; 4(3): 45-49 Available from: URL: http://www.wjgnet.com/2219-2808/full/v4/i3/45.htm DOI: http://dx.doi.org/10.5409/wjcp.v4.i3.45

INTRODUCTION

Seizures are common in the neonatal period. The incidence ranges from 2-4 in 1000 full term newborns and the prevalence is even higher in preterm babies. The etiologies are diverse, ranging from hypoxic-ischemic encephalopathy, encephalitis/meningitis, intraventricular hemorrhage, structural malformations, and metabolic or electrolyte disorders, *etc.* Phenobarbitone has been used since 1914 as the preferred first-line anticonvulsant in neonates. However, it has less than 50% efficacy in controlling neonatal seizures[1]. In animal models, phenobarbitone has been shown to cause neuronal apoptosis, and in toddlers and infants, it is associated with negative cognitive side effects[2].

Levetiracetam (LEV) is a pyrrolidine derivative, which acts through binding to and modulation of the synaptic vesicle protein SV2A. It is well tolerated with little drug-to-drug interactions. The most reported adverse effects are sedation and behavioral changes. However, its uses in neonates are still under investigation. This article aims to report our experience of using LEV in our neonatal intensive care unit especially those with hypoxic ischemic encephalopathy and compare with the reported cases.

MATERIALS AND METHODS

Infants were eligible if they received their first dose of LEV within the first four weeks of life between January 2009 to August 2014. These neonates were identified *via* the clinical data analysis and reporting system of the local health authority, which is an electronic database of the essential clinical information of all inpatients, including every single drug used. The medical records of all these infants were then retrieved. There was no loss of information in the records. Information on demographics (sex, gestational age, and Apgar score), seizure onset, aetiology, neuroimaging, treatment, response and outcome were retrieved. The study was approved by the local clinical research ethics board (CREC 2014.072).

We then searched the PubMed and EMBASE in English with keywords - "neonates", "seizures", "epilepsy" and "LEV" up to Sep 2014 and retrieved the publications. Case series/reports with patients who started LEV in less than 28 d of life or less than 44 post-conceptional weeks were included.

RESULTS

The clinical characteristics of our patients are summarized in Table 1. There were six male and six female neonates identified during the study period. Gestational age ranged from 23 6/7 wk to 40 wk (mean: 34.9 wk, median 36 wk). One baby was extreme premature (less than 28 wk), five were premature neonates with gestational age between 28 to 36 wk and six were term babies. Etiologies of neonatal seizures include six neonates with hypoxic ischemic encephalopathy, three with meningitis/encephalitis, one had metabolic cause identified, one with presumed mitochondrial disease, and one had hypoglycemia whose seizures persisted even after hypoglycemia was corrected.

Utilization of LEV

All patients received phenobarbitone loading prior to consideration of LEV. LEV was offered if there was suboptimal response to initial anticonvulsants or if significant side effects were observed. All except one received intravenous LEV. The initial dosage ranged from 7.5-20 mg/kg, while the maintenance dosage ranged from 5-60 mg/kg per day. Seven (58%) and nine (75%) achieved seizure freedom 24 h and 72 h after LEV was added, both clinically and electrographically. We did not observe any cardiovascular complications (arrhythmia, hypotension), changes in blood counts, renal and liver function, *etc.*, after the introduction of LEV. Two babies died, one because of severe hypoxic ischemic encephalopathy and the other because of underlying metabolic disease. The remaining patients were discharged on LEV. Two patients were discharged with adjunctive phenobarbitone, while four were discharged with adjunctive topiramate as well. Six patients had discontinued LEV on subsequent follow up. The longest follow up was five years and five months.

DISCUSSION

There are various mechanisms that make the immature brain more excitable as compared to adult brain. These include overabundant excitatory glutamatergic neurons and paradoxical excitatory action of gamma-aminobutyric acid in the developing brain[3]. Immature development of the neurotransmitter systems leads to difference in targets for conventional anticonvulsant to work. There is only one randomized controlled trial in

Table 1 Clinical characteristics of neonates receiving levetiracetam

	Patient 1	Patient 2	Patient 3	Patient 4	Patient 5	Patient 6	Patient 7	Patient 8	Patient 9	Patient 10	Patient 11	Patient 12
Gestation (wk)	38	39	35	38	41	29	36	23 6/7	30	39	36	40
Apgar score (1 and 5 min)	9, 10	9, 10	9, 10	9, 10	8, 10	7, 9	0, 0	4, 6	0, 0	0, 0	0, 0	4, 7
Age of seizure onset (days of life)	19	10	8	1	1	0	0	3	0	0	0	0
Etiology	GBS meningitis	HSV encephalitis	Suspected mitochond-rial	Hypoglycemia	Sulphite oxidase deficiency	*E. Coli* meningitis	HIE	HIE	HIE	HIE	HIE	HIE
Neuroimaging	Cystic encephalo-malacia	Cystic encephalo-malacia	Cystic encephalo-malacia	Normal	Cystic encephalo-malacia	Hydrocephalus with generalized atrophy	Cystic encephalo-malacia	Cystic encephalo-malacia	Peri-ventricular leukomalacia	Normal	Peri-ventricular leukomalacia	Diffuse cystic encephalo-malcia
Electrographic seizures	Yes	Yes	Yes	Yes	Yes	Yes	Yes	Yes	Yes	Yes	Yes	Yes
Clinical status epilepticus	No	No	No	No	No	Yes	No	No	No	No	No	Yes
Hypothermia	-	-	-	-	-	-	No	No	No	Yes	Yes	Yes
Anticonvulsant order	PHB/MDZ/LEV	PHB/LEV	PHB/LEV	PHB/LEV	PHB/LEV	PHB/MDZ/THI/LEV	PHB/MDZ/LEV	PHB/MDZ/LEV	PHB/MDZ/LEV	PHB/MDZ/LEV	PHB/MDZ/LEV	PHB/MDZ/LEV/THI
LEV loading dose (mg/kg)	15	20	10	7.5	10	10	15	16	18	10	8	20
Mm maintenance (mg/kg per day)	27	40	20	60	20	30	36	5	36	20	15	40
Seizure after 24 h	No	No	No	No	No	Yes	Yes	No	Yes	Yes	No	Yes
Seizure after 72 h	No	No	No	No	No	No	No	No	Yes	Yes	No	Yes
Anticonvulsant at discharge	LEV	TPM/LEV	PHB/LEV	PHB/LEV	Not applicable	TPM/LEV	Not applicable	LEV	LEV/TPM	LEV	PHB/LEV	PHB/LEV
Outcome	Mild delay	Severe delay	Severe delay	Normal	Death	Severe delay	Death	Severe delay	Moderate delay	Mild delay	Severe delay	Severe delay

GBS: Group B streptococcus; HSV: Herpes simplex virus; HIE: Hypoxic ischemic encephalopathy; PHB: Phenobarbitone; MDZ: Midazolam; LEV: Levetiracetam; THI: Thiopentone; TPM: Topiramate.

neonatal epilepsy in which Painter *et al*[1] studied the effect of phenobarbitone compared to phenytoin in a randomized crossover study. Their efficacies were similar: 43% *vs* 45% respectivelyIn our series, nine babies (75%) were seizure free within 72 h after LEV was added. But only 50% of babies with hypoxic ischemic encephalopathy had their seizures controlled after addition of LEV.

From the literature, (Table 2) there are total 144 neonates reported to have used LEV. They were heterogeneous in terms of etiology, treatment dosage and reported responses. Among these cases, up to 132 cases achieved seizure freedom, either immediately after loading dose or within 72 h. The overall results suggested that LEV could control up to 90% of neonatal seizures. In those studies with individual etiology specified, the overall seizure control rate is also lower, around 71%. The data in premature babies (defined as less than 37 gestation weeks) is encouraging. There have been 52 premature babies reported and 40 of them had seizures controlled after adding LEV (77%). But we have to bear in mind the potential problems of publication bias towards positive treatment responses.

The side effect profile of LEV is relatively mild and well tolerated. There may be nonspecific behavioral changes in up to 21% of children. Its uses in young children and acute repetitive seizure setting, even at high doses, were found to be relatively safe and effective[15]. This is consistent with our observations and those reported in case series. In our series, all neonates were cared in the neonatal intensive care unit during the period of study with close hemodynamic monitoring. There was no immediate additional ventilator or inotropic support required after LEV was given. There were also no disturbances in the blood counts or liver and renal function. As most of these infants were critically ill with multiple medications, it would be preferable to use a drug with minimal drug-drug interaction, which is also a potential advantage of LEV. LEV might prevent intubation if anesthetic agents could be avoided for seizure control.

Interestingly, recently there have been animal studies regarding any possible neuroprotective or neurotoxic effect of LEV on neonatal rats. Griesmaier *et al*[16] found that LEV *per se* did not induce neurotoxicity in the developing rodent brain, but it increases brain injury in rodents with hypoxic-ischemic brain injury under the normothermic conditions, but not hypothermic conditions. But Komur *et al*[17] found that LEV has neuroprotective effect on hypoxic ischemic injury in neonatal rats. Further studies are

Table 2 Literature review of levetiracetam use in neonates

Ref.	Year of publication	No. of patients	Drugs used before LEV	Outcome: Seizure	No. of patients with HIE	Seizure outcome in HIE patients	Dosage (loading) (mg/kg)	Dosage (maintenance) (mg/kg per day)	Remarks
Shoemaker *et al*[4]	2007	3	PHB/MDZ/fPHT	All seizure free	1	Seizure controlled within 17 min of oral bolus	60 (oral)	30	
Fürwentsches *et al*[5]	2010	6	PHB	All seizure free in 6 d	1	Seizure free	NA	10-50	Prospective
Ledet *et al*[6]	2010	1	PHB	Seizure free	0	NA	NA	40	
Ramantani *et al*[7]	2011	38	NA	30 seizure free at 1 wk	9	NA	10	45-60	Prospective
Khan *et al*[8]	2011	22	PHB or PHT	19 seizure cessation at 1 h and 22 seizure free by 72 h	12	11 seizure cessation at 1 h			
Abend *et al*[9]	2011	23	PHB or PHT	7 seizure terminated, 1 reduced seizure > 50%, 1 seizure terminated in > 24 h, 2 improvement in > 24 h, 8 no improvement, 1 unable to judge	8	2 seizure terminated, 2 reduced seizures > 50%, 1 improvement in > 24 h, 2 no improvement, 1 unable to judge	5-22	10-80	LEV as first drug in 4 cases
Aylward *et al*[10]	2011	1	fPHT	Partially responsive	0	NA	20	19	
Sharpe *et al*[11]	2012	18	PHB	6 seizure controlled	8	NA	20-40	5-10	
Rakshasbhuvankar *et al*[12]	2013	8	PHB/PHT/MDZ	6 "excellent", 1 partial, 1 ineffective	5	4 "excellent", 1 "partial"	5-10	10-35	
Khan *et al*[13]	2013	12	PHB	9 seizure stopped in 24 h	5	3 seizure stopped in 24 h, 1 no response, 1 NA	25-50	50	
Kirmani[14]	2014	12	PHB	10 seizure free by 72 h	5	NA	25-50	25-50	

PHB: Phenobarbitone; PHT: Phenytoin; MDZ: Midazolam; fPHT: Fosphenytoin; NA: Not available or applicable; HIE: Hypoxic ischemic encephalopathy; LEV: Levetiracetam.

needed to clarify the exact effect of LEV in neonatal brains, either in normothermic or hypothermic conditions and its clinical implications.

Up to date, the pharmacokinetics of LEV in neonates remains unclear. There is a wide range of dosing reported in the literature, ranging from 10-60 mg/kg loading and 10 to 80 mg/kg as maintenance and the frequency of dosing is also uncertain. We used a median dose of 12.5 mg/kg. Merhar *et al*[18] suggested that the half-life of LEV is 8.9 h, longer when compared to older children. But Sharpe *et al*[11] suggested that the clearance is higher in neonates suggesting more frequent dosing may be required. Therefore the optimal dosing and frequency of LEV in neonates still remains to be defined.

There were a few limitations to our study. This is a retrospective case series with relatively few patients. Together with published series/reports so far, could only provide level Ⅳ evidence to support use of LEV in neonates. But in real life practice, it is pragmatic to consider off-label use of drugs after gaining initial experience in older children. In fact, LEV is increasingly used in algorithms in the management of phenobarbitone-resistant neonatal seizures[19].

Secondly, neonatal seizures were known to have spontaneous cessation, which could partially contributed to the observed efficacy of LEV. As most patients were already treated with multiple anticonvulsants prior to addition of LEV, the efficacy of LEV might be difficult to be delineated from the con-interventions.

Problems in studying medical treatment are best illustrated by the recent report of Ronit Pressler and members of the treatment of Neonatal seizures with Medication Off-patent consortium in using bumetanide for treatment of neonatal seizures[20]. In the study, 30 patients were screened for electrographic seizures associated with hypoxic ischemic encephalopathy and 14 patients were enrolled. But five of them had no further seizures during the baseline period, so were de facto treatment failures. There are concerns and debates about what should be chosen and included in assessing the efficacy endpoints. It is controversial whether we should also include long-term developmental outcome and development of epilepsy, *etc.*, in the evaluation.

The experience from our case series, together with the published literature so far, supports LEV is a relatively safe and feasible option in neonatal seizures. But it may not work as well in neonates with most severe hypoxic ischemic encephalopathy. Further work is needed to evaluate its possible neuroprotective/neurotoxic effect in neonatal brains, the optimal dosage and role in neonatal seizures, *etc*.

COMMENTS

Background

Neonatal seizures are common, but there is lack of evidence to support use of anticonvulsants in this group of patients. Phenobarbitone remains the first line of treatment despite its limitations. Studies have reported the use of levetiracetam (LEV) in this group of patients.

Research frontiers

LEV is a broad-spectrum anticonvulsant which is licensed to be used in infants > 4 wk of age. Its use in neonates is still under investigation. It is very difficult to conduct controlled trials in neonatal seizures. The current research hotspot is to review our experience of using LEV in management of neonatal seizures and to compare with the experience reported in the literature.

Innovations and breakthroughs

This current study reviewed that LEV could be safely administered in sick neonates and its efficacy might be limited in those with most severe hypoxic ischemic encephalopathy. The experience from literature review also supports the relative safety of the drug.

Applications

LEV is a relatively safe and feasible treatment option for neonatal seizures.

Terminology

Neonatal seizures are common. The etiologies are diverse, ranging from hypoxic-ischemic encephalopathy, encephalitis/meningitis, intraventricular hemorrhage, structural malformations, and metabolic or electrolyte disorders, *etc.* LEV is a relatively safe and feasible treatment option for neonatal seizures.

Peer-review

Few medicines studied and approved to treat this subset of patients, management difficult.

REFERENCES

1 **Painter MJ**, Scher MS, Stein AD, Armatti S, Wang Z, Gardiner JC, Paneth N, Minnigh B, Alvin J. Phenobarbital compared with phenytoin for the treatment of neonatal seizures. *N Engl J Med* 1999; **341**: 485-489 [PMID: 10441604]

2 **Bittigau P**, Sifringer M, Genz K, Reith E, Pospischil D, Govindarajalu S, Dzietko M, Pesditschek S, Mai I, Dikranian K, Olney JW, Ikonomidou C. Antiepileptic drugs and apoptotic neurodegeneration in the developing brain. *Proc Natl Acad Sci USA* 2002; **99**: 15089-15094 [PMID: 12417760]

3 **Dulac O**, Milh M, Holmes GL. Brain maturation and epilepsy. *Handb Clin Neurol* 2013; **111**: 441-446 [PMID: 23622192 DOI: 10.1016/B978-0-444-52891-9.00047-6]

4 **Shoemaker MT**, Rotenberg JS. Levetiracetam for the treatment of neonatal seizures. *J Child Neurol* 2007; **22**: 95-98 [PMID: 17608315]

5 **Fürwentsches A**, Bussmann C, Ramantani G, Ebinger F, Philippi H, Pöschl J, Schubert S, Rating D, Bast T. Levetiracetam in the treatment of neonatal seizures: a pilot study. *Seizure* 2010; **19**: 185-189 [PMID: 20133173 DOI: 10.1016/j.seizure.2010.01.003]

6 **Ledet DS**, Wheless JW, Rubnitz JE, Brannon Morris E. Levetiracetam as monotherapy for seizures in a neonate with acute lymphoblastic leukemia. *Eur J Paediatr Neurol* 2010; **14**: 78-79 [PMID: 19186085 DOI: 10.1016/j.ejpn.2008.12.007]

7 **Ramantani G**, Ikonomidou C, Walter B, Rating D, Dinger J. Levetiracetam: safety and efficacy in neonatal seizures. *Eur J Paediatr Neurol* 2011; **15**: 1-7 [PMID: 21094062 DOI: 10.1016/j.ejpn.2010.10.003]

8 **Khan O**, Chang E, Cipriani C, Wright C, Crisp E, Kirmani B. Use of intravenous levetiracetam for management of acute seizures in neonates. *Pediatr Neurol* 2011; **44**: 265-269 [PMID: 21397167 DOI: 10.1016/j.pediatrneurol.2010.11.005]

9 **Abend NS**, Gutierrez-Colina AM, Monk HM, Dlugos DJ, Clancy RR. Levetiracetam for treatment of neonatal seizures. *J Child Neurol* 2011; **26**: 465-470 [PMID: 21233461 DOI: 10.1177/0883073810384263]

10 **Aylward SC**, Gilbert DL. Multigenerational benign familial neonatal seizures with inadequate clinical response to levetiracetam. *J Pediatr Neurol* 2011; **9**: 397-399 [DOI: 10.3233/JPN-2011-0498]

11 **Sharpe CM**, Capparelli EV, Mower A, Farrell MJ, Soldin SJ, Haas RH. A seven-day study of the pharmacokinetics of intravenous levetiracetam in neonates: marked changes in pharmacokinetics occur during the first week of life. *Pediatr Res* 2012; **72**: 43-49 [PMID: 22495532 DOI: 10.1038/pr.2012.51]

12 **Rakshasbhuvankar A**, Rao S, Kohan R, Simmer K, Nagarajan L. Intravenous levetiracetam for treatment of neonatal seizures. *J Clin Neurosci* 2013; **20**: 1165-1167 [PMID: 23664133 DOI: 10.1016/j.jocn.2012.08.014]

13 **Khan O**, Cipriani C, Wright C, Crisp E, Kirmani B. Role of intravenous levetiracetam for acute seizure management in preterm neonates. *Pediatr Neurol* 2013; **49**: 340-343 [PMID: 23921284 DOI: 10.1016/j.pediatrneurol.2013.05.008]

14 **Kirmani BF**. Levetiracetam - an alternative option in preterm neonates for acute seizure management. *Mol Cell Epilepsy* 2014; **1**: 1-3

15 **Mbizvo GK**, Dixon P, Hutton JL, Marson AG. Levetiracetam add-on for drug-resistant focal epilepsy: an updated Cochrane Review. *Cochrane Database Syst Rev* 2012; **9**: CD001901 [PMID: 22972056 DOI: 10.1002/14651858.CD001901]

16 **Griesmaier E**, Stock K, Medek K, Stanika RI, Obermair GJ, Posod A, Wegleiter K, Urbanek M, Kiechl-Kohlendorfer U. Levetiracetam increases neonatal hypoxic-ischemic brain injury under normothermic, but not hypothermic conditions. *Brain Res* 2014; **1556**: 10-18 [PMID: 24530252 DOI: 10.1016/j.brainres.2014.01.034]

17 **Komur M**, Okuyaz C, Celik Y, Resitoglu B, Polat A, Balci S, Tamer L, Erdogan S, Beydagi H. Neuroprotective effect of levetiracetam on hypoxic ischemic brain injury in neonatal rats. *Childs Nerv Syst* 2014; **30**: 1001-1009 [PMID: 24526342 DOI: 10.1007/s00381-014-2375-x]

18 **Merhar SL**, Schibler KR, Sherwin CM, Meinzen-Derr J, Shi J, Balmakund T, Vinks AA. Pharmacokinetics of levetiracetam in neonates with seizures. *J Pediatr* 2011; **159**: 152-154.e3 [PMID: 21592494 DOI: 10.1016/j.jpeds.2011.03.057]

19 **Hart AR**, Pilling EL, Alix JJ. Neonatal seizures-part 2: Aetiology of acute symptomatic seizures, treatments and the neonatal epilepsy syndromes. *Arch Dis Child Educ Pract Ed* 2015; Epub ahead of print [PMID: 25824891 DOI: 10.1136/archdischild-2014-306388]

20 **Pressler RM**, Boylan GB, Marlow N, Blennow M, Chiron C, Cross JH, de Vries LS, Hallberg B, Hellström-Westas L, Jullien V, Livingstone V, Mangum B, Murphy B, Murray D, Pons G, Rennie J, Swarte R, Toet MC, Vanhatalo S, Zohar S. Bumetanide for the treatment of seizures in newborn babies with hypoxic ischaemic encephalopathy (NEMO): an open-label, dose finding, and feasibility phase 1/2 trial. *Lancet Neurol* 2015; **14**: 469-477 [PMID: 25765333 DOI: 10.1016/S1474-4422(14)70303-5]

P- Reviewer: Onakewhor JUE, Troncoso AR **S- Editor**: Ji FF
L- Editor: A **E- Editor**: Liu SQ

Published by **Baishideng Publishing Group Inc**
8226 Regency Drive, Pleasanton, CA 94588, USA
Telephone: +1-925-223-8242
Fax: +1-925-223-8243
E-mail: bpgoffice@wjgnet.com
Help Desk: http://www.wjgnet.com/esps/helpdesk.aspx
http://www.wjgnet.com

© 2015 Baishideng Publishing Group Inc. All rights reserved.

ISSN 2219-2808 (online)

World Journal of *Clinical Pediatrics*

World J Clin Pediatr 2015 November 8; 4(4): 50-166

Published by Baishideng Publishing Group Inc

WJCP World Journal of Clinical Pediatrics

A peer-reviewed, online, open-access journal of clinical pediatrics

Editorial Board

2012-2016

The *World Journal of Clinical Pediatrics* Editorial Board consists of 247 members, representing a team of worldwide experts in pediatrics. They are from 43 countries, including Argentina (1), Australia (7), Austria (4), Belgium (2), Brazil (4), Canada (7), Chile (2), China (22), Denmark (2), Egypt (10), Finland (1), France (5), Germany (4), Greece (8), India (14), Iran (5), Israel (7), Italy (22), Japan (6), Mexico (2), Netherlands (2), New Zealand (1), Nigeria (3), Norway (1), Pakistan (2), Poland (2), Portugal (1), Russia (2), Saudi Arabia (2), Serbia (2), Singapore (3), Slovenia (1), South Africa (2), South Korea (2), Spain (5), Sweden (4), Switzerland (1), Thailand (2), Tunisia (1), Turkey (18), United Arab Emirates (1), United Kingdom (11), United States (43).

EDITOR-IN-CHIEF
Eduardo H Garin, *Gainesville*

GUEST EDITORIAL BOARD MEMBERS
Hsiao-Wen Chen, *Taipei*
Ming-Ren Chen, *Taipei*
Mu-Kuan Chen, *Changhua*
Ching-Chi Chi, *Chiayi*
Hung-Chih Lin, *Taichung*

MEMBERS OF THE EDITORIAL BOARD

Argentina

Alcides Richard Troncoso, *Buenos Aires*

Australia

Garry Inglis, *Herston*
Jagat Kanwar, *Victoria*
Katherine Kedzierska, *Parkville*
Eline Suzanne Klaassens, *Brisbane*
Sam S Mehr, *Sydney*
Jing Sun, *Brisbane*
Cuong Duy Tran, *Adelaide*

Austria

Gerhard Cvirn, *Graz*
Claudia Elisabeth Gundacker, *Vienna*
Bernhard Resch, *Graz*
Amulya K Saxena, *Graz*

Belgium

Karel Allegaert, *Leuven*
Yvan Vandenplas, *Brussels*

Brazil

Rejane Correa Marques, *Rio de Janeiro*
Priscila Krauss Pereira, *Rio de Janeiro*
Maria L Seidl-de-Moura, *Rio de Janeiro*
Sandra Elisabete Vieira, *São Paulo*

Canada

Helen SL Chan, *Toronto*
Ediriweera Desapriya, *Vancouver*
Eleftherios P Diamandis, *Toronto*
Ran D Goldman, *Vancouver*
Manjula Gowrishankar, *Edmonton*
Prakesh S Shah, *Toronto*
Pia Wintermark, *Montreal*

Chile

René Mauricio Barría, *Valdivia*
Irene Morales Bozo, *Santiago*

China

Yu-Zuo Bai, *Shenyang*
Xiao-Ming Ben, *Nanjing*
Kwong-Leung Chan, *Hong Kong*
Xian-Hui He, *Guangzhou*
Jian Hu, *Harbin*
Xi-Tai Huang, *Tianjin*
Huang-Xian Ju, *Nanjing*
Ren Lai, *Kunming*
Li Liu, *Xi'an*
Xue-Qun Luo, *Guangzhou*
Ai-Guo Ren, *Beijing*
Chiu-Lai Shan, *Hong Kong*
Yuk Him Tam, *Hong Kong*
Jin-Xing Wang, *Jinan*
Jun-Jun Wang, *Beijing*
Long-Jiang Zhang, *Nanjing*
Yi-Hua Zhou, *Nanjing*

Denmark

Jesper Bo Nielsen, *Odense*
Ole D Wolthers, *Randers*

Egypt

Mosaad Abdel-Aziz, *Cairo*
Hesham E Abdel-Hady, *Mansoura*
Mohammed Al-Biltagi, *Tanta*
Mohammad MS Al-Haggar, *Mansoura*
Ashraf MAB Bakr, *Mansoura*
Badr Eldin Mostafa, *Cairo*
Rania Refaat, *Cairo*
Omar Mamdouh Shaaban, *Assiut*
Maysaa El Sayed Zaki, *Mansoura*
Magdy Mohamed Zedan, *Mansoura*

Finland

Bright Ibeabughichi Nwaru, *Tampere*

France

Philippe Georgel, *Strasbourg*
Grill Jacques, *Villejuif*

Manuel Lopez, *Saint Etienne*
Georgios Stamatas, *Issy-les-Moulineaux*
Didier Vieau, *Villeneuve d'Ascq*

Germany

Yeong-Hoon Choi, *Cologne*
Carl Friedrich Classen, *Rostock*
Stephan Immenschuh, *Hannover*
Ales Janda, *Freiburg im Breisgau*

Greece

Michael B Anthracopoulos, *Rion-Patras*
Savas Grigoriadis, *Thessaloniki*
Vasiliki-Maria Iliadou, *Thessaloniki*
Theofilos M Kolettis, *Ioannina*
Ariadne Malamitsi-Puchner, *Athens*
Dimitrios Papandreou, *Thessaloniki*
Kostas N Priftis, *Athens*
Ioannis Michael Vlastos, *Heraklion*

India

Amit Agrawal, *Ambala*
Sameer Bakhshi, *New Delhi*
Atmaram H Bandivdekar, *Mumbai*
Sandeep Bansal, *Chandigarh*
Sriparna Basu, *Varanasi*
Ashu Seith Bhalla, *New Delhi*
Sushil Kumar Kabra, *New Delhi*
Praveen Kumar, *New Delhi*
Kaushal Kishor Prasad, *Chandigarh*
Yogesh Kumar Sarin, *New Delhi*
Kushaljit Singh Sodhi, *Chandigarh*
Raveenthiran V Venkatachalam, *Tamilnadu*
B Viswanatha, *Bangalore*
Syed Ahmed Zaki, *Mumbai*

Iran

Mehdi Bakhshaee, *Mashhad*
Maria Cheraghi, *Ahvaz*
Mehran Karimi, *Shiraz*
Samileh Noorbakhsh, *Tehran*
Firoozeh Sajedi, *Tehran*

Israel

Shraga Aviner, *Ashkelon*
Aviva Fattal-Valevski, *Ramat Aviv*
Rafael Gorodischer, *Omer*
Gil Klinger, *Petah Tikva*
Asher Ornoy, *Jerusalem*
Giora Pillar, *Haifa*
Yehuda Shoenfeld, *Tel-Hashomer*

Italy

Roberto Antonucci, *Cagliari*
CarloV Bellieni, *Siena*
Silvana Cicala, *Naples*
Sandro Contini, *Parma*
Enrico Stefano Corazziari, *Rome*
Vincenzo Cuomo, *Rome*
Vassilios Fanos, *Cagliari*
Filippo Festini, *Florence*
Irene Figa-Talamanca, *Rome*
Dario Galante, *Foggia*
Fabio Grizzi, *Milan*
Alessandro Inserra, *Rome*
Achille Iolascon, *Naples*
Cantinotti Massimiliano, *Pietrsanta*
Ornella Milanesi, *Padova*
Giovanni Nigro, *L'Aquila*
Giuseppe Rizzo, *Rome*
Claudio Romano, *Messina*
Mario Santinami, *Milano*
Gianluca Terrin, *Rome*
Alberto Tommasini, *Trieste*
Giovanni Vento, *Rome*

Japan

Ryo Aeba, *Tokyo*
Kazunari Kaneko, *Osaka*
Hideaki Senzaki, *Saitama*
Kohichiro Tsuji, *Tokyo*
Toru Watanabe, *Niigata*
Takayuki Yamamoto, *Yokkaichi*

Mexico

Fernando Guerrero-Romero, *Durango*
Mara Medeiros, *Mexico*

Netherlands

Jacobus Burggraaf, *Leiden*
Paul Eduard Sijens, *Groningen*

New Zealand

Simon James Thornley, *Auckland*

Nigeria

Akeem Olawale Lasisi, *Ibadan*
Tinuade Adetutu Ogunlesi, *Sagamu*
Joseph Ubini Ese Onakewhor, *Benin*

Norway

Lars T Fadnes, *Bergen*

Pakistan

Niloufer Sultan Ali, *Karachi*
Shakila Zaman, *Lahore*

Poland

Piotr Czauderna, *Gdansk*
Joseph Prandota, *Wroclaw*

Portugal

Alexandre M Carmo, *Porto*

Russia

Perepelitsa S Alexandrovna, *Kaliningrad*
Vorsanova Svetlana, *Moscow*

Saudi Arabia

Naser Labib Rezk, *Riyadh*
Amna Rehana Siddiqui, *Riyadh*

Serbia

Bjelakovic Borisav Bojko, *Nis*
Mirela Erić, *Novi Sad*

Singapore

Quak Seng Hock, *Singapore*
Anselm CW Lee, *Singapore*
Alvin Soon Tiong Lim, *Singapore*

Slovenia

Rok Orel, *Ljubljana*

South Africa

David Kenneth Stones, *Free State*
Eric Oghenerioborue Udjo, *Pretoria*

South Korea

Byung-Ho Choe, *Daegu*
Dong-Hee Lee, *Seoul*

Spain

Pilar Codoñer-Franch, *Valencia*
Claudio Golffier, *Barcelona*
Pablo Menendez, *Andalucía*
Juan F Martínez-Lage Sánchez, *Murcia*
Juan Antonio Tovar, *Madrid*

Sweden

Moustapha Hassan, *Stockholm*
Maria Christina Jenmalm, *Linköping*
Sandra Kleinau, *Uppsala*
Birgitta Lindberg, *Luleå*

Switzerland

Ulf Kessler, *Bern*

Thailand

Surasak Sangkhathat, *Hat Yai*
Viroj Wiwanitkit, *Bangkok*

Tunisia

John C Anyanwu, *Tunis Belvedere*

Turkey

Sinem Akgül, *Ankara*
Ayse Tuba Altug, *Ankara*
Suna Asilsoy, *Seyhan-Adana*
Ozgu Aydogdu, *Izmir*
Kadir Babaoglu, *Kocaeli*
Aksoy Berna, *Kocaeli*
Murat Biteker, *Istanbul*
Merih Çetinkaya, *Istanbul*
Aynur Emine Cicekcibasi, *Konya*
Elvan Caglar Citak, *Mersin*
Cem Dane, *Istanbul*
Mintaze Kerem Günel, *Ankara*
Ahmet Güzel, *Samsun*
Salih Kavukcu, *Izmir*
Fethullah Kenar, *Denizli*
Selim Kurtoglu, *Kayseri*
Turker Ozyigit, *Istanbul*
Yalçın Tüzün, *Istanbul*

United Arab Emirates

Iradj Amirlak, *Al Ain*

United Kingdom

Keith Collard, *Plymouth*
ASahib El-Radhi, *London*
Edzard Ernst, *Exeter*
Mohammad K Hajihosseini, *Norwich*
Tain-Yen Hsia, *London*
Claudio Nicoletti, *Norwich*
Cordula Margaret Stover, *Leicester*
Alastair Gordon Sutcliffe, *London*
Adrian Graham Thomas, *Manchester*
Richard Trompeter, *London*
Petros V Vlastarakos, *Stevenage*

United States

Stephen C Aronoff, *Philadelphia*
Hossam M Ashour, *Detroit*
Paul Ashwood, *Sacramento*
David C Bellinger, *Boston*
Vineet Bhandari, *New Haven*
FR Breijo-Marquez, *Boston*
Itzhak Brook, *Washington*
Patrick D Brophy, *Iowa*
Lavjay Butani, *Sacramento*
Archana Chatterjee, *Omaha*
Lisa M Cleveland, *San Antonio*
Shri R Deshpande, *Atlanta*
Michael Morgan Dowling, *Dallas*
Abdulrahman M El-Sayed, *New York*
Donald N Forthal, *Irvine*
Gregory Kane Friedman, *Birmingham*
Kenneth William Gow, *Seattle*
Dorothy I Bulas, *Washington*
Christopher L Coe, *Madison*
Elias Jabbour, *Houston*
Michael Van Doren Johnston, *Baltimore*
Ram V Kalpatthi, *Gainesville*
Stephen S Kim, *Annandale*
Edward Yungjae Lee, *Annandale*
Jing Lin, *New York*
Jorge Lopez, *Gainesville*
Aurelia Meloni-Ehrig, *Gainesville*
Murielle Mimeault, *Omaha*
Natan Noviski, *Omaha*
Michael David Seckeler, *Charlottesville*
Chetan Chandulal Shah, *Little Rock*
Mohamed Tarek M Shata, *Cincinnati*
Tsz-Yin So, *Greensboro*
Dennis Charles Stevens, *Sioux Falls*
Ru-Jeng Teng, *Milwaukee*
Rajan Wadhawan, *St Petersburg*
Hongjun Wang, *St Charleston*
Marie Wang, *Menlo Park*
Richard Wang, *Atlanta*
Wladimir Wertelecki, *Annandale*
Shu Wu, *Miami*
Fadi Xu, *Albuquerque*

WJCP World Journal of Clinical Pediatrics

Contents

Quarterly Volume 4 Number 4 November 8, 2015

FIELD OF VISION

50 Pediatric obesity prevention: From naïve examination of energy imbalance towards strategies that influence the competition for nutrient resources among tissues
Hanks LJ, Simpson T, McCormick K, Casazza K

REVIEW

55 Single-incision pediatric endosurgery in newborns and infants
Kozlov Y, Novozhilov V, Baradieva P, Krasnov P, Kovalkov K, Muensterer OJ

66 Congenital and childhood myotonic dystrophy: Current aspects of disease and future directions
Ho G, Cardamone M, Farrar M

81 Caffeine therapy in preterm infants
Abdel-Hady H, Nasef N, Shabaan AE, Nour I

94 Current management of pediatric soft tissue sarcomas
Sangkhathat S

MINIREVIEWS

106 Fever tree revisited: From malaria to autoinflammatory diseases
Pastore S, Vuch J, Bianco AM, Taddio A, Tommasini A

113 Efficiency of upper gastrointestinal endoscopy in pediatric surgical practice
Temiz A

120 Hirschsprung's disease: Historical notes and pathological diagnosis on the occasion of the 100th anniversary of Dr. Harald Hirschsprung's death
Sergi C

126 Acute encephalitis and encephalopathy associated with human parvovirus B19 infection in children
Watanabe T, Kawashima H

135 Use of corticosteroids during acute phase of Kawasaki disease
Yu JJ

143 Limitations of urease test in diagnosis of pediatric *Helicobacter pylori* infection
Seo JH, Park JS, Rhee KH, Youn HS

ORIGINAL ARTICLE

Retrospective Study

148 Coeliac disease in children in Christchurch, New Zealand: Presentation and patterns from 2000-2010
Kho A, Whitehead M, Day AS

155 Use of laparoscopy as the initial surgical approach of impalpable testes: 10-year experience
Chan KWE, Lee KH, Wong HYV, Tsui SYB, Wong YS, Pang KYK, Mou JWC, Tam YH

SYSTEMATIC REVIEWS

160 Inflammatory fibroid polyps in children: A new case report and a systematic review of the pediatric literature
Righetti L, Parolini F, Cengia P, Boroni G, Cheli M, Sonzogni A, Alberti D

ABOUT COVER

Editorial Board Member of *World Journal of Clinical Pediatrics*, Mehdi Bakhshaee, Assistant Professor, Otorhinolaryngology-Head and Neck Surgery, Mashhad University of Medical Sciences, Mashhad 9137913316, Iran

AIM AND SCOPE

World Journal of Clinical Pediatrics (*World J Clin Pediatr*, *WJCP*, online ISSN 2219-2808, DOI: 10.5409) is a peer-reviewed open access academic journal that aims to guide clinical practice and improve diagnostic and therapeutic skills of clinicians.

WJCP covers a variety of clinical medical topics, including fetal diseases, inborn, newborn diseases, infant diseases, genetic diseases, diagnostic imaging, endoscopy, and evidence-based medicine and epidemiology. Priority publication will be given to articles concerning diagnosis and treatment of pediatric diseases. The following aspects are covered: Clinical diagnosis, laboratory diagnosis, differential diagnosis, imaging tests, pathological diagnosis, molecular biological diagnosis, immunological diagnosis, genetic diagnosis, functional diagnostics, and physical diagnosis; and comprehensive therapy, drug therapy, surgical therapy, interventional treatment, minimally invasive therapy, and robot-assisted therapy.

We encourage authors to submit their manuscripts to *WJCP*. We will give priority to manuscripts that are supported by major national and international foundations and those that are of great clinical significance.

INDEXING/ABSTRACTING

World Journal of Clinical Pediatrics is now indexed in PubMed Central, PubMed and Digital Object Identifier.

FLYLEAF

I-III Editorial Board

EDITORS FOR THIS ISSUE

Responsible Assistant Editor: *Xiang Li*
Responsible Electronic Editor: *Xiao-Kang Jiao*
Proofing Editor-in-Chief: *Lian-Sheng Ma*
Responsible Science Editor: *Xue-Mei Gong*
Proofing Editorial Office Director: *Xiu-Xia Song*

NAME OF JOURNAL
World Journal of Clinical Pediatrics

ISSN
ISSN 2219-2808 (online)

LAUNCH DATE
June 8, 2012

FREQUENCY
Quarterly

EDITOR-IN-CHIEF
Eduardo H Garin, MD, Professor, Department of Pediatrics, University of Florida, 1600 SW Archer Road. HD214, Gainesville, FL 32610, United States

EDITORIAL OFFICE
Jin-Lei Wang, Director
Xiu-Xia Song, Vice Director
World Journal of Clinical Pediatrics
Room 903, Building D, Ocean International Center, No. 62 Dongsihuan Zhonglu, Chaoyang District, Beijing 100025, China
Telephone: +86-10-85381891
Fax: +86-10-85381893
E-mail: editorialoffice@wjgnet.com
Help Desk: http://www.wjgnet.com/esps/helpdesk.aspx
http://www.wjgnet.com

PUBLISHER
Baishideng Publishing Group Inc
8226 Regency Drive,
Pleasanton, CA 94588, USA
Telephone: +1-925-223-8242
Fax: +1-925-223-8243
E-mail: bpgoffice@wjgnet.com
Help Desk: http://www.wjgnet.com/esps/helpdesk.aspx
http://www.wjgnet.com

PUBLICATION DATE
November 8, 2015

COPYRIGHT
© 2015 Baishideng Publishing Group Inc. Articles published by this Open-Access journal are distributed under the terms of the Creative Commons Attribution Non-commercial License, which permits use, distribution, and reproduction in any medium, provided the original work is properly cited, the use is non commercial and is otherwise in compliance with the license.

SPECIAL STATEMENT
All articles published in journals owned by the Baishideng Publishing Group (BPG) represent the views and opinions of their authors, and not the views, opinions or policies of the BPG, except where otherwise explicitly indicated.

INSTRUCTIONS TO AUTHORS
Full instructions are available online at http://www.wjgnet.com/2219-2808/g_info_20100722180909.htm.

ONLINE SUBMISSION
http://www.wjgnet.com/esps/

World Journal of Clinical Pediatrics

Submit a Manuscript: http://www.wjgnet.com/esps/
Help Desk: http://www.wjgnet.com/esps/helpdesk.aspx
DOI: 10.5409/wjcp.v4.i4.50

World J Clin Pediatr 2015 November 8; 4(4): 50-54
ISSN 2219-2808 (online)
© 2015 Baishideng Publishing Group Inc. All rights reserved.

FIELD OF VISION

Pediatric obesity prevention: From naïve examination of energy imbalance towards strategies that influence the competition for nutrient resources among tissues

Lynae J Hanks, Tina Simpson, Kenneth McCormick, Krista Casazza

Lynae J Hanks, Department of Kinesiology, University of Montevallo, Montevallo, AL 35115, United States

Tina Simpson, Krista Casazza, Division of General Pediatrics and Adolescent Medicine, Department of Pediatrics, University of Alabama at Birmingham, Birmingham, AL 35233, United States

Kenneth McCormick, Division of Endocrinology, Department of Pediatrics, University of Alabama at Birmingham, Birmingham, AL 35233, United States

Author contributions: Hanks LJ, Simpson T, McCormick K and Casazza K contributed to writing, editing and revising of this paper.

Conflict-of-interest statement: We, authors declare no conflict of interest regarding our manuscript "Pediatric obesity prevention: From naïve examination of energy imbalance towards strategies that influence the competition for nutrient resources among tissues".

Open-Access: This article is an open-access article which was selected by an in-house editor and fully peer-reviewed by external reviewers. It is distributed in accordance with the Creative Commons Attribution Non Commercial (CC BY-NC 4.0) license, which permits others to distribute, remix, adapt, build upon this work non-commercially, and license their derivative works on different terms, provided the original work is properly cited and the use is non-commercial. See: http://creativecommons.org/licenses/by-nc/4.0/

Correspondence to: Krista Casazza, PhD, RD, LD, Associate Professor, Division of General Pediatrics and Adolescent Medicine, Department of Pediatrics, University of Alabama at Birmingham,1601 5th Ave S, CPPI 310, Birmingham, AL 35223, United States. kcasazza@peds.uab.edu
Telephone: +1-205-6386856
Fax: +1-205-9756503

Received: May 28, 2015
Peer-review started: June 1, 2015
First decision: August 14, 2015
Revised: September 14, 2015
Accepted: October 16, 2015
Article in press: October 19, 2015
Published online: November 8, 2015

Abstract

Current pediatric obesity interventions have collectively yielded relatively unsuccessful results. In this Field of Vision, we present plausible physiologic underpinnings fostering ineffectiveness of conventional strategies grounded in requisite induction of negative energy imbalance. Moreover, such recommendations exacerbate the underlying metabolic dysfunction by further limiting metabolic fuel availability, lowering energy expenditure, and increasing hunger (recapitulating the starvation response amid apparent nutritional adequacy) which precede and promote obesity during growth and development. The qualitative aspects of musculoskeletal system (*i.e.*, endocrine response, muscle functional capacity) are likely to improve metabolic function and increase nutrient delivery and utilization. An intricate and complex system including multiple feedback mechanisms operates to homeostatically regulate energy balance and support optimal body composition trajectories and metabolic health, during growth and development. Thus, ignoring the interdependencies of regulatory growth processes initiates a nuanced understanding of energy regulation and thus misguided attempts at preventive strategies. Importantly, these gains are not dependent upon weight-loss, rather we suggest can be achieved through resistance training. Collectively, optimizing musculoskeletal health *via* resistance training elicits augmentation of competitive capacity across systems. Further, substantial gains can be achieved in skeletal muscle mass, strength, and functional capacity through resistance training in a relatively short period of time.

Key words: Childhood obesity; Metabolic control; Energy balance; Resistance training; Effective intervention strategies; Weight loss; Musculoskeletal health

© The Author(s) 2015. Published by Baishideng Publishing Group Inc. All rights reserved.

Core tip: As obesity-related recommendations stand today, most are unproven and ineffective. While energy balance is an integral component, the etiology of pediatric obesity is a consequence of adipocytes "out competing" other cell types (*e.g.*, myocytes, osteocytes, hepatocytes) for energy. The cumulative effect of fat storage, energetically less costly is at the expense of optimal development of other tissues. The out-competition, due to hyperplasia and hypertrophy of adipocytes impairs physiologic pathways producing metabolically compromised obese children irreversible with "simple" energy balance paradigms. *Via* the activation of endocrine and paracrine effects of the musculoskeletal system, resistance training may be an effective strategy to improve health independent of initial weight loss. However, forced stress on the system is requisite (*e.g.*, resistance training). Resistance training induces systemic anabolism and enhances nutrient delivery and utilization, which are integral in optimizing metabolic control and body composition during growth and development, and in turn overall lifelong health.

Hanks LJ, Simpson T, McCormick K, Casazza K. Pediatric obesity prevention: From naïve examination of energy imbalance towards strategies that influence the competition for nutrient resources among tissues. *World J Clin Pediatr* 2015; 4(4): 50-54 Available from: URL: http://www.wjgnet.com/2219-2808/full/v4/i4/50.htm DOI: http://dx.doi.org/10.5409/wjcp.v4.i4.50

INTRODUCTION

The presage of pediatric obesity inducing a decline in life expectancy[1,2] has evoked calls for expert committees to direct stakeholders on how to best proceed with comprehensive prevention/intervention platforms. However, despite persistent calls for evidenced based policies, current dietary and physical activity interventions have collectively yielded a fairly unsuccessful paradigm. Herein, we provide a potential explanation for the chasm between the resource allocation to "combat" the pediatric obesity epidemic and improvement in health outcomes. As an exhaustive analysis of all pediatric obesity strategies, to date would be infeasible. Thus, the purpose of this Field of Vision is to highlight the conventional strategies and adoption of recommendations written by "expert committees" for governments or health authorities of the United States[3], United Kingdom[4] and Canada[5], the Institute of Medicine[6] and World Health Organization (WHO)[7] as well as Cochrane reviews[8,9] (largely grounded in inducing negative energy imbalance through increasing physical activity and dietary restriction) as naïve approaches to pediatric obesity prevention.

NAIVE EXAMINATION OF ENERGY IMBALANCE?

Despite endorsements of dietary and physical activity recommendations, the vast majority of interventions to date have had null findings. For example, in 2005, the American Medical Association, the Health Resources and Service Administration, and the Centers for Disease Control and Prevention (CDC) asked representatives from 15 national healthcare organizations to form an expert committee to make recommendations regarding the treatment of childhood and adolescent obesity. The expert committee determined the main foci should include: setting daily eating and activity goals for their overweight or obese children (increased expenditure), increasing consumption of fruits and vegetables (F and V) (modifying intake); minimizing sugary drinks (reduce calories); limiting screen time to $\leqslant$ 2 h (modifying sedentariness); attaining $\geqslant$ 1 h. physical activity (increased expenditure); encouraging primary care providers to more closely monitor these target behaviors and goals, and facilitating more explicit planning by parents to achieve weight loss. Similarly, Obesity Canada, convened a panel of experts to create clinical practice guidelines for Canadian health policy. The Steering Committee and Expert Panels in the United Kingdom and Canada reviewed the literature and several years later published their guidelines, which were very similar to those of the United States[10,11]. Since 2007, all governments in the United Kingdom have had action plans to reduce pediatric obesity prevalence[12]. The WHO globally led the charge indicating that reducing the consumption of high-calorie, energy-dense foods, including sugar-sweetened beverages, increasing the consumption of F and V; and increasing the initiation, duration, and exclusivity of breastfeeding represent comprehensive strategies for reducing pediatric obesity[7]. While we do not argue that these approaches have a reasonable basis with theoretical rationale, empirical evidence supporting implementation of any of the aforementioned for improved health outcomes have not been documented and in some instances proven to be ineffective[13]. Indeed, investigations linking pediatric obesity and early onset metabolic disease has substantiated developmental origins of disease. Despite a vast body of recommendations generated though these working groups, antiquated application of science has led to the promotion of non-evidence based, and sometimes anecdotal application of simple solutions to a complex problem. Furthermore, such unproven, unfiltered and inconsistent messages guiding pediatric weight management strategies persist despite absence of scientific supporting evidence and ultimately have contributed to a culture of confusion and disinterest. We clearly need a much more balanced approach to

discussing energy flux and long-term health. Conversely, very little attention has been devoted to determining those physiological factors characteristic of early life that could be protective to health and contribute to mitigating age-associated morbidities. While physical inactivity and the consequent adverse effects on fat storage and energy metabolism across the life course[14-19], may be more pathologic during development, this critical period also represents a stage in which capitalization on the benefits of body composition may be attained.

FAILURE OF WEIGHT LOSS STRATEGIES

We conjecture that the failure of weight loss strategies to improve health in the pediatric population is grounded in the fundamental assumption that inducing negative imbalances *via* caloric restriction and energy expenditure circumvent excessive fat storage during growth and development. Indeed, energy balance plays a role; however, during growth and development excess fat storage is a consequence of adipocytes "out competing" other cell types (*e.g.,* myocytes, osteocytes, hepatocytes) for energy due to lack of engagement of other cell types in the competition for energy[16-18]. Over the three decades encompassing the pediatric obesity "epidemic", sedentary behaviors have increased drastically, with the vast majority of free time spent by children in light activity or relatively inactive and engaged in limited (if any) moderate to high-intensity activities. During the anabolic growth stage, failure to engage skeletal muscle, as a primary tissue in the regulation of fuel utilization and delivery, in greater than day to day threshold promotes metabolic compromise. In turn, the endocrine and paracrine effects of the musculoskeletal system in which contraction greater than the "typical day to day threshold" is requisite are attenuated, while the endocrine effects of adipose tissue are up-regulated. Dietary restriction, in the absence of muscle contract, further increased sensitivity of adipokines to promote fat storage[18,19]. This conceptualization is strongly supported by extant research, given those increments in fat mass are a function of adiposity, adipocyte number is a primary determinant of obesity, and early pubertal development is a major determinant of adipocyte number and lifelong obesity risk[19]. Thus, modifying diet and/or engaging in low-intensity physical activity programs in which mechanical stress is not requisite, does not generate competitive inclusion of oseto-/myo-cytes. As such, the competitive advantage of adipocytes and ensuing loss of metabolic control due to lack of participation by the musculoskeletal system is nearly impossible to counter. The cumulative effect of nutrient partitioning to adipose at the expense of other tissues in concert with a greater number of adipocytes and impaired glucose and lipid metabolism produce metabolically compromised children predisposed to inactivity, metabolic dysfunction and obesity irrespective of short-term weight loss strategies. In this context, it is naïve to suggest that limiting availability of nutrients without enhancing utilization capacity. According many of the recommendations to date represents a futile process enhancing adipocyte dominance rather than attenuating it, with particular salience during the dynamic metabolic sequalae of critical periods in development (*e.g.,* the pubertal transition).

ABSENCE OF MUSCLE CONTRACTION

Notably, increasing daily activity by children does not merely characterize play, but encompasses an essential component of healthy growth and development. Optimal musculoskeletal development is derived from complex integration of cellular and systemic autocrine, paracrine and endocrine factors that promote the capacity to sustain work. Thus, enhanced musculoskeletal function *via* augmenting metabolic crosstalk has the capacity to improve whole body metabolism including insulin-stimulated glucose uptake, lipolysis, and resting energy expenditure in addition to improving musculoskeletal function and overall health. Substantial evidence in animals and humans highlight the great detriment of physical inactivity. For example, after 4-h of inactivity (tail suspension), a functional decline in lipoprotein lipase (LPL) activity accompanied by decreased skeletal muscle triglyceride clearance, lower HDL and attenuated muscle oxidative capacity with immediate decline in musculoskeletal function has been observed[16-18]. Occupational studies indicate workers who sat most of the day have about twice the rate of cardiovascular disease as those demanding more standing and ambulatory activities[18]. Moreover, human bed rest investigations revealed that one-to-three weeks of bed rest in otherwise healthy, active men had a more profound impact on physical work capacity than did three decades of aging in the same men[15,16]. Within days, decreased muscle activity due to prolonged bed rest decreased skeletal muscle insulin sensitivity, insulin signaling, fitness, leg muscle mass and increased intra-abdominal fat[16] and reduced insulin signaling, altered glucose and lipid metabolism and increased central adiposity even in the absence of weight-loss. We acknowledge that bed rest is an extreme model of inactivity and does not accurately mimic the low levels of physical activity that even most sedentary individuals undergo on a daily basis. However, the minimal 8 h a day of sitting in today's youth in school (not to mention the well-documented low levels of activity in the home environment) may in legitimately represent a degree of such extreme inactivity.

Importantly, the capacity for skeletal muscle to fulfill its essential role in governing glucose and lipid oxidation is largely attributable to stimulation of contractile forces which exceed the day-to-day threshold of skeletal use. Stimulation by contractile forces enhances the synthesis and release of skeletal muscle peptides which participate in a variety of metabolic actions[14,17]. A shift in paradigm is desperately needed.

SHIFT IN PARADIGM

Enhancing nutrient utilization rather than diminishing nutrient availability (*e.g.,* negative energy balance) can be more readily accepted with improved adherence. Thus, germane to our proposed shift in paradigm, contraction-dependent endocrine effects of skeletal muscle have been shown to improve metabolic parameters and offer a means of improving nutrient delivery and utilization. Importantly, these gains are not dependent upon weight-loss, rather we suggest can be achieved through resistance training. Relative to the commonly prescribed aerobic exercise, resistance exercise: (1) evokes a lower perceived exertion and is more readily accepted among obese individuals; (2) requires less cardiorespiratory capacity in the initial phases (rather short bouts of effort); and (3) activates anabolic processes leading to musculoskeletal hypertrophy. Collectively, optimizing musculoskeletal health elicits augmentation of competitive capacity of myocytes, osteocytes and hepatocytes. Further, substantial gains can be achieved in skeletal muscle mass, strength, and functional capacity through resistance training in a relatively short period of time. While the sense of urgency is now at the pinnacle, evidence of the emergence of the dire health effects caused by inactivity has been steadily mounting for several decades[2,20]. The reduced activity in contemporary youth apparent from the early 1970s to present has substantially altered growth-related outcomes in the pediatric population[21-26]. This is as evidenced by progressive and cumulative increases in height[22,23], body mass[24], bone mass, organ mass, and fat mass/adiposity[25] as well as earlier onset and progression of chronic diseases. As these metabolically compromised children mature and transition through puberty and the adverse effects of physical inactivity manifest[27], the competitive advantage of adipocytes increases, underlying the poor health and well-being prognostication of future generations. To move forward, future research and subsequent recommendations may be most productive if directed away from naïve examination of energy balance and redirected towards intervention/prevention strategies that influence the competition for nutrient resources among tissues.

CONCLUSION

The reliance on conventional strategies for decreasing pediatric obesity prevalence continues despite decades of unequivocal evidence. While, in theory, inducing negative energy imbalance seems logical, targeted efforts have been largely ineffective in sustained weight management and/or improvement in health outcomes. Herein, we explored the chasm between the current recommendations in the pediatric population driving approaches, exposing where lack of science-based direction has led to futility and propose a potential paradigmatic shift away from the adipcentric focus encompassing developmental origins of disease towards capitalizing on the substantive aspects of health during childhood. Cumulatively, work to date has vastly improved our knowledge of the complex nature of pediatric obesity and led to the identification of mechanisms underlying a competitive advantage of adipocytes during growth, however, an effective strategy to promote health outcomes in the contemporary obesogenic environment remains elusive. We contend, the failure of weight (fat) loss strategies in the pediatric population is grounded in a requisite negative energy imbalance for improving health outcomes. While weight management is imperative, we posit that induction of negative energy imbalance should not be the main, and certainly not the only, focus for treatment of the obese child for promotion of metabolic improvement. As such, the persistent dependence on caloric restriction and the prescribed about 60 min per day of aerobic activity has demonstrated that adherence, and consequent long-term weight management and metabolic health improvements are minimal. Thus, to move forward, future research and subsequent recommendations may be most productive if directed away from naïve examination of energy balance and redirected towards intervention/prevention strategies that enhance nutrient partitioning to tissues (*i.e.,* myocytes, hepatocytes, osteocytes, *etc.*). It is well-established that chronic inactivity pathologically elicits adipocyte storage feedback mechanisms (*e.g.,* hyperplastic adiposity, intensified pancreatic β-cell function, impaired skeletal muscle function), increasing the risk of metabolic disease, cardiovascular incidents and some cancers. However, inducing resistance to the musculoskeletal system exerts contractile forces which enhance the synthesis and release of peptides released from muscle, bone and liver which participate in a variety of beneficial metabolic actions, including enhancing glucose uptake and lipid oxidation. Further, nutrient utilization and delivery and in turn, metabolic profile can be improved *via* improving the signaling from other tissues. Importantly, these feed forward metabolic actions can be achieved even in the absence of weight-loss, and without negative energy imbalance.

REFERENCES

1 **Katzmarzyk PT**, Barlow S, Bouchard C, Catalano PM, Hsia DS, Inge TH, Lovelady C, Raynor H, Redman LM, Staiano AE, Spruijt-Metz D, Symonds ME, Vickers M, Wilfley D, Yanovski JA. An evolving scientific basis for the prevention and treatment of pediatric obesity. *Int J Obes* (Lond) 2014; **38**: 887-905 [PMID: 24662696 DOI: 10.1038/ijo.2014.49]

2 **Olshansky SJ**. Projecting the future of U.S. health and longevity. *Health Aff* (Millwood) 2005; **24** Suppl 2: W5R86-W5R89 [PMID: 16186155 DOI: 10.1377/hlthaff.w5.r86]

3 Solving the problem of childhood obesity within a generation: White house task force on childhood obesity report to the president. [accessed 2010 May]. Available from: URL: http://www.letsmove.gov/sites/letsmove.gov/files/TaskForce_on_Childhood_Obesity_May2010_FullReport.pdf

4 **Merrifield R.** Healthy weights for healthy kids: report of the standing committee on health. [accessed 2007 March]. Available

from: URL: http://www.parl.gc.ca/content/hoc/Committee/391/HESA/Reports/RP2795145/hesarp07/hesarp07-e.pdf

5 **Tremblay MS**. Major initiatives related to childhood obesity and physical inactivity in Canada: the year in review. *Can J Public Health* 2007; **103**: 164-169 [PMID: 22905632]

6 **Committee on Accelerating Progress in Obesity Prevention**; Food and Nutrition Board; Institute of Medicine. Glickman D, Parker L, Sim LJ, Del Valle Cook H, Miller EA, editors. Accelerating progress in obesity prevention: solving the weight of the nation. Washington (DC): National Academies Press (US), 2012

7 **World Health Organization.** Global Strategy on Diet, Physical Activity, and Health. [accessed 2014]. Available from: URL: http://www.who.int/dietphysicalactivity/childhood/en/

8 **Collins CE**, Warren JM, Neve M, McCoy P, Stokes B. Systematic review of interventions in the management of overweight and obese children which include a dietary component. *Int J Evid Based Healthc* 2007; **5**: 2-53 [PMID: 21631781 DOI: 10.1111/j.1479-6988.2007.00061]

9 **Dobbins M**, Husson H, DeCorby K, LaRocca RL. School-based physical activity programs for promoting physical activity and fitness in children and adolescents aged 6 to 18. *Cochrane Database Syst Rev* 2013; **2**: CD007651 [PMID: 23450577 DOI: 10.1002/14651858.CD007651.pub2]

10 **Lau DC**. Synopsis of the 2006 Canadian clinical practice guidelines on the management and prevention of obesity in adults and children. *CMAJ* 2007; **176**: 1103-1106 [PMID: 17420493]

11 **August GP**, Caprio S, Fennoy I, Freemark M, Kaufman FR, Lustig RH, Silverstein JH, Speiser PW, Styne DM, Montori VM. Prevention and treatment of pediatric obesity: an endocrine society clinical practice guideline based on expert opinion. *J Clin Endocrinol Metab* 2008; **93**: 4576-4599 [PMID: 18782869 DOI: 10.1210/jc.2007-2458]

12 **Trübswasser U**, Branca F. Nutrition policy is taking shape in Europe. *Public Health Nutr* 2009; **12**: 295-306 [PMID: 19210800 DOI: 10.1017/S1368980009004753]

13 **Casazza K**, Brown A, Astrup A, Bertz F, Baum C, Brown MB, Dawson J, Durant N, Dutton G, Fields DA, Fontaine KR, Heymsfield S, Levitsky D, Mehta T, Menachemi N, Newby PK, Pate R, Raynor H, Rolls BJ, Sen B, Smith DL, Thomas D, Wansink B, Allison DB. Weighing the Evidence of Common Beliefs in Obesity Research. *Crit Rev Food Sci Nutr* 2015; **55**: 2014-2053 [PMID: 24950157 DOI: 10.1080/10408398.2014.922044]

14 **Archer E**, Lavie CJ, McDonald SM, Thomas DM, Hébert JR, Taverno Ross SE, McIver KL, Malina RM, Blair SN. Maternal inactivity: 45-year trends in mothers' use of time. *Mayo Clin Proc* 2013; **88**: 1368-1377 [PMID: 24290110 DOI: 10.1016/j.mayocp.2013.09.009]

15 **Hamilton MT**, Hamilton DG, Zderic TW. Exercise physiology versus inactivity physiology: an essential concept for understanding lipoprotein lipase regulation. *Exerc Sport Sci Rev* 2004; **32**: 161-166 [PMID: 15604935 DOI: 10.2337/db07-0882]

16 **Staiano AE**, Harrington DM, Barreira TV, Katzmarzyk PT. Sitting time and cardiometabolic risk in US adults: associations by sex, race, socioeconomic status and activity level. *Br J Sports Med* 2014; **48**: 213-219 [PMID: 23981954 DOI: 10.1136/bjsports-2012-091896]

17 **Swartz AM**, Squires L, Strath SJ. Energy expenditure of interruptions to sedentary behavior. *Int J Behav Nutr Phys Act* 2011; **8**: 69 [PMID: 21708007 DOI: 10.1186/1479-5868-8-69]

18 **Zderic TW**, Hamilton MT. Physical inactivity amplifies the sensitivity of skeletal muscle to the lipid-induced downregulation of lipoprotein lipase activity. *J Appl Physiol* (1985) 2006; **100**: 249-257 [PMID: 16195388 DOI: 10.1152/japplphysiol.00925.2005]

19 **Spalding KL**, Arner E, Westermark PO, Bernard S, Buchholz BA, Bergmann O, Blomqvist L, Hoffstedt J, Näslund E, Britton T, Concha H, Hassan M, Rydén M, Frisén J, Arner P. Dynamics of fat cell turnover in humans. *Nature* 2008; **453**: 783-787 [PMID: 18454136 DOI: 10.1038/nature06902]

20 **Chakravarthy MV**, Booth FW. Eating, exercise, and "thrifty" genotypes: connecting the dots toward an evolutionary understanding of modern chronic diseases. *J Appl Physiol* (1985) 2004; **96**: 3-10 [PMID: 14660491 DOI: 10.1152/japplphysiol.00757.2003]

21 **Maher C**, Olds T, Mire E, Katzmarzyk PT. Reconsidering the sedentary behaviour paradigm. *PLoS One* 2014; **9**: e86403 [PMID: 24454968 DOI: 10.1371/journal.pone.0086403]

22 **Riddell MC**. The endocrine response and substrate utilization during exercise in children and adolescents. *J Appl Physiol* (1985) 2008; **105**: 725-733 [PMID: 18420724 DOI: 10.1152/japplphysiol.00031.2008]

23 **Gallo LA**, Tran M, Moritz KM, Wlodek ME. Developmental programming: variations in early growth and adult disease. *Clin Exp Pharmacol Physiol* 2013; **40**: 795-802 [PMID: 23581813 DOI: 10.1111/1440-1681.12092]

24 **Hanks LJ**, Newton AL, Casazza K. Getting to the height of the matter: the relationship between stature and adiposity in prepubertal children. *Ethn Dis* 2013; **23**: 71-76 [PMID: 23495625]

25 **Kagawa M**, Tahara Y, Moji K, Nakao R, Aoyagi K, Hills AP. Secular changes in growth among Japanese children over 100 years (1900-2000). *Asia Pac J Clin Nutr* 2011; **20**: 180-189 [PMID: 21669586]

26 **Ogden CL**, Carroll MD, Curtin LR, Lamb MM, Flegal KM. Prevalence of high body mass index in US children and adolescents, 2007-2008. *JAMA* 2010; **303**: 242-249 [PMID: 20071470 DOI: 10.1001/jama.2009.2012]

27 **Hamilton MT**, Hamilton DG, Zderic TW. Sedentary behavior as a mediator of type 2 diabetes. *Med Sport Sci* 2014; **60**: 11-26 [PMID: 25226797 DOI: 10.1159/000357332]

P- Reviewer: Sangkhathat S
S- Editor: Tian YL **L- Editor**: A **E- Editor**: Jiao XK

World Journal of Clinical Pediatrics

Submit a Manuscript: http://www.wjgnet.com/esps/
Help Desk: http://www.wjgnet.com/esps/helpdesk.aspx
DOI: 10.5409/wjcp.v4.i4.55

World J Clin Pediatr 2015 November 8; 4(4): 55-65
ISSN 2219-2808 (online)
© 2015 Baishideng Publishing Group Inc. All rights reserved.

REVIEW

Single-incision pediatric endosurgery in newborns and infants

Yury Kozlov, Vladimir Novozhilov, Polina Baradieva, Pavel Krasnov, Konstantin Kovalkov, Oliver J Muensterer

Yury Kozlov, Vladimir Novozhilov, Polina Baradieva, Pavel Krasnov, Department of Neonatal Surgery, Pediatric Hospital Irkutsk, 664009 Irkutsk, Russia

Yury Kozlov, Vladimir Novozhilov, Polina Baradieva, State Medical University Irkutsk, 664025 Irkutsk, Russia

Yury Kozlov, Vladimir Novozhilov, Polina Baradieva, Pavel Krasnov, State Medical Academy of Continuing Education Irkutsk, 664000 Irkutsk, Russia

Konstantin Kovalkov, Pediatric Hospital Kemerovo, 650056 Kemerovo, Russia

Oliver J Muensterer, Pediatric Surgery, University Medicine of the Johannes Gutenberg University, 55131 Mainz, Germany

Author contributions: All authors contributed to this manuscript.

Conflict-of-interest statement: No conflict-of-interest.

Open-Access: This article is an open-access article which was selected by an in-house editor and fully peer-reviewed by external reviewers. It is distributed in accordance with the Creative Commons Attribution Non Commercial (CC BY-NC 4.0) license, which permits others to distribute, remix, adapt, build upon this work non-commercially, and license their derivative works on different terms, provided the original work is properly cited and the use is non-commercial. See: http://creativecommons.org/licenses/by-nc/4.0/

Correspondence to: Yury Kozlov, MD, Department of Neonatal Surgery, Pediatric Hospital Irkutsk, 57 Sovetskaya Str, 664009 Irkutsk, Russia. yuriherz@hotmail.com
Telephone: +7-395-2291635
Fax: +7-395-2291566

Received: April 27, 2015
Peer-review started: April 29, 2015
First decision: May 19, 2015
Revised: September 27, 2015
Accepted: October 16, 2015
Article in press: October 19, 2015
Published online: November 8, 2015

Abstract

This study focuses on the successful application of single-incision pediatric endosurgery in the treatment of congenital anomalies and acquired diseases in neonates and infants. The purpose of this scientific review consists in highlighting the spectrum, indications, applicability, and effectiveness of single-port endosurgery in children during the first 3 postnatal months.

Key words: Laparoscopy; Neonates; Infants; Single-incision laparoscopic surgery; Single-incision pediatric endosurgery

© The Author(s) 2015. Published by Baishideng Publishing Group Inc. All rights reserved.

Core tip: Consequently, reports on a successful use of single-incision endosurgical technique in the treatment of congenital malformations and diseases in neonates and infants are still not numerous and often sporadic. Advanced skills and a high technical demand, along with the lack of specialized surgical equipment are factors limiting the popularity and availability of single-incision pediatric endosurgery (SIPES) for pediatric surgery in first 3 mo of life. However, the current body of evidence shows that a SIPES is indeed applicable in infants with outcome comparable to that of standard laparoscopy, and that it results in minimal post-operative surgical trauma and superb cosmesis.

Kozlov Y, Novozhilov V, Baradieva P, Krasnov P, Kovalkov K, Muensterer OJ. Single-incision pediatric endosurgery in newborns and infants. *World J Clin Pediatr* 2015; 4(4): 55-65 Available from: URL: http://www.wjgnet.com/2219-2808/full/v4/i4/55.htm DOI: http://dx.doi.org/10.5409/wjcp.v4.i4.55

INTRODUCTION

The success of minimally invasive surgery resulted

in significant changes of operative techniques that are mutually beneficial for the patient as well as the surgeon. The reduction of postoperative discomfort, quicker recovery, and improved cosmetic results became ubiquitously known advantages of laparoscopic surgery. Laparoscopy and thoracoscopy have further evolved with the purpose of making the operation virtually scarless. The first single-incision endosurgical intervention was a tubal ligation performed by Wheeless[1] in 1969. In the early nineteen nineties, Pelosi *et al*[2] described the first single-incision laparoscopic appendectomy. A few years later, the first transumbilical endoscopic appendectomy was performed in a child[3]. Single-site laparoscopic surgery developed in parallel to the idea of performing endoscopic surgery entirely *via* natural orifices [so-called natural orifice transluminal endoscopic surgery (NOTES)] and appeared as an alternative to conventional, multi-port laparoscopy. NOTES involves extensive investment in expensive specialized equipment, and involves the risk of intra-abdominal infection due to access into the abdominal cavity *via* a usually colonized hollow viscus. To solve this problem, surgeons began using a natural embryonic orifice - the umbilicus - as a "door" to the abdominal cavity, giving rise to the development of single-incision endosurgery. Just a few years ago, single-port surgery has been limited to routine operations, including appendectomy and cholecystectomy. Later, a variety of innovative methods were developed on the basis of complex endosurgical procedures that include nephrectomy, splenectomy, adrenalectomy and intestinal resection and subsequent intracorporeal anastomoses[4-7]. In children, the procedure was coined single-incision pediatric endosurgery or single-incision pediatric endosurgery (SIPES). SIPES is an alternative to triangulated multiport laparoscopy in the surgical therapy of a spectrum of entities. Despite an extensive use of single-incision endosurgery in adult patients, the implementation of this type of surgery for treating children was somewhat slower. A possible explanation is that pediatric minimally invasive techniques have historically lacked behind those of adults. Size-appropriate laparoscopic instrumentation for infants and children has been produced only by select companies due to the smaller potential market share and profit margins.

TERMINOLOGY AND DEFINITION

Currently, single-incision endosurgery is defined as minimally invasive surgery performed *via* a single incision in the abdomen, chest, or retroperitoneal space (Figure 1). Many terms have been used to describe this approach: The term Single-incision laparoscopic surgery (SILS™) is quite prevalent, but has been trademarked by a large device company. To avoid any conflicts of interest, we generally avoid it. One-port umbilical surgery[8], transumbilical endoscopic surgery[9], embryonic natural orifice transumbilical endoscopic surgery[10] have been proposed. Other abbreviations are single-port access (SPA), laparoendoscopic single-site, single laparoscopic-incision transumbilical surgery. Nevertheless, many pediatric surgeons prefer of the abbreviation SIPES[11,12] since this term comprises all laparoscopy, thoracoscopy, and retroperitoneoscopy performed in children by means of a single incision. It also is a clear statement that this type of surgery indeed is performed in children, and that device companies should make an effort to develop size-appropriate equipment for this special application.

Single-port endosurgery was employed in infants much later than in older children. This lag appeared due to misconceptions of surgeons concerning the fact that miniature but visible scars left after conventional pediatric laparoscopy, were perfectly acceptable for patients as well as for their parents. However, scars grow proportionally along with the individual, so that even small scars in infancy may translate into larger ones visible later in life. Moreover, some surgeons were very concerned about compromised maneuverability of endosurgical instruments in a small abdomen of neonates and infants. Despite this concern, pediatric surgeons explored surgical procedures in which SIPES may provide advantages superior to those of multiport access in infants. Soon enough, gastrostomy in children placed *via* a single access was proposed and compared favorably with the three-port technique[13].

Several pediatric surgical centers that use modern laparoscopy showed interest in SIPES and promptly expanded surgical indications for it. Over the last decade, this technique was applied for many new indications (Table 1). Despite the growing popularity of SIPES, it is still not widely used in the newborn and infant population[14-27]. Ponsky *et al*[28], in one of their first scientific reviews, rejected in the strongest terms a capability to perform single-port surgery in children in the first three months of life. The number of scientific publications on the application of SIPES in this age group remains small and mostly devoted to a narrow circle of diseases where single-port surgery has demonstrated its effectiveness. A recent systematic review[29] analyzed all publications of the National Library of Medicine and National Institutes of Health on the website http://www.ncbi.nlm.nih.gov.pubmed, appeared before March 2012 and related to single-incision endosurgery in children. The study identified only 99 neonates among the 4212 pediatric patients. Children in the first month of life mostly underwent operations for congenital pyloric stenosis, Hirschsprung disease, ovarian cysts, inguinal hernias and ventriculoperitoneal shunt placements.

APPLICATION OF SIPES IN SMALL BABIES

Consequently, reports on a successful use of single-incision endosurgical technique in the treatment of congenital malformations and diseases in neonates and infants are still not numerous and often sporadic. We have limited data on possible areas of application

Table 1 Indications for single-incision pediatric endosurgery

Indication	Year introduced	Comments
Inguinal herniorrhaphy[14]	2006	No intraoperative complications. Recurrence rate 0.73% in 711 children
Pyeloplasty[15]	2007	One small anastomotic leak that closed spontaneously occurred in 16 cases
Meckel diverticulectomy[16]	2008	Single-incision approach was faster than multitrocar laparoscopy
Nephrectomy[17,18]	2009, 2010	Independent case reports, technically feasible
Splenectomy[19,20]	2009, 2010	Extraction of the spleen facilitated by a larger single incision compared to standard laparoscopic surgery
Pyloromyotomy[11,12]	2010, 2011	Crossing instruments and stabilizing the antrum rather than the duodenum associated with fewer complications
Orchidopexy[21]	2010	Case report, feasible
Morgagni diaphragmatic hernia repair[22]	2010	Case report, intracorporal knot tying challenging
Fundoplication[23]	2011	SIPES intracorporal suturing is technically demanding. Several alternative techniques available
Hepaticojejunostomy[24]	2012	One bile leak early in the series of 19 patients. Two conversions to multiport laparoscopy. Operative time, length of stay, other outcome parameters same as conventional laparoscopy
Ventriculoperitoneal shunt placement[25]	2011	Successful placement of the distal shunt limb in a series of 5 patients
Total colectomy[26,27]	2011, 2012	Results similar to those after open and multiport laparoscopic surgery

SIPES: Single-incision pediatric endosurgery.

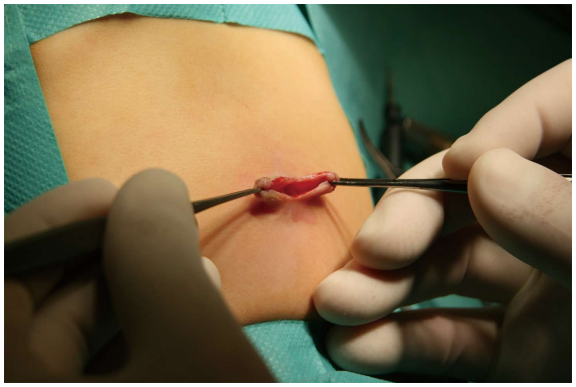

Figure 1 Creation of single umbilical incision.

of SIPES and weak evidence of its prevalence among infant populations.

Inguinal herniorrhaphy

Over the last decade single-port techniques for laparoscopic inguinal hernia repair were developed. Currently, the literature contains a limited number of reports on single-port laparoscopic surgery in neonates and infants with inguinal hernia[19,30-32].

A variety of SIPES procedures has been described, mostly including atransperitoneal dissection and percutaneous ligature without direct manipulation. Methods including LPEC[33], SEAL[34] and PIRS[35] perform the extraperitoneal ligation of the hernia sac under laparoscopic vision devoid of additional ports. These methods have specific drawbacks, however. For instance, the LPEC method (Laparoscopic Percutaneous Extraperitoneal Closure) as described by some authors requires the use of special LPEC-needle, which is not approved surgery in premature and low birth weight children. Other authors have described the use of a spinal (Touhy) needle for the dissection, an item that is widely available in most hospitals[36,37].

While using the PIRS method (percutaneous internal ring suturing), closure of the internal inguinal ringis incomplete, since the parts of the peritoneum over the spermatic cord and spermatic vessels are generally spared. Theoretically, the rate of recurrence and hydrocele formation may therefore be higher after these interventions. The SEAL method implies type of extraperitoneal hernia repair in babies without the need for special devices. In this technique a large-diameter needle is driven around the internal inguinal ring, throught the skin at another location, and in a retrograde fashion through the initial skin incision (Figure 2). SEAL allows a complete peritoneal hernia sac closure, possibly decreasing the risk of hydrocele formation[36]. Currently, there are only a few comparative studies of single-port and multi-port laparoscopic methods for pediatric inguinal hernia repair[37,38]. The Russian study[37] shows that periopioperative results of single-port herniorrhaphy are similar to those of the multi-port approach. The Indian study[38] compared results of the two discussed methods of endoscopic treatment of inguinal hernias and found superiority of the single-port laparoscopic method in the form of reduced operation time (15 min *vs* 25 min in cases of unilateral localization). This study, however, confers grave limitations in that the control group and the intervention group were subjected to different techniques of herniorrhaphy - extracorporeal and intracorporeal, respectively. This may explain the lack of superiority of the single-port approach. Both studies demonstrate the one main advantage of single-incision laparoscopic method - the impeccable cosmesis, dut to the hidden scar in the navel.

Pyloromyotomy

The first single-port pyloromyotomy without a use of special equipment or instruments was performed in Birmingham, Alabama[11]. The operation was completed through multiple puncture holes in the abdominal fascia

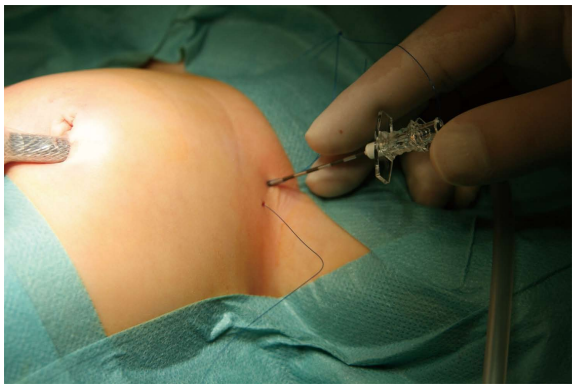

Figure 2 Position of the endoscope and Tuohy needle during subcutaneous endoscopically assisted ligation inguinal herniorrhaphy.

after the umbilical skin incision was stretched. Perforation of gastric mucosa occurred in 3.2% of cases, and SIPES was converted into a three-port laparoscopy in 4.7% of cases. As a result, the authors assumed that SIPES pyloromyotomy is feasible, but a demonstration of its safety is still under an investigation due to a high number of perforations. Since presenting their initial results, the group has changed to a cross-technique single-incision pyloromyotomy, with no further mucosal perforations so far[12]. Another group of patients[39] contained 12 patients who underwent a SIPES pyloromyotomy. That comparative study found no significant difference in operative time or length of hospitalization, as well as an uncomplicated postoperative course in the SIPES group.

Nephrectomy

A single-port laparoscopic approach for nephrectomy is not widely used in newborns and infants. Primarily, this is due to the fact that the majority of pediatric surgeons are satisfied with the cosmetic results of the multi-port endoscopic techniques. Another explanation of this phenomenon is the lack of technology and practical skills to implement SIPES in small babies. Park *et al*[17] and Johnson *et al*[40] were the first, who reported on single-incision nephrectomy in children. Publications regarding this method of nephrectomy in infants are considerably rare and limited by low case numbers[41-44]. These case series, which included 4 to 11 pediatric patients, demonstrated the possibility of removing a kidney laparoscopically through a single incision. The lowest average weight and age of patients in these scientific reports was 10.6 kg and 12 mo, respectively[44].

Nissen fundoplication

The largest series of truly single-incision laparoscopic fundoplications in children was published in 2011 and consisted of 3 infants[23]. Despite the limited number of patients and the inconsistent techniques employed, this study highlights many important aspects, challenges, and solutions of SIPES Nissen fundoplication. For one, the dissection phase of the operation is easily accomplished, whereas the reconstruction part can be quite difficult. Suturing with instruments in parallel alignment turned out to be the most complex task of the operation. The authors concluded that the so-called "Magic Wand technique" was the quickest way of tying the knots. Liver retraction during single-incision laparoscopic fundoplication is problematic. In this series, a dynamic grasper was used to hold the liver away when necessary in some cases. In the remainder, a 2-mm trocarless instrument (Mini-Lap Technologies Inc., Dobbs Ferry, NY) was passed under the liver and anchored in the diaphragm above the hiatus, suspending the liver on its shaft. At this time, the advantages of performing SIPES over conventional laparoscopic Nissen fundoplication are mainly cosmetic in nature. The benefit of virtually scarless surgery in neurologically impaired children who also require a gastrostomy is at least debatable.

Ovarian cystectomy

The relative proximity of the ovaries of newborn to the umbilical region became the object of attention of surgeons practicing single-port endoscopic techniques[45-50]. This approach allowed the surgeons to extract and resect pathological ovarian tissue through one incision made in the umbilical ring. The use of such technical innovations as transparietal aspiration and subsequent extraction of the cyst through a single but larger umbilical incision, provide the surgeon with a quick and comfortable means to remove pathological tissue from the ovaries. Ovarian cystectomy is the most common SIPES procedure reported and has been performed in patients in infancy. Prospective studies are required to demonstrate SIPES benefits in pediatric gynecology.

Other procedures

Only one report demonstrates the use of SIPES for endorectal pull-through for Hirschsprung disease in infants[51]. Though the procedure is technically complex, as it turned out, it can be safely performed with good postoperative results and without complications. Later, publications appeared on individual cases of duodenal web resection in patients with duodenal atresia[52], and resection of a NEC stricture in a premature infant[53].

ACCESS DEVICES

In the beginning of the SIPES era, there was a lack of proper tools to provide access to the abdominal cavity in infants. Enthusiastic pediatric surgeons looked for new methods and put innovative ideas into life. Originally, as an alternative to currently known port systems, they used homemade devices[17,54]. The use of surgical gloves (Glove port), introduced through, was one of the examples. Every finger of the glove was used for a individual laparoscopic tools[55]. The increasing demand for an optimal platform for SPA has led to a large number of inventions of multichannel devices such as

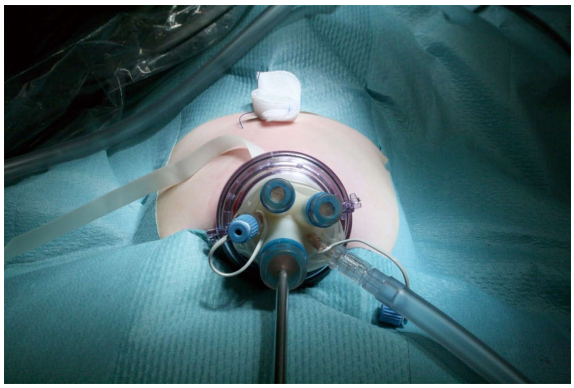

Figure 3 Placement TriPort single-port device (Advanced Surgical Concepts, Olympus, Japan) into abdominal cavity.

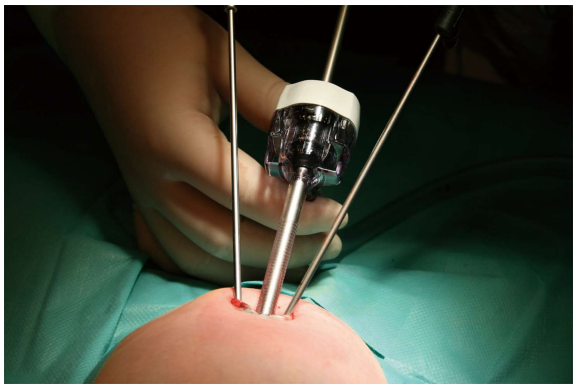

Figure 4 Installation of laparoscopic instruments through fascial wounds without a use of trocars.

the X-Cone, S-Cone and EndoCone (Karl Storz GmbH, Germany), KeyPort (Richard Wolf GmbH, Germany), TriPort and QuadPort (Advanced Surgical Concepts, Olympus, Japan), SILS-port (Covidien Inc., Switzerland), Uni-X (Pnavel Systems, United States), AirSeal (Surgi-Quest, United States), GelPort (Applied Medical, United States). However, none are particularly suitable in newborns or infants. The idea of an introducing multiple instruments through a single device was appreciated by specialists dealing with a single-port surgery[56-61]. However, a generally large size of the multiport systems, which may require a 2-3 cm fascial incision, often restricts a use in small children. Rothenberg *et al*[62] reported on a use of a special device for the performing of SIPES cholecystectomy. The technique of S. Rothenberg involved the use of an operating laparoscope with an accessory channel through which was introduced a single working tool. However, such devices for the performing of SIPES also did not gain widespread popularity in children, mostly due to their large diameter. The only exception to the above-mentioned multichannel systems are those that rely on a ringed "sleeve" such as the TriPort or QuadPort devices (Advanced Surgical Concepts, Olympus, Japan), or the GelPoint (Applied Medical, United States), which require only a 1.5 cm fascial incision, feasible even in neonates

Figure 5 Laparoscopic instruments for single-incision pediatric endosurgery - a 5 mm endoscope with a length of 45 cm and 3 mm instruments with different lengths (20 and 30 cm).

(Figure 3). Soon after the invention of multiport devices, the access to the abdominal cavity was achieved using several three to five millimeter trocars introduced individual, closely-spaced umbilical access points. That is the technique commonly used nowadays in young patients (Figure 4). When a working space is limited, for instance in infants, laparoscopic instruments are installed directly through the fascia without a use of trocars[63]. As expected, the leak of carbon dioxide became more significant using this technique[64]. However, an increased risk of postoperative umbilical hernias as a result of the "Swiss cheese" effect resulting from placing multiple trocars through the fascia in one are was not confirmed in studies[65-68].

Having considered the technical aspects of single-port technique, there are some peculiarities for its application in young children. Some authors found that the majority of SIPES operations in infants, in fact, could be done without the use of expensive proprietary multi-port systems. Placement of separate laparoscopic trocars through a single-incision provides good ergonomics and excellent cosmetic results, at no additional costs necessary for the purchase of multi-port systems[69]. Furthermore, long telescopes, instruments with a different working length (Figure 5), transparietal stitches, and a crossed manipulation system allows surgeons to perform surgical maneuvers and to avoid a collision of instruments, were all beneficial.

INSTRUMENTS AND TECHNIQUES OF MANIPULATION

Just as there are no special devices for umbilical access made specifically for small children, the available selection of instruments for SIPES in small children is limited. The lack of triangulation of instruments is a major hurdle to SIPES. To overcome these inconveniences, Hansen E made a point of using different length graspers, separating the working hands along the Z-axis. This avoids collision of the surgeon's hands and instrument handles that result from employing the

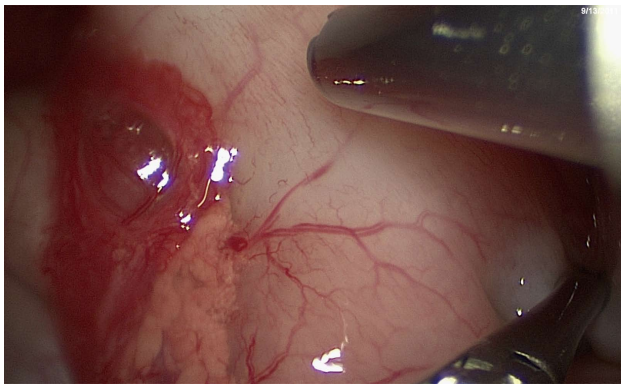

Figure 6 The technique of the "cross-handed" manipulation (cross instrumentation) during pyloromyotomy.

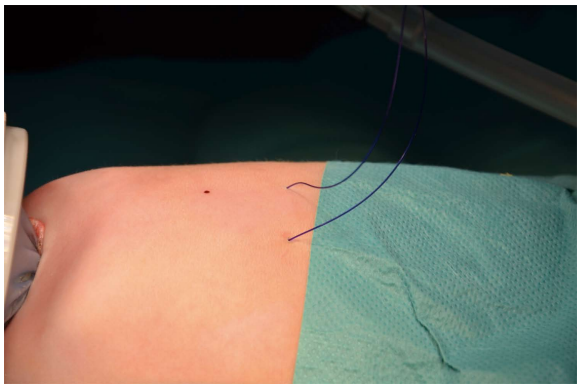

Figure 7 Transparietal stich sutured around the ligamentum teres hepatis.

usual, nonbent laparoscopic devices[64]. New instruments with a flexible distal part, or a so-called "reticulation", have an advantage in terms of their ability to avoid collision[70]. Unfortunately, the use of these modern devices is limited, since their cost is high, and application in small children is precluded by their large size.

The technique of the "cross-handed" manipulation (cross-instrumentation), proposed by Hansen *et al*[64] in 2011, gained popularity in young children due to an absence of special instruments (Figure 6). Also, to ensure the retraction of internal organs, some surgeons place an additional 2 mm diameter grasper through the abdominal wall (MiniLap, Stryker, United States)[71]. Whether this is still "single" incision laparoscopy is open to debate. A group from Argentina, led by Padilla *et al*[26], designed and manufactured mini alligator-graspers connected to a strong magnet. They were placed into the abdominal cavity at the beginning of the case, placed on the tissue to be retracted, and managed from the outside by an external sterile magnet on the surgical field. These magnet-graspers can retract abdominal organs and thereby augment the working space.

Together with above-mentioned devices for retraction, many surgeons also have started to apply transparietal stitches to fix internal organs. There are several types of such stitches described, and they are especially applicable in neonates and infants. Some of them are sutured around the ligamentum teres hepatis (Figure 7) to elevate the liver and provide access to the pylorus or to the gastroesophageal junction[64]. Others bite the seromuscular layer of hollow organs and are intended to stabilize the stomach, parts of intestine, gallbladder[63,72]. Finally, telescopes underwent further evolution. Many surgeons use laparoscopes with a length of 45-50 cm. This allows better visualization and spatial separation between the surgeon and the assistant[28].

TISSUE DIVISION

Modern minimally invasive surgery relies on innovative means of a tissue dissection. These comprise the traditional mechanical and physical ways using "cold" steel instruments along with the more advanced types of energy - high frequency, ultrasound, laser. The application of an endoscopic knife or scissors has limited application for neonates and infants and usually is employed for standard procedures - pyloromyotomy, pyeloplasty, duodenal anastomosis[11,12,73,74].

An ideal dissector and coagulator for patients of all ages does not exist. Application of a certain type of energy may be effective in adults and older children, but it may be dangerous or undesirable in small babies. Advanced energy cutting tools either use monopolar or bipolar coagulation. Monopolar tissue dissection is more commonly used in infants, because the energy of a monopolar source is sufficient enough for the delicate dissection of small diameter vessels. A 3 mm diameter monopolar hook is an ideal dissection device in an infant. Bipolar coagulation has the advantage that the current flows only through the target tissue and not the entire body of the patient. However, it is usually delivered through a clamp, mostly of 5 mm diameter or more.

In infants, tissue dissection is mostly achieved by the "pull and coagulate" principle[66]. It entails the combination of traction and countertraction of the tissue placed between two endoscopic clamps. One often, an atraumatic clamp such as the "duckbill" is employed. In the authors experience, the tissue is fixed and held with the left hand. The right hand grasps an endoscopic Kelly- or Maryland-type grasper connected to the monopolar electrosurgical source, and is used to dissect and coagulate the tissues of the patient under traction. This setup minimizes the time necessary for dissection of the tissues, and provides complete control over bleeding. In case of an intraoperative hemorrhage, having two clamps simultaneously in the abdomen allows the surgeon to stop it immediately by mechanical compression and to coagulate it with the monopolar clamp without changing tools.

The limits of bipolar dissection and coagulation in children of the first three months of life are surgical interventions requiring extensive tissue dissection, operations on parenchymal organs, and those procedures

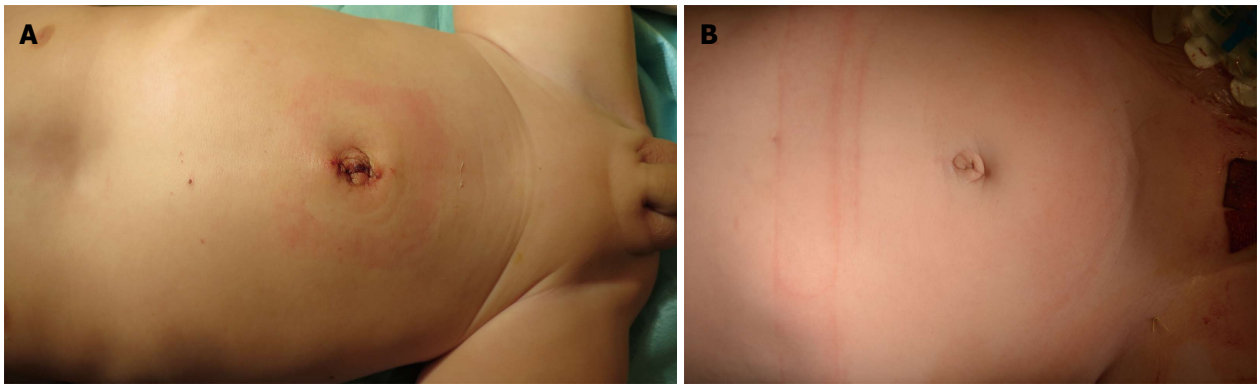

Figure 8 Cosmetic result. A: Cosmetic result after 7 d from a single-incision laparoscopic right nephrectomy; B: Cosmetic result after 1 mo from a single-incision laparoscopic right nephrectomy (same patient).

with a need of alloying vessels of big diameter - short gastric vessels, renal and suprarenal arteries and veins. The ultrasound dissector (Harmonic scalpel, Ethicon, United States) and BiClamp technology (ERBE, Germany) are the energy resources usually used for performing SIPES in infants. These devices simplify dissection of tissue planes and reduce the lateral thermal damage on adjacent tissues[28,75]. The unique design of the BiClamp allows very exact manipulations in the limited spaces of an infant body. The other benefit of this tool is the possibility of resterilization.

SUTURING

Suturing in parallel alignment turns out to be extremely challenging. Different SIPES approaches for intracorporal suturing have been[23]. In the "Magic Wand technique", the needle is grasped by the tip and used as an angulation device that helps wrap the suture around the tip of the counterinstrument. Extracorporeal knot tying is an attractive alternative for those that want to avoid the difficulties of intracorporal suturing in parallel. The "Spaghetti technique" can be performed using just one instrument, which grasps the suture close to, but not quite at the needle. The surgeon then twists the instrument around its axis so that the suture wraps around the shaft like around a fork loading up on spaghetti. After the wrapping, the instrument opens and grasps the free suture end, pulling it through the loops while the other instrument provides countertraction. Automatic suturing devices such as the Ti-knot (LSI Solutions, New York, United States) secure the suture by a metal clamp.

ADVANTAGES OF SIPES

Disputes over SIPES still exist and mainly focus on the fact that many surgical interventions are much more difficult to perform through a single access site[24,69]. Also, it has not been shown so far that single-port techniques are safer or more effective than standard laparoscopy. In addition, the aesthetic advantage has not been evaluated objectively and the "improved cosmetic result" remains a subjective outcome.

There is no doubt that a better cosmesis is the primary advantage of SIPES, which uses the umbilicus as a "keyhole" to hide the postoperative scar (Figure 8). An umbilical incision is also valuable since it can easily be converted into a multiport laparoscopy or into an extended umbilical incision, for example, for "hybrid" operations that combine principles of laparoscopic and open surgery.

Currently, there is no clear advantage of SIPES over the other methods due to a weak level of evidences in most publications, except for reports on single-port appendectomy and cholecystectomy. There are odd bits of information concerning the children of older age groups, which are discrepant.

POSTOPERATIVE PAIN

Initially, Chandler *et al*[76] reported on a decrease in the need for intravenous drugs after SIPES appendectomy in comparison with conventional multiport laparoscopy performed on 110 children. However, in 2011 St Peter *et al*[77] found the opposite - patients require more analgesia during their hospital stay after a single-port appendectomy in comparison to those who underwent conventional laparoscopic appendectomy. The postoperative length of children's hospital stay after the cholecystectomy was equal to that of a standard single-port laparoscopy[78]. However, a recent study of patients, who underwent single-incision endosurgical cholecystectomy, showed that they had a lower level of postoperative pain and required less analgesics than patients that underwent a multiport endoscopy. The same study also showed a reduction of the length of hospital stay[79].

As soon as special equipment is required, SIPES becomes less profitable. Some of the special instruments and proprietary multi-ports significantly increase expenses of these operations. Though experienced surgeons have used conventional laparoscopic instruments for SIPES, and have comparable results with

regard to operative time, it must be noted that the learning curve of these techniques is quite long and requires at least 40 cases to reach a plateau[80,81].

A definitive advantage of SIPES *vs* conventional laparoscopic surgery becomes apparent when ablative procedures are performed. It is much easier to extract a large Spleen or even a gallbladder full of stones through a single 2 cm incision than it is to do it through a 5 or even 10 mm trocar site. The other advantage is that a finger can be inserted through the larger single umbilical access site, allowing the surgeon to obtain tactile information, something impossible through several 3, 5, or even 10 mm incisions. Therefore, SIPES may be an ideal technique for ablative and oncologic indications.

COMPLICATIONS AND CONVERSIONS

Rare complications after application SIPES in neonates and infants have been reported in the literature, including intestinal perforation, trauma of adjacent organs, and wound infection[64]. In the first series of single-port pyloromyotomy, the complication rate was 6%, including perforations of the pyloric mucosa and duodenal mucosa. Although the perforations were immediately recognized, repaired, and the patients suffered no postoperative sequelae, the relatively high perforation rates prompted the authors to change their technique to the cross-technique instead.

Initial reports also raised concern over an increasing risk of wound infections after SIPES. However, later studies showed a decrease of the wound infection rate, corresponding to increased experience in handling tissues around the navel. Studies have shown that the wound infection rate (2.3%) did not differ from that of the conventional laparoscopic procedures[77]. Another concern is the possibility that a large umbilical incision may theoretically increase the risk of postoperative umbilical hernia. However, cases of this complication were not found in the existing literature.

There is no consensus in the literature concerning the definition of "conversion" in SIPES. Analyzing the available publications, it has been defined as[28,68]: (1) a need to use one or more additional ports to complete single-port procedure; or (2) a switch to the open surgery. Conversion to conventional laparoscopy or placement of additional trocarss should not be considered a failure of SIPES. A surgeon must not endanger the patient safety, must use sane judgment, and add ports as necessary. Ponsky *et al*[28] reported their experience of more than 70 cases of SIPES in children. They reported on an acceptable level of conversions to standard laparoscopy and few perioperative complications. In other studies, including that of older children, SIPES results were similar to those of conventional laparoscopic procedures, with a conversion rate of 2%-11%[63,68,76,82-84].

CONCLUSION

General interest in the umbilical ring as a "keyhole" for single-incision access to the abdominal cavity organs, has promoted the development of modern endoscopic surgery towards the development of a "stealth" techniques, those that leave no visible scar behind. We believe that SIPES, despite its initial success, still has huge obstacles to overcome in order to be recognized as a universal, standard surgical approach in children in the first 3 mo of life. Modern laparoscopic instruments of a small diameter with multidirectional reticulation and abilities to move in several planes may soon let pediatric surgeons perform complex laparoscopic procedures more efficiently. With their introduction, the limited triangulation and reduced degrees of freedom will no longer be a problem. Moreover, in the near future one could expect the introduction of single-incision port devices that are more appropriate for small children. Advanced skills and a high technical demand, along with the lack of specialized surgical equipment are factors limiting the popularity and availability of SIPES for pediatric surgery in first 3 mo of life. However, the current body of evidence shows that a SIPES is indeed applicable in infants with outcome comparable to that of standard laparoscopy, and that it results in minimal post-operative surgical trauma and superb cosmesis.

Summarizing our review, we conclude that: (1) The current experience with SIPES in children in first 3 mo of life shows good outcomes, few complications, and a low conversion rate; (2) Special costly proprietary devices and instruments are not required to perform SIPES; (3) Most surgeons perform these procedures with conventional laparoscopic instruments, standard energy devices, and some have improvised to build their own low-cost access ports; (4) Superb postoperative long-term cosmesis is the biggest advantage of the SIPES, although there is no objective evaluation of this in the literature so far studies comparing the cosmetic outcome should be performed in the future; and (5) Most endoscopic surgeons that practice SIPES believe that it is an evolutionary continuation of traditional laparoscopy. However, the prospective controlled studies must be performed to determine the real advantages of this novel approach.

Although we have made every effort to include all relevant studies in our review on SIPES in the newborn and infant, it must be remembered that published data on the subject at this time is insufficient to perform a formal meta-analysis. Most publications at this time are case series or retrospective analyses. A well-defined control group is mostly absent. Therefore, formal scientific scrutiny of SIPES techniques in infants at this time is limited. We encourage pediatric surgeons to prospectively evaluate their results with SIPES interventions in the future.

Despite these recognized limitations, our review highlights the immense creative potential of pediatric surgeons in search for less invasive methods, which might eventually develop and turn SIPES into a preferred method for endosurgical operations in infants and children.

REFERENCES

1 **Wheeless CR**. A rapid, inexpensive and effective method of surgical sterilization by laparoscopy. *J Reprod Med* 1969; **3**: 65-96

2 **Pelosi MA**, Pelosi MA. Laparoscopic appendectomy using a single umbilical puncture (minilaparoscopy). *J Reprod Med* 1992; **37**: 588-594 [PMID: 1387906]

3 **Esposito C**. One-trocar appendectomy in pediatric surgery. *Surg Endosc* 1998; **12**: 177-178 [PMID: 9479738 DOI: 10.1007/s004649900624]

4 **Desai MM**, Rao PP, Aron M, Pascal-Haber G, Desai MR, Mishra S, Kaouk JH, Gill IS. Scarless single port transumbilical nephrectomy and pyeloplasty: first clinical report. *BJU Int* 2008; **101**: 83-88 [PMID: 18086101 DOI: 10.1111/j.1464-410X.2007.07359.x]

5 **Kaouk JH**, Palmer JS. Single-port laparoscopic surgery: initial experience in children for varicocelectomy. *BJU Int* 2008; **102**: 97-99 [PMID: 18325060 DOI: 10.1111/j.1464-410X.2008.07584.x]

6 **Podolsky ER**, Curcillo PG. Single port access (SPA) surgery--a 24-month experience. *J Gastrointest Surg* 2010; **14**: 759-767 [PMID: 20155330 DOI: 10.1007/s11605-009-1081-6]

7 **Morales-Conde S**, Moreno JG, Gómez JC, Socas M, Barranco A, Alarcón I, Casado M, Cadet JM, Martín-Cartes J. Total intracorporeal anastomosis during single-port laparoscopic right hemicolectomy for carcinoma of colon: a new step forward. *Surg Innov* 2010; **17**: 226-228 [PMID: 20542952 DOI: 10.1177/1553350610372378]

8 **Rané A**, Rao P, Rao P. Single-port-access nephrectomy and other laparoscopic urologic procedures using a novel laparoscopic port (R-port). *Urology* 2008; **72**: 260-263; discussion 263-264 [PMID: 18468664 DOI: 10.1016/j.urology.2008.01.078]

9 **Zhu JF**, Hu H, Ma YZ, Xu MZ, Li F. Transumbilical endoscopic surgery: a preliminary clinical report. *Surg Endosc* 2009; **23**: 813-817 [PMID: 18649097 DOI: 10.1007/s00464-008-0086-7]

10 **Gill IS**, Canes D, Aron M, Haber GP, Goldfarb DA, Flechner S, Desai MR, Kaouk JH, Desai MM. Single port transumbilical (E-NOTES) donor nephrectomy. *J Urol* 2008; **180**: 637-641; discussion 641 [PMID: 18554653 DOI: 10.1016/j.juro.2008.04.028]

11 **Muensterer OJ**, Adibe OO, Harmon CM, Chong A, Hansen EN, Bartle D, Georgeson KE. Single-incision laparoscopic pyloromyotomy: initial experience. *Surg Endosc* 2010; **24**: 1589-1593 [PMID: 20033707 DOI: 10.1007/s00464-009-0816-5]

12 **Muensterer OJ**, Chong AJ, Georgeson KE, Harmon CM. The Cross-technique for single-incision pediatric endosurgical pyloromyotomy. *Surg Endosc* 2011; **25**: 3414-3418 [PMID: 21487868 DOI: 10.1007/s00464-011-1677-2]

13 **Ponsky TA**, Lukish JR. Single site laparoscopic gastrostomy with a 4-mm bronchoscopic optical grasper. *J Pediatr Surg* 2008; **43**: 412-414 [PMID: 18280304 DOI: 10.1016/j.jpedsurg.2007.11.009]

14 **Takehara H**, Yakabe S, Kameoka K. Laparoscopic percutaneous extraperitoneal closure for inguinal hernia in children: clinical outcome of 972 repairs done in 3 pediatric surgical institutions. *J Pediatr Surg* 2006; **41**: 1999-2003 [PMID: 17161191 DOI: 10.1016/j.jpedsurg.2006.08.032]

15 **Lima M**, Tursini S, Ruggeri G, Gargano T, Libri M, Domini M. One trocar assisted pyeloplasty (OTAP): initial experience and codification of a technique. *Pediatr Med Chir* 2007; **29**: 108-111 [PMID: 17461099]

16 **Clark JM**, Koontz CS, Smith LA, Kelley JE**.** Video-assisted transumbilical Meckel's diverticulectomy in children. *Am Surg* 2008; **74**: 327-329 [PMID: 18453298]

17 **Park YH**, Kang MY, Jeong MS, Choi H, Kim HH. Laparoendoscopic single-site nephrectomy using a homemade single-port device for single-system ectopic ureter in a child: initial case report. *J Endourol* 2009; **23**: 833-835 [PMID: 19397431 DOI: 10.1089/end.2009.0025]

18 **Wong KK**, Chung PH, Lan LC, Chan IH, Tam PK. The first report of a single-port laparoscopic nephrectomy in a child. *Hong Kong Med J* 2010; **16**: 153-154 [PMID: 20354253]

19 **Dutta S**. Early experience with single incision laparoscopic surgery: eliminating the scar from abdominal operations. *J Pediatr Surg* 2009; **44**: 1741-1745 [PMID: 19735818 DOI: 10.1016/j.jpedsurg.2008.12.024]

20 **Hansen EN**, Muensterer OJ. Single incision laparoscopic splenectomy in a 5-year-old with hereditary spherocytosis. *JSLS* 2010; **14**: 286-288 [PMID: 20932387 DOI: 10.4293/108680810X12785289144809]

21 **Raju GA**, Norris RD, Su RR, Docimo SG. Single-site laparoscopic orchidopexy in an infant. *Urology* 2010; **76**: 143-144 [PMID: 20303149 DOI: 10.1016/j.urology.2009.12.046]

22 **Danielson PD**, Chandler NM. Single-port laparoscopic repair of a Morgagni diaphragmatic hernia in a pediatric patient: advancement in single-port technology allows effective intracorporeal suturing. *J Pediatr Surg* 2010; **45**: E21-E24 [PMID: 20223304 DOI: 10.1016/j.jpedsurg.2009.12.029]

23 **Muensterer OJ**, Perger L, Hansen EN, Lacher M, Harmon CM. Single-incision pediatric endosurgical Nissen fundoplication. *J Laparoendosc Adv Surg Tech A* 2011; **21**: 641-645 [PMID: 21443443 DOI: 10.1089/lap.2010.0524]

24 **Diao M**, Li L, Dong N, Li Q, Cheng W. Single-incision laparoscopic Roux-en-Y hepaticojejunostomy using conventional instruments for children with choledochal cysts. *Surg Endosc* 2012; **26**: 1784-1790 [PMID: 22207309 DOI: 10.1007/s00464-011-2110-6]

25 **Tormenti MJ**, Adamo MA, Prince JM, Kane TD, Spinks TJ. Single-incision laparoscopic transumbilical shunt placement. *J Neurosurg Pediatr* 2011; **8**: 390-393 [PMID: 21961546 DOI: 10.3171/2011.7.PEDS115]

26 **Padilla BE**, Dominguez G, Millan C, Martinez-Ferro M. The use of magnets with single-site umbilical laparoscopic surgery. *Semin Pediatr Surg* 2011; **20**: 224-231 [PMID: 21968159 DOI: 10.1053/j.sempedsurg.2011.05.007]

27 **Potter DD**, Tung J, Faubion WA, Moir C. Single-incision laparoscopic colon and rectal surgery for pediatric inflammatory bowel disease and polyposis syndromes. *J Laparoendosc Adv Surg Tech A* 2012; **22**: 203-207 [PMID: 22047143 DOI: 10.1089/lap.2011.0117]

28 **Ponsky TA**, Diluciano J, Chwals W, Parry R, Boulanger S. Early experience with single-port laparoscopic surgery in children. *J Laparoendosc Adv Surg Tech A* 2009; **19**: 551-553 [PMID: 19575633 DOI: 10.1089/lap.2009.0092]

29 **Saldaña LJ**, Targarona EM. Single-incision pediatric endosurgery: a systematic review. *J Laparoendosc Adv Surg Tech A* 2013; **23**: 467-480 [PMID: 23560658 DOI: 10.1089/lap.2012.0467]

30 **Chang YT**, Lee JY, Tsai CJ, Chiu WC, Chiou CS. Preliminary experience of one-trocar laparoscopic herniorrhaphy in infants and children. *J Laparoendosc Adv Surg Tech A* 2011; **21**: 277-282 [PMID: 21254878 DOI: 10.1089/lap.2010.0132]

31 **Clarke S**. Pediatric inguinal hernia and hydrocele: an evidence-based review in the era of minimal access surgery. *J Laparoendosc Adv Surg Tech A* 2010; **20**: 305-309 [PMID: 20374016 DOI: 10.1089/lap.2010.9997]

32 **Muensterer OJ**, Georgeson KE. Multimedia manuscript: inguinal hernia repair by single-incision pediatric endosurgery (SIPES) using the hydrodissection-lasso technique. *Surg Endosc* 2011; **25**: 3438-3439 [PMID: 21638190 DOI: 10.1007/s00464-011-1713-2]

33 **Takahara H**, Ishibashi H, Satoh H, Fukuyama T, Iwata T, Tashiro S. Laparoscopic surgery for inguinal lesions of pediatric patients. In: Proceedings of 7th World Congress of Endoscopic Surgery. Singapore, 2000: 537-541

34 **Ozgediz D**, Roayaie K, Lee H, Nobuhara KK, Farmer DL, Bratton B, Harrison MR. Subcutaneous endoscopically assisted ligation (SEAL) of the internal ring for repair of inguinal hernias in children: report of a new technique and early results. *Surg Endosc* 2007; **21**: 1327-1331 [PMID: 17356946 DOI: 10.1007/s00464-007-9202-3]

35 **Patkowski D**, Czernik J, Chrzan R, Jaworski W, Apoznański W. Percutaneous internal ring suturing: a simple minimally invasive technique for inguinal hernia repair in children. *J Laparoendosc Adv Surg Tech A* 2006; **16**: 513-517 [PMID: 17004880 DOI: 10.1089/lap.2006.16.513]

36 **Tatekawa Y**. Laparoscopic extracorporeal ligation of hernia defects using an epidural needle and preperitoneal hydrodissection.

J Endourol 2012; **26**: 474-477 [PMID: 22168769 DOI: 10.1089/end.2011.0498]

37 **Kozlov Y**, Novozhilov V, Rasputin A, Krasnov P. Technology of single-incision laparoscopic approach in treatment of inguinal hernias in young children. *Ann Surg* 2013; **6**: 31-38 [Article in Russian]

38 **Bharathi RS**, Dabas AK, Arora M, Baskaran V. Laparoscopic ligation of internal ring-three ports versus single-port technique: are working ports necessary? *J Laparoendosc Adv Surg Tech A* 2008; **18**: 891-894 [PMID: 19105676 DOI: 10.1089/lap.2007.0246]

39 **Kozlov Y**, Novogilov V, Podkamenev A, Rasputin A, Weber I, Solovjev A, Yurkov P. Single-incision laparoscopic surgery for pyloric stenosis. *Pediatr Surg Int* 2012; **28**: 347-350 [PMID: 22179488 DOI: 10.1007/s00383-011-3029-7]

40 **Johnson KC**, Cha DY, DaJusta DG, Barone JG, Ankem MK. Pediatric single-port-access nephrectomy for a multicystic, dysplastic kidney. *J Pediatr Urol* 2009; **5**: 402-404 [PMID: 19403335 DOI: 10.1016/j.jpurol.2009.03.011]

41 **Koh CJ**, De Filippo RE, Chang AY, Hardy BE, Berger A, Eisenberg M, Patil M, Aron M, Gill IS, Desai MM. Laparoendoscopic single-site nephrectomy in pediatric patients: initial clinical series of infants to adolescents. *Urology* 2010; **76**: 1457-1461 [PMID: 20970837 DOI: 10.1016/j.urology.2010.06.066]

42 **Ham WS**, Im YJ, Jung HJ, Hong CH, Han WK, Han SW. Initial experience with laparoendoscopic single-site nephrectomy and nephroureterectomy in children. *Urology* 2011; **77**: 1204-1208 [PMID: 21131028 DOI: 10.1016/j.urology.2010.07.535]

43 **Luithle T**, Szavay P, Fuchs J. Single-incision laparoscopic nephroureterectomy in children of all age groups. *J Pediatr Surg* 2013; **48**: 1142-1146 [PMID: 23701796 DOI: 10.1016/j.jpedsurg.2013.01.040]

44 **Cabezalí Barbancho D**, Gómez Fraile A, López Vázquez F, Aransay Bramtot A. Single-port nephrectomy in infants: Initial experience. *J Pediatr Urol* 2011; **7**: 396-398 [PMID: 21398185 DOI: 10.1016/j.jpurol.2011.01.016]

45 **Bailez M**, Martinez Ferro M. Endosurgical postnatal approach to fetal ovarian cysts. *Pediatr Endosurg Innovat Tech* 1997; **1**: 111-116 [DOI: 10.1089/pei.1997.1.111]

46 **Tseng D**, Curran TJ, Silen ML. Minimally invasive management of the prenatally torsed ovarian cyst. *J Pediatr Surg* 2002; **37**: 1467-1469 [PMID: 12378456 DOI: 10.1053/jpsu.2002.35415]

47 **Prasad S**, Chui CH. Laparoscopic-assisted transumbilical ovarian cystectomy in a neonate. *JSLS* 2007; **11**: 138-141 [PMID: 17651577]

48 **Schenkman L**, Weiner TM, Phillips JD. Evolution of the surgical management of neonatal ovarian cysts: laparoscopic-assisted transumbilical extracorporeal ovarian cystectomy (LATEC). *J Laparoendosc Adv Surg Tech A* 2008; **18**: 635-640 [PMID: 18721022 DOI: 10.1089/lap.2007.0193]

49 **Cimador M**, Sireci F, Di Pace MR, De Grazia E. One-trocar, video-assisted stripping technique for use in the treatment of large ovarian cysts in infants. *J Pediatr Adolesc Gynecol* 2010; **23**: 168-171 [PMID: 20149976 DOI: 10.1016/j.jpag.2009.11.007]

50 **Kozlov IuA**, Novozhilov VA, Rasputin AA, Syrkin NV, Podkamenev AV, Iurkov PS, Solov'ev AA, Radikevich OV. [Hybrid surgery for the treatment of ovarial cysts in newborns]. *Khirurgiia* (Mosk) 2013; **11**: 40-45 [PMID: 24300610]

51 **Muensterer OJ**, Chong A, Hansen EN, Georgeson KE. Single-incision laparoscopic endorectal pull-through (SILEP) for hirschsprung disease. *J Gastrointest Surg* 2010; **14**: 1950-1954 [PMID: 20717739 DOI: 10.1007/s11605-010-1299-3]

52 **Muensterer OJ**, Hansen EN. Resection of a duodenal web using single-incision pediatric endosurgery. *J Pediatr Surg* 2011; **46**: 989-993 [PMID: 21616267 DOI: 10.1016/j.jpedsurg.2011.01.010]

53 **Muensterer OJ**, Keijzer R. Single-incision pediatric endosurgery-assisted ileocecectomy for resection of a NEC stricture. *Pediatr Surg Int* 2011; **27**: 1351-1353 [PMID: 21461885 DOI: 10.1007/s00383-011-2884-6]

54 **Yu HS**, Ham WS, Rha KH, Han SW, Choi YD, Han WK, Chang WS. Laparoendoscopic single-site nephrectomy using a modified umbilical incision and a home-made transumbilical port. *Yonsei Med J* 2011; **52**: 307-313 [PMID: 21319351 DOI: 10.3349/ymj.2011.52.2.307]

55 **Kim HJ**, Lee JI, Lee YS, Lee IK, Park JH, Lee SK, Kang WK, Cho HM, You YK, Oh ST. Single-port transumbilical laparoscopic appendectomy: 43 consecutive cases. *Surg Endosc* 2010; **24**: 2765-2769 [PMID: 20396909 DOI: 10.1007/s00464-010-1043-9]

56 **Romanelli JR**, Mark L, Omotosho PA. Single port laparoscopic cholecystectomy with the TriPort system: a case report. *Surg Innov* 2008; **15**: 223-228 [PMID: 18757383 DOI: 10.1177/1553350608322700]

57 **Kroh M**, Rosenblatt S. Single-port, laparoscopic cholecystectomy and inguinal hernia repair: first clinical report of a new device. *J Laparoendosc Adv Surg Tech A* 2009; **19**: 215-217 [PMID: 19215215 DOI: 10.1089/lap.2008.0081]

58 **Podolsky ER**, Rottman SJ, Poblete H, King SA, Curcillo PG. Single port access (SPA) cholecystectomy: a completely transumbilical approach. *J Laparoendosc Adv Surg Tech A* 2009; **19**: 219-222 [PMID: 19260790 DOI: 10.1089/lap.2008.0275]

59 **Chow A**, Purkayastha S, Paraskeva P. Appendicectomy and cholecystectomy using single-incision laparoscopic surgery (SILS): the first UK experience. *Surg Innov* 2009; **16**: 211-217 [PMID: 19723692 DOI: 10.1177/1553350609344413]

60 **Saber AA**, El-Ghazaly TH, Minnick DB. Single port access transumbilical laparoscopic Roux-en-Y gastric bypass using the SILS Port: first reported case. *Surg Innov* 2009; **16**: 343-347 [PMID: 20031939 DOI: 10.1177/1553350609354604]

61 **Gigirey Castro O**, Berlanga González L, Sánchez Gómez E. [Single port thorascopic surgery using the SILS tool as a novel method in the surgical treatment of pneumothorax]. *Arch Bronconeumol* 2010; **46**: 439-441 [PMID: 20092928 DOI: 10.1016/j.arbres.2009.11.013]

62 **Rothenberg SS**, Shipman K, Yoder S. Experience with modified single-port laparoscopic procedures in children. *J Laparoendosc Adv Surg Tech A* 2009; **19**: 695-698 [PMID: 19694566 DOI: 10.1089/lap.2009.0148]

63 **Garcia-Henriquez N**, Shah SR, Kane TD. Single-incision laparoscopic cholecystectomy in children using standard straight instruments: a surgeon's early experience. *J Laparoendosc Adv Surg Tech A* 2011; **21**: 555-559 [PMID: 21476928 DOI: 10.1089/lap.2010.0512]

64 **Hansen EN**, Muensterer OJ, Georgeson KE, Harmon CM. Single-incision pediatric endosurgery: lessons learned from our first 224 laparoendoscopic single-site procedures in children. *Pediatr Surg Int* 2011; **27**: 643-648 [PMID: 20859633 DOI: 10.1007/s00383-010-2735-x]

65 **Cobellis G**, Torino G, Noviello C, Cruccetti A, Mastroianni L, Amici G, Martino A. Versatility of one-trocar surgery in children. *J Laparoendosc Adv Surg Tech A* 2011; **21**: 549-554 [PMID: 21443436 DOI: 10.1089/lap.2010.0063]

66 **Kozlov Y**, Novozhilov V, Makhov A. Single-incision laparoscopic surgery by children at first 3 months of life. *Endoscopic Surgery* 2014; **2**: 45-55 [Article in Russian]

67 **Rich BS**, Creasy J, Afaneh C, Muensterer OJ. The international experience of single-incision pediatric endosurgery: current state of the art. *J Laparoendosc Adv Surg Tech A* 2014; **24**: 43-49 [PMID: 24147902 DOI: 10.1089/lap.2013.0294]

68 **Seims AD**, Nice TR, Mortellaro VE, Lacher M, Ba'Ath ME, Anderson SA, Beierle EA, Martin CA, Rogers DA, Harmon CM, Chen MK, Russell RT. Routine utilization of single-incision pediatric endosurgery (SIPES): a 5-year institutional experience. *J Laparoendosc Adv Surg Tech A* 2015; **25**: 252-255 [PMID: 25594666 DOI: 10.1089/lap.2014.0492]

69 **Krpata DM**, Ponsky TA. Instrumentation and equipment for single-site umbilical laparoscopic surgery. *Semin Pediatr Surg* 2011; **20**: 190-195 [PMID: 21968153 DOI: 10.1053/j.sempedsurg.2011.05.002]

70 **Ponsky TA**. Single port laparoscopic cholecystectomy in adults and children: tools and techniques. *J Am Coll Surg* 2009; **209**: e1-e6 [PMID: 19854392 DOI: 10.1016/j.jamcollsurg.2009.07.025]

71 **Ponsky TA**, Krpata DM. Single-port laparoscopy: Considerations in children. *J Minim Access Surg* 2011; **7**: 96-98 [PMID: 21197252

DOI: 10.4103/0972-9941.72395]

72 **Ateş O**, Hakgüder G, Olguner M, Akgür FM. Single-port laparoscopic appendectomy conducted intracorporeally with the aid of a transabdominal sling suture. *J Pediatr Surg* 2007; **42**: 1071-1074 [PMID: 17560223]

73 **Kozlov Y**, Rasputin A, Podkamenev A. First experience with use of single-incision laparoscopic pyloromyotomy at neonates: preliminary results. Russian Messenger of Pediatric Surgery. *Anaesth Intens Care* 2011; **2**: 15-20 [Article in Russian]

74 **Kozlov Y**, Novozhilov V, Rasputin A. Use og single-incision approach in treatment patients with congenital hypertrophed pyloric stenosis. *Endoscopic Surgery* 2013; **5**: 11-15 [Article in Russian]

75 **Joshi M**, Kurhade S, Peethambaram MS, Kalghatgi S, Narsimhan M, Ardhanari R. Single-incision laparoscopic splenectomy. *J Minim Access Surg* 2011; **7**: 65-67 [PMID: 21197245 DOI: 10.4103/0972-9941.72385]

76 **Chandler NM**, Danielson PD. Single-incision laparoscopic cholecystectomy in children: a retrospective comparison with traditional laparoscopic cholecystectomy. *J Pediatr Surg* 2011; **46**: 1695-1699 [PMID: 21929976 DOI: 10.1016/j.jpedsurg.2011.02.044]

77 **St Peter SD**, Adibe OO, Juang D, Sharp SW, Garey CL, Laituri CA, Murphy JP, Andrews WS, Sharp RJ, Snyder CL, Holcomb GW, Ostlie DJ. Single incision versus standard 3-port laparoscopic appendectomy: a prospective randomized trial. *Ann Surg* 2011; **254**: 586-590 [PMID: 21946218 DOI: 10.1097/SLA.0b013e31823003b5]

78 **Emami CN**, Garrett D, Anselmo D, Torres M, Nguyen NX. Single-incision laparoscopic cholecystectomy in children: a feasible alternative to the standard laparoscopic approach. *J Pediatr Surg* 2011; **46**: 1909-1912 [PMID: 22008326 DOI: 10.1016/j.jpedsurg.2011.03.066]

79 **Tsimoyiannis EC**, Tsimogiannis KE, Pappas-Gogos G, Farantos C, Benetatos N, Mavridou P, Manataki A. Different pain scores in single transumbilical incision laparoscopic cholecystectomy versus classic laparoscopic cholecystectomy: a randomized controlled trial. *Surg Endosc* 2010; **24**: 1842-1848 [PMID: 20174950 DOI: 10.1007/s00464-010-0887-3]

80 **Kravetz AJ**, Iddings D, Basson MD, Kia MA. The learning curve with single-port cholecystectomy. *JSLS* 2009; **13**: 332-336 [PMID: 19793472]

81 **Solomon D**, Bell RL, Duffy AJ, Roberts KE. Single-port cholecystectomy: small scar, short learning curve. *Surg Endosc* 2010; **24**: 2954-2957 [PMID: 20401494 DOI: 10.1007/s00464-010-1070-6]

82 **Erbella J**, Bunch GM. Single-incision laparoscopic cholecystectomy: the first 100 outpatients. *Surg Endosc* 2010; **24**: 1958-1961 [PMID: 20112110 DOI: 10.1007/s00464-010-0886-4]

83 **Curcillo PG**, Wu AS, Podolsky ER, Graybeal C, Katkhouda N, Saenz A, Dunham R, Fendley S, Neff M, Copper C, Bessler M, Gumbs AA, Norton M, Iannelli A, Mason R, Moazzez A, Cohen L, Mouhlas A, Poor A. Single-port-access (SPA) cholecystectomy: a multi-institutional report of the first 297 cases. *Surg Endosc* 2010; **24**: 1854-1860 [PMID: 20135180 DOI: 10.1007/s00464-009-0856-x]

84 **Blanco FC**, Kane TD. Single-port laparoscopic surgery in children: concept and controversies of the new technique. *Minim Invasive Surg* 2012; **2012**: 232347 [PMID: 22778945 DOI: 10.1155/2012/232347]

P- Reviewer: Tam PKH, Watanabe T
S- Editor: Ji FF **L- Editor**: A **E- Editor**: Jiao XK

World Journal of Clinical Pediatrics

Submit a Manuscript: http://www.wjgnet.com/esps/
Help Desk: http://www.wjgnet.com/esps/helpdesk.aspx
DOI: 10.5409/wjcp.v4.i4.66

World J Clin Pediatr 2015 November 8; 4(4): 66-80
ISSN 2219-2808 (online)
© 2015 Baishideng Publishing Group Inc. All rights reserved.

REVIEW

Congenital and childhood myotonic dystrophy: Current aspects of disease and future directions

Genevieve Ho, Michael Cardamone, Michelle Farrar

Genevieve Ho, Michael Cardamone, Michelle Farrar, Discipline of Paediatrics, School of Women's and Children's Health, UNSW Medicine, the University of New South Wales, Sydney NSW 2031, Australia

Michael Cardamone, Michelle Farrar, Department of Neurology, Sydney Children's Hospital, Randwick NSW 2031, Australia

Author contributions: Ho G contributed to literature searches and initial drafting and revision of the manuscript; Farrar M contributed to initial outline and revisions of the manuscript; Cardamone M contributed to revising the manuscript.

Conflict-of-interest statement: Ms Ho, Dr. Cardamone and Dr. Farrar report no disclosures or conflict of interests.

Open-Access: This article is an open-access article which was selected by an in-house editor and fully peer-reviewed by external reviewers. It is distributed in accordance with the Creative Commons Attribution Non Commercial (CC BY-NC 4.0) license, which permits others to distribute, remix, adapt, build upon this work non-commercially, and license their derivative works on different terms, provided the original work is properly cited and the use is non-commercial. See: http://creativecommons.org/licenses/by-nc/4.0/

Correspondence to: Dr. Michelle Farrar, MBBS, FRACP, PhD, Department of Neurology, Sydney Children's Hospital, High St, Randwick NSW 2031, Australia. m.farrar@unsw.edu.au
Telephone: +61-2-93821549
Fax: +61-2-93821580

Received: May 20, 2015
Peer-review started: May 20, 2015
First decision: August 4, 2015
Revised: August 7, 2015
Accepted: September 25, 2015
Article in press: September 28, 2015
Published online: November 8, 2015

Abstract

Myotonic dystrophy type 1 (DM1) is multisystem disease arising from mutant CTG expansion in the non-translating region of the dystrophia myotonica protein kinase gene. While DM1 is the most common adult muscular dystrophy, with a worldwide prevalence of one in eight thousand, age of onset varies from before birth to adulthood. There is a broad spectrum of clinical severity, ranging from mild to severe, which correlates with number of DNA repeats. Importantly, the early clinical manifestations and management in congenital and childhood DM1 differ from classic adult DM1. In neonates and children, DM1 predominantly affects muscle strength, cognition, respiratory, central nervous and gastrointestinal systems. Sleep disorders are often under recognised yet a significant morbidity. No effective disease modifying treatment is currently available and neonates and children with DM1 may experience severe physical and intellectual disability, which may be life limiting in the most severe forms. Management is currently supportive, incorporating regular surveillance and treatment of manifestations. Novel therapies, which target the gene and the pathogenic mechanism of abnormal splicing are emerging. Genetic counselling is critical in this autosomal dominant genetic disease with variable penetrance and potential maternal anticipation, as is assisting with family planning and undertaking cascade testing to instigate health surveillance in affected family members. This review incorporates discussion of the clinical manifestations and management of congenital and childhood DM1, with a particular focus on hypersomnolence and sleep disorders. In addition, the molecular genetics, mechanisms of disease pathogenesis and development of novel treatment strategies in DM1 will be summarised.

Key words: Clinical manifestations; Myotonic dystrophy type 1; Childhood myotonic dystrophy; Congenital myotonic dystrophy; Natural history; Management

© The Author(s) 2015. Published by Baishideng Publishing Group Inc. All rights reserved.

Core tip: Type 1 myotonic dystrophy is an often undetected neuromuscular disease in paediatric patients with variable clinical manifestations and burden of disease. We review the current understandings of disease pathogenesis, symptoms and management in congenital and childhood myotonic dystrophy with a particular focus on hypersomnolence and sleep disorders. Future directions should target standardised care and regular surveillance, understanding pathophysiology and new treatment strategies.

Ho G, Cardamone M, Farrar M. Congenital and childhood myotonic dystrophy: Current aspects of disease and future directions. *World J Clin Pediatr* 2015; 4(4): 66-80 Available from: URL: http://www.wjgnet.com/2219-2808/full/v4/i4/66.htm DOI: http://dx.doi.org/10.5409/wjcp.v4.i4.66

INTRODUCTION

Myotonic dystrophy type 1 (DM1) is a multisystem genetic disease that affects skeletal and smooth muscle as well as the eye, heart, endocrine system, and central nervous systems (CNS) caused by expansion of a CTG trinucleotide repeat in the non-coding region of the dystrophia myotonica gene (*DMPK)*. The phenotype is variable and encompasses a broad spectrum of severity from mild to severe. It is the most common adult muscular dystrophy, with an estimated worldwide prevalence of one in eight thousand, but age of onset varies from prenatal to adulthood. While the clinical manifestations and natural history of DM1 in adulthood are well established, the manifestations and management of DM1 in children warrants further evaluation. Multidisciplinary care including proactive respiratory care and nutrition optimisation have seen changes in the natural history of a number of neuromuscular disorders[1-3]. It is critical to develop a better and focused understanding of the unique issues encountered in the management of DM1 in paediatrics and neonatology to optimise outcomes and develop standards of care. Accordingly, this review will summarise the current understandings of congenital and childhood DM1, with a particular focus on sleep and hypersomnolence.

CLINICAL CLASSIFICATION AND NATURAL HISTORY

There are five clinical phenotypes of DM1 that generally correlate with CTG repeat size (Table 1), including premutation, mild adult DM, classical adult DM, childhood-onset DM and congenital DM.

Congenital myotonic dystrophy (CDM) is characterised by severe hypotonia and weakness at birth, often with respiratory insufficiency. The incidence of CDM is up to 1 in 47619 live births[4] and the mortality in the neonatal period may be 30%-40%[5].

Childhood-onset DM is initially clinically apparent between ages 1-10, however diagnosis may occur later, and predominantly affects muscle strength, cognition, respiratory, central nervous and gastrointestinal systems (Table 2). Juvenile DM is apparent between 10-20 years, however onset may be vague and manifestations overlap between childhood and classic DM. Patients with childhood and juvenile DM survive into adulthood, however the natural history remains to be fully determined, with recent advances in supportive care. Adult type problems arise in later life. Severe CDM demonstrates a unique "biphasic" course, whereby neonatal symptoms improve or stabilise in surviving neonates, before adult-type symptoms present in later life[6]. Echenne and Bassez[5] also observe a "continuum", where CDM survivors and childhood-onset/juvenile types develop the same clinical picture before eventually showing classical adult-onset manifestations. Consequently developing standards of care focusing on the neonatal and childhood periods of DM1 in addition to adult DM are needed. In addition, developing guidelines on transitioning to adult medical care for patients with congenital and childhood DM is necessary.

CLINICAL MANIFESTATIONS OF DM1 IN NEONATES AND CHILDREN

Neonatal period in CDM

Polyhydramnios, reduced foetal movements and preterm delivery often complicate CDM gestation[7]. Classically, neonates are born with hypotonia and immobility, bilateral talipes, contractures, arthrogryposis, facial dysmorphia (carp mouth, ptosis, long neck and face, temporal muscle atrophy), hyporeflexia, a weak cry, sucking and respiratory difficulties. Cases of premature (less than 36 wk gestation) and small for gestational age DM1 babies have also been reported[6]. The presence of respiratory distress is sometimes used to distinguish between mild and severe CDM[8]. Respiratory difficulties were present in about 50% of neonates (Wallgren-Petterson, Bushby, Mellies, and Simonds, 2004) and are the main cause of neonatal mortality which ranges between thirty and forty percent[9].

Musculoskeletal manifestations

Muscle weakness in DM1 is typically distal but may be proximal, the latter indicating a poorer prognosis[10]. Following initial improvement in the neonatal period, the natural history of progressive muscle weakness is variable. While strength is typically stable until adolescence with gradual deterioration subsequently evident, rarely rapid increasing weakness may occur in young adults[8,11]. Complications of muscle weakness may include scoliosis and contractures, particularly at the tendo-achiles producing foot deformity and toe walking. Bulbar muscle weakness may also produce

Table 1 Myotonic dystrophy type 1 clinical phenotypes

Phenotype	Clinical characteristics	CTG repeat length	Age of onset (yr)
Premutation	Not applicable	38-49	Not applicable
Mild/late onset adult	Mild myotonia Cataracts	50-100	20 to 70
Classical adult	Myotonia Muscle weakness Cataracts Conduction defects Insulin resistance Respiratory failure	50-1000	10 to 30 (median 20 to 25)
Childhood onset	Facial weakness Cognitive defects Psychosocial issues Incontinence	> 800	1-10
Congenital	Hypotonia Respiratory distress Cognitive defects Motor and developmental delay Feeding difficulties	> 1000	Birth

swallowing difficulties, speech and language difficulties, separate to cognitive impairment and may initiate consideration of DM1. In contrast to adult DM1, severe myotonia is not common in children but is present to some extent in most children by age 10 years[11-13]. The worsening facial dysmorphia and "carp" mouth appearance seen in CDM neonates is not a feature at birth for childhood-onset cases[12]. These patients may experience facial weakness but to a lesser severity.

Sleep disturbances

Sleep disorders are a significant complaint in both adult and childhood DM1 (Table 3) and may adversely affect learning, memory, high-level cognitive processing and physical functioning, thereby exacerbating psychomotor and cognitive delays in DM1[14,15]. Consequently, understanding sleep pathophysiology and assessment approaches are important in determining management in DM1. Normal sleep is maintained through CNS regulation of breathing and sleep-wake cycles and respiratory muscle integrity.

CNS disturbances in DM1 can affect sleep through central deregulation of breathing whilst sleeping, resulting in hypoventilation and subsequent sleep fragmentation, producing excessive Daytime Sleepiness (EDS)[16]. EDS in DM1 is characterised by persistent sleepiness, more likely during situations requiring less attention, and is not improved by naps and has been reported in approximately 50% of children with DM1[17]. It occurs concurrently and may be attributed to other sleep disorders including sleep apnoea, periodic limb movement disorders (PLMs) and rapid eye movement (REM) sleep dysregulation. Neuronal loss and gliosis in the reticular activating system and brainstem may underlie central deregulation of ventilation[18,19]. Immunoendocrine causes with abnormal levels of growth hormone, cortisol and cytokinesin DM1 may also affect sleep control[20,21]. MRI studies indicate white matter changes are evident; however, the changes do not correlate with severity of EDS[22].

Sleep disordered breathing (SDB) can arise from obstructive causes (apnoeas - airway hypotonia or tonsillar hypertrophy) or central ventilator dysfunction in DM1. Muscle weakness can contribute to obstructive sleep disorders. Apnoea-Hypnoea indices are raised in adult DM1 patients[23]. This causes nocturnal hypoxemia and hypoventilation, subsequent sleep fragmentation and EDS[24,25]. EDS and apnoeas, however have been noted to occur independently, and correction of hypoventilation does not always improve EDS[16]. Sympathetic hyperactivity associated with cardiac conduction disturbances are suspected to be linked to PLMs[26]. Thus conduction deficits seen in DM1 could in part explain sleep fragmentation and subsequent EDS by increasing the occurrence of PLMs.

Cognitive impairment

Cognitive impairment is one of the most common manifestations and challenging management aspects of childhood DM1. This may be the presenting characteristic in children, ranging from mild to moderate intellectual impairment. Overall, both groups have lower than average IQ. CDM patients are more severely affected and full-scale IQ ranges from 40-80, with a mean below 70[12]. Childhood-onset patients have a wider range from 42 to 114 and a mean of about 70-80[27-29]. It is highly possible that patients' IQ is underestimated however, due to the false impressions given by apathy and reduced facial expression commonly seen in DM1. Cognitive impairment correlates with severity of muscle weakness, size of CTG repeat and maternal transmission[27,28].

Psychosocial function

Approximately half of children with DM1 have at least one DSM-IV psychiatric diagnosis[27], with internalising disorders (phobia, depression, anxiety) and attention deficit hyperactivity disorders being common. Avoidant personality types, apathy and autistic features may also be evident[30,31]. Brain imaging of (CT, MRI) CDM and JDM patients often reveal ventricular dilatation, cortical atrophy, and hypoplasia of the corpus callosum, and hyper-intense white matter in cortical regions seem to be specific to CDM[32]. While not evident during paediatric management, these may relate to subsequent development of dementia, and are important considerations in further understanding pathogenic mechanisms of neuro-degeneration.

Respiratory

Respiratory manifestations, related to inspiratory and expiratory muscle weakness, are a major feature of CDM and remain important in childhood. These include sleep breathing disorders, recurrent infections, weak cough

Table 2 Summary of the clinical manifestations in congenital and childhood-onset/juvenile myotonic dystrophy type 1

System	Congenital (CDM)	Childhood-onset/juvenile onset
Prenatal	Polyhydramnios	Not applicable
	Reduced foetal movements	
	Preterm delivery	
Muscular	Hypotonia at birth	Facial dysmorphia (may be subtle)
	Talipes	Generalised muscle weakness
	Contractures	Myotonia, usually after 1st decade
	Scoliosis, lordosis, kyphosis	Muscle atrophy
	Arthrogryposis	Brisk reflexes
	Characteristic facial dysmorphia	Mild talipes and contractures Motor delay
	Hyporeflexia	
	Generalised muscle weakness (distal > proximal)	
	Muscle atrophy	
	Motor delay	
Vision	Visual impairment	Visual impairment
	Strabismus	Strabismus
	Reduced visual acuity	Reduced visual acuity
	Lens pathology	Lens pathology
Respiratory	Respiratory distress at birth	Recurrent infections (weak cough)
	Raised right hemi-diaphragm	Sleep apnoea and sleep disordered breathing
	Pulmonary hypoplasia	
	Bronchopulmonary dysplasia	
	Aspiration pneumonia	
	Sleep apnoea and sleep disordered breathing	
	Pneumothorax	
	Recurrent infections	
	Impaired central respiratory control	
Gastrointestinal and feeding	Sucking difficulties from birth	Recurrent abdominal pain
	Gastroparesis	
	Gastroesophageal reflux and aspiration	
	Constipation	
	Recurrent diarrhoea	
	Faecal incontinence	
	Anal dilatation	
	Persistent abdominal pain	
CNS	Increased sensitivity to anaesthesia	Hypersomnolence and fatigue
	Neuroendocrine disturbance	Periodic limb movements
	Psychiatric disorders (ADHD, anxiety, depression)	Psychiatric disorders
	Autism	Autism
	Hypersomnolence and fatigue	
Cognitive function	Lower IQ	Lower IQ
	Full scale ranges between 40-80	Full scale ranges from 42 to 114
	Mean less than 70	Mean between 70 and 80
Cardiac	Conduction disturbances	Conduction disturbances
	Structural abnormality, valve defects (most commonly mitral)	Structural abnormality, valve defects (More common in older patients)
Endocrine	Testicular atrophy	Testicular atrophy
	Hormone abnormalities: growth hormone, hypothyroidism (late teens)	Later onset: hormone abnormalities
Hearing	Recurrent otitis media	Recurrent otitis media (less common)
Oral health	Dental caries, plaque, gingivitis decay/trauma	Dental caries, plaque, gingivitis decay/trauma
Speech and language	Nasal voice and dysarthria	Speech delay
	Speech delay	Nasal voice and dysarthria
Life expectancy	30%-40% death rate within neonatal period	Mortality similar to adult-onset
	Mean life expectancy: 45 yr	Mean life expectancy: approximately 60 yr

CDM: Congenital myotonic dystrophy; ADHD: Attention-deficit/hyperactivity disorder; CNS: Central nervous system; IQ: Intelligence quotient.

and aspiration pneumonia[8,12,33]. It is also important to appreciate DM1 patients have hypersensitivity to anaesthesia, which arises from respiratory muscle compromise and central dysregulation of breathing[34]. Separately, obesity may adversely affect pulmonary function and sleep-disordered breathing in adults with DM1, although this remains to be defined in paediatric DM1 patients. Cognitivive impairment may affect an individual's ability to reliability undertake conventional respiratory function tests. Consequently sniff nasal inspiratory pressure (SNIP), which correlates with pulmonary function, may provide an easier and more accurate measurement[35].

Gastrointestinal symptoms

Gastrointestinal complaints often predate diagnosis of DM1 and significantly contribute to morbidity. Previous studies have determined that forty per cent of

Table 3 Sleep disorders in myotonic dystrophy type 1 that contribute to hypersomnolence

Sleep disorder	Description and components
Excessive daytime sleepiness	Greater susceptibility to falling asleep, especially when in situations requiring less attention Naps are long, frequent and unrefreshing
Long night time sleep	Sleep often does not feel sufficient or restorative Sleep fragmentation and frequent arousals
Sleep related breathing disorders	Sleep apnoea or hypopnoea: Obstructive and/or central Hypercapnoea and hypoxemia in both day and night time
RLS and PLM	RLS refers to the urge to move limbs while both awake and asleep, while PLM refers to uncontrolled limb movements during sleep. Both commonly co-exist
REM sleep dysregulation	Abnormal periods of SOREMPs during MSLTs Increased density and frequency of REM sleep nocturnally

RLS: Restless leg syndrome; PLM: Periodic limb movements; SOREMPs: Sleep-onset REM periods; MSLTs: Multiple sleep latency tests; REM: Rapid eye movement.

children and young adults regularly experience faecal incontinence, with twenty per cent stating this was their worst symptom[36]. Up to a third may also report constipation and irregular bowel habits[37]. Recurrent or persistent diffuse abdominal pain are common[38]. In both adults and children, dysphagia, gastroesophageal reflux and choking have been observed[4,39,40]. Dyspeptic symptoms of nausea, vomiting, and early satiety may be attributed to delayed gastric emptying. Lower tract problems also include faecal incontinence, episodic and recurrent diarrhoea, with significant social implications[37,39].

There are multiple factors that cause the gastrointestinal disturbances, including reduced peristalsis and secondary bacterial overgrowth. The latter is a mechanism of diarrhoea which may be overcome with antibiotics[41,42]. Delayed gastric emptying may also be related to gut hormone abnormalities guiding future management strategies[43,44].

Other systems

Many key features of adult "classic" DM are not evident in childhood, including cataracts, significant cardiac disorders and diabetes mellitus. Even so, lens pathology may be evident in 41% of patients, and may be predictive of future cataract development[45]. Conduction disturbances observed on electrocardiography are not uncommon in children, however they do not often present symptomatically with dyspnoea, palpitations or syncope. Valve abnormalities have also been observed, but again, are not clinically significant. Hypothyroidism, hypogonadism, growth hormone imbalance and androgen insensitivity have been observed but are rare[8,46]. In contrast, testicular atrophy and infertility are common amongst CDM males. Females with severe CDM patients may experience very irregular periods and prolonged episodes of amenorrhoea[46].

CURRENT TREATMENT AND MANAGEMENT

Management of childhood DM1 is currently adapted from approaches to adult myotonic dystrophy. A multidisciplinary team approach is critical in providing supportive care to manage manifestations, reduce complications, optimise function and undertake health surveillance (Table 4). This includes involvement of genetic counsellors, nurses, educators, physiotherapists, speech therapists, occupational therapists, social workers, and dieticians in addition to medical specialists. Standards of care for other rare neuromuscular disorders, for example spinal muscular atrophy and Duchenne Muscular Dystrophy, have been established and are easily accessible to health care professionals and patients[1-3]. Advances in the management of respiratory impairment and nutrition have seen an evolution in the natural history of these disorders[47]. The multisystemic nature of DM1 brings about similar complex care, yet the unique cognitive and psychological manifestations of DM1 may limit ongoing engagement with medical services. Patients may present ad hoc to clinicians unfamiliar with DM1. Consequently creating standards of care, encompassing the specific needs of children with DM1 and anticipating transition to adult services, for best practice is critical. Further these need to be accessible and practical to primary care physicians and converted into individual health care plans.

In severe CDM, neonatal intensive care is often required to provide respiratory support. Chest radiography may demonstrate diaphragm elevation, prompting additional management of pulmonary hypoplasia. Nutrition and feeding may require enteral supplementation. Oesophageal function should be evaluated with barium studies and speech pathology assessments to consider aspiration. Cerebral ultrasounds or head CT may be undertaken for concurrent birth related hypoxia or cerebral haemorrhage. Splinting of talipes is also commenced[48].

Recognising cognitive impairment and psychiatric/psychological manifestations are critical in guiding overall management and planning appropriate educational support. Formal cognitive testing and psychological assessments are essential. Special education is common and previous studies have revealed that more than two thirds of DM1 children have repeated a grade at

Table 4 Current management strategies in congenital and childhood myotonic dystrophy type 1

Clinical problem	Management strategies
Muscle weakness	
General	Exercise and physical therapy
	Possible drug therapy (DHEA, IGF-1, BP3, Creatinine use has shown possible benefits but this is not routinely done)
Talipes, foot drop, osteopenia, contractures	Orthopaedic surgery (*e.g.*, tendon transfer, if required)
	Mobility aids
	Physiotherapy, ankle foot orthoses, splints
(Scoliosis, kyphosis)	Optimise vitamin D and calcium
	Physiotherapy, stretches and splints
Speech (dysarthria)	Orthopaedic surgery
Swallowing/feeding	Speech therapy
	Speech therapy
	Modification of food consistency
	Physiotherapy to enhance swallowing
Myotonia	Occupational therapy – adaptive devices
	Drug therapy (Mexiletine, anti-epileptics, amino acids, antidepressants)
Respiratory	
Chest wall weakness and respiratory function	Regular surveillance screening with a symptom checklist including:
	Orthopnoea, dyspnoea with ADLs, sleep disturbances, morning headaches, apnoea, reduced cognition, EDS, fatigue, recent chest infections
	Respiratory function tests including
	Regular forced vital capacity, FEV1, pulse oximetry and peak expiratory cough flow
	Elective monitoring also includes mean inspiratory and
	expiratory pressures, and arterial blood gas analysis
	Imaging may include chest radiography or ultrasound for detection of motion abnormalities and thinning of diaphragm
	Nocturnal non-invasive ventilation: BiPAP or CPAP (in more obstructive cases)
Weak cough	CDM: Intubation and ventilation during neonatal period
Greater	Physiotherapy incorporating airway clearing techniques, manual assisted cough and postural drainage of secretions
Susceptibility to infections/recurrent infections	Antibiotics for management of acute infections
	Prophylactic vaccinations
	Respiratory physician consultation
	Prophylactic antibiotics
Cardiac	
Conduction disorders	Annual surveillance with ECG and echocardiography
	Holter monitoring
	Pacemaker or defibrillator insertion if indicated
Sleep	
Sleep related breathing disorders	Respiratory function testing
	Overnight pulse oximetry
	Polysomnography
	Non-invasive ventilation
Upper airway obstruction/apnoea	Total tonsillectomy or adenoidectomy may be beneficial
Periodic limb movements	Assessment of serum iron and ferritin
	Consider dopaminergic agents
Excessive daytime somnolence	Thorough assessment (questionnaires, actigraphy)
	Drug therapy/psychostimulants (Modafanil)
Hearing	Regular assessment
	Antibiotics for otitis media
	Grommets for recurrent otitis media
Gastrointestinal	
Nutrition	Monitoring growth
	Assessment of micronutrients (*e.g.*, iron and vitamin D) and supplementation as needed
	Dietician consultation
Irritable bowel syndrome type symptoms	Antibiotics to counteract bacterial overgrowth
Diarrhoea	Antibiotics (erythromycin)
	Drug therapy (cholestyramine)
Constipation	Stool softeners
	Laxatives/stimulating agents
	Regular toileting routine assisted by bulking agents and laxatives
Faecal incontinence	Cholestyramine
(Anal dilatation)	Colostomy (last resort)
Abdominal Pain	Pain medication (NSAIDs)
	Cholestyramine
Anaesthesia	

Hypersensitivity with risk of respiratory depression	Detailed anaesthetic work up and assessment that may include ultrasound examination of gastric volume for risk of aspiration Establish airway: modified rapid induction, tracheal tube/supra-glottic device
Increased risk of intraoperative myotonia	Avoid opioid infusions and intravenous administrations Consider local anaesthetia as an alternative (Caudal, spinal and epidural) Extensive post-operative monitoring and support Paracetamol and NSAIDs
Poor oral health	Regular dental hygiene Regular visits to general and specialist dental clinics Good home care techniques: cleaning, plaque removal
Vision	Early and regular screening Prevention of amblyopia Early correction of hyperopia and astigmatism
Psychological	
Cognitive deficits and mental retardation	Cognitive assessment Planning of appropriate education environment and support
Neuropsychiatric comorbidities (Attention deficit, personality disorders)	Psychotherapy, social skills training Drug therapy (*e.g.*, stimulants for ADHD)
Social issues	Specialised school or special arrangements

DHEA: Dehydroepiandrosterone; IGF: Insulin-like growth factor; EDS: Excessive daytime sleepiness; BiPAP: Bi-level positive airway pressure; CPAP: Continuous positive airway pressure; CDM: Congenital myotonic dystrophy; NSAIDs: Non-steroidal anti-inflammatory drugs; BP3: Binding protein 3; ADL: Activities of daily living; FEV1: Forced expiratory volume in 1 s; ECG: Electrocardiogram; NSAIDS: Non-steroidal inflammatory drugs; ADHD: Attention deficit hyperactivity disorder.

school[27]. Anticipating economic and vocational support are critical, with unemployment common in young adults. Taken together, special education, psychotherapy, social and vocational skills training should be utilised to maximise functionality. Stimulant medication may be prescribed for management of attention deficit hyperactivity disorder, a common comorbidity, with attention to screening for cardiac rhythm disorders.

Muscle weakness is rarely progressive in childhood; however physiotherapy, occupational therapy and orthopaedic surgery are important to limit and manage complications (contractures, pain and scoliosis) and maximise function. This includes regular assessments of strength, range of motion and function. Stretches, orthoses and assistive devices may be utilised. Tendo-achilles lengthening and scoliosis surgery may be indicated. Even though exercise therapy is commonly used, studies have shown neither benefit nor harm[49]. A Cochrane review published in 2006[50] found limited evidence supporting drugs for myotonia. Agents analysed included sodium channel blockers (such as procainamide and mexiletine), calcium channel blockers (nifedipine), benzodiazepines (diazepam), taurine and tricyclic antidepressants (clomipramine and imipramine). A more recent study has found that mexiletine is effective and well tolerated for improving debilitating grip myotonia in adults[51]. Facial weakness worsens with age and swallowing dysfunction may be assisted with diet modification and speech pathology. Speech therapy will also assist in language development. In addition facial weakness and an open mouth posture may cause more plaque, gingivitis and caries such that more frequent brushing, dental hygiene and regular dental reviews are important[52].

Regular surveillance for respiratory and cardiac complications is important in childhood. The most recent European Neuromuscular Centre workshop (ENMC) for chronic respiratory disease in DM1 describes consensus recommendations for assessment, management and follow-up based on current evidence and clinician experience[53]. Interviews with patient and carer should include a checklist for symptoms of orthopnoea, dyspnoea while performing activities of daily living, sleep disturbances, morning headaches, apnoea, reduced cognition, EDS, fatigue and chest infections since last review to identify and quantify respiratory insufficiency[53]. Accompanying tests should include respiratory function testing, pulse oximetry and polysomnography (Table 4). Management should include routine vaccination for pertussis, pneumococcus and influenza in preventing respiratory infections. Airway clearance techniques are beneficial in management of weak cough. Respiratory support is more commonly indicated in neonates than in childhood. Non-invasive ventilation may improve quality of life when there is hypoventilation or apnoea, however clinicians still debate its efficacy and further studies will clarify utility[53]. While Bi-level positive airway pressure (BiPAP) use is first line, continuous positive airway pressure (CPAP) should be used when there is a predominantly obstructive component in respiratory insufficiency. CPAP use should be accompanied with careful monitoring of blood gases[53]. Importantly, there may be a possible relation between apnoea and dysrhythmia[54] such that cardiac monitoring should accompany appropriate respiratory management when spontaneous apnoea is present[53].

Routine electrocardiography and echocardiogram should be performed and Holter monitoring may be undertaken if clinically indicated to assess for arrhythmia. Cardiac interventions, such as pacing or implanted defibrillator, are more likely to be needed closer to adulthood.

Recurrent and persistent otitis media is common

in CDM[12] and should be referred to ear, nose and throat (ENT) specialists for assessment of hearing and management. Likewise, gastrointestinal problems are an important management issue. Supportive therapies such as stool softeners/bulking agents, laxatives, antibiotics for bacterial growth, and pain medication are useful. Some drug therapies have also proven effective in remediating symptoms (Table 4). Bile acid sequestrator agents, such as cholestyramine, have been noted to reduce diarrhoea, incontinence and abdominal pain[33].

Genetic counselling is crucial in understanding the nature and inheritance pattern of DM1[55]. Multiple family members are commonly affected, and early counselling allows for surveillance and early intervention in these individuals as well as family planning with foetus risk assignment depending on parental disease. Genetic anticipation, the occurrence of decreasing age of onset and increasing severity in successive generations related to expansion of CTG repeats during meiosis, is an important consideration in genetic counselling. Notably, women have a higher risk of CDM offspring and risk factors include length of triplet repeats, symptoms during pregnancy and severity of their clinical presentation. Previous studies vary in estimation of CDM risk related to maternal CTG repeat length, rendering specific risk assessments difficult. Maternal alleles longer than 300 repeats have been demonstrated to have a 59% risk of CDM, compared with a 10% risk when CTG repeats are less than 300[56]. Different studies have found a maternal CTG length greater than 100 may have a 63% risk of CDM[57,58]. Anticipation with paternal inheritance is also possible and risk factors include onset less than aged 30 years and previous CDM pregnancies[59,60]. A parent may be identified with DM1 following diagnosis in their child and is of significance in planning of health care for the family.

Management of sleep disturbances

Sleep disturbances have been shown to be linked to greater psychosocial issues, depressive symptoms and lower quality of life[16,61,62]. Further, it is a condition faced in both adult and paediatric populations; hence early management is highly beneficial. Current management involves a thorough assessment and quantification of the sleep problem with appropriate tests. This includes polysomnography, lung function, and subjective questionnaires to assess daytime sleepiness, quality of life assessments and monitoring activity and rest cycles through non-invasive actigraphy. If a SDB is suspected, supportive ventilation with CPAP, BiPAP, sero-ventilation can improve arterial blood gases and prolong survival but may not always alleviate EDS[62]. Use of psychostimulants remains debated. A Cochrane review[63] found that evidence was inconclusive to support psychostimulant use in hypersomnia, but subjective clinician experience and other studies have found modafinil to be beneficial for EDS[64,65]. The American Academy of Sleep Medicine recognises modafinil as a therapeutic option for EDS in adult DM1, and states the current dosing recommendation as 200 mg once daily for treatment of EDS in narcolepsy[66]. There are limited clinical trials and safety information for modafinil use in children, hence modafinil is not approved by regulatory bodies for use in young children. Further studies in this group are needed to determine safety and efficacy.

GENETICS AND PATHOGENESIS OF DM1

DM1 has autosomal dominant inheritance and penetrance is variable (Figure 1). It is caused by a CTG repeat expansion of the non-coding DNA segment on the *DMPK* gene on chromosome 19q13.3. In unaffected individuals, the *DMPK* gene segment is highly polymorphic and can range from 5-27 copies[67]. There can be greater than 2000 CTG repeats in DM1[68]. Larger repeats correlate with greater symptom severity and earlier age of onset (Figure 2). One study demonstrated that in severe congenital DM1, 44% had more than 4.5 kb (up to 2000 repeats), however the largest repeat was not conditional for congenital disease[69].

DM1 demonstrates anticipation, as the CTG repeat expansion in *DMPK* may increase and become unstable with each generation. Even though amplification occurs regardless of the parental sex, offspring repeat size seems to increase more in paternally transmitted cases when the father has smaller repeats[70], but instability is greater when the mother has an expansion of more than 0.5 kb[71]. Many studies have also found occasional contractions in repeat size and variants to the repeats, but it has yet to be established if variants or interruptions in the repeats alters pathogenesis[72,73]. A sound understanding is especially important in management with regard to family planning. Adequate counselling of women who are considering pregnancy is crucial and foetal risk of disease should be assessed based on parental repeat size and presence of siblings with DM1 as mentioned before[59].

MOLECULAR PATHOGENESIS

The molecular pathogenesis of DM1 is mediated by toxic RNA with disruption of splicing of pre-mRNA transcripts including CUG binding protein (CUG-BP) and Musclebind-like protein (MBNL) (Figure 3). The CTG DNA expansion produces transcription of mutant (CUG) RNA repeats which bind to splice-regulating proteins producing aggregation and formation of ribonuclear inclusions[74,75]. Deregulated alternative splicing of pre-mRNAs has been attributed to abnormal levels of splice-regulating proteins. MBNL and CUG-BP are the two main proteins indicated[76], and the RNA toxicity mediated process is commonly known as "spliceopathy". It is uncertain as to how many other RNA-binding proteins/splice-regulating proteins are involved in DM1 pathogenesis.

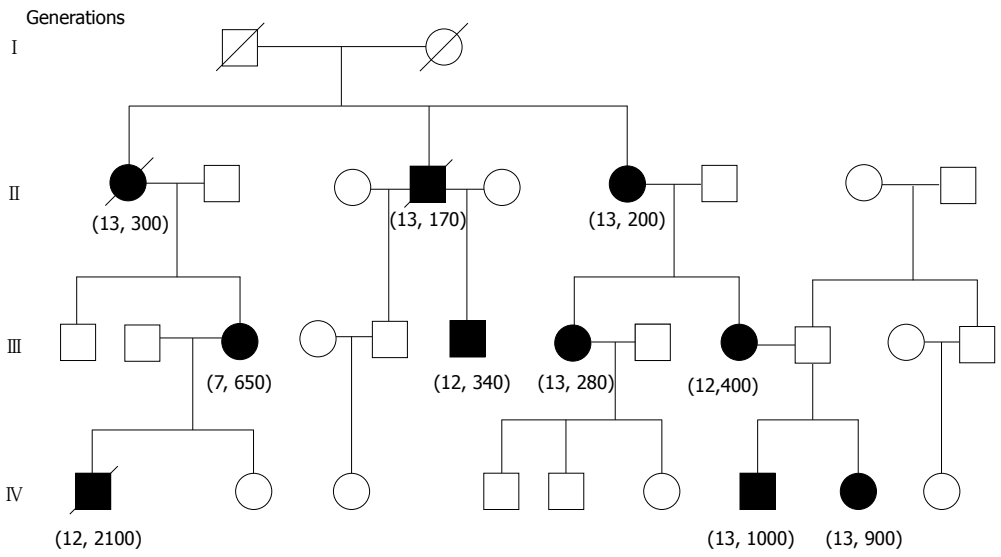

Figure 1 Genogram of family with myotonic dystrophy type 1 illustrating autosomal dominant inheritance. The numbers in brackets indicate the number of CTG triplet repeats in the 3' untranslated portion of the *DMPK* gene of affected individuals. Square = male; Circle = female; Black symbol = DM1 affected individuals; Strikethrough symbol = deceased.

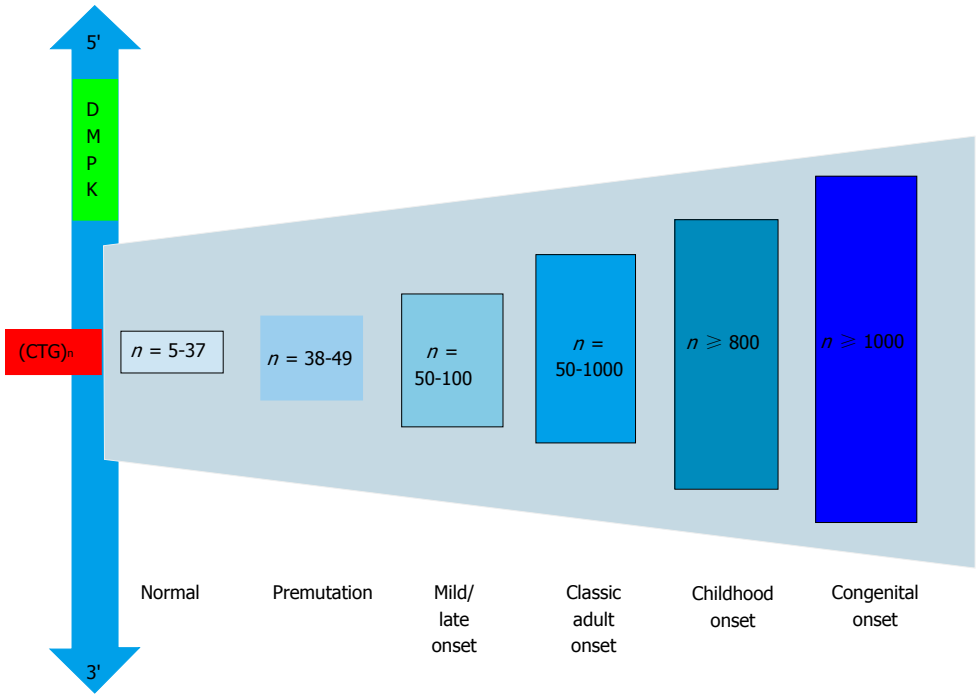

Figure 2 The genetic basis of myotonic dystrophy type 1. In DM1 there is an unstable CTG expansion at the DM1 locus, DMPK. Repeat size correlates with phenotype of DM1. DM1: Myotonic dystrophy type 1; DMPK: Dystrophia myotonica protein kinase.

MBNL 1 is most abundant in skeletal muscle, whilst MBNL 2 abnormalities have been identified in brain tissue[77,78]. In DM1, they are sequestered in the nucleus and unable to be utilised by the cell (RNA "loss of function"). CUG-BP, conversely is elevated in DM1 (RNA "gain of function") *via* increased activation and phosphorylation through several other protein mediators such as protein kinase C[79]. CUG-BP has been noted to bind to human cardiac troponin pre-mRNA[80], explaining cardiac abnormalities. Elevated CUB-BP also forms abnormally spliced insulin receptor (IR) pre-mRNA resulting in a switch to IR-A which is an abnormal isoform, thus explaining insulin resistance in adult DM1[81]. Furthermore, CUG-BP elevation has been noted to inhibit myoblast differentiation, form stress granules which reduce DNA repair, and result in loss of CIC-1 chloride channels through disruption of alternative splicing[75,82,83]. Other mechanisms identified include: overexpression of miRNA (non-coding RNA that modulates gene expression post-transcriptionally), increased myoblast cell decay, increased repeat-associated non-ATG translation (translation without an ATG

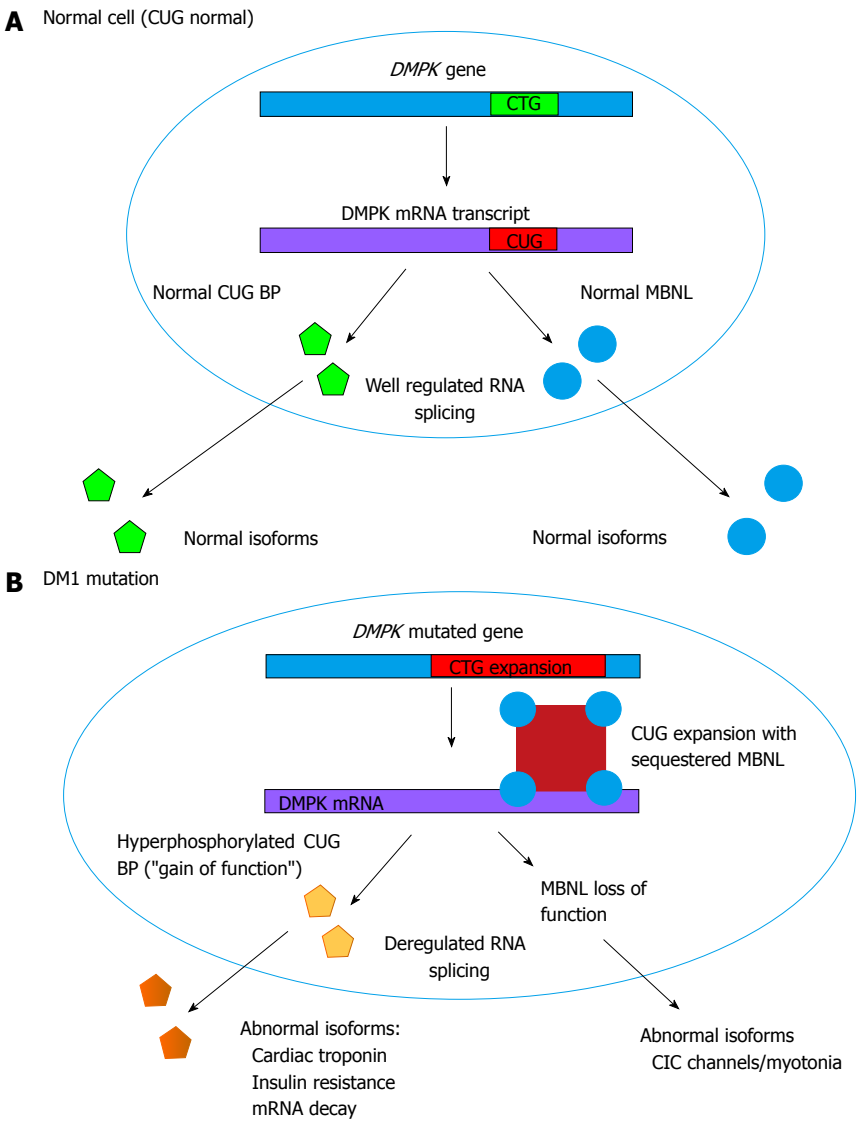

Figure 3 Pathogenic mechanisms in myotonic dystrophy type 1: (A) Normal RNA processing in cell with normal CTG repeats at the myotonic dystrophy type 1 locus; (B) Effects of expanded CTG repeat at the DM1 locus. A: Normal actions of MBNL and CUG BP in regulating alternative splicing within a cell; B: Pathogenic mechanisms involving MBNL and CUG BP, resulting in deregulated alternative splicing. While DM1 mutation is an untranslated CTG expansion, it is expressed at the RNA level and the CUG binds with two RNA binding proteins (CUGBP and MBNL) to disrupt RNA processing and splicing of other genes. For example, altered splicing of chloride channel and insulin receptor transcripts leads to myotonia and insulin resistance, respectively. DM1: Myotonic dystrophy type 1; MBNL: Musclebind-like protein; CUG BP: CUG binding protein.

start code resulting in abnormal protein aggregates), and there may even be a role for promoting oxidative stress[84-87].

NOVEL THERAPIES

There is exciting research in gene therapy that holds much promise for the treatment of myotonic dystrophy. Current management is supportive, but gene therapy may modify disease in the future. Most studies are RNA-based and focus on the RNA mediated pathways of disease (Figure 4). The most promising is antisense therapy. Strands of nucleic acid [called antisense oligonucleotides (AONs)] complimentary to target mutations are synthesised, in the hope that the target mutant sequence is silenced. Studies have effectively targeted exon 7a which codes for the defective chloride channel involved in DM1[88]. Others have effectively inhibited RNA sequestration by binding to CUG mRNA expansions[89] and sites for abnormal MBNL binding[90]. AONs have also been used to degrade the RNA expansions and the mutant DMPK allele through enzymatic actions[91-94]. Effective delivery of AONs remains the main problem with such therapies. Systemic delivery is ideal but AON levels have to be sufficiently abundant to penetrate muscle tissue and have an effect. This is greatly limited by the intact muscle surface membrane, and currently only mouse models have successfully enhanced AON uptake in muscle fibres with systemic administration[95]. Further, the effects of these novel drugs can be very specific and targets only myotonia in muscles, and thus not addressing the multi-

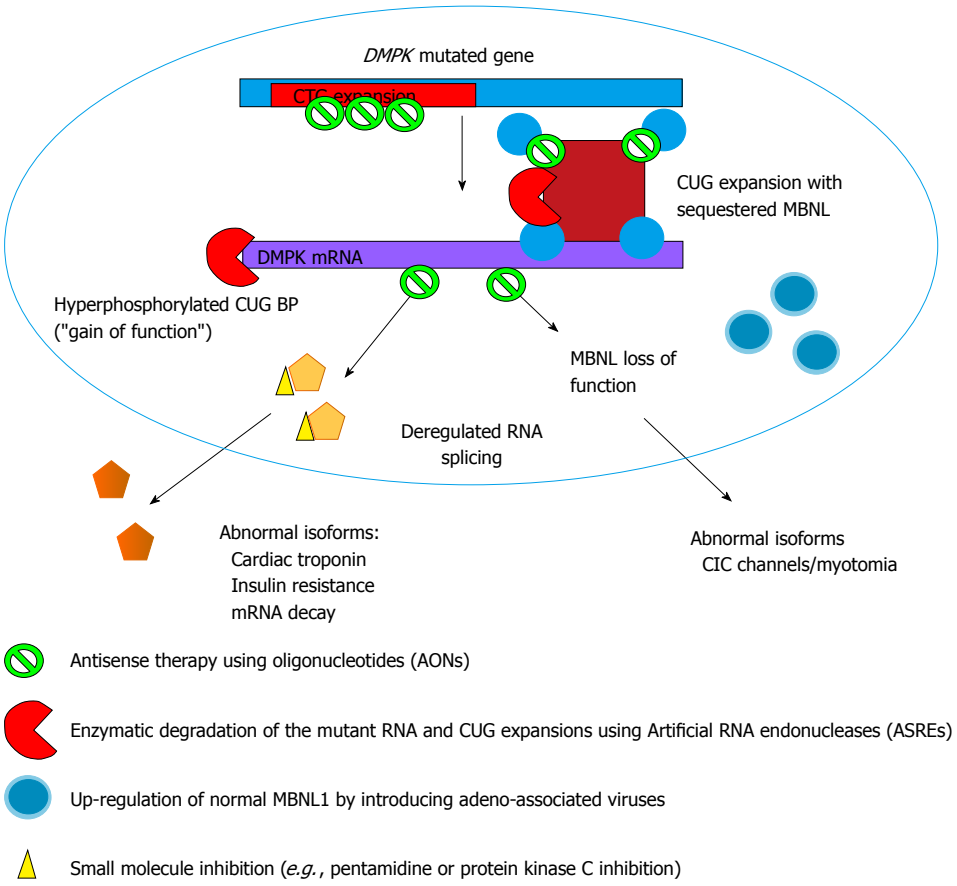

Figure 4 Novel therapies using RNA-based mechanisms to mediate RNA toxicity in a myotonic dystrophy type 1 cell. Promising trials have shown various means and targets of RNA mediated therapy with the aim of reversing or modifying "spliceopathy" and normalising cellular splice protein levels and actions. MBNL: Musclebind-like protein.

systemic problems.

MBNL-1 loss of function is well established as a feature of DM1 pathogenesis and studies have also explored means to up-regulate this splice mediator since it is abnormally sequestered in DM1. AONs have also been used for this but MBNL1 up-regulation has also been achieved in transgenic mice through the introduction of adeno-associated virus. This stimulates the overexpression of MBNL1, overcoming the sequestration and normalising MNBL function[96]. CUG-BP1 activity is increased in DM1, and down-regulation strategies by direct inhibition *via* small molecules like pentamidine or by inhibiting protein kinase C (involved in activating CUG-BP1) which potentially normalises CUG-BP1 levels[79,97]. There have also been studies looking specifically at reducing muscle weakness by introducing anabolic stimuli. Agents studied include testosterone, creatine[98-100], dehydroepiandrosterone[101] and recombinant insulin-like growth factor (IGF-1)[102]. Studies have yet to show improvements in muscle function in patients. Myostatin is known to down-regulate muscle growth and function, and inhibiting its production may be beneficial to DM1 patients; although no trial has been done specifically in DM1[95]. Future therapies will need to address the issues of efficient delivery and global effectiveness, especially in the CNS as this aspect is often most concerning for patients.

CONCLUSION

DM1 is a multisystem disease that predominantly affects muscle strength, cognition, respiratory, central nervous and gastrointestinal systems in neonates and children. Sleep disorders are often under recognised yet a significant morbidity. No effective disease modifying treatment is currently available and neonates and children with DM1 may experience severe physical and intellectual disability, which may be life limiting in congenital DM1. Novel therapies, which target the gene and the pathogenic mechanism of abnormal splicing, are emerging, but multidisciplinary management is currently supportive, incorporating regular surveillance and treatment of manifestations. It is important to develop a standard of care of congenital and childhood-onset patients to optimise outcomes.

ACKNOWLEDGMENTS

Genevieve Ho was awarded the David Walsh Memorial Scholarship.

REFERENCES

1 **Bushby K**, Finkel R, Birnkrant DJ, Case LE, Clemens PR, Cripe L, Kaul A, Kinnett K, McDonald C, Pandya S, Poysky J, Shapiro F, Tomezsko J, Constantin C. Diagnosis and management of Duchenne muscular dystrophy, part 1: diagnosis, and pharmacological and psychosocial management. *Lancet Neurol* 2010; **9**: 77-93 [PMID: 19945913 DOI: 10.1016/S1474-4422(09)70271-6]

2 **Bushby K**, Finkel R, Birnkrant DJ, Case LE, Clemens PR, Cripe L, Kaul A, Kinnett K, McDonald C, Pandya S, Poysky J, Shapiro F, Tomezsko J, Constantin C. Diagnosis and management of Duchenne muscular dystrophy, part 2: implementation of multidisciplinary care. *Lancet Neurol* 2010; **9**: 177-189 [PMID: 19945914 DOI: 10.1016/S1474-4422(09)70272-8]

3 **Wang CH**, Finkel RS, Bertini ES, Schroth M, Simonds A, Wong B, Aloysius A, Morrison L, Main M, Crawford TO, Trela A. Consensus statement for standard of care in spinal muscular atrophy. *J Child Neurol* 2007; **22**: 1027-1049 [PMID: 17761659 DOI: 10.1177/0883073807305788]

4 **Campbell C**, Levin S, Siu VM, Venance S, Jacob P. Congenital myotonic dystrophy: Canadian population-based surveillance study. *J Pediatr* 2013; **163**: 120-5.e1-120-5.e3 [PMID: 23415617 DOI: 10.1016/j.jpeds.2012.12.070]

5 **Echenne B**, Bassez G. Congenital and infantile myotonic dystrophy. *Handb Clin Neurol* 2013; **113**: 1387-1393 [PMID: 23622362 DOI: 10.1016/B978-0-444-59565-2.00009-5]

6 **Hageman AT**, Gabreëls FJ, Liem KD, Renkawek K, Boon JM. Congenital myotonic dystrophy; a report on thirteen cases and a review of the literature. *J Neurol Sci* 1993; **115**: 95-101 [PMID: 8166775 DOI: 10.1016/0022-510X(93)90072-7]

7 **Meola G**, Cardani R. Myotonic dystrophies: An update on clinical aspects, genetic, pathology, and molecular pathomechanisms. *Biochim Biophys Acta* 2015; **1852**: 594-606 [PMID: 24882752 DOI: 10.1016/j.bbadis.2014.05.019]

8 **Echenne B**, Rideau A, Roubertie A, Sébire G, Rivier F, Lemieux B. Myotonic dystrophy type I in childhood Long-term evolution in patients surviving the neonatal period. *Eur J Paediatr Neurol* 2008; **12**: 210-223 [PMID: 17892958 DOI: 10.1016/j.ejpn.2007.07.014]

9 **Wallgren-Pettersson C**, Bushby K, Mellies U, Simonds A. 117th ENMC workshop: ventilatory support in congenital neuromuscular disorders -- congenital myopathies, congenital muscular dystrophies, congenital myotonic dystrophy and SMA (II) 4-6 April 2003, Naarden, The Netherlands. *Neuromuscul Disord* 2004; **14**: 56-69 [PMID: 14659414 DOI: 10.1016/j.nmd.2003.09.003]

10 **Mathieu J**, Allard P, Potvin L, Prévost C, Bégin P. A 10-year study of mortality in a cohort of patients with myotonic dystrophy. *Neurology* 1999; **52**: 1658-1662 [PMID: 10331695]

11 **Kroksmark AK**, Ekström AB, Björck E, Tulinius M. Myotonic dystrophy: muscle involvement in relation to disease type and size of expanded CTG-repeat sequence. *Dev Med Child Neurol* 2005; **47**: 478-485 [PMID: 15991869 DOI: 10.1111/j.1469-8749.2005.tb01175.x]

12 **Harper PS**. Myotonic Dystrophy. 3rd ed. London: W.B. Saunders, 2001

13 **Schara U**, Schoser BG. Myotonic dystrophies type 1 and 2: a summary on current aspects. *Semin Pediatr Neurol* 2006; **13**: 71-79 [PMID: 17027856 DOI: 10.1016/j.spen.2006.06.002]

14 **Pace-Schott EF**, Hobson JA. The neurobiology of sleep: genetics, cellular physiology and subcortical networks. *Nat Rev Neurosci* 2002; **3**: 591-605 [PMID: 12154361 DOI: 10.1038/nrn895]

15 **Hobson JA**, Pace-Schott EF. The cognitive neuroscience of sleep: neuronal systems, consciousness and learning. *Nat Rev Neurosci* 2002; **3**: 679-693 [PMID: 12209117 DOI: 10.1038/nrn915]

16 **Laberge L**, Gagnon C, Dauvilliers Y. Daytime sleepiness and myotonic dystrophy. *Curr Neurol Neurosci Rep* 2013; **13**: 340 [PMID: 23430686 DOI: 10.1007/s11910-013-0340-9]

17 **Quera Salva MA**, Blumen M, Jacquette A, Durand MC, Andre S, De Villiers M, Eymard B, Lofaso F, Heron D. Sleep disorders in childhood-onset myotonic dystrophy type 1. *Neuromuscul Disord* 2006; **16**: 564-570 [PMID: 16934465 DOI: 10.1016/j.nmd.2006.06.007]

18 **Ono S**, Kanda F, Takahashi K, Fukuoka Y, Jinnai K, Kurisaki H, Mitake S, Inagaki T, Nagao K. Neuronal loss in the medullary reticular formation in myotonic dystrophy: a clinicopathological study. *Neurology* 1996; **46**: 228-231 [PMID: 8559381]

19 **Ono S**, Kurisaki H, Sakuma A, Nagao K. Myotonic dystrophy with alveolar hypoventilation and hypersomnia: a clinicopathological study. *J Neurol Sci* 1995; **128**: 225-231 [PMID: 7738599 DOI: 10.1016/0022-510X(94)00244-I]

20 **Culebras A**, Podolsky S, Leopold NA. Absence of sleep-related growth hormone elevations in myotonic dystrophy. *Neurology* 1977; **27**: 165-167 [PMID: 556833]

21 **Johansson A**, Carlström K, Ahrén B, Cederquist K, Krylborg E, Forsberg H, Olsson T. Abnormal cytokine and adrenocortical hormone regulation in myotonic dystrophy. *J Clin Endocrinol Metab* 2000; **85**: 3169-3176 [PMID: 10999804 DOI: 10.1210/jcem.85.9.6794]

22 **Minnerop M**, Weber B, Schoene-Bake JC, Roeske S, Mirbach S, Anspach C, Schneider-Gold C, Betz RC, Helmstaedter C, Tittgemeyer M, Klockgether T, Kornblum C. The brain in myotonic dystrophy 1 and 2: evidence for a predominant white matter disease. *Brain* 2011; **134**: 3530-3546 [PMID: 22131273 DOI: 10.1093/brain/awr299]

23 **Yu H**, Laberge L, Jaussent I, Bayard S, Scholtz S, Raoul M, Pages M, Dauvilliers Y. Daytime sleepiness and REM sleep characteristics in myotonic dystrophy: a case-control study. *Sleep* 2011; **34**: 165-170 [PMID: 21286250]

24 **Cirignotta F**, Mondini S, Zucconi M, Barrot-Cortes E, Sturani C, Schiavina M, Coccagna G, Lugaresi E. Sleep-related breathing impairment in myotonic dystrophy. *J Neurol* 1987; **235**: 80-85 [PMID: 3430195 DOI: 10.1007/BF00718014]

25 **Laberge L**, Bégin P, Dauvilliers Y, Beaudry M, Laforte M, Jean S, Mathieu J. A polysomnographic study of daytime sleepiness in myotonic dystrophy type 1. *J Neurol Neurosurg Psychiatry* 2009; **80**: 642-646 [PMID: 19211594 DOI: 10.1136/jnnp.2008.165035]

26 **Walters AS**, Rye DB. Review of the relationship of restless legs syndrome and periodic limb movements in sleep to hypertension, heart disease, and stroke. *Sleep* 2009; **32**: 589-597 [PMID: 19480225]

27 **Douniol M**, Jacquette A, Cohen D, Bodeau N, Rachidi L, Angeard N, Cuisset JM, Vallée L, Eymard B, Plaza M, Héron D, Guilé JM. Psychiatric and cognitive phenotype of childhood myotonic dystrophy type 1. *Dev Med Child Neurol* 2012; **54**: 905-911 [PMID: 22861906 DOI: 10.1111/j.1469-8749.2012.04379.x]

28 **Angeard N**, Gargiulo M, Jacquette A, Radvanyi H, Eymard B, Héron D. Cognitive profile in childhood myotonic dystrophy type 1: is there a global impairment? *Neuromuscul Disord* 2007; **17**: 451-458 [PMID: 17433680 DOI: 10.1016/j.nmd.2007.02.012]

29 **Angeard N**, Jacquette A, Gargiulo M, Radvanyi H, Moutier S, Eymard B, Héron D. A new window on neurocognitive dysfunction in the childhood form of myotonic dystrophy type 1 (DM1). *Neuromuscul Disord* 2011; **21**: 468-476 [PMID: 21592796 DOI: 10.1016/j.nmd.2011.04.009]

30 **Rubinsztein JS**, Rubinsztein DC, Goodburn S, Holland AJ. Apathy and hypersomnia are common features of myotonic dystrophy. *J Neurol Neurosurg Psychiatry* 1998; **64**: 510-515 [PMID: 9576545 DOI: 10.1136/jnnp.64.4.510]

31 **Ekström AB**, Hakenäs-Plate L, Samuelsson L, Tulinius M, Wentz E. Autism spectrum conditions in myotonic dystrophy type 1: a study on 57 individuals with congenital and childhood forms. *Am J Med Genet B Neuropsychiatr Genet* 2008; **147B**: 918-926 [PMID: 18228241 DOI: 10.1002/ajmg.b.30698]

32 **Kuo HC**, Hsiao KM, Chen CJ, Hsieh YC, Huang CC. Brain magnetic resonance image changes in a family with congenital and classic myotonic dystrophy. *Brain Dev* 2005; **27**: 291-296 [PMID: 15862193 DOI: 10.1016/j.braindev.2004.09.002]

33 **Turner C**, Hilton-Jones D. Myotonic dystrophy: diagnosis, management and new therapies. *Curr Opin Neurol* 2014; **27**: 599-606 [PMID: 25121518 DOI: 10.1097/WCO.0000000000000128]

34 **Veyckemans F**, Scholtes JL. Myotonic dystrophies type 1 and 2: anesthetic care. *Paediatr Anaesth* 2013; **23**: 794-803 [PMID: 23384336 DOI: 10.1111/pan.12120]

35 **Anderson VB**, McKenzie JA, Seton C, Fitzgerald DA, Webster RI, North KN, Joffe DA, Young HK. Sniff nasal inspiratory pressure and sleep disordered breathing in childhood neuromuscular disorders. *Neuromuscul Disord* 2012; **22**: 528-533 [PMID: 22386707 DOI: 10.1016/j.nmd.2012.02.002]

36 **Kerr TP**, Robb SA, Clayden GS. Lower gastrointestinal tract disturbance in congenital myotonic dystrophy. *Eur J Pediatr* 2002; **161**: 468-469 [PMID: 12269262 DOI: 10.1007/s00431-002-0971-3]

37 **Reardon W**, Newcombe R, Fenton I, Sibert J, Harper PS. The natural history of congenital myotonic dystrophy: mortality and long term clinical aspects. *Arch Dis Child* 1993; **68**: 177-181 [PMID: 8481038 DOI: 10.1136/adc.68.2.177]

38 **Rönnblom A**, Andersson S, Hellström PM, Danielsson A. Gastric emptying in myotonic dystrophy. *Eur J Clin Invest* 2002; **32**: 570-574 [PMID: 12190956 DOI: 10.1046/j.1365-2362.2002.01028.x]

39 **Rönnblom A**, Forsberg H, Danielsson A. Gastrointestinal symptoms in myotonic dystrophy. *Scand J Gastroenterol* 1996; **31**: 654-657 [PMID: 8819213 DOI: 10.3109/00365529609009145]

40 **Bellini M**, Biagi S, Stasi C, Costa F, Mumolo MG, Ricchiuti A, Marchi S. Gastrointestinal manifestations in myotonic muscular dystrophy. *World J Gastroenterol* 2006; **12**: 1821-1828 [PMID: 16609987]

41 **Rönnblom A**, Andersson S, Danielsson A. Mechanisms of diarrhoea in myotonic dystrophy. *Eur J Gastroenterol Hepatol* 1998; **10**: 607-610 [PMID: 9855087 DOI: 10.1097/00042737-199807000-00015]

42 **Tarnopolsky MA**, Pearce E, Matteliano A, James C, Armstrong D. Bacterial overgrowth syndrome in myotonic muscular dystrophy is potentially treatable. *Muscle Nerve* 2010; **42**: 853-855 [PMID: 21104859 DOI: 10.1002/mus.21787]

43 **Rönnblom A**, Hellström PM, Holst JJ, Theodorsson E, Danielsson A. Gastric myoelectrical activity and gut hormone secretion in myotonic dystrophy. *Eur J Gastroenterol Hepatol* 2001; **13**: 825-831 [PMID: 11474313 DOI: 10.1097/00042737-200107000-00011]

44 **Rönnblom A**, Danielsson A, el-Salhy M. Intestinal endocrine cells in myotonic dystrophy: an immunocytochemical and computed image analytical study. *J Intern Med* 1999; **245**: 91-97 [PMID: 10356607 DOI: 10.1046/j.1365-2796.1999.00413.x]

45 **Ekström AB**, Tulinius M, Sjöström A, Aring E. Visual function in congenital and childhood myotonic dystrophy type 1. *Ophthalmology* 2010; **117**: 976-982 [PMID: 20346513 DOI: 10.1016/j.ophtha.2010.01.055]

46 **O'Brien TA**, Harper PS. Course, prognosis and complications of childhood-onset myotonic dystrophy. *Dev Med Child Neurol* 1984; **26**: 62-67 [PMID: 6230279 DOI: 10.1111/j.1469-8749.1984.tb04407.x]

47 **Farrar MA**, Vucic S, Johnston HM, du Sart D, Kiernan MC. Pathophysiological insights derived by natural history and motor function of spinal muscular atrophy. *J Pediatr* 2013; **162**: 155-159 [PMID: 22809660 DOI: 10.1016/j.jpeds.2012.05.067]

48 **Moxley RT**. Channelopathies Affecting Skeletal Muscle: Myotonic Disorders Including Myotonic Dystrophy and Periodic Paralysis. In: Jones H, De Vivo D, Darras B, editors. Neuromuscul. Disord. Infancy, Childhood, Adolesc. A Clin. Approach. illustrated, Butterworth-Heinemann, 2003: 783-812

49 **Voet NB**, van der Kooi EL, Riphagen II, Lindeman E, van Engelen BG, Geurts AC. Strength training and aerobic exercise training for muscle disease. *Cochrane Database Syst Rev* 2013; **7**: CD003907 [PMID: 23835682 DOI: 10.1002/14651858.CD003907.pub4]

50 **Trip J**, Drost G, van Engelen BG, Faber CG. Drug treatment for myotonia. *Cochrane Database Syst Rev* 2006; **(1)**: CD004762 [PMID: 16437496 DOI: 10.1002/14651858.CD004762.pub2]

51 **Logigian EL**, Martens WB, Moxley RT, McDermott MP, Dilek N, Wiegner AW, Pearson AT, Barbieri CA, Annis CL, Thornton CA, Moxley RT. Mexiletine is an effective antimyotonia treatment in myotonic dystrophy type 1. *Neurology* 2010; **74**: 1441-1448 [PMID: 20439846 DOI: 10.1212/WNL.0b013e3181dc1a3a]

52 **Engvall M**. On oral health in children and adults with myotonic dystrophy. *Swed Dent J Suppl* 2010; **(203)**: 1-51 [PMID: 20514921]

53 **Sansone VA**, Gagnon C. 207th ENMC Workshop on chronic respiratory insufficiency in myotonic dystrophies: management and implications for research, 27-29 June 2014, Naarden, The Netherlands. *Neuromuscul Disord* 2015; **25**: 432-442 [PMID: 25728518 DOI: 10.1016/j.nmd.2015.01.011]

54 **Lazarus A**, Varin J, Jauvert G, Alonso C, Duboc D. Relationship between cardiac arrhythmias and sleep apnoea in permanently paced patients with type I myotonic dystrophy. *Neuromuscul Disord* 2007; **17**: 392-399 [PMID: 17360183 DOI: 10.1016/j.nmd.2007.01.014]

55 **Machuca-Tzili L**, Brook D, Hilton-Jones D. Clinical and molecular aspects of the myotonic dystrophies: a review. *Muscle Nerve* 2005; **32**: 1-18 [PMID: 15770660 DOI: 10.1002/mus.20301]

56 **Cobo AM**, Poza JJ, Martorell L, López de Munain A, Emparanza JI, Baiget M. Contribution of molecular analyses to the estimation of the risk of congenital myotonic dystrophy. *J Med Genet* 1995; **32**: 105-108 [PMID: 7760317 DOI: 10.1136/jmg.32.2.105]

57 **Redman JB**, Fenwick RG, Fu YH, Pizzuti A, Caskey CT. Relationship between parental trinucleotide GCT repeat length and severity of myotonic dystrophy in offspring. *JAMA* 1993; **269**: 1960-1965 [PMID: 8464127 DOI: 10.1001/jama.269.15.1960]

58 **Martorell L**, Cobo AM, Baiget M, Naudó M, Poza JJ, Parra J. Prenatal diagnosis in myotonic dystrophy type 1. Thirteen years of experience: implications for reproductive counselling in DM1 families. *Prenat Diagn* 2007; **27**: 68-72 [PMID: 17154336 DOI: 10.1002/pd.1627]

59 **Magee AC**, Hughes AE, Kidd A, Lopez De Munain A, Cobo AM, Kelly K, Dean J, Nevin NC. Reproductive counselling for women with myotonic dystrophy. *J Med Genet* 2002; **39**: E15 [PMID: 11897835 DOI: 10.1136/jmg.39.3.e15]

60 **Koch MC**, Grimm T, Harley HG, Harper PS. Genetic risks for children of women with myotonic dystrophy. *Am J Hum Genet* 1991; **48**: 1084-1091 [PMID: 2035529]

61 **Phillips MF**, Steer HM, Soldan JR, Wiles CM, Harper PS. Daytime somnolence in myotonic dystrophy. *J Neurol* 1999; **246**: 275-282 [PMID: 10367695 DOI: 10.1007/s004150050346]

62 **Dauvilliers YA**, Laberge L. Myotonic dystrophy type 1, daytime sleepiness and REM sleep dysregulation. *Sleep Med Rev* 2012; **16**: 539-545 [PMID: 22465566 DOI: 10.1016/j.smrv.2012.01.001]

63 **Annane D**, Moore DH, Barnes PR, Miller RG. Psychostimulants for hypersomnia (excessive daytime sleepiness) in myotonic dystrophy. *Cochrane Database Syst Rev* 2006: **(13)**: CD003218 [PMID: 16855999 DOI: 10.1002/14651858.CD003218.pub2]

64 **Kumar R**. Approved and investigational uses of modafinil: an evidence-based review. *Drugs* 2008; **68**: 1803-1839 [PMID: 18729534 DOI: 10.2165/00003495-200868130-00003]

65 **Hilton-Jones D**, Bowler M, Lochmueller H, Longman C, Petty R, Roberts M, Rogers M, Turner C, Wilcox D. Modafinil for excessive daytime sleepiness in myotonic dystrophy type 1--the patients' perspective. *Neuromuscul Disord* 2012; **22**: 597-603 [PMID: 22425060 DOI: 10.1016/j.nmd.2012.02.005]

66 **Morgenthaler TI**, Kapur VK, Brown T, Swick TJ, Alessi C, Aurora RN, Boehlecke B, Chesson AL, Friedman L, Maganti R, Owens J, Pancer J, Zak R. Practice parameters for the treatment of narcolepsy and other hypersomnias of central origin. *Sleep* 2007; **30**: 1705-1711 [PMID: 18246980]

67 **Brook JD**, McCurrach ME, Harley HG, Buckler AJ, Church D, Aburatani H, Hunter K, Stanton VP, Thirion JP, Hudson T. Molecular basis of myotonic dystrophy: expansion of a trinucleotide (CTG) repeat at the 3' end of a transcript encoding a protein kinase family member. *Cell* 1992; **69**: 385 [PMID: 1568252 DOI: 10.1016/0092-8674(92)90154-5]

68 **Mahadevan M**, Tsilfidis C, Sabourin L, Shutler G, Amemiya C, Jansen G, Neville C, Narang M, Barceló J, O'Hoy K. Myotonic dystrophy mutation: an unstable CTG repeat in the 3' untranslated region of the gene. *Science* 1992; **255**: 1253-1255 [PMID: 1546325 DOI: 10.2307/2876544]

69 **Tsilfidis C**, MacKenzie AE, Mettler G, Barceló J, Korneluk RG. Correlation between CTG trinucleotide repeat length and frequency of severe congenital myotonic dystrophy. *Nat Genet* 1992; **1**: 192-195 [PMID: 1303233 DOI: 10.1038/ng0692-192]

70 **Brunner HG**, Brüggenwirth HT, Nillesen W, Jansen G, Hamel BC, Hoppe RL, de Die CE, Höweler CJ, van Oost BA, Wieringa B. Influence of sex of the transmitting parent as well as of parental allele size on the CTG expansion in myotonic dystrophy (DM). *Am J Hum Genet* 1993; **53**: 1016-1023 [PMID: 8213829]

71 **Lavedan C**, Hofmann-Radvanyi H, Shelbourne P, Rabes JP, Duros C, Savoy D, Dehaupas I, Luce S, Johnson K, Junien C. Myotonic dystrophy: size- and sex-dependent dynamics of CTG meiotic instability, and somatic mosaicism. *Am J Hum Genet* 1993; **52**: 875-883 [PMID: 8098180]

72 **Ashizawa T**, Anvret M, Baiget M, Barceló JM, Brunner H, Cobo AM, Dallapiccola B, Fenwick RG, Grandell U, Harley H. Characteristics of intergenerational contractions of the CTG repeat in myotonic dystrophy. *Am J Hum Genet* 1994; **54**: 414-423 [PMID: 8116611]

73 **Santoro M**, Masciullo M, Pietrobono R, Conte G, Modoni A, Bianchi ML, Rizzo V, Pomponi MG, Tasca G, Neri G, Silvestri G. Molecular, clinical, and muscle studies in myotonic dystrophy type 1 (DM1) associated with novel variant CCG expansions. *J Neurol* 2013; **260**: 1245-1257 [PMID: 23263591 DOI: 10.1007/s00415-012-6779-9]

74 **Timchenko LT**, Timchenko NA, Caskey CT, Roberts R. Novel proteins with binding specificity for DNA CTG repeats and RNA CUG repeats: implications for myotonic dystrophy. *Hum Mol Genet* 1996; **5**: 115-121 [PMID: 8789448 DOI: 10.1093/hmg/5.1.115]

75 **Paul S**, Dansithong W, Kim D, Rossi J, Webster NJ, Comai L, Reddy S. Interaction of muscleblind, CUG-BP1 and hnRNP H proteins in DM1-associated aberrant IR splicing. *EMBO J* 2006; **25**: 4271-4283 [PMID: 16946708 DOI: 10.1038/sj.emboj.7601296]

76 **Mankodi A**, Teng-Umnuay P, Krym M, Henderson D, Swanson M, Thornton CA. Ribonuclear inclusions in skeletal muscle in myotonic dystrophy types 1 and 2. *Ann Neurol* 2003; **54**: 760-768 [PMID: 14681885 DOI: 10.1002/ana.10763]

77 **Holt I**, Jacquemin V, Fardaei M, Sewry CA, Butler-Browne GS, Furling D, Brook JD, Morris GE. Muscleblind-like proteins: similarities and differences in normal and myotonic dystrophy muscle. *Am J Pathol* 2009; **174**: 216-227 [PMID: 19095965 DOI: 10.2353/ajpath.2009.080520]

78 **Charizanis K**, Lee KY, Batra R, Goodwin M, Zhang C, Yuan Y, Shiue L, Cline M, Scotti MM, Xia G, Kumar A, Ashizawa T, Clark HB, Kimura T, Takahashi MP, Fujimura H, Jinnai K, Yoshikawa H, Gomes-Pereira M, Gourdon G, Sakai N, Nishino S, Foster TC, Ares M, Darnell RB, Swanson MS. Muscleblind-like 2-mediated alternative splicing in the developing brain and dysregulation in myotonic dystrophy. *Neuron* 2012; **75**: 437-450 [PMID: 22884328 DOI: 10.1016/j.neuron.2012.05.029]

79 **Kuyumcu-Martinez NM**, Wang GS, Cooper TA. Increased steady-state levels of CUGBP1 in myotonic dystrophy 1 are due to PKC-mediated hyperphosphorylation. *Mol Cell* 2007; **28**: 68-78 [PMID: 17936705 DOI: 10.1016/j.molcel.2007.07.027]

80 **Philips AV**, Timchenko LT, Cooper TA. Disruption of splicing regulated by a CUG-binding protein in myotonic dystrophy. *Science* 1998; **280**: 737-741 [PMID: 9563950 DOI: 10.1126/science.280.5364.737]

81 **Savkur RS**, Philips AV, Cooper TA. Aberrant regulation of insulin receptor alternative splicing is associated with insulin resistance in myotonic dystrophy. *Nat Genet* 2001; **29**: 40-47 [PMID: 11528389]

82 **Huichalaf C**, Sakai K, Jin B, Jones K, Wang GL, Schoser B, Schneider-Gold C, Sarkar P, Pereira-Smith OM, Timchenko N, Timchenko L. Expansion of CUG RNA repeats causes stress and inhibition of translation in myotonic dystrophy 1 (DM1) cells. *FASEB J* 2010; **24**: 3706-3719 [PMID: 20479119 DOI: 10.1096/fj.09-151159]

83 **Charlet-B N**, Savkur RS, Singh G, Philips AV, Grice EA, Cooper TA. Loss of the muscle-specific chloride channel in type 1 myotonic dystrophy due to misregulated alternative splicing. *Mol Cell* 2002; **10**: 45-53 [PMID: 12150906 DOI: 10.1016/S1097-2765(02)00572-5]

84 **Gambardella S**, Rinaldi F, Lepore SM, Viola A, Loro E, Angelini C, Vergani L, Novelli G, Botta A. Overexpression of microRNA-206 in the skeletal muscle from myotonic dystrophy type 1 patients. *J Transl Med* 2010; **8**: 48 [PMID: 20487562 DOI: 10.1186/1479-5876-8-48]

85 **Lee JE**, Lee JY, Wilusz J, Tian B, Wilusz CJ. Systematic analysis of cis-elements in unstable mRNAs demonstrates that CUGBP1 is a key regulator of mRNA decay in muscle cells. *PLoS One* 2010; **5**: e11201 [PMID: 20574513 DOI: 10.1371/journal.pone.0011201]

86 **Zu T**, Gibbens B, Doty NS, Gomes-Pereira M, Huguet A, Stone MD, Margolis J, Peterson M, Markowski TW, Ingram MA, Nan Z, Forster C, Low WC, Schoser B, Somia NV, Clark HB, Schmechel S, Bitterman PB, Gourdon G, Swanson MS, Moseley M, Ranum LP. Non-ATG-initiated translation directed by microsatellite expansions. *Proc Natl Acad Sci USA* 2011; **108**: 260-265 [PMID: 21173221 DOI: 10.1073/pnas.1013343108]

87 **Kumar A**, Kumar V, Singh SK, Muthuswamy S, Agarwal S. Imbalanced oxidant and antioxidant ratio in myotonic dystrophy type 1. *Free Radic Res* 2014; **48**: 503-510 [PMID: 24472045 DOI: 10.3109/10715762.2014.887847]

88 **Wheeler TM**, Lueck JD, Swanson MS, Dirksen RT, Thornton CA. Correction of ClC-1 splicing eliminates chloride channelopathy and myotonia in mouse models of myotonic dystrophy. *J Clin Invest* 2007; **117**: 3952-3957 [PMID: 18008009 DOI: 10.1172/JCI33355]

89 **Wheeler TM**, Leger AJ, Pandey SK, MacLeod AR, Nakamori M, Cheng SH, Wentworth BM, Bennett CF, Thornton CA. Targeting nuclear RNA for in vivo correction of myotonic dystrophy. *Nature* 2012; **488**: 111-115 [PMID: 22859208 DOI: 10.1038/nature11362]

90 **Wheeler TM**, Sobczak K, Lueck JD, Osborne RJ, Lin X, Dirksen RT, Thornton CA. Reversal of RNA dominance by displacement of protein sequestered on triplet repeat RNA. *Science* 2009; **325**: 336-339 [PMID: 19608921 DOI: 10.1126/science.1173110]

91 **Furling D**, Doucet G, Langlois MA, Timchenko L, Belanger E, Cossette L, Puymirat J. Viral vector producing antisense RNA restores myotonic dystrophy myoblast functions. *Gene Ther* 2003; **10**: 795-802 [PMID: 12704419 DOI: 10.1038/sj.gt.3301955]

92 **Mulders SA**, van den Broek WJ, Wheeler TM, Croes HJ, van Kuik-Romeijn P, de Kimpe SJ, Furling D, Platenburg GJ, Gourdon G, Thornton CA, Wieringa B, Wansink DG. Triplet-repeat oligonucleotide-mediated reversal of RNA toxicity in myotonic dystrophy. *Proc Natl Acad Sci USA* 2009; **106**: 13915-13920 [PMID: 19667189 DOI: 10.1073/pnas.0905780106]

93 **Krol J**, Fiszer A, Mykowska A, Sobczak K, de Mezer M, Krzyzosiak WJ. Ribonuclease dicer cleaves triplet repeat hairpins into shorter repeats that silence specific targets. *Mol Cell* 2007; **25**: 575-586 [PMID: 17317629 DOI: 10.1016/j.molcel.2007.01.031]

94 **Zhang W**, Wang Y, Dong S, Choudhury R, Jin Y, Wang Z. Treatment of type 1 myotonic dystrophy by engineering site-specific RNA endonucleases that target (CUG)(n) repeats. *Mol Ther* 2014; **22**: 312-320 [PMID: 24196578 DOI: 10.1038/mt.2013.251]

95 **Wheeler TM**. Myotonic dystrophy: therapeutic strategies for the future. *Neurotherapeutics* 2008; **5**: 592-600 [PMID: 19019311 DOI: 10.1016/j.nurt.2008.08.001]

96 **Lin X**, Miller JW, Mankodi A, Kanadia RN, Yuan Y, Moxley RT, Swanson MS, Thornton CA. Failure of MBNL1-dependent post-natal splicing transitions in myotonic dystrophy. *Hum Mol Genet* 2006; **15**: 2087-2097 [PMID: 16717059 DOI: 10.1093/hmg/ddl132]

97 **Warf MB**, Nakamori M, Matthys CM, Thornton CA, Berglund JA. Pentamidine reverses the splicing defects associated with myotonic dystrophy. *Proc Natl Acad Sci USA* 2009; **106**: 18551-18556 [PMID: 19822739 DOI: 10.1073/pnas.0903234106]

98 **Griggs RC**, Pandya S, Florence JM, Brooke MH, Kingston W, Miller JP, Chutkow J, Herr BE, Moxley RT. Randomized controlled trial of testosterone in myotonic dystrophy. *Neurology* 1989; **39**: 219-222 [PMID: 2521699 DOI: 10.1212/wnl.39.2.219]

99 **Walter MC**, Reilich P, Lochmüller H, Kohnen R, Schlotter B, Hautmann H, Dunkl E, Pongratz D, Müller-Felber W. Creatine monohydrate in myotonic dystrophy: a double-blind, placebo-

controlled clinical study. *J Neurol* 2002; **249**: 1717-1722 [PMID: 12529796 DOI: 10.1007/s00415-002-0923-x]

100 **Schneider-Gold C**, Beck M, Wessig C, George A, Kele H, Reiners K, Toyka KV. Creatine monohydrate in DM2/PROMM: a double-blind placebo-controlled clinical study. Proximal myotonic myopathy. *Neurology* 2003; **60**: 500-502 [PMID: 12578937 DOI: 10.1212/01.wnl.0000044405.29988.e1]

101 **Sugino M**, Ohsawa N, Ito T, Ishida S, Yamasaki H, Kimura F, Shinoda K. A pilot study of dehydroepiandrosterone sulfate in myotonic dystrophy. *Neurology* 1998; **51**: 586-589 [PMID: 9710041 DOI: 10.1212/wnl.51.2.586]

102 **Heatwole CR**, Eichinger KJ, Friedman DI, Hilbert JE, Jackson CE, Logigian EL, Martens WB, McDermott MP, Pandya SK, Quinn C, Smirnow AM, Thornton CA, Moxley RT. Open-label trial of recombinant human insulin-like growth factor 1/recombinant human insulin-like growth factor binding protein 3 in myotonic dystrophy type 1. *Arch Neurol* 2011; **68**: 37-44 [PMID: 20837825 DOI: 10.1001/archneurol.2010.227]

P- Reviewer: Rajeshwari K, Sener RN
S- Editor: Ji FF **L- Editor**: A **E- Editor**: Jiao XK

World Journal of Clinical Pediatrics

Submit a Manuscript: http://www.wjgnet.com/esps/
Help Desk: http://www.wjgnet.com/esps/helpdesk.aspx
DOI: 10.5409/wjcp.v4.i4.81

World J Clin Pediatr 2015 November 8; 4(4): 81-93
ISSN 2219-2808 (online)
© 2015 Baishideng Publishing Group Inc. All rights reserved.

REVIEW

Caffeine therapy in preterm infants

Hesham Abdel-Hady, Nehad Nasef, Abd Elazeez Shabaan, Islam Nour

Hesham Abdel-Hady, Nehad Nasef, Abd Elazeez Shabaan, Islam Nour, Neonatal Intensive Care Unit, Mansoura University Children's Hospital, Mansoura 35516, Egypt

Author contributions: All authors contributed to literature review, manuscript writing, critical review of final manuscript.

Conflict-of-interest statement: No conflict of interest is declared by any of the authors.

Open-Access: This article is an open-access article which was selected by an in-house editor and fully peer-reviewed by external reviewers. It is distributed in accordance with the Creative Commons Attribution Non Commercial (CC BY-NC 4.0) license, which permits others to distribute, remix, adapt, build upon this work non-commercially, and license their derivative works on different terms, provided the original work is properly cited and the use is non-commercial. See: http://creativecommons.org/licenses/by-nc/4.0/

Correspondence to: Hesham Abdel-Hady, Professor of Pediatrics and Neonatology, Neonatal Intensive Care Unit, Mansoura University Children's Hospital, Gomhoria street, Mansoura 35516, Egypt. hehady@yahoo.com
Telephone: +2-10-05278051
Fax: +2-50-2234092

Received: March 30, 2015
Peer-review started: March 31, 2015
First decision: June 3, 2015
Revised: July 11, 2015
Accepted: August 20, 2015
Article in press: August 21, 2015
Published online: November 8, 2015

Abstract

Caffeine is the most commonly used medication for treatment of apnea of prematurity. Its effect has been well established in reducing the frequency of apnea, intermittent hypoxemia, and extubation failure in mechanically ventilated preterm infants. Evidence for additional short-term benefits on reducing the incidence of bronchopulmonary dysplasia and patent ductus arteriosus has also been suggested. Controversies exist among various neonatal intensive care units in terms of drug efficacy compared to other methylxanthines, dosage regimen, time of initiation, duration of therapy, drug safety and value of therapeutic drug monitoring. In the current review, we will summarize the available evidence for the best practice in using caffeine therapy in preterm infants.

Key words: Apnea; Caffeine; Preterm; Methylxanthines

© The Author(s) 2015. Published by Baishideng Publishing Group Inc. All rights reserved.

Core tip: Caffeine is among the most commonly prescribed medications in neonatal intensive care units, it has now largely replaced other methylxanthines. Caffeine reduces the frequency of apnea, intermittent hypoxemia, facilitates extubation from mechanical ventilation, and reduces the incidence of bronchopulmonary and patent ductus arteriosus in preterm infants. There are controversies regarding the safety and efficacy of high-dose, early *vs* late administration, duration of therapy, value in older gestational age infants and the value of therapeutic drug monitoring.

Abdel-Hady H, Nasef N, Shabaan AE, Nour I. Caffeine therapy in preterm infants. *World J Clin Pediatr* 2015; 4(4): 81-93 Available from: URL: http://www.wjgnet.com/2219-2808/full/v4/i4/81.htm DOI: http://dx.doi.org/10.5409/wjcp.v4.i4.81

INTRODUCTION

Methylxanthines are among the most commonly used medications in preterm infants[1,2]. They have been used for the treatment of apnea of prematurity (AOP) over the past 40 years[3-8]. Caffeine has now largely replaced theophylline and aminophylline for treatment of AOP because of its wider therapeutic index and longer half-life that allows once daily administration[9]. In the pioneering study "Caffeine for Apnea of Prematurity (CAP) trial"[10], infants who received caffeine had a lower incidence

of bronchopulmonary (BPD) and severe retinopathy of prematurity (ROP). On follow-up at 18 mo, they had a lower incidence of cerebral palsy and cognitive delay. Approximately one-half of this neuroprotective effect was attributed to improved respiratory morbidity, including an approximate 1 wk reduction in the duration of mechanical ventilation[11]. By 5 years of age, the reduction in rates of cerebral palsy with caffeine treatment was no longer statistically significant, but the gross motor function improved and the incidence of developmental coordination disorder was reduced[12,13]. A recent study, demonstrated that early caffeine initiation is associated with reduced neonatal morbidity, including a decreased incidence of BPD and of patent ductus arteriosus (PDA) requiring treatment in very low-birth-weight (VLBW) infants. Many NICUs have changed their practice toward earlier initiation of caffeine therapy[14,15]. Cost-effectiveness analysis showed caffeine to be both cost-saving and beneficial[16]. Moreover, methylxanthines increase the success of extubation of preterm infants within 1 wk of age[17].

MECHANISM OF ACTION

The pharmacological effects of caffeine in AOP include: (1) stimulation of the respiratory center in the medulla; (2) increased sensitivity to carbon dioxide; (3) increased skeletal muscle tone; (4) enhanced diaphragmatic contractility; (5) increased minute ventilation; (6) increased metabolic rate; and (7) increased oxygen consumption[18-20]. Caffeine also stimulates the central nervous and cardiovascular systems, enhances catecholamine secretion, has a diuretic effect, and alters glucose homeostasis[21].

Caffeine acts as a selective adenosine antagonist at the A2a receptors and a non-selective adenosine antagonist at A1 receptor[22,23]. Through this action it modulates many neurotransmitters, such as noradrenaline, dopamine, serotonin, acetylcholine, glutamine, and gamma-aminobutyric acid[24]. It also increases cyclic adenosine 3′,5′ monophosphate and cyclic guanosine monophosphate leading to bronchodilatation[9,22,25]. Moreover, caffeine enhances peripheral chemoreceptors activity, thus it can terminate apnea and initiate normal breathing[26]. Caffeine may also have an anti-inflammatory action in the immature lung[27]. The benefits of caffeine therapy on respiratory functions increase the success of early nasal-continuous positive airway pressure (CPAP) therapy, facilitate earlier weaning from mechanical ventilation, and reduce ventilator-induced lung injury. This is particularly important in the early neonatal period, when AOP is prevalent and early nasal-CPAP therapy may not be successful in all infants[28-31].

PHARMACOKINETICS

The route of administration of caffeine does not affect its pharmacokinetics as there is almost complete bioavailability after its administration orally or intravenously. Caffeine is absorbed rapidly from the gastrointestinal tract with minimal-to-no first pass metabolism, and its peak plasma concentrations frequently occur in less than one h[20,32,33].

Caffeine is hydrophobic and distributes rapidly without tissue accumulation. It is rapidly distributed into the brain, and in preterm infants the levels of caffeine in the cerebro-spinal fluid approximate the plasma levels. In infants the mean volume of distribution is 0.8-0.9 L/kg compared to 0.6 L/kg in adults[33].

Biotransformation of caffeine occurs in the liver mainly by microsomal cytochrome P450 mono-oxygenases (CYP1A2) and partially by xanthine oxidase. The predominant process of caffeine metabolism in the preterm infant is N7-demethylation, which matures at about the age of 4 mo[31]. The demethylation process is postnatal age dependent, regardless of gestational age or birth weight[31,34-36]. There is a higher rate of caffeine metabolism in female than male neonates[31].

The metabolism of caffeine in the preterm infants is limited by immaturity of the hepatic enzymes. The plasma half-life of caffeine remains prolonged for as long as 38 wk gestation and reaches adult levels at the age of 3 to 4.5 mo[34,37]. Furthermore, the caffeine half-life may be prolonged further in exclusively breastfed infants and infants with cholestatic jaundice[38]. Interconversion between caffeine and theophylline has been reported with a greater rate of theophylline converting to caffeine than caffeine converting to theophylline. Approximately 3%-10% of caffeine converts to theophylline, whereas up to 50% of theophylline converts to caffeine[33,39,40].

In the first weeks of life, caffeine is eliminated mainly by renal excretion[38]. Caffeine elimination is slower in the premature and term neonate, compared with older children and adults, because of immaturity of renal functions. Several factors influence caffeine clearance in neonates including gestational age, postconceptional age and parenteral nutrition; thus preterm infants receiving parenteral nutrition, may need closer monitoring of plasma caffeine concentrations[38,41]. Renal clearance of caffeine differs between preterm and full-term neonates due to lower glomerular filtration rates (GFR) in preterm infants[36]. The GFR increases rapidly during the first 2 wk of life and then rises steadily until 8-12 mo of age, when adult values are reached[42]. Theophylline has a serum half-life ranging from 24.7 to 36.5 h, and an estimated clearance from 0.02 to 0.05 L/kg per hour in premature neonates, compared with healthy adults, who have an estimated elimination half-life of 6.3 h[43]. On the other hand, caffeine has a longer serum half-life of 101 h in neonates[44], whereas its half-life ranges from 3 to 6 h in adults[43]. Differences in the pharmacokinetics of caffeine and theophylline are shown in Table 1.

CAFFEINE *VS* THEOPHYLLINE

The comparative effectiveness of caffeine *vs* theophylline

Table 1 Pharmacokinetics of caffeine compared to theophylline

	Caffeine	Theophylline
Mechanism of action:		
CNS stimulation	More active	Less active
Cardiac stimulation	Less active	More active
Diuresis	Less active	More active
Loading dose	20 to 40 mg/kg per dose Ⅳ/PO	4 to 8 mg/kg per dose Ⅳ
Maintenance dose	5 to 8 mg/kg per dose once daily Ⅳ/PO	1.5 to 3 mg/kg per dose every 8 to 12 h Ⅳ
Plasma half-life (h)	40 to 230 (mean, 103)	12 to 64 (mean, 30)
Therapeutic level (mg/L)	5 to 25	7 to 12
Toxic level (mg/L)	> 40 to 50	> 20
Adverse effects:		
Cardiovascular	Tachycardia, dysrhythmia	Tachycardia, dysrhythmia
Gastrointestinal	Feeding intolerance, GER	Feeding intolerance, GER
CNS	Jitteriness, irritability, seizures	Jitteriness, irritability, seizures, decreased CBF
Signs of toxicity	Tachycardia, cardiac failure, pulmonary edema, hypertonia, sweating, metabolic disturbances	Tachycardia, agitation, hypokalemia, diuresis, gastric bleeding, seizure
Metabolism	Excreted unchanged or N-demethylation *via* CYP P450 (CYP1A2) liver-methyltransferase pathway	Excreted unchanged or undergoes 8-hydroxylation *via* CYP1A2 and CYP2E1
Inter-conversion	3% to 8% converted to theophylline *via* CYP1A2	25% converted to caffeine *via* methylation
Routine blood level	Not required	Required
Elimination	86% unchanged in urine	50% unchanged in urine
CSF level	Similar to plasma concentrations	Crosses into the CSF
Clearance (L/kg per hour)[9,43]	0.002 to 0.017	0.02 to 0.05

CNS: Central nervous system; CBF: Cerebral blood flow; CSF: Cerebrospinal fluid; GER: Gastroesophageal reflux; GIT: Gastrointestinal tract.

regarding improving respiratory function has been evaluated by several small studies conducted over the past 40 years[45-48]. A meta-analysis of previous trials revealed that caffeine is as effective as theophylline on both apnea/bradycardia with some therapeutic advantages of caffeine over theophylline such as, better enteral absorption, higher therapeutic ratio, and longer half-life as well as less adverse effects such as tachycardia and feeding intolerance[49]. Moreover, caffeine has less plasma concentration fluctuations, and greater central nervous system penetration without producing fluctuations in cerebral blood flow[20]. Furthermore, theophylline therapy has been associated with seizures and hypokalemia in the neonatal population[50]. All the aforementioned benefits of caffeine make it the drug of choice in the treatment of AOP.

However, the results of the above mentioned meta-analysis[49] should be interpreted with caution due to limitations, including small sample size of the included studies; variations in the gestational age, birth weight and clinical status of the infants enrolled in the studies; and absence of data regarding drugs safety and their effects on neurodevelopmental term outcomes. Larger randomized controlled trials (RCTs) enrolling lower birth weight and gestational age infants are highly recommended to demonstrate the effectiveness and safety of varying doses of caffeine compared to theophylline with respect to important clinical outcomes such as safety, growth and long-term effects on neurodevelopmental outcome.

DOSAGE

The current loading and maintenance dosage of caffeine, which have been approved by the Food and Drug Administration (FDA) for treatment of AOP is 20 mg/kg (equivalent to 10 mg/kg of caffeine base) and 10 mg/kg per dose (equivalent to 5 mg/kg caffeine base) once daily, respectively[20,51]. The goal is to achieve a therapeutic blood level of 5 to 25 mg/L of caffeine in preterm infants less than 32 wk post-menstrual age (PMA). However, higher loading and maintenance doses of caffeine have been evaluated in various settings of treatment for AOP and to facilitate of extubation from mechanical ventilation (Table 2). In the CAP trial, Schmidt *et al*[10] used a loading dose of 20 mg/kg and a maintenance dose of 5 to 10 mg/kg per dose once daily of caffeine citrate for treatment of apnea in preterm infants. Prior to the CAP trial, a loading dose of 50 mg/kg caffeine citrate (25 mg/kg caffeine base) was shown to be more effective in reducing apneic episodes within 8 h than a loading dose of 25 mg/kg in preterm infants[48]. Furthermore, a daily maintenance dose of 30 mg/kg caffeine citrate was reported to be administered safely in preterm infants[52].

Steer *et al*[53] found that a high dose regimen of 20 mg/kg caffeine citrate, given 24 h before a planned extubation in preterm infants, reduced the rate of extubation failure compared to a low dose regimen of 5 mg/kg caffeine citrate with no effect on infant mortality, major neonatal morbidity, death, or severe disability. Shah and Wai[54] compared two dosing regimens of caffeine (loading dose of 20 mg/kg over 30 min and maintenance dose of 5 mg/kg per day *vs* loading dose of 10 mg/kg over 30 min and maintenance dose of 2.5 mg/kg per day) in preterm infants less than 34 wk gestation and found that the higher dose caffeine was associated with lower frequency of shallow breathing,

Table 2 Recommended caffeine doses

Trial	Design	Population	Intervention	Outcomes	Main results
Scanlon *et al*[48] United Kingdom	Prospective, randomized, controlled trial	44 preterm infants less than 31 wk gestation	High (loading 25 mg/kg and maintenance 6 mg/kg per day) *vs* low (loading 12.5 mg/kg and maintenance 3 mg/kg per day) caffeine citrate given 24 h prior to extubation	Frequency of apnea	High dose caffeine significantly decreased the frequency of apnea
Steer *et al*[52] Australia	Prospective, randomized, blinded, controlled trial	127 preterm infants less than 32 wk gestation	Three dosing regimens of caffeine citrate (3, 15 and 30 mg/kg) for peri-extubation management of ventilated preterm infants	Successful extubation defined as staying off ventilation for 7 d post-extubation	No statistically significant difference in the incidence of successful extubation however, infants in the two higher dose groups had statistically significantly less documented apnea
Steer *et al*[53] Australia	Prospective, randomized, blinded, controlled trial	234 preterm infants less than 30 wk gestation on mechanical ventilation	High (loading 80 mg/kg and maintenance 20 mg/kg per day) *vs* low (loading 20 mg/kg and maintenance 5 mg/kg per day) caffeine citrate given 24 h prior to extubation	Primary: Successful extubation of mechanically ventilated infants Secondary: Frequency of apnea	High dose caffeine significantly increased the chance for successful extubation, decreased the frequency of apnea and shortened the duration of respiratory support
Shah *et al*[54] Singapore	Prospective, case control trial	Preterm infants less than 34 wk gestation	High (loading 20 mg/kg and maintenance 5 mg/kg per day) *vs* low (loading 10 mg/kg and maintenance 2.5 mg/kg per day) caffeine citrate	Primary: Frequency of apnea, desaturation, and shallow breathing Secondary: Side effect of caffeine, BPD, and ROP	High-dose caffeine significantly reduced episodes of apnea and shallow breathing without side effects
Gray *et al*[125] Australia	Prospective, randomized, blinded, controlled trial	287 preterm infants less than 30 wk gestation exhibit AOP or require mechanical ventilation	Loading dose of 40 mg/kg followed by two maintenance doses of either 20 or 5 mg/kg per day	Primary: Cognitive development at 1 yr of age on the Griffiths Mental Development Scales Secondary: Neonatal morbidity, death and disability, temperament at 1 yr and behavior at 2 yr of age	High maintenance dose was associated with borderline benefit in cognitive outcome without increasing morbidity, temperament or behavior disorders
Mohammed *et al*[55] Egypt	Prospective, randomized, blinded, controlled trial	120 preterm infants less than 32 wk gestation exhibit AOP or require mechanical ventilation	High (loading 40 mg/kg and maintenance 20 mg/kg per day) *vs* low (loading 20 mg/kg and maintenance 10 mg/kg per day) caffeine citrate	Primary: Successful extubation of mechanically ventilated infants Secondary: Frequency and documented days of apnea	High dose caffeine significantly increased the chance for successful extubation, decreased frequency of apnea

BPD: Bronchopulmonary; ROP: Retinopathy of prematurity; AOP: Apnea of prematurity.

apnea, bradycardia and cyanosis without significant increase in the rate of side effects. In a recent RCT, we have found that the use of high loading (20 mg/kg caffeine base) and maintenance (10 mg/kg caffeine base) doses of caffeine was associated with a decreased chance for extubation failure in mechanically ventilated preterm infants and decreased the frequency of apnea without significant side effects[55].

Clinical practice varies considerably between NICUs. Most of NICUs in the US do not exceed a loading dose of 20 mg/kg and a maintenance dose of 10 mg/kg per day of caffeine citrate. Some NICUs outside the US use, maintenance doses as high as 20 mg/kg per day[15]. Until further evidence exists from large, well-designed RCTs and meta-analyses we recommend using the FDA-approved doses of 20 mg/kg and 10 mg/kg per day of caffeine citrate as loading and maintenance doses, respectively.

TIMING OF CAFFEINE THERAPY

Methylxanthines have been used to treat apnea in preterm infants for more than 40 years[3,56]. Subsequent studies reported potential advantages for early therapy, which prompted physicians to initiate methylxanthines as a prophylactic therapy before the occurrence of apnea[7]. Moreover, the initial beneficial neurodevelopmental effect demonstrated in the CAP trial[10,11] re-promoted the use of prophylactic caffeine therapy among different NICUs. In a meta-analysis of two RCTs that included 104 preterm infants, prophylactic caffeine therapy did not decrease the frequency of apnea, bradycardia, or episodes of hypoxemia and did not shorten the duration of mechanical ventilation[57]. However, none of the trials included in this meta-analysis reported long-term outcomes for prophylactic methylxanthine therapy. In a retrospective analysis of a large database including over 29000 VLBW infants from Pediatrix Medical Group, Dobson *et al*[14] found that early initiation of caffeine therapy (within 3 d of life) was associated with a lower incidence of BPD, less treatment of PDA, and a shorter duration of mechanical ventilation.

A recent study[58] demonstrated that early initiation of caffeine therapy (within 2 h of age) in non-intubated preterm infants was not associated with a reduction in the need for intubation or vasopressors by 12 h of age. However, it was associated with improved hemodynamic status as measured by blood pressure and superior vena cava flow. Patel *et al*[59] in a retrospective cohort study including 140 preterm neonates have demonstrated that early caffeine therapy (initiated within 3 d of life) was associated with decreased incidence of the composite outcome of death or BPD adjusted odds ratio (AOR: 0.26, 95%CI: 0.09-0.70), PDA requiring treatment (AOR: 0.28, 95%CI: 0.10-0.73), and duration of mechanical ventilation.

In a large retrospective study that included data from 29 NICUs participating in the Canadian Neonatal Network and conducted over more than 5000 preterm infants less than 31 wk gestation, prophylactic (initiated within 2 d after birth) caffeine therapy was associated with decreased odds of a composite outcome of death or BPD (AOR: 0.81, 95%CI: 0.67-0.98) and PDA (AOR: 0.74, 95%CI: 0.62-0.89) with no difference in mortality (AOR: 0.98, 95%CI: 0.70-1.37), necrotizing enterocolitis (NEC) (AOR: 0.88, 95%CI: 0.65-1.20), severe ROP (AOR: 0.78, 95%CI: 0.56-1.10), or severe neurological injury (AOR: 0.80, 95%CI: 0.63-1.01)[60].

Most of the previous trials were either retrospective data analysis, which could be subject to selection bias, or prospective but not powered or designed to detect short and long-term benefits of prophylactic caffeine therapy. It was also unclear from previous data, whether these beneficial short and long-term effects of caffeine are attributed to a real effect of the drug or due to shortening the duration of mechanical ventilation. Given the uncertainty of the evidence, more RCTs are needed to evaluate the short and long-term benefits of prophylactic caffeine therapy in mechanically ventilated and non-ventilated preterm infants.

DURATION OF CAFFEINE THERAPY

There are no clinical trials to support decisions about when to discontinue caffeine therapy in preterm infants. However, because AOP is not common past 34 wk gestation, caffeine therapy should be continued until preterm infants are 34 to 36 wk corrected gestational age and free of any apnea episodes for at least 8 d[61]. Despite the existence of apnea and sudden infant death syndrome in preterm and late preterm infants after discharge from the NICU[62], continuation of caffeine therapy at home is not recommended.

In a recent prospective RCT, late discontinuation of caffeine therapy at 40 wk PMA significantly reduced the episodes of IH in preterm infants compared to standard discontinuation at 34-35 wk gestation[63]. Although previous animal and human studies have shown that IH is pro-inflammatory and may result in cardio-respiratory instability, ROP, and neurodevelopmental deficits[64-66]; the clinical relevance of late discontinuation of caffeine therapy beyond 35 wk gestation is yet to be established in further RCTs.

THERAPEUTIC EFFECTS

Apnea of prematurity

AOP is a developmental disorder caused by immaturity of the respiratory control mechanisms[67,68], and consequently exhibited a widely variable incidence according to gestational age and birth weight. It was estimated to occur in virtually all infants born at less than 28 wk gestation or less than 1000 g[69,70], 50% of infants born between 30-32 wk[71], as well as in 50% of infants born at 33-35 wk gestation[72]. In most infants, apneic episodes cease by term gestation[73], though apnea might persist beyond term in the most immature infants born less than 28 wk gestation[74].

In 2012, an updated Cochrane review[75] with an aggregate meta-analysis of five trials (two trials of caffeine) that included 192 preterm infants with apnea, revealed that infants treated with methylxanthine compared with those who received placebo had less apneic events relative risk (RR: 0.44, 95%CI: 0.32-0.60) and less need for intermittent positive pressure ventilation (RR: 0.34, 95%CI: 0.12-0.97). Analysis of the two trials evaluating caffeine use[76,77], also found significantly less treatment failure (RR: 0.46, 95%CI: 0.27-0.78). Although, the CAP trial[10] was included in the updated review, the data from this trial were not pooled with the other studies as it was not primarily designed to evaluate the efficacy of caffeine for alleviation of apnea-related symptoms. In the CAP trial[10], caffeine therapy was associated with younger PMA at last supplemental oxygen use compared to placebo. The earlier weaning from mechanical ventilation with caffeine ultimately

supports a decrease in the frequency of apnea[27].

Of particular interest, in a subsequent report of the CAP trial[10], the reduction of duration of mechanical ventilation was only evident in those who received caffeine in the first 3 d of life[78]. In response to this result, several retrospective analyses comparing early (within 3 d of life) *vs* late start of caffeine therapy were conducted and revealed that the early start of therapy was associated with less incidence of BPD, less treatment of PDA, and shorter duration of mechanical ventilation[14,59,60].

According to the evidence above, caffeine is considered the first-choice drug for treatment of AOP as a result of the better safety profile compared to theophylline, alongside its associated respiratory and neuroprotective benefits.

Prevention of extubation failure

The CAP trial had not directly reported extubation failure rates, but the caffeine group was associated with reduction in PMAs at last use of positive pressure ventilation, and endotracheal intubation[10]. A meta-analysis of six studies reported that prophylactic methylxanthine treatment in intubated preterm infants results in a significant reduction in failure of extubation within 1 wk (RR: 0.48, 95%CI: 0.32-0.71)[17]. Steer *et al*[52] conducted two randomized, double-blind clinical trials comparing different dosing regimens of caffeine commenced in the pre-extubation period. In the first trial, 127 infants born at less than 32 wk were enrolled and randomly assigned to 3 groups according to maintenance dosages of caffeine citrate (3, 15 and 30 mg/kg). Although there was no statistically significant difference in the primary outcome of the failure of extubation between groups, reported apnea episodes were significantly reduced in infants in the 2 higher dose groups. The second trial[53], compared a two dose regimens (20 mg/kg *vs* 5 mg/kg) in 120 preterm with gestational age less than 30 wk, the high-dose regimen was associated with a significant reduction in extubation failure (15% *vs* 29.8%; RR: 0.51, 95%CI: 0.31-0.85) number needed to treat (NNT: 7). The two groups did not differ in infant mortality, major neonatal morbidity, or severe disability at 12 mo corrected age. Furthermore, subgroup analysis based on gestational age revealed that infants born at less than 28 wk gained more respiratory benefit of a higher dose of caffeine as evidenced by a significant reduction of mechanical ventilation duration and more marked reduction of extubation failure rate (NNT: 3). In a recent pilot, randomized, double blinded study comparing two different dosing regimens of caffeine citrate (loading dose, 20 mg/kg; maintenance dose, 10 mg/kg *vs* loading dose, 40 mg/kg; maintenance dose, 20 mg/kg); the use of high, in comparison to low, dose caffeine was associated with a significant reduction of extubation failure among mechanically ventilated preterm infants and fewer apnea episodes[55].

The exact mechanisms of increased chances of successful extubation in association of caffeine are still unclear, however, caffeine may improve respiratory mechanics through mounting central respiratory drive[79,80], improving respiratory muscle strength[81], inducing diuresis and hence improving lung compliance[82].

Postoperative apnea

Preterm infants, who undergo general anesthesia for surgical procedures may exhibit postoperative apnea episodes. The risk of postoperative apneas is increased in babies who previously experienced apnea[83,84], younger PMA[84,85], BPD[84] and pre-operative anemia[86]. Henderson-Smart *et al*[87] conducted a meta-analysis of three trials that compared administration of caffeine during or immediately after induction of anesthesia, with placebo, as prophylaxis for postoperative apnea. Results revealed that caffeine use was associated with significant reduction of postoperative apnea and bradycardia (RR: 0.09, 95%CI: 0.02-0.34). Therefore, use of caffeine to prevent postoperative apnea in infants born prematurely is recommended; however, more studies are warranted to resolve if all preterm infants should receive caffeine adjunctive to general anesthesia or only those with one of the previously mentioned risk factors.

Bronchiolitis-related apnea

Infants with bronchiolitis may exhibit episodes of apnea, which may require assisted ventilation. Infants who were born prematurely and those less than two months old are more vulnerable to bronchiolitis-related apnea[88]. Two case reports involving a total of 3 infants, who were born preterm and presented with bronchiolitis-related apneas, showed improvement of apnea after aminophylline therapy[89,90]. Furthermore, two retrospective reviews showed that caffeine use in those infants may be associated with significant reduction of need for mechanical ventilation[91,92]. So an appropriately powered RCT evaluating efficacy and safety of caffeine as a treatment of bronchiolitis-related apnea is needed.

Bronchopulmonary dysplasia

Bronchopulmonary dysplasia (BPD) is a common complication in preterm infants, which may be associated with significant mortality[93], alongside deleterious long-term pulmonary[94,95] and neurodevelopmental morbidities[96,97]. One of the major findings for the secondary short-term outcomes of the CAP trial is significant reduction of BPD incidence in infants who received caffeine (36%) *vs* (47%) in the placebo group (OR: 0.63, 95%CI: 0.52-0.76; $P < 0.001$). This decrement of BPD rates was attributed in part to a shorter duration (about 1 wk) of endotracheal intubation and positive pressure ventilation in the caffeine-treated patients compared with the controls[10]. Notably, the short-term respiratory benefits of caffeine were most significant when treatment was started in the first 3 d of life[78].

Recently, in a large multicenter cohort study using data of 62056 VLBW infants, the use of early caffeine therapy within the first three days of life was associated with a lower incidence of BPD compared with later use (23% *vs* 31%, OR: 1.23, 95%CI: 1.05-1.43)[14]. Another two retrospective reports revealed similar results[60,98]. A clinical trial is currently conducted by Bancalari to evaluate short-term respiratory benefits of early caffeine use commenced within the first five days of life in mechanically ventilated preterm infants born less than 31 wk of gestation (ClinicalTrials, gov, NCT01751724).

The pulmonary protective effects of caffeine in neonates may be, at least partly due to reduction of pulmonary inflammation[99], as evidenced by inhibition of proinflammatory cytokines in both *in vitro* and *in vivo* clinical studies[100-103]. In addition, accumulating evidence has established beneficial effects of caffeine on pulmonary mechanics. In animal models with respiratory distress syndrome, early caffeine therapy in combination with prophylactic surfactant was associated with reduced airway resistance, enhanced lung compliance, and improved ventilator efficiency index within the first 24 h after birth[29]. In agreement with this, human studies reported upgrading of pulmonary function parameters following caffeine administration as exhibited by improved minute ventilation[18], decreased total lung resistance[28], and increased respiratory muscle contractility[19,81].

Intermittent hypoxemia

Intermittent hypoxemia (IH) is defined as brief, repetitive episodes of decreased hemoglobin oxygen saturation from a normoxic baseline followed by reoxygenation and return to normoxia. IH occurs frequently in preterm infants, even until term-equivalent age and after cessation of any clinically apparent apnea-associated symptoms[63,104]. Severe and frequent episodes of decreased hemoglobin oxygen saturation in early infancy have been shown to increase the risk of later neurodevelopmental impairments[105,106]. Furthermore, Di Fiore *et al*[66] reported a significant association between IH and severity of ROP.

A recent prospective, multicenter RCT enrolled 105 infants, who were born less than 32 wk gestation and formerly treated with caffeine, were randomly assigned to either extended caffeine treatment compared to usual caffeine discontinuation. The results revealed significant reductions in IH at 35 and 36 wk PMA with prolonged caffeine treatment[63]. However, further studies are needed to evaluate the optimum dosing regimen of caffeine required to alleviate IH and long-term effects of extended use.

PDA

The post-hoc analysis of the CAP trial revealed that infants in the caffeine group were significantly less likely to require pharmacological treatment for PDA closure compared with infants in the control group (29% *vs* 38% adjusted OR: 0.67, 95%CI: 0.54-0.82). In addition, caffeine therapy was associated with reduced risk of surgical ligation of PDA (adjusted OR: 0.29, 95%CI: 0.2-0.43)[10]. Furthermore, evidence from retrospective studies found that early caffeine therapy within the first 3 d of age was associated with significant reduction of incidence of PDA requiring treatment compared with later initiation of therapy[14,59,61].

The beneficial effects of caffeine on PDA may be attributed to favorable hemodynamic changes, including increase in cardiac index, stroke volume, and heart rate, alongside its diuretic and prostaglandin antagonistic properties[107-109]. Also, caffeine use was reported to be associated with increased blood pressure with no significant changes of systemic vascular resistance[107].

Neuroprotective effects

Animal studies found that adenosine A1 receptors activation contributed to hypoxia-induced periventricular white matter injury[110-112]. In agreement with this, caffeine administration in hypoxia-exposed neonatal pups was associated with enhanced myelination and reduced ventriculomegaly[110,111,113]. Moreover, caffeine potentiates neural plasticity at the level of N-methyl-D-aspartate receptors with documented altered morphology of neural synapses and increased size of dendritic spines[114,115]. However, other animal studies raised concerns about long-term consequences of exposing the growing brain to caffeine. Silva *et al*[116] reported that maternal caffeine consumption in rodents during pregnancy and lactation may have adverse effects on the neural development and adult behavior of their offspring. Also, postnatal caffeine treatment of neonatal mice was associated with altered astrocytogenesis[117].

Several studies evaluated short-term neurological effects of caffeine use in preterm infants. Two observational studies reported enhanced cerebral cortical activity in the brains of preterm infants treated with caffeine[118,119]. Also, caffeine-treated preterm infants exhibited improved measures of auditory processing[120]. Studies assessing the effect of caffeine on sleep organization in preterm infants exhibited contradictory results[26,121,122]. However, in a recently published study, evaluation of sleep architecture of 201 children aged 5-12 years who were previously enrolled in the CAP trial revealed no long-term effects on sleep duration or sleep apnea during childhood[123].

The CAP trial[10] found a higher patient survival rate without neurodevelopmental disability (cognitive delay, cerebral palsy, severe hearing loss or bilateral blindness) at a corrected age of 18 to 21 mo in infants within the caffeine group compared with those in the placebo group (59.8% *vs* 53.8%; adjusted OR: 0.77, 95%CI: 0.64-0.93, P = 0.008). Of note, caffeine use nearly halved the rate of cerebral palsy[11]. Subsequent follow-up of 1640 of infants enrolled in the CAP trial, at the age of 5 years, demonstrated no significant difference between the two groups in the combined outcome of death or severe neurodevelopmental impairment (78.9% *vs* 75.2% adjusted OR: 0.82, 95%CI: 0.65-1.03)[78].

Although, by 5 years of age, there was no significant difference in rates of cerebral palsy between both groups, there was a significant reduction of the incidence of developmental coordination disorder in the caffeine treated group (11.3% *vs* 15.2% adjusted OR: 0.70, 95%CI: 0.51-0.95)[13]. The authors attributed the improvements in motor function to improved cerebral white matter micro-structural development as demonstrated in magnetic resonance imaging (MRI) done at term equivalent age[124].

Gray *et al*[125] randomized 287 infants to receive one of two maintenance-dose regimens of caffeine citrate (20 *vs* 5 mg/kg per day). The results of their trial revealed no significant difference in adverse outcomes related to temperament and behavior at 1 and 2 years of age. In addition, infants in the higher-dose group exhibited a trend towards higher cognitive scores at 1 year of age.

Cerebral blood flow

Methylxanthines are non-specific inhibitors of A1 and A2a adenosine receptors, therefore, attenuates adenosine induced vasodilation that can potentially impair cerebral blood flow. Such effect has been reported in adults[126]. Hoecker *et al*[127,128] found that caffeine citrate administration at a loading dose of 50 mg/kg in preterm infants; either as a single or divided doses; was associated with significant reduction of cerebral blood flow. Another trial revealed a significant reduction in the cerebral oxygenation, and cerebral blood flow velocities 1 h after administration of 20 mg/kg loading dose of caffeine citrate with partial recovery at 4 h[129]. However, there were no documented changes of cerebral hemodynamics in preterm infants after the administration of the maintenance dose of caffeine citrate (5 mg/kg once a day)[130].

ROP

In the CAP trial, ROP detection rates did not differ significantly between both groups[10], however fewer infants in the caffeine group exhibited severe ROP compared to the control group (5.1% *vs* 7.9%; adjusted OR: 0.61, 95%CI: 0.42-0.89)[11]. The authors attributed that to the shorter duration of positive airway pressure and supplemental oxygen in caffeine-treated patients. In addition, improvement of IH episodes associated with caffeine use may decrease the severity of ROP[63].

Growth

The CAP trial revealed that infants in the caffeine group gained less weight than those in the control group during the first 3 wk after randomization[10]. However, follow-up of infants at 18 to 21 m showed no long-term difference in weight gain among infants in both groups[11]. Moreover, Bauer *et al*[131] reported increased energy expenditure (2.1 to 3 kcal/kg per hour) and oxygen consumption (7 to 8.8 mL/kg per minute) in caffeine-treated preterm infants compared with baseline measurements. Also, caffeine use was associated with less weight gain during the four-week study period and infants receiving caffeine required a lower incubator temperature to maintain a normal body temperature[131]. In a recently published clinical trial comparing two dosing regimens of caffeine citrate in preterm infants (loading dose, 20 mg/kg; maintenance dose, 10 mg/kg *vs* loading dose, 40 mg/kg; maintenance dose, 20 mg/kg); we reported no significant difference in weight gain between both groups. In agreement with this, Steer *et al*[53] have conducted a study comparing maintenance caffeine doses of 5 and 20 mg/kg per day and found no difference in the overall weight gain between both groups, however infants who received higher dose required longer time to regain birth weight.

Renal

Caffeine exerts a diuretic effect through increasing creatinine clearance, as an indicator of GFR, within 12 h of administration[108]. Also, methylxanthines use was reported to be associated with increased urinary calcium excretion[132]. However, caffeine did not alter serum calcium, phosphorus, sodium, or potassium concentrations[9].

Gastrointestinal

AOP and gastroesophageal reflux (GER) are relatively common in preterm infants, however, there is no evidenced temporal relationship between both conditions[133,134]. Mehtylxanthines may aggravate reflux through delayed gastric emptying and decreasing tone of lower oesophageal sphincter[135,136], they also increase gastrin secretion[137]. Clinical trials did not find aggravation of GER symptoms in caffeine-treated preterm infants[138].

Caffeine citrate administration in preterm infants at a loading dose of 25 to 50 mg/kg were reported to be associated with a reduction of mesenteric blood flow velocities[119,127,128,139], whereas a single 20 mg/kg intravenous loading dose of caffeine citrate did not cause significant changes in superior mesenteric artery flow velocities. In the CAP trial, there were no significant differences in the rates of NEC between both groups[10]. In a recent RCT study, we reported no increment in the rates of NEC in preterm infants after receiving a loading dose of caffeine citrate of 20 mg/kg per day followed by maintenance doses of 10 mg/kg per day compared to standard-dose regimen[55].

Anti-inflammatory effect

The immunomodulatory effects of caffeine may be related to blocking of adenosine receptors located on the surface of immune cells and subsequent up-regulation of Toll-like receptors[140]. Chavez Valdez *et al*[103] had conducted an observational study to determine cytokine level changes in 26 caffeine-treated preterm infants. Results revealed that caffeine levels within the therapeutic range (10-20 mg/L) were associated with a decrease in interleukin-6, tumor necrosis factor-α (pro-inflammatory cytokines) levels, and an increase in interleukin-10 (anti-inflammatory cytokine) levels. However, caffeine levels outside the therapeutic range

were associated with a proinflammatory profile.

ADVERSE EFFECTS

Caffeine has various dose-related side effects on different systems. Accidental administration of high dose caffeine in preterm infants was associated with tachycardia, tachypnea, agitation, irritability, tremor, hypertonia, and tonic-clonic movements representative of seizure activity[141]. The CAP trial and its subsequent reports of outcomes did not reveal any significant short or long-term adverse effects of caffeine therapy in the NICU[10,11]. In the RCTs using high-dose caffeine therapy, the initial slow rate of growth[53] and clinically insignificant tachycardia[55] were the only reported side effects. Metabolic acidosis and hyperglycemia have been reported in acute caffeine toxicity and accidental overdose[141,142].

THERAPEUTIC DRUG MONITORING

Most published researches do not support routine therapeutic drug monitoring (TDM) when caffeine is given at standard doses, as the majority of neonates were found to have plasma concentrations within the recommended therapeutic range (5.5-23.7 mg/L)[51,143,144]. However, TDM may be necessary when higher doses are used or toxicities are suspected[143].

ECONOMIC IMPACT OF CAFFEINE THERAPY

A recent study evaluated the cost per survivor without neurodevelopmental impairment in patients enrolled in the CAP trial (n = 1869); caffeine was found to be a cost-saving therapy compared with the placebo. This effect is mainly caused by the reduced number of days on mechanical ventilation[16]. However, this study has some limitations which may affect the precision of these results such as the existence of retrospective analysis of cost-effectiveness data. In addition, certain resource utilization data were not evaluated adequately in the CAP trial such as costs of inter-hospital transport, post-discharge use of drugs, and other outpatient healthcare services. Moreover, consensus panels recommended that outcomes measured should be expressed in terms of quality-adjusted life-years rather than biological outcomes used in the CAP trial, such as the survival without neurodevelopmental impairment. Finally, they applied Canadian costs from a single center although the trial was an international multicenter trial involving 9 countries.

CONCLUSION

Caffeine is the preferred first-line of treatment of AOP as it has a wider therapeutic range and is associated with less adverse events compared to theophylline. Further RCTs are needed to assess the safety and efficacy of high-dose caffeine especially on long-term neurodevelopmental outcomes, early prophylactic *vs* late caffeine therapy, which gestational age candidate for prophylactic therapy, duration of caffeine therapy, and efficacy of caffeine therapy in infants older than 34 wk gestation.

REFERENCES

1 **Clark RH**, Bloom BT, Spitzer AR, Gerstmann DR. Reported medication use in the neonatal intensive care unit: data from a large national data set. *Pediatrics* 2006; **117**: 1979-1987 [PMID: 16740839 DOI: 10.1542/peds.2005-1707]

2 **Hsieh EM**, Hornik CP, Clark RH, Laughon MM, Benjamin DK, Smith PB. Medication use in the neonatal intensive care unit. *Am J Perinatol* 2014; **31**: 811-821 [PMID: 24347262 DOI: 10.1055/s-0033-1361933]

3 **Kuzemko JA**, Paala J. Apnoeic attacks in the newborn treated with aminophylline. *Arch Dis Child* 1973; **48**: 404-406 [PMID: 4703073 DOI: 10.1136/adc.48.5.404]

4 **Schmidt B**, Davis PG, Roberts RS. Timing of caffeine therapy in very low birth weight infants. *J Pediatr* 2014; **164**: 957-958 [PMID: 24630349 DOI: 10.1016/j.jpeds.2014.01.054]

5 **Aranda JV**, Gorman W, Bergsteinsson H, Gunn T. Efficacy of caffeine in treatment of apnea in the low-birth-weight infant. *J Pediatr* 1977; **90**: 467-472 [PMID: 14241 DOI: 10.1016/S0022-3476(77)80718-X]

6 **Kreutzer K**, Bassler D. Caffeine for apnea of prematurity: a neonatal success story. *Neonatology* 2014; **105**: 332-336 [PMID: 24931325 DOI: 10.1159/000360647]

7 **Schoen K**, Yu T, Stockmann C, Spigarelli MG, Sherwin CM. Use of methylxanthine therapies for the treatment and prevention of apnea of prematurity. *Paediatr Drugs* 2014; **16**: 169-177 [PMID: 24399614 DOI: 10.1007/s40272-013-0063-z]

8 **Dobson NR**, Hunt CE. Pharmacology review: Caffeine use in neonates: Indications, pharmacokinetics, clinical effects, outcomes. *NeoReviews* 2013; **14**: e540-e550 [DOI: 10.1542/neo.14-11-e540]

9 **Natarajan G**, Lulic-Botica M, Aranda J. Pharmacology review clinical pharmacology of caffeine in the newborn. *NeoReviews* 2007; **8**: e214-e221 [DOI: 10.1542/neo.8-5-e214]

10 **Schmidt B**, Roberts RS, Davis P, Doyle LW, Barrington KJ, Ohlsson A, Solimano A, Tin W. Caffeine therapy for apnea of prematurity. *N Engl J Med* 2006; **354**: 2112-2121 [PMID: 16707748 DOI: 10.1056/NEJMoa054065]

11 **Schmidt B**, Roberts RS, Davis P, Doyle LW, Barrington KJ, Ohlsson A, Solimano A, Tin W. Long-term effects of caffeine therapy for apnea of prematurity. *N Engl J Med* 2007; **357**: 1893-1902 [PMID: 17989382 DOI: 10.1056/NEJMoa073679]

12 **Schmidt B**, Anderson PJ, Doyle LW, Dewey D, Grunau RE, Asztalos EV, Davis PG, Tin W, Moddemann D, Solimano A, Ohlsson A, Barrington KJ, Roberts RS. Survival without disability to age 5 years after neonatal caffeine therapy for apnea of prematurity. *JAMA* 2012; **307**: 275-282 [PMID: 22253394 DOI: 10.1001/jama.2011.2024]

13 **Doyle LW**, Schmidt B, Anderson PJ, Davis PG, Moddemann D, Grunau RE, O'Brien K, Sankaran K, Herlenius E, Roberts R. Reduction in developmental coordination disorder with neonatal caffeine therapy. *J Pediatr* 2014; **165**: 356-359.e2 [PMID: 24840756 DOI: 10.1016/j.jpeds.2014.04.016]

14 **Dobson NR**, Patel RM, Smith PB, Kuehn DR, Clark J, Vyas-Read S, Herring A, Laughon MM, Carlton D, Hunt CE. Trends in caffeine use and association between clinical outcomes and timing of therapy in very low birth weight infants. *J Pediatr* 2014; **164**: 992-998.e3 [PMID: 24461786 DOI: 10.1016/j.jpeds.2013.12.025]

15 **Abu Jawdeh EG**, O'Riordan M, Limrungsikul A, Bandyopadhyay A, Argus BM, Nakad PE, Supapannachart S, Yunis KA, Davis PG, Martin RJ. Methylxanthine use for apnea of prematurity among an international cohort of neonatologists. *J Neonatal Perinatal Med*

2013; **6**: 251-256 [PMID: 24246598 DOI: 10.3233/NPM-1371013]
16 **Dukhovny D**, Lorch SA, Schmidt B, Doyle LW, Kok JH, Roberts RS, Kamholz KL, Wang N, Mao W, Zupancic JA. Economic evaluation of caffeine for apnea of prematurity. *Pediatrics* 2011; **127**: e146-e155 [PMID: 21173002 DOI: 10.1542/peds.2010-1014]
17 **Henderson-Smart DJ**, Davis PG. Prophylactic methylxanthines for endotracheal extubation in preterm infants. *Cochrane Database Syst Rev* 2010; **(12)**: CD000139 [PMID: 21154342 DOI: 10.1002/14651858.cd000139.pub2]
18 **Aranda JV**, Turmen T, Davis J, Trippenbach T, Grondin D, Zinman R, Watters G. Effect of caffeine on control of breathing in infantile apnea. *J Pediatr* 1983; **103**: 975-978 [PMID: 6644439 DOI: 10.1016/S0022-3476(83)80735-5]
19 **Kraaijenga JV**, Hutten GJ, de Jongh FH, van Kaam AH. The Effect of Caffeine on Diaphragmatic Activity and Tidal Volume in Preterm Infants. *J Pediatr* 2015; **167**: 70-75 [PMID: 25982138 DOI: 10.1016/j.jpeds.2015.04.040]
20 **Comer AM**, Perry CM, Figgitt DP. Caffeine citrate: a review of its use in apnoea of prematurity. *Paediatr Drugs* 2001; **3**: 61-79 [PMID: 11220405 DOI: 10.2165/00128072-200103010-00005]
21 **Aranda JV**, Chemtob S, Laudignon N, Sasyniuk BI. Pharmacologic effects of theophylline in the newborn. *J Allergy Clin Immunol* 1986; **78**: 773-780 [PMID: 3534058 DOI: 10.1016/0091-6749(86)90060-6]
22 **Wilson CG**, Martin RJ, Jaber M, Abu-Shaweesh J, Jafri A, Haxhiu MA, Zaidi S. Adenosine A2A receptors interact with GABAergic pathways to modulate respiration in neonatal piglets. *Respir Physiol Neurobiol* 2004; **141**: 201-211 [PMID: 15239970 DOI: 10.1016/j.resp.2004.04.012]
23 **Mayer CA**, Haxhiu MA, Martin RJ, Wilson CG. Adenosine A2A receptors mediate GABAergic inhibition of respiration in immature rats. *J Appl Physiol* 2006; **100**: 91-97 [PMID: 16141383 DOI: 10.1152/japplphysiol.00459.2005]
24 **Fredholm BB**, Bättig K, Holmén J, Nehlig A, Zvartau EE. Actions of caffeine in the brain with special reference to factors that contribute to its widespread use. *Pharmacol Rev* 1999; **51**: 83-133 [PMID: 10049999]
25 **Herlenius E**, Lagercrantz H. Adenosinergic modulation of respiratory neurones in the neonatal rat brainstem in vitro. *J Physiol* 1999; **518** (Pt1): 159-172 [PMID: 10373698 DOI: 10.1111/j.1469-7793.1999.0159r.x]
26 **Chardon K**, Bach V, Telliez F, Cardot V, Tourneux P, Leke A, Libert JP. Effect of caffeine on peripheral chemoreceptor activity in premature neonates: interaction with sleep stages. *J Appl Physiol* 2004; **96**: 2161-2166 [PMID: 14966021 DOI: 10.1152/japplphysiol.01160.2003]
27 **Bancalari E**. Caffeine for apnea of prematurity. *N Engl J Med* 2006; **354**: 2179-2181 [PMID: 16707756 DOI: 10.1056/NEJMe068028]
28 **Davis JM**, Bhutani VK, Stefano JL, Fox WW, Spitzer AR. Changes in pulmonary mechanics following caffeine administration in infants with bronchopulmonary dysplasia. *Pediatr Pulmonol* 1989; **6**: 49-52 [PMID: 2704583 DOI: 10.1002/ppul.1950060112]
29 **Yoder B**, Thomson M, Coalson J. Lung function in immature baboons with respiratory distress syndrome receiving early caffeine therapy: a pilot study. *Acta Paediatr* 2005; **94**: 92-98 [PMID: 15858967 DOI: 10.1111/j.1651-2227.2005.tb01794.x]
30 **Finer NN**, Carlo WA, Walsh MC, Rich W, Gantz MG, Laptook AR, Yoder BA, Faix RG, Das A, Poole WK, Donovan EF, Newman NS, Ambalavanan N, Frantz ID, Buchter S, Sánchez PJ, Kennedy KA, Laroia N, Poindexter BB, Cotten CM, Van Meurs KP, Duara S, Narendran V, Sood BG, O'Shea TM, Bell EF, Bhandari V, Watterberg KL, Higgins RD. Early CPAP versus surfactant in extremely preterm infants. *N Engl J Med* 2010; **362**: 1970-1979 [PMID: 20472939 DOI: 10.1056/NEJMoa0911783]
31 **al-Alaiyan S**, al-Rawithi S, Raines D, Yusuf A, Legayada E, Shoukri MM, el-Yazigi A. Caffeine metabolism in premature infants. *J Clin Pharmacol* 2001; **41**: 620-627 [PMID: 11402630 DOI: 10.1177/00912700122010500]
32 **Donovan JL**, DeVane CL. A primer on caffeine pharmacology and its drug interactions in clinical psychopharmacology. *Psychopharmacol Bull* 2001; **35**: 30-48 [PMID: 12397877]
33 **Johnson PJ**. Caffeine citrate therapy for apnea of prematurity. *Neonatal Netw* 2011; **30**: 408-412 [PMID: 22052121 DOI: 10.1891/0730-0832.30.6.408]
34 **Aranda JV**, Collinge JM, Zinman R, Watters G. Maturation of caffeine elimination in infancy. *Arch Dis Child* 1979; **54**: 946-949 [PMID: 533298 DOI: 10.1136/adc.54.12.946]
35 **Cazeneuve C**, Pons G, Rey E, Treluyer JM, Cresteil T, Thiroux G, D'Athis P, Olive G. Biotransformation of caffeine in human liver microsomes from foetuses, neonates, infants and adults. *Br J Clin Pharmacol* 1994; **37**: 405-412 [PMID: 8054245 DOI: 10.1111/j.1365-2125.1994.tb05706.x]
36 **Kearns GL**, Abdel-Rahman SM, Alander SW, Blowey DL, Leeder JS, Kauffman RE. Developmental pharmacology--drug disposition, action, and therapy in infants and children. *N Engl J Med* 2003; **349**: 1157-1167 [PMID: 13679531 DOI: 10.1056/NEJMra035092]
37 Acute respiratory disease. *Med J Aust* 1968; **2**: 1142-1143 [PMID: 4303017 DOI: 10.1016/S0022-3476(79)80047-5]
38 **Le Guennec JC**, Billon B, Paré C. Maturational changes of caffeine concentrations and disposition in infancy during maintenance therapy for apnea of prematurity: influence of gestational age, hepatic disease, and breast-feeding. *Pediatrics* 1985; **76**: 834-840 [PMID: 4058995]
39 **Davis JM**, Spitzer AR, Stefano JL, Bhutani V, Fox WW. Use of caffeine in infants unresponsive to theophylline in apnea of prematurity. *Pediatr Pulmonol* 1987; **3**: 90-93 [PMID: 3588062 DOI: 10.1002/ppul.1950030210]
40 **Francart SJ**, Allen MK, Stegall-Zanation J. Apnea of prematurity: caffeine dose optimization. *J Pediatr Pharmacol Ther* 2013; **18**: 45-52 [PMID: 23616735 DOI: 10.5863/1551-6776-18.1.45]
41 **Falcão AC**, Fernández de Gatta MM, Delgado Iribarnegaray MF, Santos Buelga D, García MJ, Dominguez-Gil A, Lanao JM. Population pharmacokinetics of caffeine in premature neonates. *Eur J Clin Pharmacol* 1997; **52**: 211-217 [PMID: 9218928 DOI: 10.1007/s002280050276]
42 **Arant BS**. Developmental patterns of renal functional maturation compared in the human neonate. *J Pediatr* 1978; **92**: 705-712 [PMID: 641617 DOI: 10.1016/S0022-3476(78)80133-80134]
43 **Carrillo JA**, Benitez J. Clinically significant pharmacokinetic interactions between dietary caffeine and medications. *Clin Pharmacokinet* 2000; **39**: 127-153 [PMID: 10976659 DOI: 10.2165/00003088-200039020-00004]
44 **Charles BG**, Townsend SR, Steer PA, Flenady VJ, Gray PH, Shearman A. Caffeine citrate treatment for extremely premature infants with apnea: population pharmacokinetics, absolute bioavailability, and implications for therapeutic drug monitoring. *Ther Drug Monit* 2008; **30**: 709-716 [PMID: 19057373 DOI: 10.1097/FTD.0b013e3181898b6f]
45 **Brouard C**, Moriette G, Murat I, Flouvat B, Pajot N, Walti H, de Gamarra E, Relier JP. Comparative efficacy of theophylline and caffeine in the treatment of idiopathic apnea in premature infants. *Am J Dis Child* 1985; **139**: 698-700 [PMID: 4014092 DOI: 10.1001/archpedi.1985.02140090060028]
46 **Bairam A**, Boutroy MJ, Badonnel Y, Vert P. Theophylline versus caffeine: comparative effects in treatment of idiopathic apnea in the preterm infant. *J Pediatr* 1987; **110**: 636-639 [PMID: 3559816 DOI: 10.1016/S0022-3476(87)80569-3]
47 **Fuglsang G**, Nielsen K, Kjaer Nielsen L, Sennels F, Jakobsen P, Thelle T. The effect of caffeine compared with theophylline in the treatment of idiopathic apnea in premature infants. *Acta Paediatr Scand* 1989; **78**: 786-788 [PMID: 2688355 DOI: 10.1111/j.1651-2227.1989.tb11147.x]
48 **Scanlon JE**, Chin KC, Morgan ME, Durbin GM, Hale KA, Brown SS. Caffeine or theophylline for neonatal apnoea? *Arch Dis Child* 1992; **67**: 425-428 [PMID: 1586184]
49 **Henderson-Smart DJ**, Steer PA. Caffeine versus theophylline for apnea in preterm infants. *Cochrane Database Syst Rev* 2010: **(1)**: CD000273 [PMID: 20091506 DOI: 10.1002/14651858.cd000273.pub2]
50 **Hascoet JM**, Hamon I, Boutroy MJ. Risks and benefits of therapies

for apnoea in premature infants. *Drug Saf* 2000; **23**: 363-379 [PMID: 11085344 DOI: 10.2165/00002018-200023050-00002]
51 **Leon AE**, Michienzi K, Ma CX, Hutchison AA. Serum caffeine concentrations in preterm neonates. *Am J Perinatol* 2007; **24**: 39-47 [PMID: 17195151 DOI: 10.1055/s-2006-958163]
52 **Steer PA**, Flenady VJ, Shearman A, Lee TC, Tudehope DI, Charles BG. Periextubation caffeine in preterm neonates: a randomized dose response trial. *J Paediatr Child Health* 2003; **39**: 511-515 [PMID: 12969204 DOI: 10.1046/j.1440-1754.2003.00207.x]
53 **Steer P**, Flenady V, Shearman A, Charles B, Gray PH, Henderson-Smart D, Bury G, Fraser S, Hegarty J, Rogers Y, Reid S, Horton L, Charlton M, Jacklin R, Walsh A. High dose caffeine citrate for extubation of preterm infants: a randomised controlled trial. *Arch Dis Child Fetal Neonatal Ed* 2004; **89**: F499-F503 [PMID: 15499141 DOI: 10.1136/adc.2002.023432]
54 **Shah VA**, Wai WC. Effectivenes and side effects of 2 different doses of caffeine citrate in preventing apnea in VLBW premature infants. Hot Topics in Neonatology Conference; 2011 Dec 4-6; Washington/DC, United States. Nemours Education, 2011
55 **Mohammed S**, Nour I, Shabaan AE, Shouman B, Abdel-Hady H, Nasef N. High versus low-dose caffeine for apnea of prematurity: a randomized controlled trial. *Eur J Pediatr* 2015; **174**: 949-956 [PMID: 25644724 DOI: 10.1007/s00431-015-2494-8]
56 **Kuzemko JA**. Aminophylline in apnoeic attacks of newborn. *Lancet* 1973; **1**: 1509 [PMID: 4123169 DOI: 10.1016/S0140-6736(73)91845-X]
57 **Henderson-Smart DJ**, Steer PA. Prophylactic methylxanthine for preventing of apnea in preterm infants. *Cochrane Database Syst Rev* 2000; **(2)**: CD000432 [PMID: 10796361]
58 **Katheria AC**, Sauberan JB, Akotia D, Rich W, Durham J, Finer NN. A Pilot Randomized Controlled Trial of Early versus Routine Caffeine in Extremely Premature Infants. *Am J Perinatol* 2015; **32**: 879-886 [PMID: 25607226]
59 **Patel RM**, Leong T, Carlton DP, Vyas-Read S. Early caffeine therapy and clinical outcomes in extremely preterm infants. *J Perinatol* 2013; **33**: 134-140 [PMID: 22538326 DOI: 10.1038/jp.2012.52]
60 **Lodha A**, Seshia M, McMillan DD, Barrington K, Yang J, Lee SK, Shah PS. Association of early caffeine administration and neonatal outcomes in very preterm neonates. *JAMA Pediatr* 2015; **169**: 33-38 [PMID: 25402629 DOI: 10.1001/jamapediatrics.2014.2223]
61 **Darnall RA**, Kattwinkel J, Nattie C, Robinson M. Margin of safety for discharge after apnea in preterm infants. *Pediatrics* 1997; **100**: 795-801 [PMID: 9346978 DOI: 10.1542/peds.100.5.795]
62 **Hunt CE**. Ontogeny of autonomic regulation in late preterm infants born at 34-37 weeks postmenstrual age. *Semin Perinatol* 2006; **30**: 73-76 [PMID: 16731280 DOI: 10.1053/j.semperi.2006.02.005]
63 **Rhein LM**, Dobson NR, Darnall RA, Corwin MJ, Heeren TC, Poets CF, McEntire BL, Hunt CE. Effects of caffeine on intermittent hypoxia in infants born prematurely: a randomized clinical trial. *JAMA Pediatr* 2014; **168**: 250-257 [PMID: 24445955 DOI: 10.1001/jamapediatrics.2013.4371]
64 **Urlesberger B**, Kaspirek A, Pichler G, Müller W. Apnoea of prematurity and changes in cerebral oxygenation and cerebral blood volume. *Neuropediatrics* 1999; **30**: 29-33 [PMID: 10222458 DOI: 10.1055/s-2007-973453]
65 **Nagata N**, Saji M, Ito T, Ikeno S, Takahashi H, Terakawa N. Repetitive intermittent hypoxia-ischemia and brain damage in neonatal rats. *Brain Dev* 2000; **22**: 315-320 [DOI: 10.1016/S0387-7604(00)00123-6]
66 **Di Fiore JM**, Bloom JN, Orge F, Schutt A, Schluchter M, Cheruvu VK, Walsh M, Finer N, Martin RJ. A higher incidence of intermittent hypoxemic episodes is associated with severe retinopathy of prematurity. *J Pediatr* 2010; **157**: 69-73 [PMID: 20304417 DOI: 10.1016/j.jpeds.2010.01.046]
67 **Mathew OP**. Apnea of prematurity: pathogenesis and management strategies. *J Perinatol* 2011; **31**: 302-310 [PMID: 21127467 DOI: 10.1038/jp.2010.126]
68 **Di Fiore JM**, Martin RJ, Gauda EB. Apnea of prematurity--perfect storm. *Respir Physiol Neurobiol* 2013; **189**: 213-222 [PMID: 23727228 DOI: 10.1016/j.resp.2013.05.026]
69 **Robertson CM**, Watt MJ, Dinu IA. Outcomes for the extremely premature infant: what is new? And where are we going? *Pediatr Neurol* 2009; **40**: 189-196 [PMID: 19218032 DOI: 10.1016/j.pediatrneurol.2008.09.017]
70 **Hofstetter AO**, Legnevall L, Herlenius E, Katz-Salamon M. Cardiorespiratory development in extremely preterm infants: vulnerability to infection and persistence of events beyond term-equivalent age. *Acta Paediatr* 2008; **97**: 285-292 [PMID: 18298775 DOI: 10.1111/j.1651-2227.2007.00618.x]
71 **Martin RJ**, Abu-Shaweesh JM, Baird TM. Apnoea of prematurity. *Paediatr Respir Rev* 2004; **5** Suppl A: S377-S382 [PMID: 14980300]
72 **Eichenwald EC**, Zupancic JA, Mao WY, Richardson DK, McCormick MC, Escobar GJ. Variation in diagnosis of apnea in moderately preterm infants predicts length of stay. *Pediatrics* 2011; **127**: e53-e58 [PMID: 21187315 DOI: 10.1542/peds.2010-0495]
73 **Henderson-Smart DJ**. The effect of gestational age on the incidence and duration of recurrent apnoea in newborn babies. *Aust Paediatr J* 1981; **17**: 273-276 [PMID: 7347216]
74 **Eichenwald EC**, Aina A, Stark AR. Apnea frequently persists beyond term gestation in infants delivered at 24 to 28 weeks. *Pediatrics* 1997; **100**: 354-359 [PMID: 9282705]
75 **Henderson-Smart DJ**, De Paoli AG. Methylxanthine treatment for apnoea in preterm infants. *Cochrane Database Syst Rev* 2010; **(12)**: CD000140 [PMID: 21154343 DOI: 10.1002/14651858.CD000140.pub2]
76 **Murat I**, Moriette G, Blin MC, Couchard M, Flouvat B, De Gamarra E, Relier JP, Dreyfus-Brisac C. The efficacy of caffeine in the treatment of recurrent idiopathic apnea in premature infants. *J Pediatr* 1981; **99**: 984-989 [PMID: 7310594]
77 **Erenberg A**, Leff RD, Haack DG, Mosdell KW, Hicks GM, Wynne BA. Caffeine citrate for the treatment of apnea of prematurity: a double-blind, placebo-controlled study. *Pharmacotherapy* 2000; **20**: 644-652 [PMID: 10853619]
78 **Davis PG**, Schmidt B, Roberts RS, Doyle LW, Asztalos E, Haslam R, Sinha S, Tin W. Caffeine for Apnea of Prematurity trial: benefits may vary in subgroups. *J Pediatr* 2010; **156**: 382-387 [PMID: 19926098 DOI: 10.1016/j.jpeds.2009.09.069]
79 **Julien CA**, Joseph V, Bairam A. Caffeine reduces apnea frequency and enhances ventilatory long-term facilitation in rat pups raised in chronic intermittent hypoxia. *Pediatr Res* 2010; **68**: 105-111 [PMID: 20453714 DOI: 10.1203/00006450-201011001-00202]
80 **Kumral A**, Tuzun F, Yesilirmak DC, Duman N, Ozkan H. Genetic basis of apnoea of prematurity and caffeine treatment response: role of adenosine receptor polymorphisms: genetic basis of apnoea of prematurity. *Acta Paediatr* 2012; **101**: e299-e303 [PMID: 22462821 DOI: 10.1111/j.1651-2227.2012.02664.x]
81 **Kassim Z**, Greenough A, Rafferty GF. Effect of caffeine on respiratory muscle strength and lung function in prematurely born, ventilated infants. *Eur J Pediatr* 2009; **168**: 1491-1495 [PMID: 19271237 DOI: 10.1007/s00431-009-0961-9]
82 **Rieg T**, Steigele H, Schnermann J, Richter K, Osswald H, Vallon V. Requirement of intact adenosine A1 receptors for the diuretic and natriuretic action of the methylxanthines theophylline and caffeine. *J Pharmacol Exp Ther* 2005; **313**: 403-409 [PMID: 15590766]
83 **Frumiento C**, Abajian JC, Vane DW. Spinal anesthesia for preterm infants undergoing inguinal hernia repair. *Arch Surg* 2000; **135**: 445-451 [PMID: 10768710]
84 **Murphy JJ**, Swanson T, Ansermino M, Milner R. The frequency of apneas in premature infants after inguinal hernia repair: do they need overnight monitoring in the intensive care unit? *J Pediatr Surg* 2008; **43**: 865-868 [PMID: 18485955 DOI: 10.1016/j.jpedsurg]
85 **Coté CJ**, Zaslavsky A, Downes JJ, Kurth CD, Welborn LG, Warner LO, Malviya SV. Postoperative apnea in former preterm infants after inguinal herniorrhaphy. A combined analysis. *Anesthesiology* 1995; **82**: 809-822 [PMID: 7717551]
86 **Warner LO**, Teitelbaum DH, Caniano DA, Vanik PE, Martino JD, Servick JD. Inguinal herniorrhaphy in young infants: perianesthetic complications and associated preanesthetic risk factors. *J Clin Anesth* 1992; **4**: 455-461 [PMID: 1457112]

87 **Henderson-Smart DJ**, Steer P. Prophylactic caffeine to prevent postoperative apnea following general anesthesia in preterm infants. *Cochrane Database Syst Rev* 2001; **(4)**: CD000048 [PMID: 11687065]

88 **Ricart S**, Rovira N, Garcia-Garcia JJ, Pumarola T, Pons M, Muñoz-Almagro C, Marcos MA. Frequency of apnea and respiratory viruses in infants with bronchiolitis. *Pediatr Infect Dis J* 2014; **33**: 988-990 [PMID: 24797994 DOI: 10.1097/INF.0000000000000365]

89 **Johnston DM**, Kuzemko JA. Virus-induced apnoea and theophylline. *Lancet* 1992; **340**: 1352 [PMID: 1360064]

90 **DeBuse P**, Cartwright D. Respiratory syncytial virus with apnoea treated with theophylline. *Med J Aust* 1979; **2**: 307-308 [PMID: 522760]

91 **Tobias JD**. Caffeine in the treatment of apnea associated with respiratory syncytial virus infection in neonates and infants. *South Med J* 2000; **93**: 294-296 [PMID: 10728517]

92 **Cesar K**, Iolster T, White D, Latifi S. Caffeine as treatment for bronchiolitis-related apnoea. *J Paediatr Child Health* 2012; **48**: 619 [PMID: 22758900 DOI: 10.1111/j.1440-1754.2012.02497.x]

93 **Walsh MC**, Morris BH, Wrage LA, Vohr BR, Poole WK, Tyson JE, Wright LL, Ehrenkranz RA, Stoll BJ, Fanaroff AA. Extremely low birthweight neonates with protracted ventilation: mortality and 18-month neurodevelopmental outcomes. *J Pediatr* 2005; **146**: 798-804 [PMID: 15973322]

94 **Groothuis JR**, Gutierrez KM, Lauer BA. Respiratory syncytial virus infection in children with bronchopulmonary dysplasia. *Pediatrics* 1988; **82**: 199-203 [PMID: 3399292]

95 **Cristea AI**, Carroll AE, Davis SD, Swigonski NL, Ackerman VL. Outcomes of children with severe bronchopulmonary dysplasia who were ventilator dependent at home. *Pediatrics* 2013; **132**: e727-e734 [PMID: 23918888 DOI: 10.1542/peds.2012-2990]

96 **Ehrenkranz RA**, Walsh MC, Vohr BR, Jobe AH, Wright LL, Fanaroff AA, Wrage LA, Poole K. Validation of the National Institutes of Health consensus definition of bronchopulmonary dysplasia. *Pediatrics* 2005; **116**: 1353-1360 [PMID: 16322158]

97 **Hughes CA**, O'Gorman LA, Shyr Y, Schork MA, Bozynski ME, McCormick MC. Cognitive performance at school age of very low birth weight infants with bronchopulmonary dysplasia. *J Dev Behav Pediatr* 1999; **20**: 1-8 [PMID: 10071939]

98 **Taha D**, Kirkby S, Nawab U, Dysart KC, Genen L, Greenspan JS, Aghai ZH. Early caffeine therapy for prevention of bronchopulmonary dysplasia in preterm infants. *J Matern Fetal Neonatal Med* 2014; **27**: 1698-1702 [PMID: 24479608 DOI: 10.3109/14767058.2014.885941]

99 **Weichelt U**, Cay R, Schmitz T, Strauss E, Sifringer M, Bührer C, Endesfelder S. Prevention of hyperoxia-mediated pulmonary inflammation in neonatal rats by caffeine. *Eur Respir J* 2013; **41**: 966-973 [PMID: 22878872 DOI: 10.1183/09031936.00012412]

100 **Ritter M**, Hohenberger K, Alter P, Herzum M, Tebbe J, Maisch M. Caffeine inhibits cytokine expression in lymphocytes. *Cytokine* 2005; **30**: 177-181 [PMID: 15863391]

101 **Chavez-Valdez R**, Wills-Karp M, Ahlawat R, Cristofalo EA, Nathan A, Gauda EB. Caffeine modulates TNF-alpha production by cord blood monocytes: the role of adenosine receptors. *Pediatr Res* 2009; **65**: 203-208 [PMID: 19047957 DOI: 10.1203/PDR.0b013e31818d66b1]

102 **Horrigan LA**, Kelly JP, Connor TJ. Immunomodulatory effects of caffeine: friend or foe? *Pharmacol Ther* 2006; **111**: 877-892 [PMID: 16540173]

103 **Chavez Valdez R**, Ahlawat R, Wills-Karp M, Nathan A, Ezell T, Gauda EB. Correlation between serum caffeine levels and changes in cytokine profile in a cohort of preterm infants. *J Pediatr* 2011; **158**: 57-64, 64.e1 [PMID: 20691455 DOI: 10.1016/j.jpeds.2010.06.051]

104 **Hunt CE**, Corwin MJ, Weese-Mayer DE, Ward SL, Ramanathan R, Lister G, Tinsley LR, Heeren T, Rybin D. Longitudinal assessment of hemoglobin oxygen saturation in preterm and term infants in the first six months of life. *J Pediatr* 2011; **159**: 377-383.e1 [PMID: 21481418 DOI: 10.1016/j.jpeds.2011.02.011]

105 **Hunt CE**, Corwin MJ, Baird T, Tinsley LR, Palmer P, Ramanathan R, Crowell DH, Schafer S, Martin RJ, Hufford D, Peucker M, Weese-Mayer DE, Silvestri JM, Neuman MR, Cantey-Kiser J. Cardiorespiratory events detected by home memory monitoring and one-year neurodevelopmental outcome. *J Pediatr* 2004; **145**: 465-471 [PMID: 15480368]

106 **Pillekamp F**, Hermann C, Keller T, von Gontard A, Kribs A, Roth B. Factors influencing apnea and bradycardia of prematurity - implications for neurodevelopment. *Neonatology* 2007; **91**: 155-161 [PMID: 17377399]

107 **Soloveychik V**, Bin-Nun A, Ionchev A, Sriram S, Meadow W. Acute hemodynamic effects of caffeine administration in premature infants. *J Perinatol* 2009; **29**: 205-208 [PMID: 19052555 DOI: 10.1038/jp.2008.193]

108 **Gillot I**, Gouyon JB, Guignard JP. Renal effects of caffeine in preterm infants. *Biol Neonate* 1990; **58**: 133-136 [PMID: 2279048]

109 **Manku MS**, Horrobin DF. Chloroquine, quinine, procaine, quinidine, tricyclic antidepressants, and methylxanthines as prostaglandin agonists and antagonists. *Lancet* 1976; **2**: 1115-1117 [PMID: 62951]

110 **Turner CP**, Yan H, Schwartz M, Othman T, Rivkees SA. A1 adenosine receptor activation induces ventriculomegaly and white matter loss. *Neuroreport* 2002; **13**: 1199-1204 [PMID: 12151769]

111 **Turner CP**, Seli M, Ment L, Stewart W, Yan H, Johansson B, Fredholm BB, Blackburn M, Rivkees SA. A1 adenosine receptors mediate hypoxia-induced ventriculomegaly. *Proc Natl Acad Sci USA* 2003; **100**: 11718-11722 [PMID: 12975523]

112 **Rivkees SA**, Wendler CC. Adverse and protective influences of adenosine on the newborn and embryo: implications for preterm white matter injury and embryo protection. *Pediatr Res* 2011; **69**: 271-278 [PMID: 21228731 DOI: 10.1203/PDR.0b013e31820efbcf]

113 **Back SA**, Craig A, Luo NL, Ren J, Akundi RS, Ribeiro I, Rivkees SA. Protective effects of caffeine on chronic hypoxia-induced perinatal white matter injury. *Ann Neurol* 2006; **60**: 696-705 [PMID: 17044013]

114 **Connolly S**, Kingsbury TJ. Caffeine modulates CREB-dependent gene expression in developing cortical neurons. *Biochem Biophys Res Commun* 2010; **397**: 152-156 [PMID: 20493822 DOI: 10.1016/j.bbrc.2010.05.054]

115 **Yoshimura H**. The potential of caffeine for functional modification from cortical synapses to neuron networks in the brain. *Curr Neuropharmacol* 2005; **3**: 309-316 [PMID: 18369398]

116 **Silva CG**, Métin C, Fazeli W, Machado NJ, Darmopil S, Launay PS, Ghestem A, Nesa MP, Bassot E, Szabó E, Baqi Y, Müller CE, Tomé AR, Ivanov A, Isbrandt D, Zilberter Y, Cunha RA, Esclapez M, Bernard C. Adenosine receptor antagonists including caffeine alter fetal brain development in mice. *Sci Transl Med* 2013; **5**: 197ra104 [PMID: 23926202 DOI: 10.1126/scitranslmed.3006258]

117 **Desfrere L**, Olivier P, Schwendimann L, Verney C, Gressens P. Transient inhibition of astrocytogenesis in developing mouse brain following postnatal caffeine exposure. *Pediatr Res* 2007; **62**: 604-609 [PMID: 18049373]

118 **Supcun S**, Kutz P, Pielemeier W, Roll C. Caffeine increases cerebral cortical activity in preterm infants. *J Pediatr* 2010; **156**: 490-491 [PMID: 20176190]

119 **Hassanein SM**, Gad GI, Ismail RI, Diab M. Effect of caffeine on preterm infants' cerebral cortical activity: an observational study. *J Matern Fetal Neonatal Med* 2015; **28**: 2090-2095 [PMID: 25330842]

120 **Maitre NL**, Chan J, Stark AR, Lambert WE, Aschner JL, Key AP. Effects of caffeine treatment for apnea of prematurity on cortical speech-sound differentiation in preterm infants. *J Child Neurol* 2015; **30**: 307-313 [PMID: 24939976 DOI: 10.1177/0883073814538500]

121 **Hayes MJ**, Akilesh MR, Fukumizu M, Gilles AA, Sallinen BA, Troese M, Paul JA. Apneic preterms and methylxanthines: arousal deficits, sleep fragmentation and suppressed spontaneous movements. *J Perinatol* 2007; **27**: 782-789 [PMID: 17805341]

122 **Curzi-Dascalova L**, Aujard Y, Gaultier C, Rajguru M. Sleep organization is unaffected by caffeine in premature infants. *J Pediatr* 2002; **140**: 766-771 [PMID: 12072884]

123 **Marcus CL**, Meltzer LJ, Roberts RS, Traylor J, Dix J, D'ilario

J, Asztalos E, Opie G, Doyle LW, Biggs SN, Nixon GM, Narang I, Bhattacharjee R, Davey M, Horne RS, Cheshire M, Gibbons J, Costantini L, Bradford R, Schmidt B. Long-term effects of caffeine therapy for apnea of prematurity on sleep at school age. *Am J Respir Crit Care Med* 2014; **190**: 791-799 [PMID: 25171195 DOI: 10.1164/rccm.201406-1092OC]

124 **Doyle LW**, Cheong J, Hunt RW, Lee KJ, Thompson DK, Davis PG, Rees S, Anderson PJ, Inder TE. Caffeine and brain development in very preterm infants. *Ann Neurol* 2010; **68**: 734-742 [PMID: 21031585 DOI: 10.1002/ana.22098]

125 **Gray PH**, Flenady VJ, Charles BG, Steer PA. Caffeine citrate for very preterm infants: Effects on development, temperament and behaviour. *J Paediatr Child Health* 2011; **47**: 167-172 [PMID: 21244548 DOI: 10.1111/j.1440-1754.2010.01943.x]

126 **Lunt MJ**, Ragab S, Birch AA, Schley D, Jenkinson DF. Comparison of caffeine-induced changes in cerebral blood flow and middle cerebral artery blood velocity shows that caffeine reduces middle cerebral artery diameter. *Physiol Meas* 2004; **25**: 467-474 [PMID: 15132312]

127 **Hoecker C**, Nelle M, Poeschl J, Beedgen B, Linderkamp O. Caffeine impairs cerebral and intestinal blood flow velocity in preterm infants. *Pediatrics* 2002; **109**: 784-787 [PMID: 11986437]

128 **Hoecker C**, Nelle M, Beedgen B, Rengelshausen J, Linderkamp O. Effects of a divided high loading dose of caffeine on circulatory variables in preterm infants. *Arch Dis Child Fetal Neonatal Ed* 2006; **91**: F61-F64 [PMID: 16204358]

129 **Tracy MB**, Klimek J, Hinder M, Ponnampalam G, Tracy SK. Does caffeine impair cerebral oxygenation and blood flow velocity in preterm infants? *Acta Paediatr* 2010; **99**: 1319-1323 [PMID: 20412101 DOI: 10.1111/j.1651-2227.2010.01828.x]

130 **Dani C**, Bertini G, Reali MF, Tronchin M, Wiechmann L, Martelli E, Rubaltelli FF. Brain hemodynamic changes in preterm infants after maintenance dose caffeine and aminophylline treatment. *Biol Neonate* 2000; **78**: 27-32 [PMID: 10878419]

131 **Bauer J**, Maier K, Linderkamp O, Hentschel R. Effect of caffeine on oxygen consumption and metabolic rate in very low birth weight infants with idiopathic apnea. *Pediatrics* 2001; **107**: 660-663 [PMID: 11335740]

132 **Zanardo V**, Dani C, Trevisanuto D, Meneghetti S, Guglielmi A, Zacchello G, Cantarutti F. Methylxanthines increase renal calcium excretion in preterm infants. *Biol Neonate* 1995; **68**: 169-174 [PMID: 8534781]

133 **Barrington KJ**, Tan K, Rich W. Apnea at discharge and gastro-esophageal reflux in the preterm infant. *J Perinatol* 2002; **22**: 8-11 [PMID: 11840235]

134 **Di Fiore JM**, Arko M, Whitehouse M, Kimball A, Martin RJ. Apnea is not prolonged by acid gastroesophageal reflux in preterm infants. *Pediatrics* 2005; **116**: 1059-1063 [PMID: 16263989]

135 **Gounaris A**, Kokori P, Varchalama L, Konstandinidi K, Skouroliakou M, Alexiou N, Costalos C. Theophylline and gastric emptying in very low birthweight neonates: a randomised controlled trial. *Arch Dis Child Fetal Neonatal Ed* 2004; **89**: F297-F299 [PMID: 15210659]

136 **Skopnik H**, Koch G, Heimann G. [Effect of methylxanthines on periodic respiration and acid gastroesophageal reflux in newborn infants]. *Monatsschr Kinderheilkd* 1990; **138**: 123-127 [PMID: 2352535]

137 **Feurle G**, Arnold R, Helmstädter V, Creutzfeldt W. The effect of intravenous theophylline ethylenediamine on serum gastrin concentration in control subjects and patients with duodenal ulcers and Zollinger-Ellison syndrome. *Digestion* 1976; **14**: 227-231 [PMID: 955329]

138 **Mezzacappa MA**, Rosa AC. Clinical predictors of abnormal esophageal pH monitoring in preterm infants. *Arq Gastroenterol* 2008; **45**: 234-238 [PMID: 18852953]

139 **Lane AJ**, Coombs RC, Evans DH, Levin RJ. Effect of caffeine on neonatal splanchnic blood flow. *Arch Dis Child Fetal Neonatal Ed* 1999; **80**: F128-F129 [PMID: 10325790]

140 **Tunc T**, Aydemir G, Karaoglu A, Cekmez F, Kul M, Aydinoz S, Babacan O, Yaman H, Sarici SU. Toll-like receptor levels and caffeine responsiveness in rat pups during perinatal period. *Regul Pept* 2013; **182**: 41-44 [PMID: 23313844 DOI: 10.1016/j.regpep.2012.12.016]

141 **Ergenekon E**, Dalgiç N, Aksoy E, Koç E, Atalay Y. Caffeine intoxication in a premature neonate. *Paediatr Anaesth* 2001; **11**: 737-739 [PMID: 11696154]

142 **Anderson BJ**, Gunn TR, Holford NH, Johnson R. Caffeine overdose in a premature infant: clinical course and pharmacokinetics. *Anaesth Intensive Care* 1999; **27**: 307-311 [PMID: 10389569]

143 **Natarajan G**, Botica ML, Thomas R, Aranda JV. Therapeutic drug monitoring for caffeine in preterm neonates: an unnecessary exercise? *Pediatrics* 2007; **119**: 936-940 [PMID: 17473094]

144 **Skouroliakou M**, Bacopoulou F, Markantonis SL. Caffeine versus theophylline for apnea of prematurity: a randomised controlled trial. *J Paediatr Child Health* 2009; **45**: 587-592 [PMID: 19751376 DOI: 10.1111/j.1440-1754.2009.01570.x]

P- Reviewer: Richard W
S- Editor: Qiu S **L- Editor**: A **E- Editor**: Jiao XK

World Journal of Clinical Pediatrics

Submit a Manuscript: http://www.wjgnet.com/esps/
Help Desk: http://www.wjgnet.com/esps/helpdesk.aspx
DOI: 10.5409/wjcp.v4.i4.94

World J Clin Pediatr 2015 November 8; 4(4): 94-105
ISSN 2219-2808 (online)
© 2015 Baishideng Publishing Group Inc. All rights reserved.

REVIEW

Current management of pediatric soft tissue sarcomas

Surasak Sangkhathat

Surasak Sangkhathat, Department of Surgery and Tumor Biology Research Unit, Faculty of Medicine, Prince of Songkla University, Songkhla 90110, Thailand

Author contributions: Sangkhathat S reviewed and composed the manuscript.

Supported by The Anandamahidol Foundation.

Conflict-of-interest statement: None declared.

Open-Access: This article is an open-access article which was selected by an in-house editor and fully peer-reviewed by external reviewers. It is distributed in accordance with the Creative Commons Attribution Non Commercial (CC BY-NC 4.0) license, which permits others to distribute, remix, adapt, build upon this work non-commercially, and license their derivative works on different terms, provided the original work is properly cited and the use is non-commercial. See: http://creativecommons.org/licenses/by-nc/4.0/

Correspondence to: Surasak Sangkhathat, MD, PhD, Department of Surgery and Tumor Biology Research Unit, Faculty of Medicine, Prince of Songkla University, Hat Yai, Songkhla 90110, Thailand. surasak.sa@psu.ac.th
Telephone: +66-74-451401
Fax: +66-74-429384

Received: May 29, 2015
Peer-review started: June 2, 2015
First decision: July 3, 2015
Revised: July 21, 2015
Accepted: September 29, 2015
Article in press: September 30, 2015
Published online: November 8, 2015

Abstract

Pediatric soft tissue sarcomas are a group of malignant neoplasms arising within embryonic mesenchymal tissues during the process of differentiation into muscle, fascia and fat. The tumors have a biphasic peak for age of incidence. Rhabdomyosarcoma (RMS) is diagnosed more frequently in younger children, whereas adult-type non-RMS soft tissue sarcoma is predominately observed in adolescents. The latter group comprises a variety of rare tumors for which diagnosis can be difficult and typically requires special studies, including immunohistochemistry and molecular genetic analysis. Current management for the majority of pediatric sarcomas is based on the data from large multi-institutional trials, which has led to great improvements in outcomes over recent decades. Although surgery remains the mainstay of treatment, the curative aim cannot be achieved without adjuvant treatment. Pre-treatment staging and risk classification are of prime importance in selecting an effective treatment protocol. Tumor resectability, the response to induction chemotherapy, and radiation generally determine the risk-group, and these factors are functions of tumor site, size and biology. Surgery provides the best choice of local control of small resectable tumors in a favorable site. Radiation therapy is added when surgery leaves residual disease or there is evidence of regional spread. Chemotherapy aims to reduce the risk of relapse and improve overall survival. In addition, upfront chemotherapy reduces the aggressiveness of the required surgery and helps preserve organ function in a number of cases. Long-term survival in low-risk sarcomas is feasible, and the intensity of treatment can be reduced. In high-risk sarcoma, current research is allowing more effective disease control.

Key words: Pediatric tumor; Rhabdomyosarcoma; Soft tissue sarcoma; Non-rhabdomyosarcoma pediatric soft tissue tumor

© The Author(s) 2015. Published by Baishideng Publishing Group Inc. All rights reserved.

Core tip: The manuscript describes current management of pediatric soft tissue sarcomas, a large group of rare tumors in pediatric age group. The group has two main categories; rhabdomyosarcoma (RMS) and non-RMS pediatric soft tissue tumors. Treatment of these tumors is in multidisciplinary fashion comprising of surgery, chemotherapy and radiation therapy. Decision making in management protocol for each patient is based on

the risk determined by various clinical and pathological parameters. For cases with low-risk, surgical removal is usually adequate when adjuvant chemoradiation are proven helpful in cases with significant risk of recurrence. The overall survival in these tumors has become brighter in the recent decades.

Sangkhathat S. Current management of pediatric soft tissue sarcomas. *World J Clin Pediatr* 2015; 4(4): 94-105 Available from: URL: http://www.wjgnet.com/2219-2808/full/v4/i4/94.htm DOI: http://dx.doi.org/10.5409/wjcp.v4.i4.94

INTRODUCTION

Pediatric soft tissue sarcomas are part of a heterogeneous group of tumors originating from embryonic mesodermal tissues during the process of differentiation into various mesenchymal tissue components of the human body. These tumors constitute 6% to 8% of all cancers in children less than 15 years of age[1-5]. Age-standardized incidence rates in Western countries are slightly increased compared with Asian countries[5]. Of all soft tissue sarcomas in this age group, approximately 50% to 60% are rhabdomyosarcoma (RMS), whereas the remainder are non-RMS soft tissue sarcomas (NRSTS), a designation that includes a variety of rarer soft tissue tumors including fibrosarcomas, synovial sarcomas, the extraosseous Ewing's family of tumors, malignant peripheral nerve sheath tumors (MPNSTs) and inflammatory myofibroblastic tumors (IMT)[6,7]. According to the International Classification of Childhood Cancers, version 3, Kaposi sarcoma is also categorized as a NRSTS tumors[8]. Approximately two-thirds of RMSs are diagnosed before 6 years of age, and the incidence decreases with age[7,9]. In contrast, NRSTSs occur in older children, increasing in incidence throughout adolescent years[6]. In African countries wherein the human immunodeficiency virus is endemic, an exceptionally increased incidence of Kaposi sarcoma has been reported[2].

Although most soft tissue sarcomas occur sporadically, these lesions are associated with cancer predisposition syndrome in some patients, (*e.g.,* Li-Fraumeni syndrome, which is linked to p53 germline mutations). Neurofibrosarcomas typically develop in individuals affected with neurofibromatosis type 1, an autosomal dominant disorder caused by mutations in the neurofibromatosis 1 gene (*NF1*). Individuals harboring germline mutations of NF1 are also prone to the development of embryonal RMS[10]. At the somatic level, specific chromosomal translocations and an expression of chimeric transcription factors are molecular signatures in a number of pediatric sarcomas. In RMS, PAX-FOXO1 fusion is a characteristic of the unfavorable histology or alveolar RMS. Such specific molecular patterns help differentiate sarcoma subtypes in which accurate pathological diagnosis may be difficult at a histopathological level.

The outcomes of pediatric soft tissue sarcomas have improved significantly during the past 3 decades[11]. The prognosis of pediatric soft tissue sarcoma, particularly RMS in younger children, is far better than that for sarcomas in adults. With modern evidence-based medicine, a multidisciplinary therapeutic approach not only increases survival rates but also provides a better chance to preserve the affected organ, particularly in the extremities and genitourinary organs. This article reviews current management practices for pediatric soft tissue sarcomas, with an emphasis on RMS and some soft tissue tumors that are more commonly found in the pediatric age group.

CLINICAL PRESENTATION AND DIAGNOSIS OF PEDIATRIC SOFT TISSUE SARCOMA

As soft tissue sarcomas are derived from primitive mesenchymal cells during their development into various mature mesenchymal tissue types (including muscle, fascia and fat), these tumors can be located in any part of the human body. The most common sites of primary RMSs are the head and neck, the genitourinary system and the limbs. The classic presentation is a growing lump that may or may not affect the function of nearby organs. RMS in some organ systems may cause specific symptoms. For example, frequent urination can be an initial presentation of an RMS that arises within the urinary bladder. Obstructive jaundice is one manifestation of bile duct RMS. Multiple plexiform neurofibrosarcomas can be benign tumors that follow neurofibrosarcoma in an individual with neurofibromatosis. Localization of the tumor site and its relation to the surrounding organs is typically accomplished by an imaging study, preferably magnetic resonance imaging (MRI) and/or computerized tomography (CT)[12]. From a surgical standpoint, the location, proximity to vascular structures, and potential morbidity caused by surgical resection determine the "resectability" of a sarcoma. To date, no serum markers are available for the diagnosis of soft tissue sarcomas. Image-guided core needle biopsy typically, but not always, provides a definitive diagnosis[13]. During a biopsy, extra tissue can be collected for further studies, *i.e.,* electron microscopy and molecular diagnosis. Repeat biopsy using an open technique is performed when a histopathological diagnosis cannot be made upon examining a small strip of tissue obtained from a needle coring-out. Suspected lymph node metastasis should be confirmed by histopathology, particularly in sarcoma of the limbs and the paratesticular area.

Pre-treatment clinical staging aims to categorize the disease according to the tumor site, size, local invasion, regional lymph node involvement and distant metastasis. The metastatic work-up includes bone marrow aspiration/biopsy, bone scintigraphy, and axial imaging studies of the brain, lung and liver (CT or MRI).

Table 1 Intergroup rhabdomyosarcoma study pretreatment staging and clinical grouping classification

Stage	Sites	T[1]	Size[2]	N[3]	M[4]
1	Orbit, head and neck (excluding parameningeal), genitourinary tract (non-bladder, non-prostate), biliary tract	T1 or T2	a or b	N0 or N1 or Nx	M0
2	Bladder.Prostate, extremity, parameningeal, others (trunk, retroperitoneum, *etc.*)	T1 or T2	a	N0 or Nx	M0
3	Bladder.Prostate, extremity, parameningeal, others (trunk, retroperitoneum, *etc.*)	T1 or T2	a	N1	M0
			b	N0 or N1 or Nx	M0
4	Any sites	T1 or T2	a or b	N0 or N1	M1
Clinical group	Description				
Ⅰ	Localized disease, completely resected				
Ⅱ	Grossly resected tumor with evidence of regional spread				
	ⅡA: Grossly resected tumor with microscopic residual disease				
	ⅡB: Involved regional nodes completely resected with no microscopic residual disease				
	ⅡC: Involved regional nodes grossly resected with evidence of microscopic residual disease				
Ⅲ	Incomplete resection with gross residual disease after biopsy or after gross or major resection of the primary tumor				
Ⅳ	Distant metastatic disease present at diagnosis				

[1]T: Tumor; T1: Confined to the anatomic origin; T2: Extension and/or fixation to surrounding tissue; [2]Size, a: ≤ 5 cm; b: > 5 cm; [3]N: Regional nodes; N0: Regional nodes not clinically involved; Nx: Clinical status of regional nodes unknown; N1: Regional nodes clinically involved; [4]M: Metastasis; M0: No distant metastasis; M1: Distant metastasis present (includes positive cytology in pleural, peritoneal or cerebrospinal fluid).

Table 2 Risk group stratification for rhabdomyosarcoma according to the International Rhabdomyosarcoma Study

Risk group	Histology	Pretreatment stage	Clinical group
Low (subset 1)	Embryonal	1	Ⅰ, Ⅱ
		1	Ⅲ (orbit)
		2	Ⅰ, Ⅱ
Low (subset 2)		1	Ⅲ (non-orbit)
		3	Ⅰ, Ⅱ
Intermediate	Embryonal	2, 3	Ⅲ
	Alveolar	1, 2, 3	Ⅰ, Ⅱ, Ⅲ
High	Any	4	Ⅳ

A spinal tap for cerebrospinal fluid is indicated in cases of suspected parameningeal tumor. A recent systematic review suggested the potential benefit of a functional imaging study, such as positron emission tomography (PET-CT), for increasing the accuracy of pretreatment staging, particularly in the evaluation of nodal status and distant metastasis[14,15]. Sentinel lymph node biopsy using radio-tracer exhibits feasibility and good concordance with PET-CT results in pediatric soft tissue sarcomas[16,17].

MULTIDISCIPLINARY MANAGEMENT OF PEDIATRIC SOFT TISSUE SARCOMA

RMS

RMS is a malignant mesenchymal tumor originating from immature striated muscle. Approximately 40% of RMSs occur in the head and neck region, 20% occur at genitourinary sites, 20% in the extremities, and 20% in other locations[9,12] (Figure 1). On hematoxylin and eosin histology, the tumor is characterized by the presence of spindle-shaped or small round-cell rhabdomyofibroblasts with eosinophilic cytoplasm. Cross-striations can be observed in some cases with relatively high tumor differentiation. Immunohistochemical studies that support the diagnosis of RMS include actin, desmin, myoglobin, myogenin and Myo-D. Pediatric RMS cases are generally categorized into 2 types: embryonal RMS (80%) and alveolar RMS (15%-20%)[12]. The botryoid subtype is a variant of embryonal RMS commonly located in the genitourinary tract, vagina, and biliary and nasopharyngeal sites. The spindle cell subtype is another subtype of embryonal RMS found in paratesticular locations. Alveolar RMS is observed in older children and generally has a more unfavorable histology.

After the diagnosis is made, pre-treatment staging is performed according to a standard classification, such as the InterGroup Rhabdomyosarcoma Pretreatment Staging Classification (Table 1). The value of pretreatment staging involves determining disease prognosis. In addition to the stage, completeness of tumor removal defines the "clinical group" of RMS. Management plans for RMS can be divided into local control and systemic therapy and generally rely on risk categorization as determined by the Intergroup Rhabdomyosarcoma Studies (IRS) stage with the clinical group (Table 2). Surgery therefore has an integral role in the initial stages of decision-making on multimodality treatment in pediatric RMS.

Local control

Surgery has been the most effective method to eliminate pathology. Surgery should be conducted in a manner that maintains function and cosmesis. In primary surgery, the extent of the initial surgery is generally subject to the judgment of the surgical team. In principle, resectability means that a tumor and its tumor-free surrounding tissue can be removed without operative risk or unacceptable post-operative morbidity. In the cases in which an excisional biopsy is performed without awareness of an adequate surgical margin, re-excision of the tumor bed should be considered[18,19].

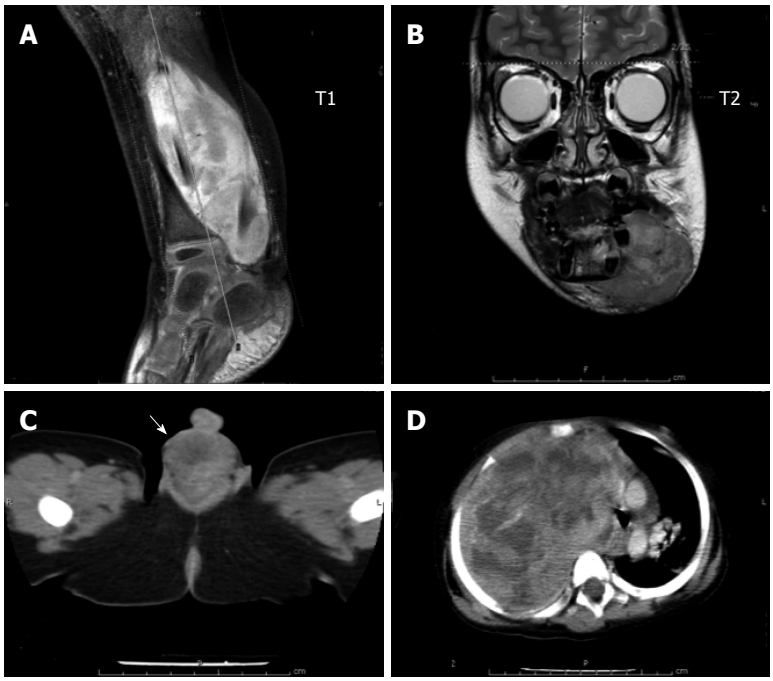

Figure 1 Radiographic images of common rhabdomyosarcoma. A: Extremity; B: Head and neck; C: Genitourinary (paratesticular); D: Axial (intraabdominal).

In general, factors determining resectability include anatomical characters, such as site, size and vital structure involvement. However, in cases in which primary definitive surgery is not likely to provide complete resection without significant morbidity, delayed primary resection after upfront chemotherapy should be considered with an aim for organ salvage without compromising the long-term survival outcome. When delayed primary resection after neoadjuvant treatment is planned, compliance should also be considered. Intractable symptoms from the tumor and psychosocial factors may impact therapeutic compliance. Symptom control surgery during induction therapy (*i.e.,* temporary urinary diversion in urinary bladder RMS) might be indicated[20]. Radical surgery is indicated in patients who are unable to tolerate intensive chemoradiation.

A recent multi-institutional data review demonstrated that approximately 90% of clinical group Ⅲ embryonal RMS patients experienced a volume reduction of 33% or greater after induction chemotherapy[21]. Although the effect of the chemotherapeutic response on event-free survival (EFS) remains unclear, the study found that cases with at least a partial response experienced significantly enhanced overall survival (OS), particularly in head and neck RMS[21]. These results were consistent with a recent report using functional imaging tool 2-fluoro-2-deoxy-d-glucose-positron emission topography from the Memorial Sloan Kettering Cancer Center suggesting that the response after induction chemotherapy significantly predicted both EFS and OS[22]. An earlier report from the Intergroup Rhabdomyosarcoma Study Ⅳ (IRS-Ⅳ) revealed an 81% response to chemotherapy in group Ⅲ RMS cases with no significant difference in the response rate between embryonal and alveolar RMS, and the size of the initial tumor had no influence on the response[23]. According to both studies, parameningeal RMS appeared to have a poorer response rate even when chemotherapy was administered with radiation[24]. Although the number of cases was lower, genitourinary tract sites (except bladder and prostate) exhibited better response rates[21]. The delayed primary resection strategy has reduced the extent of surgery in pelvic RMS. Pelvic exenteration, a historical standard in bladder and vaginal RMS, is rarely practiced today.

Second-look exploration aims to confirm the clinical/radiological response and to achieve oncologic resection when possible. Imaging evaluation may underestimate the degree of the response. According to IRS-Ⅲ data, 46% of patients who achieved partial remission were found to be in complete remission at surgical exploration, and an additional 28% could be converted to complete remission. In addition, 30% of patients who had clinically stable disease after induction chemotherapy exhibited pathological complete remission, and an additional 43% could be converted to complete remission[23]. To achieve oncologic resection, radical organ removal must be performed in some situations. In urinary bladder RMS that arises at the base of the bladder or prostate, a partial cystectomy is not sufficient given the high risk of local failure. Total cystectomy and urologic conduit is a surgical option that potentially leads to long-term, disease-free survival with an acceptable quality of life. Bladder-preserving surgery is reserved for cases with a good response to induction chemoradiation therapy. In addition, the tumor location must allow a 2- to 3-cm tumor-free margin, and at least two-thirds of the bladder must be retained[20,25]. In vaginal RMS, residual tumor after chemotherapy is an indication

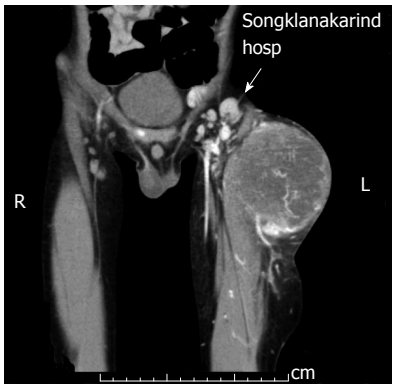

Figure 2 Inguinal lymph node enlargement in a case of extremity rhabdomyosarcoma.

for total hysterectomy with gonadal preservation[26]. Pancreaticoduodenectomy is the operation of choice in cases in which the RMS involves the distal common bile duct[27].

Lymph node management is of prime importance in pre-treatment staging and clinical grouping of RMS, both of which determine the risk category. Radical lymph node dissection does not impact outcome. Enlarged nodes detected clinically or by radiologic evidence should be excised for histopathological examination (Figure 2). Regardless of radiologic evidence, lymph node sampling is indicated in extremity RMS and for children older than 10 years with paratesticular tumor[9,11,28]. When an adjacent node is positive, more distant nodes should be searched for and biopsied. To reduce the morbidity caused by extensive lymph node sampling, the concept of sentinel lymph node sampling, which is the current standard in melanoma and breast cancer, has also been adapted for pediatric soft tissue sarcoma. Trials in pediatric sarcomas had relatively small numbers in each series[16,17,29]. Most studies used the lymphoscintigraphy technique and reported that the technique was feasible in pediatric sarcomas; however, specific data regarding identification rates and false negative rates in RMS remain inconclusive.

Radiation therapy is unnecessary for embryonal RMS in clinical group Ⅰ (completely resected) when it provides better failure-free survival in alveolar RMS. Radiation enhances local control in cases with residual disease after definitive surgery, positive locoregional lymph nodes and unresectable RMS after tumor biopsy. Radiation doses to microscopic residual tumors (total 36 Gy) are typically less than those for gross residual or primary unresectable tumors (50.4 Gy)[11]. Orbital tumors are an exception as their clinical group Ⅲ requires 45 Gy. Data from the German trial CWS91 indicated that hyperfractionated accelerated radiotherapy may reduce the total radiation dose in RMS (32 Gy in low-risk and 48 Gy in high-risk patients) without compromising treatment outcomes[30]. Alternative radiation therapy techniques, such as intensity modulated radiation therapy, brachytherapy, and proton beam therapy, are used in some centers with the aim of reducing locoregional side effects[31].

Systemic therapy

Chemotherapy is an essential component of the multimodality treatment of RMS. The standard regimen in non-metastatic RMS is a combination of vincristine, actinomycin-D and cyclophosphamide (VAC)[32]. Omitting cyclophosphamide from the regimen has been attempted in low-risk RMS cases to reduce the cumulative dose of cyclophosphamide (IRS-D9602 protocol). Although VA produced an excellent outcome in a subset of low-risk RMS cases, including group Ⅰ-Ⅱ, stage 1-2 and group Ⅲ orbital tumor (subset 1, Table 2), the data suggested that cyclophosphamide should be retained with vincristine and actinomycin-D in the other subset of low-risk RMS cases (subset 2: group Ⅰ-Ⅱ, stage 3 and group Ⅲ, stage Ⅰ except orbital tumor) because the failure-free survival was poorer than that of comparable patients in the IRS-Ⅳ study who received a triple drug regimen[33]. IRS-Ⅳ data also demonstrated that substitution of cyclophosphamide with ifosfamide (VAI) or substitution of actinomycin-D/cyclophosphamide with ifosfamide and etoposide did not improve the failure-free survival in non-metastatic RMS[34]. A subsequent study from the Children's Oncology Group (COG), directed toward a shorter duration of VA and dose reduction of cyclophosphamide (ARST0331) in low-risk RMS patients, was recently published. Although the study reported an increased incidence of local failure with use of the shorter therapy, the study recommended its use in low-risk RMS cases given the reduced toxicity[35]. For intermediate- and high-risk patients, successive COG trials have attempted to improve the survival outcome by incorporating novel agents, such as doxorubicin, ifosfamide and etoposide (VDC/IE), and irenotecan (VAC/VI), with the aim of reducing the cumulative cyclophosphamide dose[36]. Various molecular targeting drugs are being explored in high-risk RMS cases, including vascular endothelial growth factors (bevacizumab), mTOR (temsirolimus) and IGF-1R (temozolomide). A phase Ⅱ trial of temozolomide has demonstrated its safety and feasibility; however, the preliminary response rate was not impressive[37]. For metastatic RMS, another study found that the incorporation of VDC-IE or Ⅵ with VAC therapy resulted in improved outcomes in embryonal RMS[38].

Outcome of current multimodality management in RMS

Since the establishment of the International Rhabdomyosarcoma Study Group in 1972 (currently the Cooperative Soft Tissue Sarcoma Study Group), survival of pediatric RMS patients has been steadily improving. Before the era of multimodality treatment, surgery alone resulted in survival rates less than 20% (11). With the new available treatments, the five-year OS increased from 55% in IRS-Ⅰ to 63% in IRS-Ⅱ and to 71% in IRS-Ⅲ and IRS-Ⅳ. Data from IRS-Ⅱ to IRS-Ⅳ

Table 3 Risk stratification in nonrhabdomyosarcoma soft tissue sarcoma and treatment proposal according to the Children's Oncology Group (NCT00346164)

Risk group	Factors				Proposed treatment
	Grade	Size	Stage	Initial resectability	
Low	Low	Any	Nonmetastatic	Gross resection	Observation
	High	< 5 cm	Nonmetastatic	Without microscopic margins	Observation
	High	< 5 cm	Nonmetastatic	With microscopic margin	Adjuvant radiation therapy
Intermediate	High	> 5 cm	Nonmetastatic	Gross resection	Adjuvant chemotherapy and radiation therapy
	High	> 5 cm	Nonmetastatic	Unresected	Neoadjuvant chemoradiotherapy, surgery, adjuvant chemotherapy with or without radiation therapy
High	Low	Any	Metastatic	Gross resection	Observation
	High	Any	Metastatic	Gross resection	Adjuvant chemotherapy and radiation therapy
	High	Any	Metastatic	Unresected	Neoadjuvant chemoradiotherapy, surgery, adjuvant chemotherapy with or without radiation therapy

revealed an 88% 3-year failure-free survival in low risk embryonal RMS. Intermediate-risk embryonal RMS had a 4-year failure-free survival rate of approximately 68% to 78%; however, survival in high-risk patients remains poor at less than 25%[39].

NON-RMS SOFT TISSUE SARCOMAS

NRSTSs are a heterogeneous group of rare mesenchymal tumors that exhibit a wide variety of histopathologies and biologies. The majority of NRSTSs occur more frequently in adult patients, and the prognosis is generally poorer than for pediatric sarcomas. Given their heterogeneity, ambiguity in pathological diagnosis is common, and care should be taken when obtaining tissue samples[40]. A multidisciplinary conference before the initiation of treatment for any individual case allows the team to arrive at a consensus and understand the role of each discipline in the treatment process. Surgery has a primary role in the treatment of resectable NRSTSs, whereas adjuvant treatment relies on a Children's Oncology Group risk stratification guideline[41] (Table 3). Basically, radiation therapy is administered to patients whose resection margins are close to the tumor (except for very low-risk tumors). Chemotherapy provides a poorer response than pediatric RMS and is advocated in select types of NRSTS. Ifosfamide and doxorubicin are backbones recommended as post-operative adjuvant therapy for localized resectable STSs[42,43]. A recent systematic review found that autologous hematopoietic stem cell transplantation following high-dose chemotherapy in locally advanced or metastatic NRSTS did not result in better OS than standard-dose chemotherapy[44].

Extraosseous Ewing's sarcoma family of tumors

Extraosseous primitive neuroectodermal tumors, namely, Ewing's sarcoma and Adkin tumor of the chest wall, are grouped together as the Ewing's family of tumors because they share a chromosomal translocation, t(11;22)(q24;q12), leading to a chimeric fusion, EWSR1-FLI1[45]. Extraosseous Ewing's sarcoma presents predominately in the second decade of life. The tumor is comprises 15% to 20% of all Ewing's sarcomas[46,47]. The tumor can occur anywhere in the body but commonly presents on the extremities, chest and pelvis. Histologically, the tumor belongs to the small round blue cell group and demonstrates positive immunoreactivity to the surface glycoprotein CD99. Poor prognostic indicators include axial site tumors, particularly in the pelvic region; large tumor size; late stage; poor response to induction chemotherapy; advanced age; and high serum lactate dehydrogenase levels[46-49]. The definitive treatment for extraosseous EFSTs is surgical removal. Complete resection is the best option for cure, and the likelihood of achieving negative surgical margins is increased when induction chemotherapy is administered[50]. Although these tumors are relatively sensitive to radiation, radiation is reserved for cases with positive surgical margins or incompletely resected tumor because late effects of radiation, such as a second malignancy, are of concern. Post-operative chemotherapy aims to improve OS and reduce the likelihood of local recurrence. The therapeutic regimen in extraosseous EFST follows that used in either NRSTS or Ewing's sarcoma of the bone and typically comprises ifosfamide/etoposide with or without carboplatin (ICE) alternated with a combination of vincristine, doxorubicin and cyclophosphamide (VDC)[47]. The results from the EICESS-92 study and the successive trial Euro-Ewing-99-R1 from the European InterGroup Cooperative Ewing's Sarcoma Study concluded that ifosfamide can be substituted with cyclophosphamide in the consolidation phase in standard risk EFST (localized tumor with either good histological response after induction chemotherapy, small tumor resected at diagnosis, or receiving radiotherapy alone as a local treatment)[48,51]. A report from the French Society of Pediatric Oncology (SFOP-EW93) suggested that induction with cyclophosphamide and doxorubicin followed by histopathological response-based chemotherapy (VAC or VAC/VIE or IE + high dose busulfan/melphalan) provided superior outcomes to those of an ifosfamide-based regimen (VAI) for all cases[52]. Other studies reported a five-year OS of between 60% and 70% in non-metastatic extraosseous EFSTs[46,52,53], whereas another study reported that

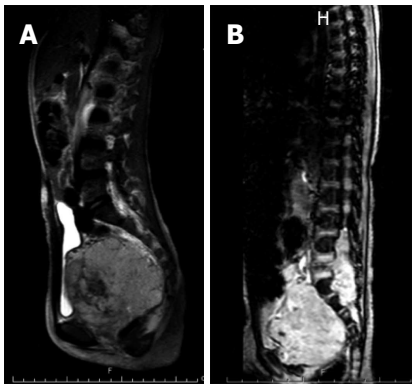

Figure 3 Magnetic resonance imaging T2: Providing a comparison between growth patterns. A: Pelvic RMS; B: MPNST. Although RMS is a locally advanced tumor, a thin surgical plane typically exists between the tumor and the adjacent bone when the MPNST involves the dural space and nerve root. RMS: Rhabdomyosarcoma; MPNST: Malignant peripheral nerve sheath tumor.

metastatic EFST exhibited a 5-year OS of approximately 25%[53].

MPNST

MPNSTs, malignant schwannomas, neurofibrosarcomas and neurogenic sarcomas account for approximately 6% of all NRSTSs[54], and approximately half of these cases are associated with neurofibromatosis type 1 syndrome[55]. An individual with the NF1 mutation has a cumulative 8% to 13% lifetime risk of developing MPNST[56]. MPNST develops within benign neurofibromas in NF1 patients[57]. In the pediatric age group, the incidence increases with age, with more than 80% of cases diagnosed at the age 10 years or older[58]. Among pediatric NRSTSs, the tumor has the worst prognosis, with a 5-year OS of 43% to 59%[59]. Complete surgical removal is the only chance for cure. Unfortunately, a number of MPNSTs involve the nerve root, preventing complete removal (Figure 3). Radiation therapy is recommended in cases with residual tumor after surgery; however, no evidence indicates that this improves survival[60]. Studies have reported that adjuvant chemotherapy exhibits only minimal benefit[58,61,62].

Synovial sarcoma

Synovial sarcoma (SS) is an aggressive spindle cell tumor that accounts for approximately 10% of all STSs[63]. Although the tumor is principally located in the lower extremities, primary SS at other sites (including the head and neck, hands, retroperitoneum, digestive system and mediastinum) have been reported[64-66]. Histologically, SS contains spindle cells with a varying degree of epithelial differentiation[67]. On immunohistochemical study, SS is marked with both mesenchymal and epithelial markers. The cytogenetic signature of SS is a reciprocal translocation t(X;18) (p11.2;q11.2) that leads to a chimeric fusion between SS18 from chromosome 18 and one of the SSXs (SSX1, SSX2 or SSX4) from chromosome X. The SS18-SSX2 fusion protein activates canonical Wnt/beta-catenin signaling, which suggests a future therapeutic target in a subset of SS[68,69]. The current management of SS is based on risk categorization, and risk determinants include the clinical group (as in RMS), size (5 cm) and sites[70]. Low-risk tumors include group Ⅰ SS and are less than 5 cm in size. Axial site tumors (head and neck, trunk, lungs and pleura) are considered high risk[71]. According to the European Pediatric Soft Tissue Sarcoma Study Group Trial (EpSSG NRSTS2005), low-risk SSs are best treated with surgery alone, with 91.7% experiencing 3-year EFS and 100% OS[71]. In that study, the surgical strategy recommended in most low-risk cases was conservative surgery. Survival in intermediate-risk SSs (group Ⅰ, size > 5 cm and group Ⅱ) after surgery followed by chemotherapy (ifosfamide and doxorubicin) with or without radiation is comparable with that of the low-risk group. Chemotherapy is the mainstay treatment in high-risk (group Ⅲ or axial SS) patients. The chemotherapy response rate in group Ⅲ SS was 55%, and OS was 74%[71].

Congenital infantile fibrosarcoma

Unlike tumors in the adult-type NRSTS group that are typically found in teenagers and adolescents, congenital infantile fibrosarcoma (CIF) can be noted during the first month of life and is often misdiagnosed as a hemangioma or vascular malformation. A rapid growth rate and ulceration are clinical clues necessitating a biopsy[72]. Histologically, CIF is densely packed with spindle cells arranged in bundles and fascicles. Tumor cells typically exhibit positive immunoreactivity with the mesenchymal marker vimentin but are negative for desmin and S100 protein. A chromosomal translocation t(12;15)(p13;q25), which leads to a fusion ETV6-NTRK3, has been reported. The tumor is locally aggressive, and distant metastasis is rarely reported. Destruction of adjacent bony structures can be observed (Figure 4). Surgical removal of the lesion is the recommended primary treatment. Adjuvant treatment is generally unnecessary except when the mass is very large and involves vital structures. In such instances, neoadjuvant chemotherapy may help down-size the tumor[73,74]. Prognostic factors include the site and extent of the lesion at the diagnosis. Extremity IF has a more favorable outcome than do axial tumors. In addition, pediatric CIF has a better outcome than adult fibrosarcoma. The five-year OS is approximately 90%[75,76].

Desmoplastic small round cell tumors

Desmoplastic small round cell tumors (DSRCT) is a rare, highly aggressive mesenchymal tumor originating on the peritoneal surface typically in an adolescent[77]. The tumor can also be found at other sites, such as the head and neck, pleura, kidneys, ovaries and testes[78-81] and was first described in 1989 in a pathological case report by Gerald and Rosai[82]. Histologically, DSRCT exhibits

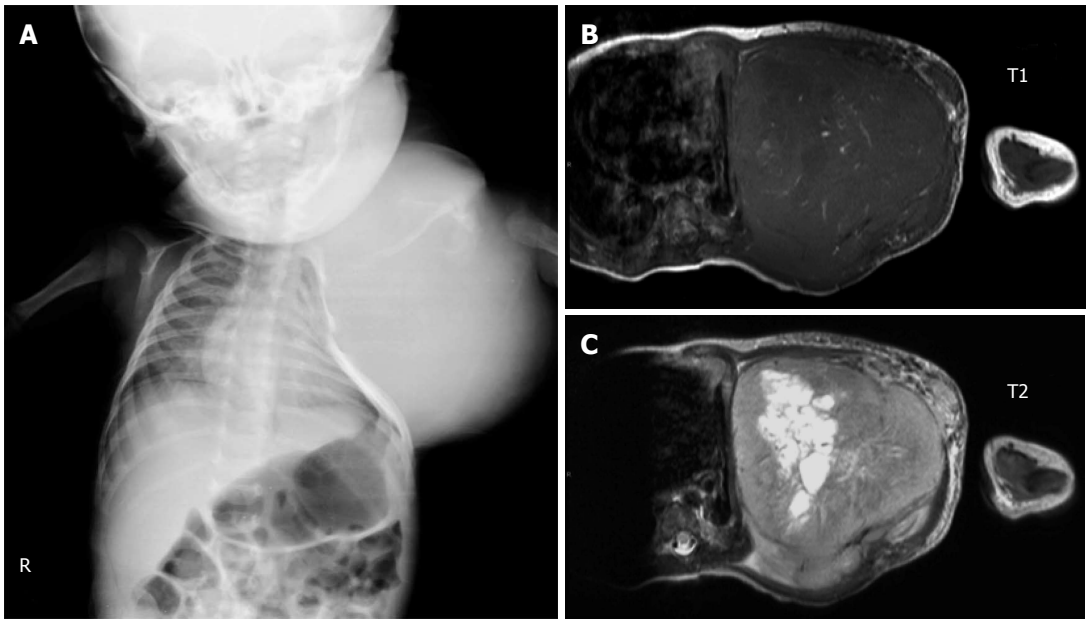

Figure 4 Plain radiographic and magnetic resonance images demonstrating deformity of the left chest wall caused by a congenital infantile sarcoma (A, B and C).

Figure 5 Computerized tomography image of a case of splenic inflammatory myofibroblastic tumor.

small round cells arranged in nests within abundant desmoplastic stroma[77]. Central necrosis and trabecular or indian fire arrangements are also observed[83]. The tumor expresses polyphenotypic differentiation with co-expression of epithelial, mesenchymal and neuronal markers[77]. In addition, nuclear staining of the WT1 protein has been reported[83]. The tumor is highly aggressive, and approximately 60% of patients die of the disease within 2 years[84]. Complete resection is not possible in the majority of cases. Surgical debulking of the primary tumor followed by radiation therapy is recommended[85,86]. The tumor appears to respond to multi-agent chemotherapy consisting of cyclophosphamide, doxorubicin, vincristine, ifosfamide and etoposide; however, recurrent disease is common[85,87]. The use of alternative therapies, including molecular targeting therapy and intraperitoneal infusion of chemotherapy, is reported infrequently[88-90]. In one study, the 3-year OS was reported at 44%, with a 5-year OS of 15%[85].

IMT

IMT (IMT, also known as inflammatory pseudotumor or plasma cell granuloma) is a rare benign tumor with recurrence potential that most often occurs in children and young adults. The lung is the most common site of IMT. Other reported sites include the urinary bladder, intestine and mesentery, spleen, liver and kidney[91-94]. The etiology of IMT may include certain infections, such as Epstein Barr virus. Whether the tumor is a true neoplasm or an inflammatory response remains controversial. However, recurrence after surgery is common and malignant transformation has been reported[95,96]. Studies have demonstrated that a number of IMT involve fusion between the *AKT* gene in chromosome 2 (2q23) and various fusion partners, including IMT, TPM3, TPM4, CLTC, CARS, RANBP2, ATIC, SEC 31L1 and PPFBP1[97-103]. CT typically reveals a coin lesion that is difficult to differentiate from other causes of similar lesions. The diagnosis is typically made by tissue biopsy that often exhibit spindle-shaped myofibroblast-like cells and chronic inflammation comprising plasma cells, lymphocytes and histiocytes[104]. Surgical resection is the only treatment option. Radiation and chemotherapy have no role in IMT (Figure 5).

STSs in the pediatric age group are a heterogeneous group of rare mesenchymal tumors. Survival outcome in pediatric STS has improved since cooperative studies were initiated by various international organizations, particularly the International Rhabdomyosarcoma Study Group. Treatment of these tumors relies on knowledge of their natural history and tumor biology as this information is used to categorize STSs according to their risk. Although surgery has been the main treatment in localized low-risk tumors, good outcomes are not achieved without adjuvant radiation and chemotherapy. Future studies in the treatment of STS are directed

toward the use of molecular diagnosis as an integral part of tumor classification. While novel modalities for the treatment of advanced stage tumors are under investigation, trials should be conducted on the reduction of treatment intensity in low-risk patients.

ACKNOWLEDGMENTS

The Anandamahidol Foundation, Thailand provided support to Sangkhathat S for this work. The inclusion of clinical and radiological pictures was approved by the Institution Review Board of the Faculty of Medicine, Prince of Songkla University. The author acknowledges the help of Dave Patterson in English language editing for the manuscript.

REFERENCES

1 **Kaatsch P**. Epidemiology of childhood cancer. *Cancer Treat Rev* 2010; **36**: 277-285 [PMID: 20231056 DOI: 10.1016/j.ctrv.2010.02.003]

2 **Hadley LG**, Rouma BS, Saad-Eldin Y. Challenge of pediatric oncology in Africa. *Semin Pediatr Surg* 2012; **21**: 136-141 [PMID: 22475119 DOI: 10.1053/j.sempedsurg.2012.01.006]

3 **Siegel DA**, King J, Tai E, Buchanan N, Ajani UA, Li J. Cancer incidence rates and trends among children and adolescents in the United States, 2001-2009. *Pediatrics* 2014; **134**: e945-e955 [PMID: 25201796 DOI: 10.1542/peds.2013-3926]

4 **Ward E**, DeSantis C, Robbins A, Kohler B, Jemal A. Childhood and adolescent cancer statistics, 2014. *CA Cancer J Clin* 2014; **64**: 83-103 [PMID: 24488779 DOI: 10.3322/caac.21219]

5 **Liu YL**, Lo WC, Chiang CJ, Yang YW, Lu MY, Hsu WM, Ho WL, Li MJ, Miser JS, Lin DT, Lai MS. Incidence of cancer in children aged 0-14 years in Taiwan, 1996-2010. *Cancer Epidemiol* 2015; **39**: 21-28 [PMID: 25599927 DOI: 10.1016/j.canep.2014.11.010]

6 **Loeb DM**, Thornton K, Shokek O. Pediatric soft tissue sarcomas. *Surg Clin North Am* 2008; **88**: 615-627, vii [PMID: 18514702 DOI: 10.1016/j.suc.2008.03.008]

7 **Kapoor G**, Das K. Soft tissue sarcomas in children. *Indian J Pediatr* 2012; **79**: 936-942 [PMID: 21935710 DOI: 10.1007/s12098-011-0560-4]

8 **Steliarova-Foucher E**, Stiller C, Lacour B, Kaatsch P. International Classification of Childhood Cancer, third edition. *Cancer* 2005; **103**: 1457-1467 [PMID: 15712273 DOI: 10.1002/cncr.20910]

9 **Dasgupta R**, Rodeberg DA. Update on rhabdomyosarcoma. *Semin Pediatr Surg* 2012; **21**: 68-78 [PMID: 22248972 DOI: 10.1053/j.sempedsurg.2011.10.007]

10 **Crucis A**, Richer W, Brugières L, Bergeron C, Marie-Cardine A, Stephan JL, Girard P, Corradini N, Munzer M, Lacour B, Minard-Colin V, Sarnacki S, Ranchere-Vince D, Orbach D, Bourdeaut F. Rhabdomyosarcomas in children with neurofibromatosis type I: A national historical cohort. *Pediatr Blood Cancer* 2015; **62**: 1733-1738 [PMID: 25893277 DOI: 10.1002/pbc.25556]

11 **Paulino AC**, Okcu MF. Rhabdomyosarcoma. *Curr Probl Cancer* 2008; **32**: 7-34 [PMID: 18206520 DOI: 10.1016/j.currproblcancer.2007.11.001]

12 **Leaphart C**, Rodeberg D. Pediatric surgical oncology: management of rhabdomyosarcoma. *Surg Oncol* 2007; **16**: 173-185 [PMID: 17689957 DOI: 10.1016/j.suronc.2007.07.003]

13 **Ilivitzki A**, Abugazala M, Arkovitz M, Benbarak A, Postovsky S, Arad-Cohen N, Ben-Arush M. Ultrasound-guided core biopsy as the primary tool for tissue diagnosis in pediatric oncology. *J Pediatr Hematol Oncol* 2014; **36**: 333-336 [PMID: 23274381 DOI: 10.1097/MPH.0b013e31827e4c4d]

14 **Federico SM**, Spunt SL, Krasin MJ, Billup CA, Wu J, Shulkin B, Mandell G, McCarville MB. Comparison of PET-CT and conventional imaging in staging pediatric rhabdomyosarcoma. *Pediatr Blood Cancer* 2013; **60**: 1128-1134 [PMID: 23255260 DOI: 10.1002/pbc.24430]

15 **Norman G**, Fayter D, Lewis-Light K, McHugh K, Levine D, Phillips B. Mind the gap: extent of use of diffusion-weighted MRI in children with rhabdomyosarcoma. *Pediatr Radiol* 2015; **45**: 778-781 [PMID: 25208650 DOI: 10.1007/s00247-014-3120-z]

16 **Alcorn KM**, Deans KJ, Congeni A, Sulkowski JP, Bagatell R, Mattei P, Minneci PC. Sentinel lymph node biopsy in pediatric soft tissue sarcoma patients: utility and concordance with imaging. *J Pediatr Surg* 2013; **48**: 1903-1906 [PMID: 24074665 DOI: 10.1016/j.jpedsurg.2013.04.013]

17 **Dall'Igna P**, De Corti F, Alaggio R, Cecchetto G. Sentinel node biopsy in pediatric patients: the experience in a single institution. *Eur J Pediatr Surg* 2014; **24**: 482-487 [PMID: 25478665 DOI: 10.1055/s-0034-1396422]

18 **Cecchetto G**, Guglielmi M, Inserra A, Zanetti I, Dall'Igna P, Gigante C, Carli M. Primary re-excision: the Italian experience in patients with localized soft-tissue sarcomas. *Pediatr Surg Int* 2001; **17**: 532-534 [PMID: 11666052 DOI: 10.1007/s003830100580]

19 **Chui CH**, Spunt SL, Liu T, Pappo AS, Davidoff AM, Rao BN, Shochat SJ. Is reexcision in pediatric nonrhabdomyosarcoma soft tissue sarcoma necessary after an initial unplanned resection? *J Pediatr Surg* 2002; **37**: 1424-1429 [PMID: 12378447 DOI: 10.1053/jpsu.2002.35405]

20 **Komasara L**, Gołębiewski A, Anzelewicz S, Czauderna P. A review on surgical techniques and organ sparing procedures in bladder/prostate rhabdomyosarcoma. *Eur J Pediatr Surg* 2014; **24**: 467-473 [PMID: 25486411 DOI: 10.1055/s-0034-1396424]

21 **Dantonello TM**, Stark M, Timmermann B, Fuchs J, Selle B, Linderkamp C, Handgretinger R, Hagen R, Feuchtgruber S, Kube S, Kosztyla D, Kazanowska B, Ladenstein R, Niggli F, Ljungman G, Bielack SS, Klingebiel T, Koscielniak E. Tumour volume reduction after neoadjuvant chemotherapy impacts outcome in localised embryonal rhabdomyosarcoma. *Pediatr Blood Cancer* 2015; **62**: 16-23 [PMID: 25263634 DOI: 10.1002/pbc.25207]

22 **Casey DL**, Wexler LH, Fox JJ, Dharmarajan KV, Schoder H, Price AN, Wolden SL. Predicting outcome in patients with rhabdomyosarcoma: role of [(18)f]fluorodeoxyglucose positron emission tomography. *Int J Radiat Oncol Biol Phys* 2014; **90**: 1136-1142 [PMID: 25539372 DOI: 10.1016/j.ijrobp.2014.08.005]

23 **Rosenberg AR**, Anderson JR, Lyden E, Rodeberg DA, Wolden SL, Kao SC, Parham DM, Arndt C, Hawkins DS. Early response as assessed by anatomic imaging does not predict failure-free survival among patients with Group III rhabdomyosarcoma: a report from the Children's Oncology Group. *Eur J Cancer* 2014; **50**: 816-823 [PMID: 24361229 DOI: 10.1016/j.ejca.2013.11.031]

24 **Ladra MM**, Mandeville HC, Niemierko A, Padera TP, Friedmann AM, MacDonald SM, Ebb D, Chen YL, Tarbell NJ, Yock TI. Local failure in parameningeal rhabdomyosarcoma correlates with poor response to induction chemotherapy. *Int J Radiat Oncol Biol Phys* 2015; **92**: 358-367 [PMID: 25864172 DOI: 10.1016/j.ijrobp.2015.01.049]

25 **Stein R**, Frees S, Schröder A, Russo A, Gutjahr P, Faber J, Thüroff JW. Radical surgery and different types of urinary diversion in patients with rhabdomyosarcoma of bladder or prostate--a single institution experience. *J Pediatr Urol* 2013; **9**: 932-939 [PMID: 23385048 DOI: 10.1016/j.jpurol.2013.01.008]

26 **van Sambeeck SJ**, Martens SJ, Hundscheid T, Janssen EJ, Vos GD. Dutch paediatrician's opinions about acute care for critically ill children in general hospitals. *Eur J Pediatr* 2015; **174**: 607-613 [PMID: 25339423 DOI: 10.1007/s00431-014-2439-7]

27 **d'Ambrosio G**, del Prete L, Grimaldi C, Bertocchini A, Lo Zupone C, Monti L, de Ville de Goyet J. Pancreaticoduodenectomy for malignancies in children. *J Pediatr Surg* 2014; **49**: 534-538 [PMID: 24726107 DOI: 10.1016/j.jpedsurg.2013.09.010]

28 **Dang ND**, Dang PT, Samuelian J, Paulino AC. Lymph node management in patients with paratesticular rhabdomyosarcoma: a population-based analysis. *Cancer* 2013; **119**: 3228-3233 [PMID: 23744806 DOI: 10.1002/cncr.28198]

29 **Gow KW**, Rapkin LB, Olson TA, Durham MM, Wyly B, Shehata

BM. Sentinel lymph node biopsy in the pediatric population. *J Pediatr Surg* 2008; **43**: 2193-2198 [PMID: 19040933 DOI: 10.1016/j.jpedsurg.2008.08.063]

30 **Dantonello TM**, Int-Veen C, Harms D, Leuschner I, Schmidt BF, Herbst M, Juergens H, Scheel-Walter HG, Bielack SS, Klingebiel T, Dickerhoff R, Kirsch S, Brecht I, Schmelzle R, Greulich M, Gadner H, Greiner J, Marky I, Treuner J, Koscielniak E. Cooperative trial CWS-91 for localized soft tissue sarcoma in children, adolescents, and young adults. *J Clin Oncol* 2009; **27**: 1446-1455 [PMID: 19224858 DOI: 10.1200/JCO.2007.15.0466]

31 **Egas-Bejar D**, Huh WW. Rhabdomyosarcoma in adolescent and young adult patients: current perspectives. *Adolesc Health Med Ther* 2014; **5**: 115-125 [PMID: 24966711]

32 **Ruymann FB**. The development of VAC chemotherapy in rhabdomyosarcoma: what does one do for an encore? *Curr Oncol Rep* 2003; **5**: 505-509 [PMID: 14521810 DOI: 10.1007/s11912-003-0012-z]

33 **Raney RB**, Walterhouse DO, Meza JL, Andrassy RJ, Breneman JC, Crist WM, Maurer HM, Meyer WH, Parham DM, Anderson JR. Results of the Intergroup Rhabdomyosarcoma Study Group D9602 protocol, using vincristine and dactinomycin with or without cyclophosphamide and radiation therapy, for newly diagnosed patients with low-risk embryonal rhabdomyosarcoma: a report from the Soft Tissue Sarcoma Committee of the Children's Oncology Group. *J Clin Oncol* 2011; **29**: 1312-1318 [PMID: 21357783 DOI: 10.1200/JCO.2010.30.4469]

34 **Crist WM**, Anderson JR, Meza JL, Fryer C, Raney RB, Ruymann FB, Breneman J, Qualman SJ, Wiener E, Wharam M, Lobe T, Webber B, Maurer HM, Donaldson SS. Intergroup rhabdomyosarcoma study-IV: results for patients with nonmetastatic disease. *J Clin Oncol* 2001; **19**: 3091-3102 [PMID: 11408506]

35 **Walterhouse DO**, Pappo AS, Meza JL, Breneman JC, Hayes-Jordan AA, Parham DM, Cripe TP, Anderson JR, Meyer WH, Hawkins DS. Shorter-duration therapy using vincristine, dactinomycin, and lower-dose cyclophosphamide with or without radiotherapy for patients with newly diagnosed low-risk rhabdomyosarcoma: a report from the Soft Tissue Sarcoma Committee of the Children's Oncology Group. *J Clin Oncol* 2014; **32**: 3547-3552 [PMID: 25267746 DOI: 10.1200/JCO.2014.55.6787]

36 **Weiss A**, Gill J, Goldberg J, Lagmay J, Spraker-Perlman H, Venkatramani R, Reed D. Advances in therapy for pediatric sarcomas. *Curr Oncol Rep* 2014; **16**: 395 [PMID: 24894064 DOI: 10.1007/s11912-014-0395-z]

37 **Pappo AS**, Vassal G, Crowley JJ, Bolejack V, Hogendoorn PC, Chugh R, Ladanyi M, Grippo JF, Dall G, Staddon AP, Chawla SP, Maki RG, Araujo DM, Geoerger B, Ganjoo K, Marina N, Blay JY, Schuetze SM, Chow WA, Helman LJ. A phase 2 trial of R1507, a monoclonal antibody to the insulin-like growth factor-1 receptor (IGF-1R), in patients with recurrent or refractory rhabdomyosarcoma, osteosarcoma, synovial sarcoma, and other soft tissue sarcomas: results of a Sarcoma Alliance for Research Through Collaboration study. *Cancer* 2014; **120**: 2448-2456 [PMID: 24797726 DOI: 10.1002/cncr.28728]

38 **McDowell HP**, Foot AB, Ellershaw C, Machin D, Giraud C, Bergeron C. Outcomes in paediatric metastatic rhabdomyosarcoma: results of The International Society of Paediatric Oncology (SIOP) study MMT-98. *Eur J Cancer* 2010; **46**: 1588-1595 [PMID: 20338746 DOI: 10.1016/j.ejca.2010.02.051]

39 **Breneman JC**, Lyden E, Pappo AS, Link MP, Anderson JR, Parham DM, Qualman SJ, Wharam MD, Donaldson SS, Maurer HM, Meyer WH, Baker KS, Paidas CN, Crist WM. Prognostic factors and clinical outcomes in children and adolescents with metastatic rhabdomyosarcoma--a report from the Intergroup Rhabdomyosarcoma Study IV. *J Clin Oncol* 2003; **21**: 78-84 [PMID: 12506174 DOI: 10.1200/JCO.2003.06.129]

40 **Magro G**, Longo FR, Angelico G, Spadola S, Amore FF, Salvatorelli L. Immunohistochemistry as potential diagnostic pitfall in the most common solid tumors of children and adolescents. *Acta Histochem* 2015; **117**: 397-414 [PMID: 25881477 DOI: 10.1016/j.acthis.2015.03.011]

41 **Waxweiler TV**, Rusthoven CG, Proper MS, Cost CR, Cost NG, Donaldson N, Garrington T, Greffe BS, Heare T, Macy ME, Liu AK. Non-Rhabdomyosarcoma Soft Tissue Sarcomas in Children: A Surveillance, Epidemiology, and End Results Analysis Validating COG Risk Stratifications. *Int J Radiat Oncol Biol Phys* 2015; **92**: 339-348 [PMID: 25968827 DOI: 10.1016/j.ijrobp.2015.02.007]

42 **Pervaiz N**, Colterjohn N, Farrokhyar F, Tozer R, Figueredo A, Ghert M. A systematic meta-analysis of randomized controlled trials of adjuvant chemotherapy for localized resectable soft-tissue sarcoma. *Cancer* 2008; **113**: 573-581 [PMID: 18521899 DOI: 10.1002/cncr.23592]

43 **Tanaka K**, Mizusawa J, Fukuda H, Araki N, Chuman H, Takahashi M, Ozaki T, Hiruma T, Tsuchiya H, Morioka H, Hatano H, Iwamoto, Y. Perioperative chemotherapy with ifosfamide and doxorubicin for high-grade soft tissue sarcomas in the extremities (JCOG0304). *Jpn J Clin Oncol* 2015; **45**: 555-561 [PMID: 25838293 DOI: 10.1093/jjco/hyv042]

44 **Peinemann F**, Labeit AM. Autologous haematopoietic stem cell transplantation following high-dose chemotherapy for non-rhabdomyosarcoma soft tissue sarcomas: a Cochrane systematic review. *BMJ Open* 2014; **4**: e005033 [PMID: 25079925 DOI: 10.1136/bmjopen-2014-005033]

45 **Delattre O**, Zucman J, Plougastel B, Desmaze C, Melot T, Peter M, Kovar H, Joubert I, de Jong P, Rouleau G. Gene fusion with an ETS DNA-binding domain caused by chromosome translocation in human tumours. *Nature* 1992; **359**: 162-165 [PMID: 1522903 DOI: 10.1038/359162a0]

46 **Biswas B**, Shukla NK, Deo SV, Agarwala S, Sharma DN, Vishnubhatla S, Bakhshi S. Evaluation of outcome and prognostic factors in extraosseous Ewing sarcoma. *Pediatr Blood Cancer* 2014; **61**: 1925-1931 [PMID: 25132242 DOI: 10.1002/pbc.25095]

47 **Brunetto AL**, Castillo LA, Petrilli AS, Macedo CD, Boldrini E, Costa C, Almeida MT, Kirst D, Rodriguez-Galindo C, Pereira WV, Watanabe FM, Pizza M, Benites E, Morais V, Gadelha A, Nakasato A, Abujamra AL, Gregianin LJ. Carboplatin in the treatment of Ewing sarcoma: Results of the first Brazilian collaborative study group for Ewing sarcoma family tumors-EWING1. *Pediatr Blood Cancer* 2015; **62**: 1747-1753 [PMID: 25917418 DOI: 10.1002/pbc.25562]

48 **Obata H**, Ueda T, Kawai A, Ishii T, Ozaki T, Abe S, Tanaka K, Tsuchiya H, Matsumine A, Yabe H. Clinical outcome of patients with Ewing sarcoma family of tumors of bone in Japan: the Japanese Musculoskeletal Oncology Group cooperative study. *Cancer* 2007; **109**: 767-775 [PMID: 17238190 DOI: 10.1002/cncr.22481]

49 **Duchman KR**, Gao Y, Miller BJ. Prognostic factors for survival in patients with Ewing's sarcoma using the surveillance, epidemiology, and end results (SEER) program database. *Cancer Epidemiol* 2015; **39**: 189-195 [PMID: 25595632 DOI: 10.1016/j.canep.2014.12.012]

50 **Shamberger RC**, LaQuaglia MP, Gebhardt MC, Neff JR, Tarbell NJ, Marcus KC, Sailer SL, Womer RB, Miser JS, Dickman PS, Perlman EJ, Devidas M, Linda SB, Krailo MD, Grier HE, Granowetter L. Ewing sarcoma/primitive neuroectodermal tumor of the chest wall: impact of initial versus delayed resection on tumor margins, survival, and use of radiation therapy. *Ann Surg* 2003; **238**: 563-567; discussion 567-568 [PMID: 14530727 DOI: 10.1097/01.sla.0000089857.45191.52]

51 **Paulussen M**, Craft AW, Lewis I, Hackshaw A, Douglas C, Dunst J, Schuck A, Winkelmann W, Köhler G, Poremba C, Zoubek A, Ladenstein R, van den Berg H, Hunold A, Cassoni A, Spooner D, Grimer R, Whelan J, McTiernan A, Jürgens H. Results of the EICESS-92 Study: two randomized trials of Ewing's sarcoma treatment--cyclophosphamide compared with ifosfamide in standard-risk patients and assessment of benefit of etoposide added to standard treatment in high-risk patients. *J Clin Oncol* 2008; **26**: 4385-4393 [PMID: 18802150 DOI: 10.1200/JCO.2008.16.5720]

52 **Castex MP**, Rubie H, Stevens MC, Escribano CC, de Gauzy JS, Gomez-Brouchet A, Rey A, Delattre O, Oberlin O. Extraosseous localized ewing tumors: improved outcome with anthracyclines--the French society of pediatric oncology and international society of pediatric oncology. *J Clin Oncol* 2007; **25**: 1176-1182 [PMID:

17401006 DOI: 10.1200/JCO.2005.05.0559]
53 **Raney RB**, Asmar L, Newton WA, Bagwell C, Breneman JC, Crist W, Gehan EA, Webber B, Wharam M, Wiener ES, Anderson JR, Maurer HM. Ewing's sarcoma of soft tissues in childhood: a report from the Intergroup Rhabdomyosarcoma Study, 1972 to 1991. *J Clin Oncol* 1997; **15**: 574-582 [PMID: 9053479]
54 **Spunt SL**, Pappo AS. Childhood nonrhabdomyosarcoma soft tissue sarcomas are not adult-type tumors. *J Clin Oncol* 2006; **24**: 1958-1959; author reply 1959-1960 [PMID: 16622276 DOI: 10.1200/JCO.2005.05.4957]
55 **Pourtsidis A**, Doganis D, Baka M, Bouhoutsou D, Varvoutsi M, Synodinou M, Giamarelou P, Kosmidis H. Malignant peripheral nerve sheath tumors in children with neurofibromatosis type 1. *Case Rep Oncol Med* 2014; **2014**: 843749 [PMID: 25317349 DOI: 10.1155/2014/843749]
56 **Ferner RE**, Gutmann DH. International consensus statement on malignant peripheral nerve sheath tumors in neurofibromatosis. *Cancer Res* 2002; **62**: 1573-1577 [PMID: 11894862]
57 **Schaefer IM**, Fletcher CD. Malignant peripheral nerve sheath tumor (MPNST) arising in diffuse-type neurofibroma: clinicopathologic characterization in a series of 9 cases. *Am J Surg Pathol* 2015; **39**: 1234-1241 [PMID: 25929351 DOI: 10.1097/Pas.0000000000000447]
58 **Bates JE**, Peterson CR, Dhakal S, Giampoli EJ, Constine LS. Malignant peripheral nerve sheath tumors (MPNST): a SEER analysis of incidence across the age spectrum and therapeutic interventions in the pediatric population. *Pediatr Blood Cancer* 2014; **61**: 1955-1960 [PMID: 25130403 DOI: 10.1002/pbc.25149]
59 **Carli M**, Ferrari A, Mattke A, Zanetti I, Casanova M, Bisogno G, Cecchetto G, Alaggio R, De Sio L, Koscielniak E, Sotti G, Treuner J. Pediatric malignant peripheral nerve sheath tumor: the Italian and German soft tissue sarcoma cooperative group. *J Clin Oncol* 2005; **23**: 8422-8430 [PMID: 16293873 DOI: 10.1200/JCO.2005.01.4886]
60 **Kahn J**, Gillespie A, Tsokos M, Ondos J, Dombi E, Camphausen K, Widemann BC, Kaushal A. Radiation therapy in management of sporadic and neurofibromatosis type 1-associated malignant peripheral nerve sheath tumors. *Front Oncol* 2014; **4**: 324 [PMID: 25452937 DOI: 10.3389/fonc.2014.00324]
61 **Grier HE**, Krailo MD, Tarbell NJ, Link MP, Fryer CJ, Pritchard DJ, Gebhardt MC, Dickman PS, Perlman EJ, Meyers PA, Donaldson SS, Moore S, Rausen AR, Vietti TJ, Miser JS. Addition of ifosfamide and etoposide to standard chemotherapy for Ewing's sarcoma and primitive neuroectodermal tumor of bone. *N Engl J Med* 2003; **348**: 694-701 [PMID: 12594313 DOI: 10.1056/NEJMoa020890]
62 **Milano GM**, Cozza R, Ilari I, De Sio L, Boldrini R, Jenkner A, De Ioris M, Inserra A, Dominici C, Donfrancesco A. High histologic and overall response to dose intensification of ifosfamide, carboplatin, and etoposide with cyclophosphamide, doxorubicin, and vincristine in patients with high-risk Ewing sarcoma family tumors: the Bambino Gesù Children's Hospital experience. *Cancer* 2006; **106**: 1838-1845 [PMID: 16532434 DOI: 10.1002/cncr.21780]
63 **Merchant MS**, Mackall CL. Current approach to pediatric soft tissue sarcomas. *Oncologist* 2009; **14**: 1139-1153 [PMID: 19897537 DOI: 10.1634/theoncologist.2009-0160]
64 **Hu PA**, Zhou ZR. Clinical, pathological and unusual MRI features of five synovial sarcomas in head and neck. *Br J Radiol* 2015; **88**: 20140843 [PMID: 25945512 DOI: 10.1259/bjr.20140843]
65 **Kambo JS**, Richardson B, Ionescu DN, Tucker T, Kraushaar G. Primary pulmonary synovial sarcoma: a case report with unique and impressive computed tomography findings. *Can Respir J* 2015; **22**: e1-e3 [PMID: 25664459]
66 **Romeo S**, Rossi S, Acosta Marín M, Canal F, Sbaraglia M, Laurino L, Mazzoleni G, Montesco MC, Valori L, Campo Dell'Orto M, Gianatti A, Lazar AJ, Dei Tos AP. Primary Synovial Sarcoma (SS) of the digestive system: a molecular and clinicopathological study of fifteen cases. *Clin Sarcoma Res* 2015; **5**: 7 [PMID: 25699170 DOI: 10.1186/s13569-015-0021-3]
67 **Thway K**, Fisher C. Synovial sarcoma: defining features and diagnostic evolution. *Ann Diagn Pathol* 2014; **18**: 369-380 [PMID: 25438927 DOI: 10.1016/j.anndiagpath.2014.09.002]
68 **Barham W**, Frump AL, Sherrill TP, Garcia CB, Saito-Diaz K, VanSaun MN, Fingleton B, Gleaves L, Orton D, Capecchi MR, Blackwell TS, Lee E, Yull F, Eid JE. Targeting the Wnt pathway in synovial sarcoma models. *Cancer Discov* 2013; **3**: 1286-1301 [PMID: 23921231 DOI: 10.1158/2159-8290.CD-13-0138]
69 **Trautmann M**, Sievers E, Aretz S, Kindler D, Michels S, Friedrichs N, Renner M, Kirfel J, Steiner S, Huss S, Koch A, Penzel R, Larsson O, Kawai A, Tanaka S, Sonobe H, Waha A, Schirmacher P, Mechtersheimer G, Wardelmann E, Büttner R, Hartmann W. SS18-SSX fusion protein-induced Wnt/β-catenin signaling is a therapeutic target in synovial sarcoma. *Oncogene* 2014; **33**: 5006-5016 [PMID: 24166495 DOI: 10.1038/onc.2013.443]
70 **Brecht IB**, Ferrari A, Int-Veen C, Schuck A, Mattke AC, Casanova M, Bisogno G, Carli M, Koscielniak E, Treuner J. Grossly-resected synovial sarcoma treated by the German and Italian Pediatric Soft Tissue Sarcoma Cooperative Groups: discussion on the role of adjuvant therapies. *Pediatr Blood Cancer* 2006; **46**: 11-17 [PMID: 16292743]
71 **Ferrari A**, De Salvo GL, Brennan B, van Noesel MM, De Paoli A, Casanova M, Francotte N, Kelsey A, Alaggio R, Oberlin O, Carli M, Ben-Arush M, Bergeron C, Merks JH, Jenney M, Stevens MC, Bisogno G, Orbach D. Synovial sarcoma in children and adolescents: the European Pediatric Soft Tissue Sarcoma Study Group prospective trial (EpSSG NRSTS 2005). *Ann Oncol* 2015; **26**: 567-572 [PMID: 25488687 DOI: 10.1093/annonc/mdu562]
72 **Mnif H**, Zrig M, Maazoun K, Sahnoun L, Bannour S, Koubaa M, Nouri A, Abid A. Congenital infantile fibrosarcoma of the forearm. *Chir Main* 2011; **30**: 148-151 [PMID: 21411358 DOI: 10.1016/j.main.2011.01.018]
73 **Russell H**, Hicks MJ, Bertuch AA, Chintagumpala M. Infantile fibrosarcoma: clinical and histologic responses to cytotoxic chemotherapy. *Pediatr Blood Cancer* 2009; **53**: 23-27 [PMID: 19340853 DOI: 10.1002/pbc.21981]
74 **Akyüz C**, Küpeli S, Varan A, Gedikoglu G, Yalçin B, Kutluk T, Büyükpamukçu M. Infantile fibrosarcoma: retrospective analysis of eleven patients. *Tumori* 2011; **97**: 166-169 [PMID: 21617710 DOI: 10.1700/667.7778]
75 **Orbach D**, Rey A, Cecchetto G, Oberlin O, Casanova M, Thebaud E, Scopinaro M, Bisogno G, Carli M, Ferrari A. Infantile fibrosarcoma: management based on the European experience. *J Clin Oncol* 2010; **28**: 318-323 [PMID: 19917847 DOI: 10.1200/JCO.2009.21.9972]
76 **Sulkowski JP**, Raval MV, Browne M. Margin status and multimodal therapy in infantile fibrosarcoma. *Pediatr Surg Int* 2013; **29**: 771-776 [PMID: 23765394 DOI: 10.1007/s00383-013-3318-4]
77 **Lae ME**, Roche PC, Jin L, Lloyd RV, Nascimento AG. Desmoplastic small round cell tumor: a clinicopathologic, immunohistochemical, and molecular study of 32 tumors. *Am J Surg Pathol* 2002; **26**: 823-835 [PMID: 12131150 DOI: 10.1097/00000478-200207000-00001]
78 **Finke NM**, Lae ME, Lloyd RV, Gehani SK, Nascimento AG. Sinonasal desmoplastic small round cell tumor: a case report. *Am J Surg Pathol* 2002; **26**: 799-803 [PMID: 12023587 DOI: 10.1097/00000478-200206000-00016]
79 **Jian Z**, Shaohong H, Wenzhao Z, Lijia G. Misdiagnosed desmoplastic small round cell tumor of the pleura: case report and literature review. *J Formos Med Assoc* 2014; **113**: 60-61 [PMID: 24445012 DOI: 10.1016/j.jfma.2011.12.002]
80 **Rao P**, Tamboli P, Fillman EP, Meis JM. Primary intra-renal desmoplastic small round cell tumor: expanding the histologic spectrum, with special emphasis on the differential diagnostic considerations. *Pathol Res Pract* 2014; **210**: 1130-1133 [PMID: 24953786 DOI: 10.1016/j.prp.2014.05.013]
81 **Yue X**, Wang JZ, Tian Y, Wang KJ. Paratesticular desmoplastic small round cell tumor with metastasis: a report of two cases. *Kaohsiung J Med Sci* 2014; **30**: 104-105 [PMID: 24444541 DOI: 10.1016/j.kjms.2013.01.018]
82 **Gerald WL**, Rosai J. Case 2. Desmoplastic small cell tumor with divergent differentiation. *Pediatr Pathol* 1989; **9**: 177-183 [PMID: 2473463 DOI: 10.3109/15513818909022347]

83 **Lee YS**, Hsiao CH. Desmoplastic small round cell tumor: a clinicopathologic, immunohistochemical and molecular study of four patients. *J Formos Med Assoc* 2007; **106**: 854-860 [PMID: 17964965 DOI: 10.1016/S0929-6646(08)60051-0]

84 **Ordóñez NG**, el-Naggar AK, Ro JY, Silva EG, Mackay B. Intra-abdominal desmoplastic small cell tumor: a light microscopic, immunocytochemical, ultrastructural, and flow cytometric study. *Hum Pathol* 1993; **24**: 850-865 [PMID: 8375856 DOI: 10.1016/0046-8177(93)90135-4]

85 **Lal DR**, Su WT, Wolden SL, Loh KC, Modak S, La Quaglia MP. Results of multimodal treatment for desmoplastic small round cell tumors. *J Pediatr Surg* 2005; **40**: 251-255 [PMID: 15868593 DOI: 10.1016/j.jpedsurg.2004.09.046]

86 **Lettieri CK**, Garcia-Filion P, Hingorani P. Incidence and outcomes of desmoplastic small round cell tumor: results from the surveillance, epidemiology, and end results database. *J Cancer Epidemiol* 2014; **2014**: 680126 [PMID: 25431592 DOI: 10.1155/2014/680126]

87 **Saab R**, Khoury JD, Krasin M, Davidoff AM, Navid F. Desmoplastic small round cell tumor in childhood: the St. Jude Children's Research Hospital experience. *Pediatr Blood Cancer* 2007; **49**: 274-279 [PMID: 16685737 DOI: 10.1002/pbc.20893]

88 **Frezza AM**, Benson C, Judson IR, Litiere S, Marreaud S, Sleijfer S, Blay JY, Dewji R, Fisher C, van der Graaf W, Hayward L. Pazopanib in advanced desmoplastic small round cell tumours: a multi-institutional experience. *Clin Sarcoma Res* 2014; **4**: 7 [PMID: 25089183 DOI: 10.1186/2045-3329-4-7]

89 **de Araújo RA**, Araújo BJ. Desmoplastic small round cell tumor: report of 2 cases treated with chemotherapy alone or in combination with bevacizumab. *Case Rep Oncol* 2014; **7**: 102-108 [PMID: 24707256 DOI: 10.1159/000359997]

90 **Fan HS**, I'Ons B, McConnell R, Kumar V, Alzahrani S, Morris DL. Peritonectomy and hyperthermic intraperitoneal chemotherapy as treatment for desmoplastic small round cell tumour. *Int J Surg Case Rep* 2015; **7C**: 85-88 [PMID: 25598401 DOI: 10.1016/j.ijscr.2014.09.022]

91 **Bhagat P**, Bal A, Das A, Singh N, Singh H. Pulmonary inflammatory myofibroblastic tumor and IgG4-related inflammatory pseudotumor: a diagnostic dilemma. *Virchows Arch* 2013; **463**: 743-747 [PMID: 24100523 DOI: 10.1007/s00428-013-1493-2]

92 **Nagarajan S**, Jayabose S, McBride W, Prasadh I, Tanjavur V, Marvin MR, Rodriguez-Davalos MI. Inflammatory myofibroblastic tumor of the liver in children. *J Pediatr Gastroenterol Nutr* 2013; **57**: 277-280 [PMID: 23974058 DOI: 10.1097/MPG.0b013e31829e0b3b]

93 **Pradhan MR**, Ranjan P, Rao RN, Chipde SS, Pradhan K, Kapoor R. Inflammatory myofibroblastic tumor of the urinary bladder managed by laparoscopic partial cystectomy. *Korean J Urol* 2013; **54**: 797-800 [PMID: 24255764 DOI: 10.4111/kju.2013.54.11.797]

94 **Groenveld RL**, Raber MH, Oosterhof-Berktas R, Eijken E, Klaase JM. Abdominal inflammatory myofibroblastic tumor. *Case Rep Gastroenterol* 2014; **8**: 67-71 [PMID: 24707245 DOI: 10.1159/000360843]

95 **Ernst CW**, Van Der Werff Ten Bosch J, Desprechins B, de Mey J, De Maeseneer M. Malignant transformation of an abdominal inflammatory myofibroblastic tumor with distant metastases in a child. *JBR-BTR* 2011; **94**: 78-80 [PMID: 21699040 DOI: 10.5334/jbr-btr.500]

96 **Ak G**, Jaaback K, Yin H, Maley P, Scurry J. Malignant inflammatory myofibroblastic tumour of the uterus. *Pathology* 2015; **47**: 380-381 [PMID: 25938352 DOI: 10.1097/PAT.0000000000000260]

97 **Lawrence B**, Perez-Atayde A, Hibbard MK, Rubin BP, Dal Cin P, Pinkus JL, Pinkus GS, Xiao S, Yi ES, Fletcher CD, Fletcher JA. TPM3-ALK and TPM4-ALK oncogenes in inflammatory myofibroblastic tumors. *Am J Pathol* 2000; **157**: 377-384 [PMID: 10934142 DOI: 10.1016/S0002-9440(10)64550-6]

98 **Bridge JA**, Kanamori M, Ma Z, Pickering D, Hill DA, Lydiatt W, Lui MY, Colleoni GW, Antonescu CR, Ladanyi M, Morris SW. Fusion of the ALK gene to the clathrin heavy chain gene, CLTC, in inflammatory myofibroblastic tumor. *Am J Pathol* 2001; **159**: 411-415 [PMID: 11485898 DOI: 10.1016/S0002-9440(10)61711-7]

99 **Cools J**, Wlodarska I, Somers R, Mentens N, Pedeutour F, Maes B, De Wolf-Peeters C, Pauwels P, Hagemeijer A, Marynen P. Identification of novel fusion partners of ALK, the anaplastic lymphoma kinase, in anaplastic large-cell lymphoma and inflammatory myofibroblastic tumor. *Genes Chromosomes Cancer* 2002; **34**: 354-362 [PMID: 12112524 DOI: 10.1002/gcc.10033]

100 **Debiec-Rychter M**, Marynen P, Hagemeijer A, Pauwels P. ALK-ATIC fusion in urinary bladder inflammatory myofibroblastic tumor. *Genes Chromosomes Cancer* 2003; **38**: 187-190 [PMID: 12939746 DOI: 10.1002/gcc.10267]

101 **Ma Z**, Hill DA, Collins MH, Morris SW, Sumegi J, Zhou M, Zuppan C, Bridge JA. Fusion of ALK to the Ran-binding protein 2 (RANBP2) gene in inflammatory myofibroblastic tumor. *Genes Chromosomes Cancer* 2003; **37**: 98-105 [PMID: 12661011 DOI: 10.1002/gcc.10177]

102 **Panagopoulos I**, Nilsson T, Domanski HA, Isaksson M, Lindblom P, Mertens F, Mandahl N. Fusion of the SEC31L1 and ALK genes in an inflammatory myofibroblastic tumor. *Int J Cancer* 2006; **118**: 1181-1186 [PMID: 16161041 DOI: 10.1002/ijc.21490]

103 **Takeuchi K**, Soda M, Togashi Y, Sugawara E, Hatano S, Asaka R, Okumura S, Nakagawa K, Mano H, Ishikawa Y. Pulmonary inflammatory myofibroblastic tumor expressing a novel fusion, PPFIBP1-ALK: reappraisal of anti-ALK immunohistochemistry as a tool for novel ALK fusion identification. *Clin Cancer Res* 2011; **17**: 3341-3348 [PMID: 21430068 DOI: 10.1158/1078-0432.CCR-11-0063]

104 **Karnak I**, Senocak ME, Ciftci AO, Cağlar M, Bingöl-Koloğlu M, Tanyel FC, Büyükpamukçu N. Inflammatory myofibroblastic tumor in children: diagnosis and treatment. *J Pediatr Surg* 2001; **36**: 908-912 [PMID: 11381424 DOI: 10.1053/jpsu.2001.23970]

P- Reviewer: Chen MK, Mostafa BE
S- Editor: Tian YL **L- Editor**: A **E- Editor**: Jiao XK

World Journal of Clinical Pediatrics

Submit a Manuscript: http://www.wjgnet.com/esps/
Help Desk: http://www.wjgnet.com/esps/helpdesk.aspx
DOI: 10.5409/wjcp.v4.i4.106

World J Clin Pediatr 2015 November 8; 4(4): 106-112
ISSN 2219-2808 (online)
© 2015 Baishideng Publishing Group Inc. All rights reserved.

MINIREVIEWS

Fever tree revisited: From malaria to autoinflammatory diseases

Serena Pastore, Josef Vuch, Anna Monica Bianco, Andrea Taddio, Alberto Tommasini

Serena Pastore, Andrea Taddio, Alberto Tommasini, Department of Pediatrics, Institute for Maternal and Child Health, IRCCS Burlo Garofolo, 34137 Trieste, Italy

Josef Vuch, Andrea Taddio, Department of Medical Surgical and Health Sciences, University of Trieste, 34137 Trieste, Italy

Anna Monica Bianco, Department of Laboratory, Institute for Maternal and Child Health, IRCCS Burlo Garofolo, 34137 Trieste, Italy

Author contributions: Pastore S drafted the manuscript; Vuch J critically revised the manuscript; Bianco AM critically revised the biological and genetic content of the manuscript; Taddio A designed and discussed the article; Tommasini A designed the article and approved the final version of the article to be published.

Conflict-of-interest statement: The authors declare no conflict of interest relevant to this study.

Open-Access: This article is an open-access article which was selected by an in-house editor and fully peer-reviewed by external reviewers. It is distributed in accordance with the Creative Commons Attribution Non Commercial (CC BY-NC 4.0) license, which permits others to distribute, remix, adapt, build upon this work non-commercially, and license their derivative works on different terms, provided the original work is properly cited and the use is non-commercial. See: http://creativecommons.org/licenses/by-nc/4.0/

Correspondence to: Alberto Tommasini, MD, PhD, Department of Pediatrics, Institute for Maternal and Child Health, IRCCS Burlo Garofolo, Via dell'Istria 65/1, 34137 Trieste, Italy. alberto.tommasini@burlo.trieste.it
Telephone: +39-40-3785422

Received: January 22, 2015
Peer-review started: February 1, 2015
First decision: March 6, 2015
Revised: March 20, 2015
Accepted: September 7, 2015
Article in press: September 8, 2015
Published online: November 8, 2015

Abstract

Over the centuries the idea of recurrent fevers has mainly been associated with malaria, but many other fevers, such as typhoid and diphtheria were cause for concern. It is only in recent times, with the more severe forms of fever from infectious origin becoming less frequent or a cause for worry that we started noticing recurrent fevers without any clear infectious cause, being described as having a pathogenesis of autoinflammatory nature. The use of molecular examinations in many cases can allow a diagnosis where the cause is monogenic. In other cases, however the pathogenesis is likely to be multifactorial and the diagnostic-therapeutic approach is strictly clinical. The old fever tree paradigm developed to describe fevers caused by malaria has been revisited here to describe today's periodic fevers from the periodic fever adenitis pharyngitis aphthae syndrome to the more rare autoinflammatory diseases. This model may allow us to place cases that are yet to be identified which are likely to be of multifactorial origin.

Key words: Recurrent fevers; Malaria; Autoinflammatory diseases; Periodic fever adenitis pharyngytis aphthe syndrome; History of medicine; Interleukin-1; Genetics; The fever tree

© The Author(s) 2015. Published by Baishideng Publishing Group Inc. All rights reserved.

Core tip: Periodic fevers of autoinflammatory nature have been increasingly recognized in recent decades, in many cases reflecting monogenic disorders of inflammation. However, patients can be encountered in clinical practice who don't fit in any definite category of periodic fever, despite of extensive molecular analyses. A clinical approach based on the analogy with the well defined monogenic diseases can be reasonable in these cases, which likely represent an heterogeneous group of multifactorial disorders. We propose revising the

historical image of the fever tree to figure the possible existence of a disease continuum between multifactorial and monogenic periodic fever syndromes.

Pastore S, Vuch J, Bianco AM, Taddio A, Tommasini A. Fever tree revisited: From malaria to autoinflammatory diseases. *World J Clin Pediatr* 2015; 4(4): 106-112 Available from: URL: http://www.wjgnet.com/2219-2808/full/v4/i4/106.htm DOI: http://dx.doi.org/10.5409/wjcp.v4.i4.106

THE CONCEPT OF FEVER: FROM FEBRILE ILLNESS TO HYPERSENSITIVITY

Fever has been considered for a long time as a primary illness in itself rather than a physiologic process occurring with disorders of various origin, marked by a raised body temperature mostly of infectious nature. In spite of this, since antiquity, some physicians believed that the high temperatures during a febrile illness could have some beneficial effects, being followed usually by a spell of sweating and subsequent resolution[1]. The idea of fever as "a mighty engine which Nature brings into the world for the conquest of her enemies" was promoted by Thomas Sydenham, even though he was unsuspecting that fever occurs as the result of immune activation caused by such "enemies" usually represented by bacteria or viruses[2].

In recent centuries, following the urbanization and the overcrowding of cities, fevers caused by epidemics such as diphtheria, flue, smallpox, measles and pertussis became a serious concern in most areas of the World, being accountable for a high death rate in early childhood. These epidemiological changes probably conditioned the notion of fever, which started to be considered a harmful reaction to infections by the body. Thus, antipyretics were initially introduced rather as an attempt to cure the fever instead of relieving sufferers from their discomfort. In actual fact, enhanced microbiological knowledge didn't immediately result in downgrading the importance of febrile temperature vis-à-vis to the infection itself, until the beginning of the twentieth century when a new concept emerges which considers fever as a manifestation of immune activation to exogenous agents[3]. At the same time, on the other hand, it was becoming apparent that hyperthermia or fever could be beneficial in supporting the healing process following various diseases such as gonorrhea and syphilis[4].

Although the mortality rate caused by infectious febrile illnesses dramatically decreased in western countries around the mid XX century, the fear of fever, or "fever phobia" quoting a term coined by Schmitt[5] in 1980, persisted within folklore beliefs to some extent until today. Moreover, it has been argued that the unrealistic concerns about fever sprung from the patient's and the caregiver's misconceptions concerning what constitutes a high temperature[1,6,7]. It may be worth recalling that as far back as 1871 Wunderlich, after collecting data on one million measurements of body temperature, established 37.0 ℃ (range 36.2-37.5) as the normal human body temperature, suggesting that temperatures above 38.0 ℃ had to be considered "suspicious" of febrile nature[8].

RECURRENT FEVERS: FROM MALARIA TO AUTOINFLAMMATORY PERIODIC FEVERS

Flares of fever recurring with a repetitive clinical picture characterize recurrent fevers, suggesting that they are brought about by a single and persistent cause[9,10]. In ancient civilizations, fever caused by malaria and typhoid was probably among the febrile illnesses of major concern. Indeed, medical historicists are still debating whether Alexander the Great died of malaria or typhoid fever[11]. Especially malaria has been for many centuries the most common and alarming recurrent fever among people living around the Mediterranean Sea. Ancient Romans celebrated the Etruscan divinity Februs with a purification ritual on the month of February. The celebration was later dedicated to the divinity febris (fever), protector from recurrent seasonal fevers due to malaria. This is where the Valentine Day celebration probably later originated from, maybe in reference to "love fever". Malaria was so rooted in the Italian wetlands that people venerated the Virgin Mary of fevers to seek for protection (Figure 1)[12].

In 1712, a few decades after quinine had become available to cure the disease, the Italian physician Torti[13] proposed a classification of febrile illnesses based on the response to quinine, which was represented in his famous figure of the fever tree (Figure 2). The fever tree was not only about malaria, but it covered all types of fever known at that time. Regardless of the real utility of a classification based on apparent response to quinine, this figure reflected the concept of fever as a leading feature of diseases.

During the first decades of the XX century, eradication of malaria from most Western countries, together with improved socioeconomic conditions and the availability of vaccines and drugs for many infectious diseases, contributed to a dramatic reduction in the mortality rates caused by febrile illnesses. At the same time, the development of laboratory diagnostics and the observation of ex juvantibus' response to antibiotics allowed the identification, in many cases, of the fever's infectious cause. It is not surprising that only in this scenario was the recurrence of fevers beginning to be noticed in some individuals without a putative infectious cause. Indeed, only after the Second World War did physicians start describing subjects with seemingly unprovoked episodes of fever, simultaneously recurring with a set of various other complaints, usually on the skin, in the joints, muscles, abdomen, chest and lymph

Figure 1 The Virgin Mary of Fevers, by Nicola Mellini, XIX century, Bologna, Italy.



Figure 2 The fever tree, Francesco Torti (image from the Comenius Project, http://89.97.218.226/web1/pontina/biologia/p_37.htm)[10].

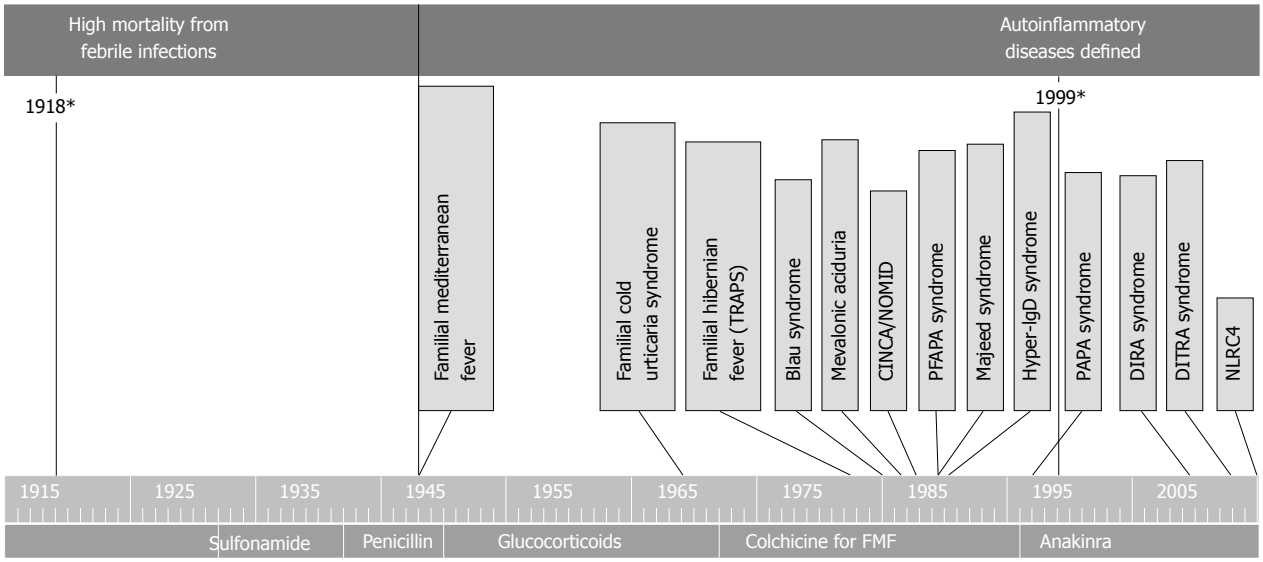

Figure 3 Timeline discovery periodic fevers autoinflammatory disease. PFAPA: Periodic fever adenitis pharyngitis aphthae; DITRA: Deficiency or interleukin-36-receptor antagonist deficiency; DIRA: Deficiency of interleukin-1–receptor antagonist; PAPA: Pyogenic arthritis, pyoderma gangrenosum, and acne.

nodes (Figure 3).

It was quite clear that such recurrent fevers were the result of a pathologic immune mechanism, but the term "autoinflammatory" was only proposed at the end of the century to describe the particular pathogenesis of these disorders[14]. The pivotal role of Interleukin 1 (IL-1) in the pathogenesis of autoinflammatory disorders (ADs) was highlighted both in experimental studies as well as in therapeutic trials with IL-1 blocking agents[15]. This change in knowledge was of particular importance, as a proper identification of this category of disorders could allow better diagnostic and therapeutic choices, avoiding useless examinations and treatments such as antibiotics[16]. Moreover, the conception of fever was changing once again, from beneficial in most infections, to harmful when becoming the expression of immune dysregulation. Actually, it is not fever in itself that is harmful, but IL-1 related inflammation.

The first AD described was familial Mediterranean fever (FMF) called by the name of "benign paroxysmal peritonitis". Clinically, FMF is characterized by recurrent and self-limited attacks of fever lasting 12-72 h with peritonitis, pleurisy, arthritis or erysipelas-like skin disease and a marked acute-phase response. Subsequent complications of untreated patients are due to renal amyloidosis. The temperature may reach 38-40 ℃ and can anticipate other symptoms, although some patients may only have a fever. Diagnosis of FMF is primarily clinical and based on the use of the diagnostic criteria[17-19].

After FMF, a number of other monogenic AD's are described, presenting recurrent fever together with several other combinations of clinical features (Figure 3).

Actually, there is a great heterogeneity among AD's concerning prevalence, severity and clinical features. On one end of the spectrum one finds the rare and often severe disorders due to mutations in a number of inflammasome-related genes, as is the case for Cryopyrinopathies, DIRA, DITRA and others, and on the opposite end there is the periodic fever adenitis pharyngitis aphthae syndrome (PFAPA). This is a relatively common disorder with likely multifactorial pathogenesis,

usually characterized by mild symptoms and a benign course[20]. It is worth noting that, although it is the most common among autoinflammatory periodic fevers, PFAPA has been described relatively late, in 1989. This delay may be related to concerns raised during the previous two centuries about rheumatic fever, in addition to the higher incidence of other serious febrile illnesses of infectious origin. Indeed, in the first decades of the XX century, Rheumatic Fever, usually occurring as a sequel of Group A Streptococcus (GAS) tonsillitis, was still a prominent health problem in developed countries, being associated with the high risk of carditis. In some subjects GAS tonsillitis could recur, increasing the risk of developing chronic hearth injury. In fact, almost one third of children underwent early tonsillectomy in the years before the Second World War and we cannot know how many of them could have had PFAPA syndrome rather than GAS tonsillitis. More often than not tonsillectomy was performed as prevention in subjects who had never developed tonsillitis. Actually, during the past century, Western countries witnessed a progressive decline in the incidence of rheumatic fever, mostly irrespective of the availability of antibiotics and to the practice of tonsillectomy[21]. Nevertheless, fear of Rheumatic Fever persisted for decades and might have been in part responsible for the delayed identification of PFAPA[22].

Half way between PFAPA and rare monogenic AD, there is a group of well characterized hereditary periodic fevers that can show up with a higher frequency in certain populations, as FMF in Mediterranean people, mevalonate kinase deficiency (MKD) in Dutch and tumor necrosis factor associated periodic fever (TRAPS) in people with Northern European ancestry[23]. Patients with MKD present fever episodes lasting 3 to 7 d that typically recur every 4 to 6 wk. The fever may be accompanied by lymphadenopathy, abdominal pain with diarrhea or vomiting, headache, polyarthralgia or arthritis of large joints, skin lesions such as papular, urticarial, nodular or purpuric rash. Patients with TRAPS show attacks of extremely variable duration and intensity (from 1-2 d to 3-4 wk), characterized by fever accompanied more or less constantly by sterile peritonitis with abdominal pain, diarrhea or constipation, nausea, and vomiting. Mono- or bilateral periorbital edema is a very characteristic and almost pathognomonic sign of the disease, often associated with conjunctivitis and periorbital pain. Also very frequent are arthralgias, muscle cramps, centrifugally spreading migratory myalgias, chronic fasciitis, serpiginous rash, consisting of migratory and painful patches[24,25].

Besides a few exceptions, a common feature of periodic fever syndromes is the reversibility of symptoms with a complete sense of wellbeing outside the flares, lacking the development of sustained autoimmunity and progressive inflammatory damage. Exceptions are severe ADs which tend to present a continuous course rather than a periodic one as well as specific syndromes such as FMF and TRAPS which, if not treated, present a varying high risk of developing amyloidosis[26].

NOVEL CONCEPTS AND THE FEVER TREE REVISITED

In the last decade, some evidences have been accumulated demonstrating a poor correlation between phenotype and genotype in AD. Environmental factors can modify the clinical presentation, as in the case of FMF. This was elegantly demonstrated by the evidence represented by the people with FMF who immigrated to Germany and in spite of similar genetic backgrounds, tended to present milder symptoms compared with their cousins who remained in Turkey[27]. In addition, although it is well known that FMF is transmitted with autosomal recessive inheritance, in certain families some mutations can be associated with a dominant inheritance, this has lead to the belief that there are other possible contributions in the pathology stemming from other genetic and environmental factors.

Indeed, patients with heterozygous mutation or with multiple low penetrance variants in the *MEFV* gene may display attenuated phenotypes resembling more PFAPA than FMF, making it difficult to definitely confirm the diagnosis of FMF[28].

A similar behavior is also described when talking about other periodic fever syndromes, such as TRAPS. Some genetic variants for example, relatively common in the general population, may have low penetrance occurring mostly in healthy people, that can also be associated, in some individuals, with a typical manifestation of the disease[29]. In fact, the correlation between genotype and phenotype in patients with AD is often incomplete and many patients could receive the wrong diagnoses such as inflammatory bowel disease, Behçet disease or adult onset Still disease, being excluded from genetic testing for AD[16,30].

In addition, a number of recent reports showed that it could be relatively common, even following extensive molecular analysis, to find subjects with periodic fever lacking a definite genetic diagnosis[31-34]. In some cases genetic variants of uncertain significance in AD-related genes may be found, yet their relevance for diagnosis is currently unpredictable[35,36]. Recently, evidence-based provisional clinical classification criteria for autoinflammatory periodic fevers have been proposed, which may help diagnosing patients with uncertain genetic results[37]. In addition, these criteria can be used to classify patients with undifferentiated diseases based on the similarity of their clinical pictures with the known hereditary periodic fever syndromes.

To represent this complexity, we proposed revisiting the ancient figure of the fever tree (Figure 4).

The figure of the tree can serve to represent AD as a disease continuum, from the common multifactorial PFAPA syndrome, which is figured by the trunk, to the rare monogenic diseases, represented by the tip of the branches. Going from the trunk to the major limbs

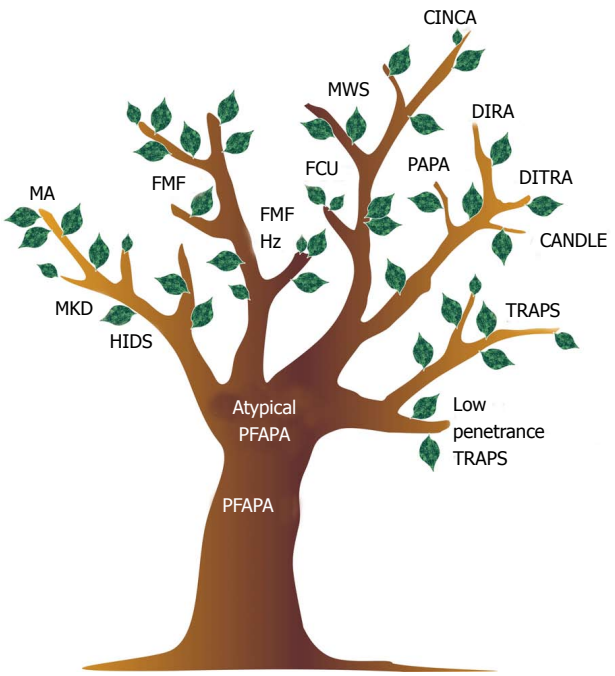

Figure 4 The fever tree revisited. PFAPA: Periodic fever adenitis pharyngitis aphthae; MKD: Mevalonate kinase deficiency; FMF: Familial mediterranean fever; HIDS: Hyper-IgD syndrome; CINCA: Chronic infantile neurologic cutaneous and articular syndrome; MWS: Muckle wells syndrome; DIRA: Deficiency of the interleukin-1 receptor antagonist; FCU: Familial cold urticaria; DITRA: Deficiency or interleukin-36-receptor antagonist deficiency; MA: Mevalonic aciduria.

and then up to the top of the smaller branches, we can find a number of intermediate phenotypes, which might be underpinned by a variety of genetic variants in the same genes, which have evolved towards more severe forms, or other genes altogether which are yet to be identified. For example, low penetrance mutations in the genes responsible for FMF, TRAPS and MKD have been associated with PFAPA-like phenotype[28,29]. Indeed, MKD encompasses a wide range of phenotypes, from the most severe end, represented by mevalonic aciduria which we can figure on the tip of the branch, to MKD and Hyper-IgD syndrome, which in milder cases can closely resemble PFAPA[38].

PFAPA itself may not be actually considered as a single disease, but rather as a heterogeneous syndrome. Atypical cases have been described, and can currently be encountered. Typically, patients with PFAPA present episodes of tonsillopharyngitis accompanied by enlarged neck lymph nodes and mouth aphthae: the periodic recurrence of fever episodes, the response to a single administration of low dose glucocorticoids, and the conclusive healing after tonsillectomy are all characteristic features of the disease. However, it is not uncommon to encounter patients with periodic fever and tonsillitis who present atypical signs, such as a poor response to glucocorticoids, a recurrence following tonsillectomy or the presence of significant cutaneous, articular or abdominal symptoms, in addition to pharyngeal involvement. In a small proportion of these atypical PFAPA cases, a definite diagnosis of hereditary periodic fever can be done (*e.g.*, MKD or TRAPS), while in most cases the analysis of a more or less complete set of genes associated with HPF can only reveal the presence of common genetic variants of vague significance or no variants at all. Few cases in this group may still be due to yet unidentified monogenic disorders or to somatic mosaicism for mutations in autoinflammatory genes, similarly to what has been described for subjects with cryopirin associated periodic syndromes or Blau sindrome[39,40]. In most cases, however, it is reasonable to assume that this group is composed by patients with true multifactorial disorders with intermediate characteristics between PFAPA and various types of autoinflammatory diseases. In this regard, it is worth noting that some patients with atypical PFAPA may respond to colchicine, in analogy with FMF. Operatively, we could represent the disease of such patients on the fever tree positioned between the PFAPA trunk and the bottom of the FMF branch.

This picture doesn't claim to be complete but can help to be confronted with an expanding spectrum of AD's, including patients with atypical presentations lacking a definite genetic diagnosis. Further studies are needed to understand the role of genetic and environmental factors in these cases. Moreover, it remains to be evaluated whether a practical approach based on the clinical analogies with well defined AD's can represent a reasonable choice in these cases.

In fact, so far, we can identify only a few groups of diseases based on the response to treatments and in particular if there is a preferential response to low dose glucocorticoids, colchicines or cytokine inhibitors (IL-1 or TNF-α).

It may be worth recording that, in regards to autoinflammatory diseases, fever in itself, is never the harm. Treatments should be aimed at relieving patients from pain and discomfort and, in some diseases in preventing long-term damage from chronic inflammation.

This review may tell just a part of the story and represent a simplification of the field. However, as physicians, we still need to be able to cure, understand, and act expediently in daily practice when dealing with the disease, without necessarily knowing the genetic makeup of each individual patient with his or her individual variability, manifestation and diseases development, keeping in mind that the personalization of medicine is not just genetically driven.

REFERENCES

1 **El-Radhi AS**. Fever management: Evidence vs current practice. *World J Clin Pediatr* 2012; **1**: 29-33 [PMID: 25254165 DOI: 10.5409/wjcp.v1.i4.29]

2 **Avner JR**. Acute fever. *Pediatr Rev* 2009; **30**: 5-13; quiz 13 [PMID: 19118137 DOI: 10.1542/pir.30-1-5]

3 **Menkin V**. Chemical basis of fever. *Science* 1944; **100**: 337-338 [PMID: 17743364 DOI: 10.1126/science.100.2598.337]

4 **Whitrow M**. Wagner-Jauregg and fever therapy. *Med Hist* 1990; **34**: 294-310 [PMID: 2214949 DOI: 10.1017/S0025727300052431]

5 **Schmitt BD**. Fever phobia: misconceptions of parents about

fevers. *Am J Dis Child* 1980; **134**: 176-181 [PMID: 7352443 DOI: 10.1001/archpedi.1980.02130140050015]
6 **Crocetti M**, Moghbeli N, Serwint J. Fever phobia revisited: have parental misconceptions about fever changed in 20 years? *Pediatrics* 2001; **107**: 1241-1246 [PMID: 11389237 DOI: 10.1542/peds.107.6.1241]
7 **Wallenstein MB**, Schroeder AR, Hole MK, Ryan C, Fijalkowski N, Alvarez E, Carmichael SL. Fever literacy and fever phobia. *Clin Pediatr* (Phila) 2013; **52**: 254-259 [PMID: 23349363 DOI: 10.1177/0009922812472252]
8 **Marshall GS**. Prolonged and recurrent fevers in children. *J Infect* 2014; **68** Suppl 1: S83-S93 [PMID: 24120354 DOI: 10.1016/j.jinf.2013.09.017]
9 **Kastner DL**. Hereditary periodic fever syndromes. *Hematology Am Soc Hematol Educ Program* 2005: 74-81 [PMID: 16304362 DOI: 10.1182/asheducation-2005.1.74]
10 **Larsson C**, Andersson M, Bergström S. Current issues in relapsing fever. *Curr Opin Infect Dis* 2009; **22**: 443-449 [PMID: 19623064 DOI: 10.1097/QCO.0b013e32832fb22b]
11 **Cunha BA**. The death of Alexander the Great: malaria or typhoid fever? *Infect Dis Clin North Am* 2004; **18**: 53-63 [PMID: 15081504 DOI: 10.1016/S0891-5520(03)00090-4]
12 **Lavagnino A**. La mala aria. Palermo, Italy: Sellerio, 2010
13 **Torti F**. Therapeutice specialis ad febres quasdam perniciosas, inopinato, ac repente lethales, una verò China China, peculiari methodo ministrata, sanabiles. Modena, Italy: Typis Bartholomaei Soliani, 1712
14 **McDermott MF**, Aksentijevich I, Galon J, McDermott EM, Ogunkolade BW, Centola M, Mansfield E, Gadina M, Karenko L, Pettersson T, McCarthy J, Frucht DM, Aringer M, Torosyan Y, Teppo AM, Wilson M, Karaarslan HM, Wan Y, Todd I, Wood G, Schlimgen R, Kumarajeewa TR, Cooper SM, Vella JP, Amos CI, Mulley J, Quane KA, Molloy MG, Ranki A, Powell RJ, Hitman GA, O'Shea JJ, Kastner DL. Germline mutations in the extracellular domains of the 55 kDa TNF receptor, TNFR1, define a family of dominantly inherited autoinflammatory syndromes. *Cell* 1999; **97**: 133-144 [PMID: 10199409]
15 **McGonagle D**, Aziz A, Dickie LJ, McDermott MF. An integrated classification of pediatric inflammatory diseases, based on the concepts of autoinflammation and the immunological disease continuum. *Pediatr Res* 2009; **65**: 38R-45R [PMID: 19190531 DOI: 10.1203/PDR.0b013e31819dbd0a]
16 **Berody S**, Galeotti C, Koné-Paut I, Piram M. A restrospective survey of patients's journey before the diagnosis of mevalonate kinase deficiency. *Joint Bone Spine* 2015; **82**: 240-244 [PMID: 25677409 DOI: 10.1016/j.jbspin.2014.12.011]
17 **Livneh A**, Langevitz P, Zemer D, Zaks N, Kees S, Lidar T, Migdal A, Padeh S, Pras M. Criteria for the diagnosis of familial Mediterranean fever. *Arthritis Rheum* 1997; **40**: 1879-1885 [PMID: 9336425]
18 **Yalçinkaya F**, Ozen S, Ozçakar ZB, Aktay N, Cakar N, Düzova A, Kasapçopur O, Elhan AH, Doganay B, Ekim M, Kara N, Uncu N, Bakkaloglu A. A new set of criteria for the diagnosis of familial Mediterranean fever in childhood. *Rheumatology* (Oxford) 2009; **48**: 395-398 [PMID: 19193696 DOI: 10.1093/rheumatology/ken509]
19 **Portincasa P**, Scaccianoce G, Palasciano G. Familial mediterranean fever: a fascinating model of inherited autoinflammatory disorder. *Eur J Clin Invest* 2013; **43**: 1314-1327 [PMID: 24117178 DOI: 10.1111/eci.12170]
20 **Marshall GS**, Edwards KM, Lawton AR. PFAPA syndrome. *Pediatr Infect Dis J* 1989; **8**: 658-659 [PMID: 2797967 DOI: 10.1097/00006454-198909000-00026]
21 **English PC**. Rheumatic fever in America and Britain: A biological, epidemiological, and medical history. Rutgers University Press, 1999
22 **Frenkel J**, Kuis W. Overt and occult rheumatic diseases: the child with chronic fever. *Best Pract Res Clin Rheumatol* 2002; **16**: 443-469 [PMID: 12387810 DOI: 10.1016/S1521-6942(02)90239-1]
23 **Drenth JP**, van der Meer JW. Hereditary periodic fever. *N Engl J Med* 2001; **345**: 1748-1757 [PMID: 11742050 DOI: 10.1056/NEJMra010200]
24 **Caso F**, Rigante D, Vitale A, Lucherini OM, Costa L, Atteno M, Compagnone A, Caso P, Frediani B, Galeazzi M, Punzi L, Cantarini L. Monogenic autoinflammatory syndromes: state of the art on genetic, clinical, and therapeutic issues. *Int J Rheumatol* 2013; **2013**: 513782 [PMID: 24282415 DOI: 10.1155/2013/513782]
25 **Almeida de Jesus A**, Goldbach-Mansky R. Monogenic autoinflammatory diseases: concept and clinical manifestations. *Clin Immunol* 2013; **147**: 155-174 [PMID: 23711932 DOI: 10.1016/j.clim.2013.03.016]
26 **van der Hilst JC**, Simon A, Drenth JP. Hereditary periodic fever and reactive amyloidosis. *Clin Exp Med* 2005; **5**: 87-98 [PMID: 16284730 DOI: 10.1007/s10238-005-0071-6]
27 **Giese A**, Örnek A, Kilic L, Kurucay M, Şendur SN, Lainka E, Henning BF. Disease severity in adult patients of Turkish ancestry with familial mediterranean fever living in Germany or Turkey. Does the country of residence affect the course of the disease? *J Clin Rheumatol* 2013; **19**: 246-251 [PMID: 23872541 DOI: 10.1097/RHU.0b013e31829ce005]
28 **Federici S**, Calcagno G, Finetti M, Gallizzi R, Meini A, Vitale A, Caroli F, Cattalini M, Caorsi R, Zulian F, Tommasini A, Insalaco A, Sormani MP, Baldi M, Ceccherini I, Martini A, Gattorno M. Clinical impact of MEFV mutations in children with periodic fever in a prevalent western European Caucasian population. *Ann Rheum Dis* 2012; **71**: 1961-1965 [PMID: 22580583 DOI: 10.1136/annrheumdis-2011-200977]
29 **Pelagatti MA**, Meini A, Caorsi R, Cattalini M, Federici S, Zulian F, Calcagno G, Tommasini A, Bossi G, Sormani MP, Caroli F, Plebani A, Ceccherini I, Martini A, Gattorno M. Long-term clinical profile of children with the low-penetrance R92Q mutation of the TNFRSF1A gene. *Arthritis Rheum* 2011; **63**: 1141-1150 [PMID: 21225694 DOI: 10.1002/art.30237]
30 **Hoffmann GF**, Charpentier C, Mayatepek E, Mancini J, Leichsenring M, Gibson KM, Divry P, Hrebicek M, Lehnert W, Sartor K. Clinical and biochemical phenotype in 11 patients with mevalonic aciduria. *Pediatrics* 1993; **91**: 915-921 [PMID: 8386351]
31 **Bleeker-Rovers CP**, Vos FJ, de Kleijn EM, Mudde AH, Dofferhoff TS, Richter C, Smilde TJ, Krabbe PF, Oyen WJ, van der Meer JW. A prospective multicenter study on fever of unknown origin: the yield of a structured diagnostic protocol. *Medicine* (Baltimore) 2007; **86**: 26-38 [PMID: 17220753 DOI: 10.1097/MD.0b013e31802fe858]
32 **Simon A**, van der Meer JW, Vesely R, Myrdal U, Yoshimura K, Duys P, Drenth JP. Approach to genetic analysis in the diagnosis of hereditary autoinflammatory syndromes. *Rheumatology* (Oxford) 2006; **45**: 269-273 [PMID: 16234278 DOI: 10.1093/rheumatology/kei138]
33 **Cantarini L**, Vitale A, Lucherini OM, De Clemente C, Caso F, Costa L, Emmi G, Silvestri E, Magnotti F, Maggio MC, Prinzi E, Lopalco G, Frediani B, Cimaz R, Galeazzi M, Rigante D. The labyrinth of autoinflammatory disorders: a snapshot on the activity of a third-level center in Italy. *Clin Rheumatol* 2015; **34**: 17-28 [PMID: 24953660 DOI: 10.1007/s10067-014-2721-0]
34 **De Pieri C**, Vuch J, De Martino E, Bianco AM, Ronfani L, Athanasakis E, Bortot B, Crovella S, Taddio A, Severini GM, Tommasini A. Genetic profiling of autoinflammatory disorders in patients with periodic fever. A prospective study. *Pediatr Rheumatol Online J* 2015; **13**: 11 [DOI: 10.1186/s12969-015-0006-z]
35 **Shinar Y**, Obici L, Aksentijevich I, Bennetts B, Austrup F, Ceccherini I, Costa JM, De Leener A, Gattorno M, Kania U, Kone-Paut I, Lezer S, Livneh A, Moix I, Nishikomori R, Ozen S, Phylactou L, Risom L, Rowczenio D, Sarkisian T, van Gijn ME, Witsch-Baumgartner M, Morris M, Hoffman HM, Touitou I. Guidelines for the genetic diagnosis of hereditary recurrent fevers. *Ann Rheum Dis* 2012; **71**: 1599-1605 [PMID: 22661645 DOI: 10.1136/annrheumdis-2011-201271]
36 **Marcuzzi A**, Piscianz E, Kleiner G, Tommasini A, Severini GM, Monasta L, Crovella S. Clinical genetic testing of periodic fever syndromes. *Biomed Res Int* 2013; **2013**: 501305 [PMID: 23484126 DOI: 10.1155/2013/501305]

37 **Federici S**, Sormani MP, Ozen S, Lachmann HJ, Amaryan G, Woo P, Koné-Paut I, Dewarrat N, Cantarini L, Insalaco A, Uziel Y, Rigante D, Quartier P, Demirkaya E, Herlin T, Meini A, Fabio G, Kallinich T, Martino S, Butbul AY, Olivieri A, Kuemmerle-Deschner J, Neven B, Simon A, Ozdogan H, Touitou I, Frenkel J, Hofer M, Martini A, Ruperto N, Gattorno M. Evidence-based provisional clinical classification criteria for autoinflammatory periodic fevers. *Ann Rheum Dis* 2015; **74**: 799-805 [PMID: 25637003 DOI: 10.1136/annrheumdis-2014-206580]

38 **De Pieri C**, Taddio A, Insalaco A, Barbi E, Lepore L, Ventura A, Tommasini A. Different presentations of mevalonate kinase deficiency: a case series. *Clin Exp Rheumatol* 2015; **33**: 437-442 [PMID: 25897835]

39 **de Inocencio J**, Mensa-Vilaro A, Tejada-Palacios P, Enriquez-Merayo E, González-Roca E, Magri G, Ruiz-Ortiz E, Cerutti A, Yagüe J, Aróstegui JI. Somatic NOD2 mosaicism in Blau syndrome. *J Allergy Clin Immunol* 2015; **136**: 484-487.e2 [PMID: 25724124 DOI: 10.1016/j.jaci.2014.12.1941]

40 **Nakagawa K**, Gonzalez-Roca E, Souto A, Kawai T, Umebayashi H, Campistol JM, Cañellas J, Takei S, Kobayashi N, Callejas-Rubio JL, Ortego-Centeno N, Ruiz-Ortiz E, Rius F, Anton J, Iglesias E, Jimenez-Treviño S, Vargas C, Fernandez-Martin J, Calvo I, Hernández-Rodríguez J, Mendez M, Dordal MT, Basagaña M, Bujan S, Yashiro M, Kubota T, Koike R, Akuta N, Shimoyama K, Iwata N, Saito MK, Ohara O, Kambe N, Yasumi T, Izawa K, Kawai T, Heike T, Yagüe J, Nishikomori R, Aróstegui JI. Somatic NLRP3 mosaicism in Muckle-Wells syndrome. A genetic mechanism shared by different phenotypes of cryopyrin-associated periodic syndromes. *Ann Rheum Dis* 2015; **74**: 603-610 [PMID: 24326009 DOI: 10.1136/annrheumdis-2013-204361]

P- Reviewer: Lichtor T, Schattner M, Yves R
S- Editor: Gong XM **L- Editor**: A **E- Editor**: Jiao XK

World Journal of Clinical Pediatrics

Submit a Manuscript: http://www.wjgnet.com/esps/
Help Desk: http://www.wjgnet.com/esps/helpdesk.aspx
DOI: 10.5409/wjcp.v4.i4.113

World J Clin Pediatr 2015 November 8; 4(4): 113-119
ISSN 2219-2808 (online)
© 2015 Baishideng Publishing Group Inc. All rights reserved.

MINIREVIEWS

Efficiency of upper gastrointestinal endoscopy in pediatric surgical practice

Abdulkerim Temiz

Abdulkerim Temiz, Department of Pediatric Surgery, Başkent University, Faculty of Medicine, Adana Research and Educational Hospital, 01150 Seyhan, Turkey

Author contributions: Temiz A solely contributed to this manuscript.

Conflict-of-interest statement: None.

Open-Access: This article is an open-access article which was selected by an in-house editor and fully peer-reviewed by external reviewers. It is distributed in accordance with the Creative Commons Attribution Non Commercial (CC BY-NC 4.0) license, which permits others to distribute, remix, adapt, build upon this work non-commercially, and license their derivative works on different terms, provided the original work is properly cited and the use is non-commercial. See: http://creativecommons.org/licenses/by-nc/4.0/

Correspondence to: Dr. Abdulkerim Temiz, MD, Associate Professor, Department of Pediatric Surgery, Baskent University, Faculty of Medicine, Adana Research and Educational Hospital, Baraj Road, 1. Stop, Seyhan Hospital, 01150 Seyhan, Turkey. aktemiz@yahoo.com
Telephone: +90-322-4586868-1000
Fax: +90-322-4592622

Received: April 28, 2015
Peer-review started: April 29, 2015
First decision: May 14, 2015
Revised: June 17, 2015
Accepted: August 13, 2015
Article in press: August 14, 2015
Published online: November 8, 2015

Abstract

After the introduction of flexible fiber optic endoscopy to pediatric gastroenterology in the 1970s, upper gastrointestinal (UGI) endoscopy can be performed for the diagnosis and treatment of all age groups of children. We review indications, contraindications, preparation of patients for the procedure, and details of diagnostic and therapeutic UGI endoscopy used in pediatric surgery. We also discuss potential complications of endoscopy.

Key words: Endoscopy; Upper gastrointestinal system; Pediatric surgery; Diagnosis; Treatment

© The Author(s) 2015. Published by Baishideng Publishing Group Inc. All rights reserved.

Core tip: Flexible upper gastrointestinal (UGI) endoscopy is a diagnostic and therapeutic procedure accepted worldwide for some UGI diseases in children. With the advances and innovations in the field of pediatric endoscopy and equipment, UGI endoscopic procedures have been safely and effectively used in children with minor complications in experienced hands. In this review, we summarize the efficiency of UGI endoscopic procedures in pediatric surgery.

Temiz A. Efficiency of upper gastrointestinal endoscopy in pediatric surgical practice. *World J Clin Pediatr* 2015; 4(4): 113-119 Available from: URL: http://www.wjgnet.com/2219-2808/full/v4/i4/113.htm DOI: http://dx.doi.org/10.5409/wjcp.v4.i4.113

INTRODUCTION

The anatomical area located above the junction of the duodenum and jejunum is described as the upper gastrointestinal (UGI) system. It includes the mouth, pharynx, esophagus, stomach and duodenum with the extra-hepatic pancreaticobiliary tree. Many congenital or acquired pathologies of the UGI system are encountered in pediatric surgical practice. Several diagnostic and therapeutic endoscopic interventions are required in some of these patients. After the introduction of flexible fiber optic endoscopy to pediatric gastroenterology in the 1970s, and through technological developments in the

Table 1 Most common indications of diagnostic upper gastrointestinal endoscopy

Caustic ingestion
Gastrointestinal bleeding
Dysphagia or odynophagia
Recurrent or epigastric abdominal pain
Failure to thrive or weight loss
Vomiting
Chronic or complicated GER
Diarrhea or malabsorption
Investigation for iron deficiency anemia
Inflammatory bowel disease

GER: Gastroesophageal reflux.

Table 2 Most common detected pathologies in upper gastrointestinal bleeding

Erosive esophagitis
Gastritis
Peptic ulcer disease
Esophageal varices
Duodenitis or duodenal ulcer
Mallory-Weiss tears
Gastric erosion
Dieulafoy's lesion
Angioectasia
Esophageal or gastric polyps

size and flexibility of endoscopes, UGI endoscopy can be performed even on premature infants from the first day of birth with smaller endoscopes[1-5]. Initially, endoscopy was used only for diagnostic study in children. With advances and innovations in the field of pediatric endoscopy and equipment, the frequency of therapeutic procedures such as removal of ingested foreign bodies, percutaneous endoscopic gastrostomy (PEG), ligation of esophageal varices, polypectomy, injection therapy, endoscopic retrograde cholangiopancreaticography (ERCP), and peroral endoscopic myotomy (POEM) has gradually increased in children.

DIAGNOSTIC ENDOSCOPY

Dyspepsia, UGI bleeding and abdominal pain are the most common indications for diagnostic UGI endoscopy in pediatric surgical practice[3,4,6-10]. The indications are summarized in Table 1[1-3]. Because endoscopy is performed easily and quickly, the number of patients undergoing negative endoscopy increases gradually, which causes increased economic burden. However, as a result of this practice several new diseases and pathologies of the UGI system in childhood have been described[10]. There is still no definitive description of dyspepsia. Epigastric pain, fullness, vomiting, regurgitation, nausea, abdominal discomfort, and bloating are commonly accepted as dyspeptic symptoms[11]. Guariso *et al*[11] reported that endoscopy is not necessary for all children with dyspeptic symptoms. They recommended endoscopy for patients with a family history of peptic ulcer or *Helicobacter pylori* infection, older than 10 years of age, with symptoms continuing for more than 6 mo or whose daily activities are affected. Various disorders such as gastritis, duodenitis, esophagitis, and peptic ulcer may cause recurrent or chronic abdominal pain in children. UGI endoscopy should be performed in children with intractable or unexplained abdominal pain. Multiple biopsies should be done randomly from the esophagus, stomach and duodenum during endoscopy, especially from the distal esophagus and antrum, even if these areas are macroscopically normal.

UGI bleeding is not uncommon and is usually a self-limited clinical condition. The causes of UGI bleeding are listed in Table 2[3,12-15]. UGI bleeding affected only 5% of patients who underwent UGI endoscopy[12]. Although causes vary among reports, excessive UGI bleeding commonly arises from esophageal varices, peptic ulcer, gastritis, esophagitis or esophageal ulcer[3,13-15]. Polyps, inflammatory disorders, Dieulafoy's lesion or vascular malformations such as angioectasia are less common in children[3,16-19]. The causes and sources of UGI bleeding are defined by endoscopy in 85%-90% of patients. Rates of misdiagnosis of bleeding of between 10% and 27% have been reported in different studies[15,20,21].

The diagnosis of gastroesophageal reflux disease (GERD) is commonly made by pH meter, barium meal test or scintigraphy. Endoscopy and esophageal biopsy are used for the diagnosis of complicated GERD, suspected but unproven or demonstrated GERD, or to exclude other diseases that can mimic GERD such as eosinophilic or infectious esophagitis and Crohn's disease[22,23]. Because normal endoscopic appearance of the esophageal mucosa does not exclude esophagitis, endoscopic biopsy should be done in all patients. The tonus of the lower esophageal sphincter and the location of the esophagogastric junction are also considered. El Mouzan *et al*[23] reported that esophageal pH monitoring was the most specific diagnostic study (91% specificity), whereas endoscopy was the most sensitive diagnostic tool (92% sensitivity) for GERD.

Caustic ingestion is another common clinical condition which requires UGI endoscopy in pediatric surgical practice. Different diagnostic trials such as radiocontrast esophagography, scintigraphy, and esophageal ultrasound have been conducted to diagnose caustic injuries. Several studies have reported that clinical signs are not always helpful in predicting the degree of injury[24-26]. Upper gastrointestinal system endoscopy is the most effective method for establishing the severity of injury and for planning treatment. Because the esophagus is weakest between days 7 and 21 after caustic injury and the frequency of endoscopic complications also usually increases during this period, endoscopy is recommended in the first 24-48 h of injury[24-26]. It is usually recommended to stop endoscopy at the first circumferential esophageal burn because of the increased risk of complications beyond this point[27]. This approach might cause a more severely burned esophagus or

stomach to be missed. We observed severe gastric injury in 18.4% of patients; gastric injury was more severe than esophageal injury in 3.4% of patients in our study[28]. Therefore we suggest complete upper GİS endoscopy if possible in children with caustic injuries[28]. UGI endoscopy revealed severe esophageal injury in 19.3% of our patients that did not have symptoms. In contrast, 59.7% of the patients with positive clinical symptoms had no or grade 1 esophageal injury. In these circumstances endoscopy prevents unnecessary hospitalization and also decreases complication rates[28].

DIAGNOSTIC ENDOSCOPY WITH THERAPEUTIC PROCEDURES

Massive UGI bleeding is a life-threatening condition and requires expeditious resuscitation and hemostatic therapy. Massive bleeding usually results from peptic ulcer, esophageal varices, Dieulafoy's lesion or vascular malformations[3,14,20]. Therapeutic interventions should be attempted at the same time as diagnostic endoscopy in the presence of active bleeding, non-bleeding visible vessels, or adherent cloth. Endoscopic therapies include adrenalin or alcohol injection, thermal coagulation, band ligation, tissue adhesives and mechanical clamping[3,4]. Similarly, diagnosis of polyposis and polypectomy can be made as successive procedures[3,6].

ERCP has been widely accepted as both a diagnostic and therapeutic tool for extrahepatic biliary and pancreatic diseases. The most common indication for ERCP, especially for its use as a treatment procedure in children, is biliary obstruction[29,30]. Complication rates of ERCP have been reported to be between 3.4% and 28.5%. The most common complications associated with ERCP are pancreatitis, hemorrhage, infection and perforation[30,31]. In joint diagnostic and therapeutic procedures such as ERCP, interventions to stop bleeding are usually performed by pediatric gastroenterologists. These procedures are not common in pediatric surgical practice.

THERAPEUTIC UGI ENDOSCOPY

Foreign body ingestion

Foreign body ingestions are usually encountered in small children under 5 years of age or older children. The elder children are usually with mental retardation. Most (98%) cases are reported as accidental events[32,33]. Coins are the most commonly ingested foreign body, which occurs in approximately 70% of cases[34]. However, toys, jewelry, magnets, and batteries are other commonly ingested foreign bodies[32]. Patients are asymptomatic 50% of the time; drooling, pain, refusal to feed, dysphagia, stridor, wheezing, and respiratory distress are the most common symptoms in the remaining 50% of patients[32,35,36]. Plain radiography is still the most used diagnostic modality. Barium meal study or computed tomography are indicated especially in cases of ingestion of a non-contrast object or for patients with complications[33,37]. The location of impaction usually relates to the age of the child and the size and shape of the foreign body. The esophagus, especially the upper esophageal sphincter, is the most common anatomical site for impaction of foreign bodies. The second and third most frequent anatomical sites of impaction are at the level of T4 where the distal aortic arch descends posterior to the esophagus, and the lower esophageal sphincter, respectively. Although 80%-90% of foreign bodies pass through the gastrointestinal system spontaneously, 10% or 20% of the remaining cases require endoscopic extraction. Only 1% of patients need surgery[37]. Foreign bodies detected in the stomach and intestines often tend to pass spontaneously[34]. The complication rates increase with pointed and sharp foreign bodies, button batteries, and magnets. Esophageal perforation has been detected in 2%-15% of patients with an esophageal foreign body in different studies[34]. Serious complications such as mucosal erosion, ulcer, esophageal or intestinal perforation, pneumothorax, pneumomediastinum, tracheoesophageal fistula and cervical abscess may be developed secondary to foreign body ingestion[36]. Removal of foreign bodies which are located in the esophagus is mandatory to prevent complications.

Button batteries, in particular, may lead to perforation secondary to the caustic injury or pressure effect. As a result, esophageal button batteries should be removed immediately. Ingestion of multiple magnets is another special condition, because if multiple magnets are ingested at different times, they may cling and cause intestinal perforation, peritonitis or enteroenteric fistula. For this reason, magnets should be removed as soon as they are identified[32].

The removal of the foreign bodies by endoscopy must be performed under general anesthesia with intubation to provide respiratory security. The method differs according to the shape and location of the foreign body. Use of McGill forceps is an easy procedure for foreign bodies located above the cricopharyngeal sphincter. Below this anatomical level, rigid or flexible endoscopy is required to remove foreign body impactions.

PEG

Several gastrostomy or enterostomy techniques have been described to establish long-term enteral feeding in children and adults. Stamm gastrostomy was the first surgical technique introduced for enteral nutrition. Laparoscopic gastrostomy is another method for insertion of a gastrostomy tube. Because it is less invasive and more cost-effective than surgical procedures, PEG has increasingly been used since it was described by Gauderer *et al*[38-41]. PEG is the most preferred technique especially for patients with neurological diseases[38]. However, Baker *et al*[40] revealed that there is increased risk of major complications of PEG compared to the laparoscopic gastrostomy[40]. The rate of complications

Table 3 Typical indications of percutaneous endoscopic gastrostomy

Inability to swallow
Neurological impairment
Multiple congenital malformation
Oropharyngeal dysmotility
Epidermolysis bullosa
Inadequate calorie intake
Cystic fibrosis
Congenital cardiac disease
Chronic respiratory failure
Special feeding requirements
Continuous enteral feeding
Oncologic disease
Genetic syndromes

can be reduced by an experienced endoscopist. Indications of PEG are summarized in Table 3[38,39].

Operative technique: The most preferred technique is the "pull" technique described by Gauderer[39,41]. Flexible endoscopy is performed using an appropriately sized endoscope. The stomach is insufflated. The optimal location for placement of the PEG is confirmed by both transillumination and finger indentation. A small incision less than 0.5 cm is made, then the stomach is cannulated with a needle or cannula. A thread is passed into the stomach through the cannula, grasped with a snare and pulled out of the mouth with a flexible endoscope. The PEG tube is connected to the thread and pulled from the mouth antegrade into the stomach. The bumper of the PEG tube is lubricated and manipulated to prevent esophageal damage. Finally, the position of the flange is confirmed by control endoscopy[38,39].

Replacement of PEG tube: Replacement of old, damaged or plugged PEG tubes is also performed by endoscopy. The bumper of the PEG catheter is removed endoscopically. A thread is passed into the stomach through the existing gastrostomy tunnel. Subsequent steps are identical to the initial insertion of the PEG tube.

Esophageal and pyloric dilation

UGI strictures are usually located at the esophageal level in children. Pyloric obstruction is encountered in fewer patients. The most common cause of benign esophageal stricture is ingestion of a caustic substance[42,43]. Esophageal strictures in children may be caused by congenital anomaly, foreign body ingestion, or be secondary to gastroesophageal reflux or esophageal surgery. However, of several possible surgical procedures, dilation with bougienage or balloon is the first choice of treatment for benign esophageal strictures in children[44,45]. Endoscopically or fluoroscopically guided bougienage or balloon dilation is recommended as a safe and effective treatment in children with benign esophageal stricture to reduce complication rates[44].

Pyloric stricture (PS) may be caused by peptic ulcer, granulomatous diseases and eosinophilic gastroenteritis, and caustic injury or unknown causes in children[46-48]. Diagnosis of PS is based on barium swallow. Endoscopic examination and biopsy of the UGI system should be performed to investigate the etiology of PS. Surgical correction is still the most common treatment in the majority of cases of PS[42]. However, there are some studies on endoscopic balloon dilation performed in children with PS. In these reports, success rates for balloon dilation have been reported between 16% and 80% with benign PS[49,50].

Technique: Endoscopy is performed under general anesthesia with tracheal intubation. After focusing on the narrowed esophagus or pylorus, a radiopaque guide wire is inserted under endoscopic guidance. A balloon catheter is passed over the guide wire and placed through the narrowed esophagus and pylorus. The location of the balloon is monitored endoscopically in pyloric dilation. Then the balloon is inflated with radiocontrast solution under fluoroscopy to the recommended level of pressure marked on each catheter. Inflation is performed for two minutes after expansion of the hourglass deformity of the stricture[42].

The balloon size is increased to the appropriate diameter as determined by the thumb rule for esophageal stricture. For PS, the preferred diameter of the balloon is 12-14 mm for infants and 15-18 mm for older children[42].

Miscellaneous procedures

In addition to the widespread use of endoscopy in diagnostic and therapeutic procedures, several reports presented as case reports or with limited patients include new therapeutic approaches for UGI diseases that are gradually increasing in popularity. Endoscopic treatments of duodenal duplication and duodenal web have recently been reported[51,52]. POEM has been described for achalasia in adults; clinical results of its use in children have been presented with small numbers of patients[53,54].

CONTRAINDICATIONS

Although endoscopy can be performed on children of any age from the first day of life to adolescents, it is contraindicated in patients with unstable airways, cardiovascular collapse, intestinal perforation or peritonitis[5]. Intestinal obstruction, neutropenia, severe thrombocytopenia, coagulopathy, recent gastrointestinal surgery, unstable cardiopulmonary diseases, and recent oral intake are accepted as relative contraindications[4,5].

ANTIBIOTIC PROPHYLAXIS

Antibiotic prophylaxis is not recommended for diagnostic endoscopy except for specific conditions, including congenital cardiac anomalies, cardiac surgery, neutropenia or ventriculoperitoneal shunt. However,

Table 4 Common complications of percutaneous endoscopic gastrostomy

Failure of replacement
Wound infection
Local erythema
Celulitis
Sepsis
Gastrointestinal bleeding
Gastric ulcer
Stomal leakage
Death
Gatrocolic fistula
Transient ileus
Gastroesophageal reflux
Peritonitis
Granulation tissue
Catheter migration
Hepatic injury
Aortogastric fistula
Subcutaneous emphysema

prophylactic antibiotic administration is suggested before diagnostic endoscopy with those clinical conditions and for all therapeutic endoscopic interventions such as insertion of PEG, endoscopic dilation, sclerotherapy, band ligation, and ERCP[5]. Ampicillin with sulbactam is the most commonly used antibiotic for this aim.

ANESTHESIA

Sedation with analgesia or general anesthesia is the accepted approach for endoscopy as for other interventional procedures in children. Sedation and general anesthesia facilitate endoscopic procedures and decrease the emotional stresses from separation from parents, analgesia and amnesia[4-9]. Detailed examination is recommended to choose an appropriate anesthetic modality and to reduce complications. The preferred anesthetic method and drugs should be decided by the endoscopist and anesthesiologist together[4,8]. Moderate sedation is the most preferred sedation regimen for endoscopy in children. Infants under seven months old are at higher risk because of obligatory nasal breathing; however, it has been reported that endoscopy is safe and uncomplicated with a trained practitioner even in neonates[1]. Under moderate sedation protective airway reflexes and spontaneous breathing remain active during endoscopy[5,9]. Midazolam, fentanyl, propofol and ketamine are the most commonly used anesthetic agents during endoscopy. The cardiovascular and respiratory systems of all patients should be monitored by electrocardiography and oxygen saturation. Endoscopy, especially in therapeutic interventions, should be performed under general anesthesia with endotracheal intubation in patients with poor general condition, severe respiratory disease or complex planned procedures.

COMPLICATIONS

UGI endoscopy and co-procedures are generally accepted as safe interventions in experienced hands. The complication rates reported are usually less than 2%-3% and decrease with age[55,56]. There are several complications associated with endoscopy or related procedures in the literature. Most are minor[55]. Complications are considered in two main groups. The first group is associated with anesthesia, such as delayed extubation, bronchospasm, and fever. Lee *et al*[13] reported minor complications in 1.5% of patients. The second group are complications associated with endoscopy and related procedures.

Complications after diagnostic endoscopy and endoscopic biopsy

UGI hemorrhage and duodenal hematoma may occur secondary to the endoscopy[13,57-59]. Lee *et al*[13] observed secondary bleeding following rubber banding or sclerotherapy in 3.4% of patients. Iqbal *et al*[60] reported bleeding, perforation and mucosal tears as iatrogenic complications in 6 of 9308 UGI endoscopy procedures (0.06%). A conservative approach is usually sufficient for improvement in patients without peritonitis[60].

Complications of PEG

Complications due to PEG insertion or tube are divided into major and minor complications, summarized in Table 4[38,39,61-65]. Hepatic injury secondary to the PEG placement was reported in one adult. Peristomal wound infection accounts for 30% of complications[64,66]. The risk of wound infection increases in patients with obesity, diabetes mellitus or malnutrition. Prophylactic antibiotic administration significantly reduces the risk of peristomal wound infection[64,66].

CONCLUSION

With an experienced practitioner, endoscopy is a safe and effective diagnostic and therapeutic procedure even for premature infants. Complications can easily be prevented.

REFERENCES

1 **Dupont C**, Kalach N, de Boissieu D, Barbet JP, Benhamou PH. Digestive endoscopy in neonates. *J Pediatr Gastroenterol Nutr* 2005; **40**: 406-420 [PMID: 15795585]

2 **Volonaki E**, Sebire NJ, Borrelli O, Lindley KJ, Elawad M, Thapar N, Shah N. Gastrointestinal endoscopy and mucosal biopsy in the first year of life: indications and outcome. *J Pediatr Gastroenterol Nutr* 2012; **55**: 62-65 [PMID: 22210413 DOI: 10.1097/MPG.0b013e3182478f83]

3 **Rahman I**, Patel P, Boger P, Rasheed S, Thomson M, Afzal NA. Therapeutic upper gastrointestinal tract endoscopy in Paediatric Gastroenterology. *World J Gastrointest Endosc* 2015; **7**: 169-182 [PMID: 25789087 DOI: 10.4253/wjge.v7.i3.169]

4 **Lightdale JR**, Acosta R, Shergill AK, Chandrasekhara V, Chathadi K, Early D, Evans JA, Fanelli RD, Fisher DA, Fonkalsrud L, Hwang JH, Kashab M, Muthusamy VR, Pasha S, Saltzman JR, Cash BD. Modifications in endoscopic practice for pediatric patients. *Gastrointest Endosc* 2014; **79**: 699-710 [PMID: 24593951 DOI: 10.1016/j.gie.2013.08.014]

5 **Friedt M**, Welsch S. An update on pediatric endoscopy. *Eur J*

Med Res 2013; **18**: 24 [PMID: 23885793 DOI: 10.1186/2047-783X-18-24]

6 **Lee KK**, Anderson MA, Baron TH, Banerjee S, Cash BD, Dominitz JA, Gan SI, Harrison ME, Ikenberry SO, Jagannath SB, Lichtenstein D, Shen B, Fanelli RD, Van Guilder T. Modifications in endoscopic practice for pediatric patients. *Gastrointest Endosc* 2008; **67**: 1-9 [PMID: 18155419]

7 **Chen PH**, Wu TC, Chiu CY. Pediatric gastrointestinal endoscopic sedation: a 2010 nationwide survey in Taiwan. *Pediatr Neonatol* 2012; **53**: 188-192 [PMID: 22770108 DOI: 10.1016/j.pedneo.2012.04.006]

8 **Bartkowska-Śniatkowska A**, Rosada-Kurasińska J, Zielińska M, Grześkowiak M, Bienert A, Jenkins IA, Ignyś I. Procedural sedation and analgesia for gastrointestinal endoscopy in infants and children: how, with what, and by whom? *Anaesthesiol Intensive Ther* 2014; **46**: 109-115 [PMID: 24858971 DOI: 10.5603/AIT.2014.0021]

9 **Dar AQ**, Shah ZA. Anesthesia and sedation in pediatric gastrointestinal endoscopic procedures: A review. *World J Gastrointest Endosc* 2010; **2**: 257-262 [PMID: 21160616 DOI: 10.4253/wjge.v2.i7.257]

10 **Alabd Alrazzak B**, Husien T, Preston DL, Elitsur Y. Upper endoscopy in children: do symptoms predict positive findings? *Clin Pediatr* (Phila) 2014; **53**: 474-478 [PMID: 24707023 DOI: 10.1177/0009922814528034]

11 **Guariso G**, Meneghel A, Dalla Pozza LV, Romano C, Dall'Oglio L, Lombardi G, Conte S, Calacoci M, Campanozzi A, Nichetti C, Piovan S, Zancan L, Facchin P. Indications to upper gastrointestinal endoscopy in children with dyspepsia. *J Pediatr Gastroenterol Nutr* 2010; **50**: 493-499 [PMID: 20639706 DOI: 10.1097/MPG.0b013e3181bb3362]

12 **Gilger MA**. Upper gastrointestinal bleeding. In: Walker WA, Goulet O, Kleinman RE, Sherman PM, Shneider BL, Sanderson IA, editors. Pediatric Gastrointestinal Disease, 4th ed. BC Decker Inc., 2004: 259-265

13 **Lee WS**, Zainuddin H, Boey CC, Chai PF. Appropriateness, endoscopic findings and contributive yield of pediatric gastrointestinal endoscopy. *World J Gastroenterol* 2013; **19**: 9077-9083 [PMID: 24379634 DOI: 10.3748/wjg.v19.i47.9077]

14 **Rafeey M**, Shoaran M, Majidy H. Diagnostic endoscopy and clinical characteristics of gastrointestinal bleeding in children: a 10-year retrospective study. *Iran Red Crescent Med J* 2013; **15**: 794-797 [PMID: 24616788 DOI: 10.5812/ircmj.7075]

15 **Mittal SK**, Kalra KK, Aggarwal V. Diagnostic upper GI endoscopy for hemetemesis in children: experience from a pediatric gastroenterology centre in north India. *Indian J Pediatr* 1994; **61**: 651-654 [PMID: 7721369]

16 **Septer S**, Cuffari C, Attard TM. Esophageal polyps in pediatric patients undergoing routine diagnostic upper gastrointestinal endoscopy: a multicenter study. *Dis Esophagus* 2014; **27**: 24-29 [PMID: 23551692 DOI: 10.1111/dote.12066]

17 **Isaacs KL**. Upper gastrointestinal tract endoscopy in inflammatory bowel disease. *Gastrointest Endosc Clin N Am* 2002; **12**: 451-462, vii [PMID: 12486938]

18 **Bhargava DK**, Arora A, Chopra P. Endoscopic polypectomies in upper gastrointestinal tract. *Indian J Gastroenterol* 1990; **9**: 41-42 [PMID: 2307500]

19 **Goenka AS**, Dasilva MS, Cleghorn GJ, Patrick MK, Shepherd RW. Therapeutic upper gastrointestinal endoscopy in children: an audit of 443 procedures and literature review. *J Gastroenterol Hepatol* 1993; **8**: 44-51 [PMID: 8439662]

20 **Arora NK**, Ganguly S, Mathur P, Ahuja A, Patwari A. Upper gastrointestinal bleeding: etiology and management. *Indian J Pediatr* 2002; **69**: 155-168 [PMID: 11929033]

21 **Karim B**. Upper gastrointestinal endoscopy in children - an experience at a paediatric gastroenterology unit. *Mymensingh Med J* 2003; **12**: 124-127 [PMID: 12894047]

22 **Lightdale JR**, Gremse DA. Gastroesophageal reflux: management guidance for the pediatrician. *Pediatrics* 2013; **131**: e1684-e1695 [PMID: 23629618 DOI: 10.1542/peds.2013-0421]

23 **El Mouzan MI**, Abdullah AM. The diagnosis of gastroesophageal reflux disease in children. *Saudi Med J* 2002; **23**: 164-167 [PMID: 11938391]

24 **de Jong AL**, Macdonald R, Ein S, Forte V, Turner A. Corrosive esophagitis in children: a 30-year review. *Int J Pediatr Otorhinolaryngol* 2001; **57**: 203-211 [PMID: 11223452]

25 **Kay M**, Wyllie R. Caustic ingestions and the role of endoscopy. *J Pediatr Gastroenterol Nutr* 2001; **32**: 8-10 [PMID: 11176317]

26 **Gupta SK**, Croffie JM, Fitzgerald JF. Is esophagogastroduodenoscopy necessary in all caustic ingestions? *J Pediatr Gastroenterol Nutr* 2001; **32**: 50-53 [PMID: 11176325]

27 **Thompson JN**. Corrosive esophageal injuries. I. A study of nine cases of concurrent accidental caustic ingestion. *Laryngoscope* 1987; **97**: 1060-1068 [PMID: 3306232]

28 **Temiz A**, Oguzkurt P, Ezer SS, Ince E, Hicsonmez A. Predictability of outcome of caustic ingestion by esophagogastroduodenoscopy in children. *World J Gastroenterol* 2012; **18**: 1098-1103 [PMID: 22416185 DOI: 10.3748/wjg.v18.i10.1098]

29 **Oracz G**, Pertkiewicz J, Kierkus J, Dadalski M, Socha J, Ryzko J. Efficiency of pancreatic duct stenting therapy in children with chronic pancreatitis. *Gastrointest Endosc* 2014; **80**: 1022-1029 [PMID: 24852105 DOI: 10.1016/j.gie.2014.04.001]

30 **Kieling CO**, Hallal C, Spessato CO, Ribeiro LM, Breyer H, Goldani HA, Maguilnik I. Changing pattern of indications of endoscopic retrograde cholangiopancreatography in children and adolescents: a twelve-year experience. *World J Pediatr* 2015; **11**: 154-159 [PMID: 25410666 DOI: 10.1007/s12519-014-0518-5]

31 **Hatlani MA**, Kortan P, May G, Ling SC, Walters T, Avitzur Y. Wire-guided cannulation versus contrast-guided cannulation in pediatric endoscopic retrograde cholangiopancreatography. *Saudi J Gastroenterol* 2015; **21**: 25-29 [PMID: 25672235 DOI: 10.4103/1319-3767.151219]

32 **Kramer RE**, Lerner DG, Lin T, Manfredi M, Shah M, Stephen TC, Gibbons TE, Pall H, Sahn B, McOmber M, Zacur G, Friedlander J, Quiros AJ, Fishman DS, Mamula P. Management of ingested foreign bodies in children: a clinical report of the NASPGHAN Endoscopy Committee. *J Pediatr Gastroenterol Nutr* 2015; **60**: 562-574 [PMID: 25611037 DOI: 10.1097/MPG.0000000000000729]

33 **Pinto A**, Lanza C, Pinto F, Grassi R, Romano L, Brunese L, Giovagnoni A. Role of plain radiography in the assessment of ingested foreign bodies in the pediatric patients. *Semin Ultrasound CT MR* 2015; **36**: 21-27 [PMID: 25639174 DOI: 10.1053/j.sult.2014.10.008]

34 **Peters NJ**, Mahajan JK, Bawa M, Chabbra A, Garg R, Rao KL. Esophageal perforations due to foreign body impaction in children. *J Pediatr Surg* 2015; **50**: 1260-1263 [PMID: 25783392 DOI: 10.1016/j.jpedsurg.2015.01.015]

35 **Alam E**, Mourad M, Akel S, Hadi U. A case of battery ingestion in a pediatric patient: what is its importance? *Case Rep Pediatr* 2015; **2015**: 345050 [PMID: 25692063 DOI: 10.1155/2015/345050]

36 **Costa L**, Larangeiro J, Pinto Moura C, Santos M. Foreign body ingestion: rare cause of cervical abscess. *Acta Med Port* 2014; **27**: 743-748 [PMID: 25641290]

37 **Pinto A**, Muzj C, Gagliardi N, Pinto F, Setola FR, Scaglione M, Romano L. Role of imaging in the assessment of impacted foreign bodies in the hypopharynx and cervical esophagus. *Semin Ultrasound CT MR* 2012; **33**: 463-470 [PMID: 22964412 DOI: 10.1053/j.sult.2012.06.009]

38 **Pattamanuch N**, Novak I, Loizides A, Montalvo A, Thompson J, Rivas Y, Pan D. Single-center experience with 1-step low-profile percutaneous endoscopic gastrostomy in children. *J Pediatr Gastroenterol Nutr* 2014; **58**: 616-620 [PMID: 24378575 DOI: 10.1097/MPG.0000000000000291]

39 **Khattak IU**, Kimber C, Kiely EM, Spitz L. Percutaneous endoscopic gastrostomy in paediatric practice: complications and outcome. *J Pediatr Surg* 1998; **33**: 67-72 [PMID: 9473103]

40 **Baker L**, Beres AL, Baird R. A systematic review and meta-analysis of gastrostomy insertion techniques in children. *J Pediatr Surg* 2015; **50**: 718-725 [PMID: 25783383 DOI: 10.1016/j.jpedsurg.2015.02.021]

41 **Gauderer MW**, Ponsky JL, Izant RJ. Gastrostomy without

laparotomy: a percutaneous endoscopic technique. *J Pediatr Surg* 1980; **15**: 872-875 [PMID: 6780678]

42 **Temiz A**, Oguzkurt P, Ezer SS, Ince E, Gezer HO, Hicsonmez A. Management of pyloric stricture in children: endoscopic balloon dilatation and surgery. *Surg Endosc* 2012; **26**: 1903-1908 [PMID: 22234589 DOI: 10.1007/s00464-011-2124-0]

43 **Kukkady A**, Pease PW. Long-term dilatation of caustic strictures of the oesophagus. *Pediatr Surg Int* 2002; **18**: 486-490 [PMID: 12415387]

44 **Temiz A**, Oguzkurt P, Ezer SS, Ince E, Hicsonmez A. Long-term management of corrosive esophageal stricture with balloon dilation in children. *Surg Endosc* 2010; **24**: 2287-2292 [PMID: 20177917 DOI: 10.1007/s00464-010-0953-x]

45 **Lan LC**, Wong KK, Lin SC, Sprigg A, Clarke S, Johnson PR, Tam PK. Endoscopic balloon dilatation of esophageal strictures in infants and children: 17 years' experience and a literature review. *J Pediatr Surg* 2003; **38**: 1712-1715 [PMID: 14666449]

46 **Tekant G**, Eroğlu E, Erdoğan E, Yeşildağ E, Emir H, Büyükünal C, Yeker D. Corrosive injury-induced gastric outlet obstruction: a changing spectrum of agents and treatment. *J Pediatr Surg* 2001; **36**: 1004-1007 [PMID: 11431765]

47 **Treem WR**, Long WR, Friedman D, Watkins JB. Successful management of an acquired gastric outlet obstruction with endoscopy guided balloon dilatation. *J Pediatr Gastroenterol Nutr* 1987; **6**: 992-996 [PMID: 3681588]

48 **Sharma KK**, Ranka P, Goyal P, Dabi DR. Gastric outlet obstruction in children: an overview with report of Jodhpur disease and Sharma's classification. *J Pediatr Surg* 2008; **43**: 1891-1897 [PMID: 18926227 DOI: 10.1016/j.jpedsurg.2008.07.001]

49 **DiSario JA**, Fennerty MB, Tietze CC, Hutson WR, Burt RW. Endoscopic balloon dilation for ulcer-induced gastric outlet obstruction. *Am J Gastroenterol* 1994; **89**: 868-871 [PMID: 8198096]

50 **Kuwada SK**, Alexander GL. Long-term outcome of endoscopic dilation of nonmalignant pyloric stenosis. *Gastrointest Endosc* 1995; **41**: 15-17 [PMID: 7698619]

51 **Meier AH**, Mellinger JD. Endoscopic management of a duodenal duplication cyst. *J Pediatr Surg* 2012; **47**: e33-e35 [PMID: 23164028 DOI: 10.1016/j.jpedsurg.2012.07.035]

52 **DiMaio CJ**, Kamal N, Hogan CM, Midulla PS. Pediatric therapeutic endoscopy: endoscopic management of a congenital duodenal web. *Gastrointest Endosc* 2014; **80**: 166-167 [PMID: 24785127 DOI: 10.1016/j.gie.2014.03.006]

53 **Phalanusitthepha C**, Inoue H, Ikeda H, Sato H, Sato C, Hokierti C. Peroral endoscopic myotomy for esophageal achalasia. *Ann Transl Med* 2014; **2**: 31 [PMID: 25333007 DOI: 10.3978/j.issn.2305-5839.2014.02.04]

54 **Orenstein SB**, Raigani S, Wu YV, Pauli EM, Phillips MS, Ponsky JL, Marks JM. Peroral endoscopic myotomy (POEM) leads to similar results in patients with and without prior endoscopic or surgical therapy. *Surg Endosc* 2015; **29**: 1064-1070 [PMID: 25249143 DOI: 10.1007/s00464-014-3782-5]

55 **Ament ME**, Berquist WE, Vargas J, Perisic V. Fiberoptic upper intestinal endoscopy in infants and children. *Pediatr Clin North Am* 1988; **35**: 141-155 [PMID: 3277129]

56 **Thakkar K**, El-Serag HB, Mattek N, Gilger MA. Complications of pediatric EGD: a 4-year experience in PEDS-CORI. *Gastrointest Endosc* 2007; **65**: 213-221 [PMID: 17258979]

57 **Dumitriu D**, Menten R, Smets F, Clapuyt P. Postendoscopic duodenal hematoma in children: ultrasound diagnosis and follow-up. *J Clin Ultrasound* 2014; **42**: 550-553 [PMID: 24615821 DOI: 10.1002/jcu.22145]

58 **Borsaru AD**, Nandurkar D. Intramural duodenal haematoma presenting as a complication after endoscopic biopsy. *Australas Radiol* 2007; **51**: 378-380 [PMID: 17635478]

59 **Diniz-Santos DR**, de Andrade Cairo RC, Braga H, Araújo-Neto C, Paes IB, Silva LR. Duodenal hematoma following endoscopic duodenal biopsy: a case report and review of the existing literature. *Can J Gastroenterol* 2006; **20**: 39-42 [PMID: 16432559]

60 **Iqbal CW**, Askegard-Giesmann JR, Pham TH, Ishitani MB, Moir CR. Pediatric endoscopic injuries: incidence, management, and outcomes. *J Pediatr Surg* 2008; **43**: 911-915 [PMID: 18485965 DOI: 10.1016/j.jpedsurg.2007.12.036]

61 **Lalanne A**, Gottrand F, Salleron J, Puybasset-Jonquez AL, Guimber D, Turck D, Michaud L. Long-term outcome of children receiving percutaneous endoscopic gastrostomy feeding. *J Pediatr Gastroenterol Nutr* 2014; **59**: 172-176 [PMID: 24709828 DOI: 10.1097/MPG.0000000000000393]

62 **Huang SY**, Levine MS, Raper SE. Gastrocolic fistula with migration of feeding tube into transverse colon as a complication of percutaneous endoscopic gastrostomy. *AJR Am J Roentgenol* 2005; **184**: S65-S66 [PMID: 15728025]

63 **Johnston SD**, Tham TC, Mason M. Death after PEG: results of the National Confidential Enquiry into Patient Outcome and Death. *Gastrointest Endosc* 2008; **68**: 223-227 [PMID: 18329030 DOI: 10.1016/j.gie.2007.10.019]

64 **McClave SA**, Chang WK. Complications of enteral access. *Gastrointest Endosc* 2003; **58**: 739-751 [PMID: 14595312]

65 **Lee JH**, Kim JJ, Kim YH, Jang JK, Son HJ, Peck KR, Rhee PL, Paik SW, Rhee JC, Choi KW. Increased risk of peristomal wound infection after percutaneous endoscopic gastrostomy in patients with diabetes mellitus. *Dig Liver Dis* 2002; **34**: 857-861 [PMID: 12643294]

66 **Gubler C**, Wildi SM, Bauerfeind P. Liver injury during PEG tube placement: report of two cases. *Gastrointest Endosc* 2005; **61**: 346-348 [PMID: 15729264]

P- Reviewer: Gupta DK, Gow KW, Lee HC, Muensterer OHJ, Sangkhathat S
S- Editor: Ji FF **L- Editor**: Wang TQ **E- Editor**: Jiao XK

World Journal of Clinical Pediatrics

Submit a Manuscript: http://www.wjgnet.com/esps/
Help Desk: http://www.wjgnet.com/esps/helpdesk.aspx
DOI: 10.5409/wjcp.v4.i4.120

World J Clin Pediatr 2015 November 8; 4(4): 120-125
ISSN 2219-2808 (online)
© 2015 Baishideng Publishing Group Inc. All rights reserved.

MINIREVIEWS

Hirschsprung's disease: Historical notes and pathological diagnosis on the occasion of the 100th anniversary of Dr. Harald Hirschsprung's death

Consolato Sergi

Consolato Sergi, Department of Pediatrics, Stollery Children's Hospital, Alberta T6G 2B7, Canada

Consolato Sergi, Department of Lab Medicine and Pathology, University of Alberta Hospital, Edmonton, Alberta T6G 2B7, Canada

Author contributions: Sergi C designed research, performed literature research, contributed to the analytic tools, analyzed data, and wrote the paper.

Conflict-of-interest statement: Dr. Sergi C is a "ad hoc" consultant of the World Health Organization (WHO)/International Agency for Research on Cancer (IARC) sitting in the panel as collaborator for the use of pesticides and cancer (IARC Monographs Volume 112: evaluation of five organophosphate insecticides and herbicides) and Carcinogenicity of perfluorooctanoic acid, tetrafluoroethylene, dichloromethane, 1,2-dichloropropane, and 1,3-propane sultone. Moreover, Dr. Sergi C. has received research funding from the Women and Children Research Institute, Saudi Cultural Bureau, and the Canada Foundation for Women's Health (CFWH) (Award 2009: CFWH General Research Grant Dr. L. Hornberger and Dr. C. Sergi), and has received fees for serving as grant reviewer for the Health and Medical Research Fund (HMRF), Hong Kong Special Administrative Region, and as consultant for Guidepoint.

Open-Access: This article is an open-access article which was selected by an in-house editor and fully peer-reviewed by external reviewers. It is distributed in accordance with the Creative Commons Attribution Non Commercial (CC BY-NC 4.0) license, which permits others to distribute, remix, adapt, build upon this work non-commercially, and license their derivative works on different terms, provided the original work is properly cited and the use is non-commercial. See: http://creativecommons.org/licenses/by-nc/4.0/

Correspondence to: Consolato Sergi, MD, MSc, FRCPC, PhD, Professor, Department of Lab Medicine and Pathology, University of Alberta Hospital, Edmonton, 8440 112 St, Alberta T6G 2B7, Canada. sergi@ualberta.ca
Telephone: +1-780-4077951
Fax: +1-780-4073009

Received: May 7, 2015
Peer-review started: May 8, 2015
First decision: June 9, 2015
Revised: August 21, 2015
Accepted: September 10, 2015
Article in press: September 16, 2015
Published online: November 8, 2015

Abstract

Hirschsprung's disease (HSCR) or congenital megacolon is one of the differential diagnoses of chronic constipation mostly in infancy and may indeed represent a challenge for pediatricians, pediatric surgeons, and pediatric pathologists. The diagnosis relies clearly on the identification of the absence of ganglion cells at the plexuses (submucosus and myentericus) of the bowel wall. HSCR is usually located at the terminal (distal) rectum with potential pre-terminal or proximal extension to the less distal large bowel (sigmoid colon). Astonishingly, there is some evidence that Hindu surgeons of prehistoric India may have been exposed and had considerable knowledge about HSCR, but this disease is notoriously and eponymously named to Dr. Harald Hirschsprung (1830-1916), who brilliantly presented two infants with fatal constipation at the Berlin conference of the German Society of Pediatrics more than one century ago. Historical milestones and diagnosis of HSCR (originally called "Die Hirschsprungsche Krankheit") are reviewed. More than 100 years following his meticulous and broad description, HSCR is still a puzzling disease for both diagnosis and treatment. HSCR remains a critical area of clinical pediatrics and pediatric surgery and an intense area of investigation for both molecular and developmental biologists.

Key words: Constipation; Analysis; Rectum; Medicine; Biopsy; History

© **The Author(s) 2015.** Published by Baishideng Publishing Group Inc. All rights reserved.

Core tip: Medical history is fascinating and, since its beginning, it was meant to enlighten scientific issues, booster the medical profession, and celebrate the traditions or tales of particular places. Harald Hirschsprung, who presented two infants with fatal constipation at the German Society of Pediatrics more than one century ago, is known in medicine for his eponym of intestinal aganglionosis. Events running before and after Dr. Hirschsprung's discovery may drive interest in medical students and doctors to review the diagnostic procedures of this intriguing disease and recognize the enormous input given from microscopy and pathology to this diagnosis.

Sergi C. Hirschsprung's disease: Historical notes and pathological diagnosis on the occasion of the 100th anniversary of Dr. Harald Hirschsprung's death. *World J Clin Pediatr* 2015; 4(4): 120-125 Available from: URL: http://www.wjgnet.com/2219-2808/full/v4/i4/120.htm DOI: http://dx.doi.org/10.5409/wjcp.v4.i4.120

HIRSCHSPRUNG'S ANNIVERSARY

In 2016, a particular and noteworthy anniversary recurs that will probably have enormous impact to clinical pediatrics, pediatric surgery, and pediatric pathology. Dr. Harald Hirschsprung (1830-1916), a Danish pediatrician, first described Hirschsprung's disease or congenital megacolon about one and half century ago. He is notoriously acknowledged as the writer of the first description of two children who died of intestinal obstruction called "congenital megacolon", which is now known as Hirschsprung's disease (HSCR)[1]. Dr. Hirschsprung was working as pediatrician at Queen Louise Children's Hospital in Copenhagen, Denmark, when he came across this disease. He brilliantly reported two children in 1886 in occasion of the Berlin Conference of the German Society of Pediatrics.

WHEN THE SAGA BEGAN

Dr. Hirschsprung, who graduated with a degree in medicine in 1855, showed since his first steps into medical career a strong interest in pediatrics, becoming astoundingly the chief physician of the only children's hospital in Copenhagen just fifteen years later. The appointment as professor of pediatrics came in 1877 and Dr. Hirschsprung became director of a larger children's hospital in Copenhagen from 1979 until 1904, when he retired. The new children's hospital was magnificently named after Denmark's Queen Louise (The Queen Louise Hospital for Children). Dr. Hirschsprung was fond of anatomical variations, peculiar aspects of medicine, and intriguing diseases. He was a brilliant teacher with loyal and faithful students. Between 1880 and 1885, Hirschsprung came across two infants with similar clinical presentation. The first child had bowel problems that persisted soon after birth with absence of spontaneous bowel movements. Daily enemas and laxatives were necessary. The second case had similar bowel distensions with terminal bouts of diarrhea variably alternating with impossibility to evacuate. Notwithstanding the scarcity of information continuous therapy was applied, but, unfortunately, both children eventually died and a postmortem examination was performed. At the autopsy, the rectum was narrowed, but there were striking dilation of the bowel loops with some ulceration of the mucosa associated with thickening of the bowel wall[2,3]. In his publication, Dr. Hirschsprung summarized his findings and drew attention to the typical clinical presentation of both cases. In an opinion, which is worldwide shared, his meticulous and comprehensive description is not the first one to indicate details of this disease, but he provided a complete and excellent account of this entity in consideration of his clinical experience and practice in pediatrics[4]. The name "Hirschsprung's disease" came into widespread use shortly before the end of the 20th century and, in 1916, Hirschsprung himself added an additional 10 more cases before his death[5-8].

DIGGING INTO THE PRE-HIRSCHSPRUNG ERA

The examination of the scientific literature seems indicate that approximately 20 similar cases have been recorded between 1825 and 1888[9]. However, there is evidence that Hindu surgeons of prehistoric India had considerable knowledge about HSCR[10]. Sushruta's description of a disease called Baddha Gudodaram is extraordinarily analogous to that of HSCR. Semantically, it seems indicate "abdominal distension due to blocked rectum". According to Sushruta, Baddha Gudodaram is a type of disease caused by (functional) blockage of the ano-rectal canal. The affected child or, even, young adult may show rectum and distal colon stuffed with gas, "stones" (fecaliths), "hair" (undigested fibers), and, obviously, feces. In the child, there is an abdominal distension, which is characteristically seen between the heart and the umbilicus. Scanty stools are evacuated with greatest difficulty, and, eventually, it was reported that the patient might vomit feculent fluid. However, the pre-Hirschsprung era is not complete, if additional reports are not also mentioned. Indeed, Fredericus Ruysch, a Dutch anatomist in Amsterdam (Netherland) in 1691 described a 5-year-old girl with abdominal pain. It seems that the usual treatment to relieve pain was permanently inefficacious and the child continued to pass flatulence. No evacuation was practically possible and the child ultimately died[11]. Remarkably, Domenico Battini, an Italian physician of the 19th century described a child that he followed up for 10 years with severe constipation. The child died and the autopsy demonstrated severe dilatation of the colon[12]. The posthumously published

Italian contribution showed not only a very careful clinical evolution of the child, but also provided a detailed autopsy with examination of the abdominal viscera. Particular mention to the morphological alterations occurred in the large bowel were present in the original Italian publication. Through the examination of the reports, Fiori concludes that Dr. Battini, nearly one century before Hirschsprung, may have originally achieved its target in reporting an archetypal case of megacolon of congenital type. Distinctively, a number of characteristic features, including familiarity and the peculiar selective involvement of "neural layers" of the bowel, that later became characteristic of HSCR, were remarkably well postulated by Dr. Domenico Battini. To increase the controversy between Denmark and Italy as well as other countries, there may be a few more reports that need to be listed. In 1836, Ebers[13] reported a 17-year-old boy with a history of constipation since birth or, perhaps, as toddler, while Jacobi[14] had also described two neonates with intestinal obstruction in 1869. Fragmentary reports of children who died of severe constipation appeared also in the literature in the pre-Hirschsprung era[15,16]. In fact, Gee[17] reported the autopsy findings of a 4-year-old child with a "spasm" of the sigmoid colon without involving of the rectum in 1884, while Bristowe[18] described the outcome of a 8-year-old girl who died of mechanic ileus after longstanding severe constipation of the bowel. Dr. Hirschsprung died on April 11, 1916, but his supreme legacy to clinical pediatrics, pediatric surgery, and pediatric pathology is unmatched with contributions that go further than severe constipation in children or the disease harboring his name ("Hirschsprungsche Krankheit"). The Danish pediatrician observed and described in detail several diseases, including pyloric stenosis and intussusception. Dr. Hirschsprung indicated guidelines for management of a broad spectrum of pediatric diseases, including contributions in the area of teratology and clinical dysmorphology[4]. These contributions are now part of the didactic activity and scientific investigation of innumerable professors and researchers of Pediatrics, Pediatric Surgery, and Pediatric Pathology of the 21st century. His legacy to children is marvelous. He participated actively to the building of the children's hospital and his dedication to children was adamant and unbending. Queen Louise wanted the wall spaces above doors to harbor biblical quotations for the edification of the sick children, but Dr. Hirschsprung considered more appropriate to give the children an environment that could bring some quietness. In consideration of the sensibility of the children, he firmly refused the holy quotations and suggested colorful and beautiful wall decorations of animals and flowers, which in the end were well accepted by the Danish crown to be inserted in the wall spaces above doors.

BEYOND THE HIRSCHSPRUNG'S DISCOVERY

Recently, the interest has focused on the diagnosis of HSCR mainly because of the jeopardy of methods used to make the diagnosis and their accuracy. Being a genetic disease quite diverse, main topics on HSCR involve, indeed, the investigation of the best diagnostic marker for HSCR and changes that may take place during ganglion cell maturation. In the setting of the diagnosis, we recently published a systematic review on HSCR trying to identify the value of single methods to ascertain currently this diagnosis[19]. HSCR is now known as the most common cause of neonatal lower intestinal obstruction occurring in 1:5000 live birth newborns. HSCR involves in about three quarters of cases male children, and its incidence is variable according to ethnics. The caudal migration of the primordial neural crest cells starts at the upper end of the gut following progressively the vagal fibers distally. A delay or arrest in this migration induces failure of the neural crest cells to reach the distal bowel with consequent congenital abnormal nerve innervation of the bowel. There is a caudo-cranial severity, which means from the internal anal sphincter extending proximally for a variable length of gut. Pathophysiologically, there is a proximal intestine, which is dilated and progresses to an abrupt or, alternatively, gradual transition to a normal calibrated distal bowel. This distal intestinal segment shows typically a funnel like or cone shaped zone in between (the so-called "transition zone"). Moreover, there is a proximal muscle hypertrophy. This anatomic and prominent feature of the colon, located proximal to the aganglionic segment, represents undoubtedly an effort to overcome the partial obstruction. The bowel becomes distended with thickening of its wall, and the degree of dilatation and hypertrophy depends intricately upon both the time and degree of obstruction and obviously, indirectly, to the age of the patient. Clinical presentation settings include failure to pass meconium within the 24-h of life considering that 98% of newborns pass meconium in less than 24-h of age, neonatal intestinal obstruction syndrome (abdominal distension, refusal to feed, and vomiting of bilious type), and recurrent enterocolitis (mainly infants less than 3 mo of life), toxic megacolon, spontaneous perforation, and chronic constipation with persistent failure to thrive. Toxic megacolon includes fever, abdominal distension, bile stained vomiting, explosive diarrhea, dehydration, and shock. History includes failure to pass meconium, painless abdominal distension, and, obviously, constipation. Physical examinations of children with HSCR includes enlarged abdominal circumference with numerous fecal masses. Digital or post-evacuation examinations reveal hypertonic anal sphincter, typical empty rectum, and hard fecal mass. Radiology (plain abdominal X-ray both erect and supine as well as contrast enema) typically shows narrow distal segment, funnel-shaped dilatation characteristically localized at level of transition zone as well as marked dilatation of the proximal colon. Moreover, a poor emptying of barium throughout the colon in 24-h delayed films is also found. A differential diagnosis of "psychogenic" stool is requested and, in

Table 1 Differential diagnosis of chronic pseudo-obstruction of the child and young adult

Organic colorectal diseases	
Pseudotumors (*e.g.*, rectocele)	
Neoplasms (both benign and malignant epithelial and mesenchymal)	
Strictures (postinflammatory, postischemic, posttransplant, *etc.*)	
	Apostinflammatory (*e.g.*, Crohn's disease)
	Postischemic (*e.g.*, necrotizing enterocolitis)
	Graft *vs* host disease
	Others
Dysmetabolism	
Severe hypothyroidism	
Calcium imbalance (hypercalcemia)	
Potassium imbalance (hypokalemia)	
Diabetes mellitus (autonomic neuropathy)	
Autonomic Enteric Neuro-Myopathies	
Scleroderma or systemic sclerosis	
Amyloidosis or familial mediterranean Fever	
Sarcoidosis	
Central nervous system - pathologies	
Cerebral palsy	
Spinal cord injury	
Demyelinizating disease in youth (*e.g.*, multiple sclerosis)	
Iatrogenic Chronic Pseudo-Obstruction (drugs-related)	
	Anticholinergics, antidepressants (especially tricyclic antidepressants), antipsychotics, calcium-channel blockers, aluminum (antacids), narcotics and narcotic-related drugs

Drugs-related chronic pseudo-obstruction may have different and multiple etiologies and accidental intoxication should also be taken into account.

this latter case, the barium generally collects in the distal recto-sigmoid colon. Electromanometry shows absence of the recto-anal inhibitory reflex (RAIR) when the rectum is distended. RAIR is defined as the reflex of relaxation of the internal anal sphincter following rectal distension (balloon). RAIR (+) means normal, while lack of RAIR, RAIR (-), means HSCR. Bedside or outpatient procedures seem to give no complications. The test is unreliable if the gestational age plus post-natal age is less than 39 wk and birth weight is less than 2.7 kg. However, if, at neonatal age, electromanometry is useless, it represents a good screening tool in infancy and childhood. Ultrasonography is important to rule out associated anomalies and a genetic counselling may be considered appropriate according to the familiarity and the phenotype of the patients affected with HSCR. Rectal biopsy is the definitive diagnostic test showing absence of ganglion cells, presence of nerve hypertrophy, and increased acetyl-cholinesterase activity. It may include either a suction mucosal biopsy (at different levels) or a full thickness biopsy. Suction, transmural, and jumbo biopsies are the usual biopsies taken in an infant with severe constipation. It is a general opinion that pediatricians play a major role in diagnosing HSCR and dysmorphic features remain important landmarks that need to be identified first by clinical pediatricians and, later discussed with clinical geneticists. Typically, HSCR is clinically identified as a solitary gastro-intestinal anomaly in a full term, otherwise healthy newborn or infant, but associated anomalies do occur in about 1/5 of cases, including uro-genital system (11%), cardio-vascular system (6%), gastro-intestinal system (6%), and other systemic congenital defects (8%). In as many as 1/10 of children with HSCR, the condition of prematurity has been reported. Trisomy 21 syndrome (Down syndrome) occurs in approximately 1/20 of children with HSCR. Astoundingly, the work of the pathologists is impressive and their criteria for diagnosing HSCR are quite straightforward and easy to follow in classic cases as indicated above. Figure 1 shows mature and immature ganglion cells of the submucosus plexus of a rectal suction biopsy performed at 2 cm above the pectinate line in a 3-mo-old infant and a newborn with severe constipation. It is important to highlight that not all-severe constipation mean automatically HSCR. Table 1 indicates a differential diagnosis of chronic pseudo-obstruction of the child and young adult. Figures 2 and 3 show the absence of ganglion cells and the hypertrophy of nerve fibers in an infant with HSCR operated with pull-through procedure. Both the lack of ganglion cells and the hypertrophy of nerve fibers are pathologic landmarks of HSCR.

CONCLUSION

Several loci seem to be involved in HSCR. Nevertheless, the molecular-biologic basis of this intriguing gastro-intestinal disorder remains yet essentially unknown. In our working group at the Stollery Children's Hospital, we consider that the study of combined properties of modules linking functionally related genes may shed light on an efficient and effective platform of transcriptomics that can target rare diseases. A "Pathway-Based Analysis" may help to confirm a strong association bet-

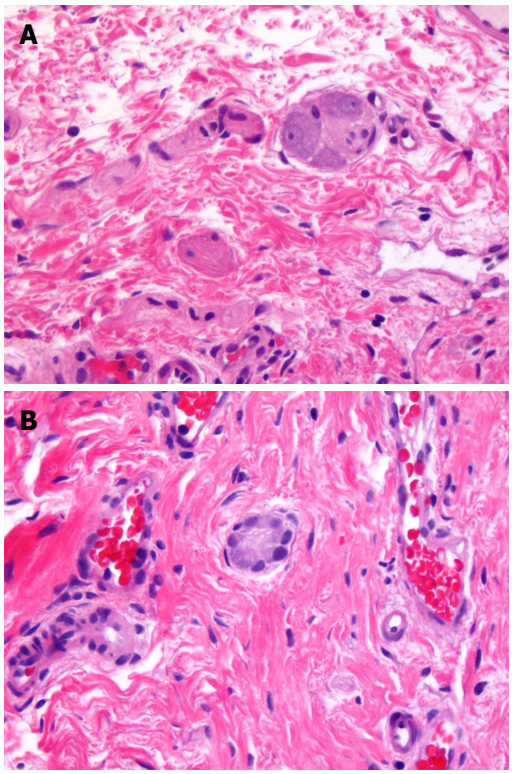

Figure 1 Mature ganglion cells (A) and immature ganglion cells (B). A: Mature ganglion cells; B: Immature ganglion cells (Hematoxylin and Eosin staining, magnification: 400 × for both photographs).

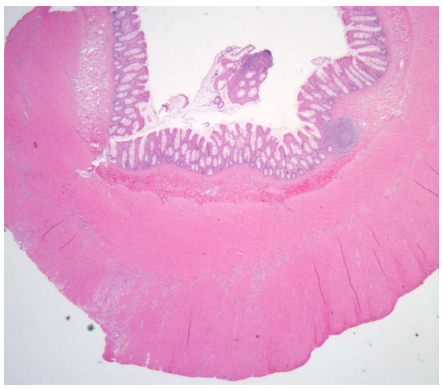

Figure 2 Hirschsprung's disease showing hypertrophy of nerve fibers.

ween genes and pathways related to signal transduction and its regulation of the enteric nervous system[20,21]. Most recently, some potential molecular markers, *e.g.,* targeting variations of *PTCH1* gene, have been reported to be useful for early diagnosis of HSCR in the Han Chinese population[22]. The *WNT8A* gene has also been involved in the susceptibility to HSCR and may play an important role in the occurrence and development of HSCR[23].

In summary, HSCR is still a disease with many unclear aspects. HSCR is due to migration failure of neural crest cells. Definitive anatomo-pathologic finding that identifies HSCR is the absence of ganglion cells in both the submucosal and myenteric plexuses. Thus,

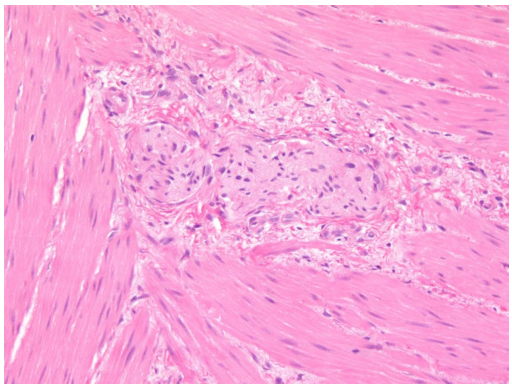

Figure 3 Hirschsprung's disease showing hypertrophy of nerve fibers and lack of ganglion cells.

rectal biopsy is definitive in most cases. In doubt, ancillary techniques may be applied, but a re-biopsy is the best choice[19]. If research is supported, signaling pathways may be identified that may play a diagnostic other than a mechanistic role. Despite genes and pathways identified in patients at the beginning of the 21st century there is still a lot to do investigating etiology, pathogenesis, and treatment modalities of this frightful disease.

ACKNOWLEDGMENTS

We are very grateful to the patients and families affected with Hirschsprung disease that allow performing research on this difficult topic. We acknowledge the contribution of pathologists (pediatric pathologists and gastrointestinal pathologists) of the Department of Laboratory Medicine and Pathology at the University of Alberta, Edmonton, Canada, who offered second opinion on surgical biopsies. Moreover, we acknowledge the contribution of pediatricians and pediatric surgeons, who gave good comments and suggestions in the diagnosis and management of Hirschsprung disease (http://lmp.med. ualberta.ca/Pages/default.aspx).

REFERENCES

1 **Skaba R**. Historic milestones of Hirschsprung's disease (commemorating the 90th anniversary of Professor Harald Hirschsprung's death). *J Pediatr Surg* 2007; **42**: 249-251 [PMID: 17208575 DOI: 10.1016/j.jpedsurg.2006.09.024]

2 **Hirschsprung H**. Constipation of newborns as a result of dilatation and hypertrophy of the colon. *Jhrb f Kinderh* 1888; **27**: 1-7

3 **Roed-Petersen K**, Erichsen G. The Danish pediatrician Harald Hirschsprung. *Surg Gynecol Obstet* 1988; **166**: 181-185 [PMID: 3276016]

4 **Jay V**. Legacy of Harald Hirschsprung. *Pediatr Dev Pathol* 2001; **4**: 203-204 [PMID: 11178638 DOI: 10.1007/s100240010144]

5 **Walker TJ**. Congenital(?) Dilatation and Hypertrophy of the Colon Fatal at the Age of 11 Years. *Br Med J* 1893; **2**: 230-231 [PMID: 20754384 DOI: 10.1136/bmj.2.1700.230]

6 **Mya G**. Two observations of congenital dilatation and hypertrophy of the colon. *Sperimentale* 1894; **48**: 215-231

7 **Genersich G**. Concerning a congenital dilatation and hypertrophy of the colon. *Jb Kinderheilk* 1894; **37**: 91-100

8 **Concetti L**. About some innate colon malformation causing habitual constipation of children. *Arch Kinderheilk* 1899; **27**: 319-353

9 **Finney MT**. Congenital idiopathic dilatation of the colon. *Surg Gynecol Obstet* 1908; **6**: 624-643

10 **Raveenthiran V**. Knowledge of ancient Hindu surgeons on Hirschsprung disease: evidence from Sushruta Samhita of circa 1200-600 BC. *J Pediatr Surg* 2011; **46**: 2204-2208 [PMID: 22075360 DOI: 10.1016/j.jpedsurg.2011.07.007]

11 **Ruysch F**. Observationum anatomico-chirurgicarum centuria. Amstelodami, 1691

12 **Fiori MG**. Domenico Battini and his description of congenital megacolon: a detailed case report one century before Hirschsprung. *J Peripher Nerv Syst* 1998; **3**: 197-206 [PMID: 10959250]

13 **Ebers G**. History of a rare case of ileus. Hufland's J 83/2:62-89, 1836

14 **Jacobi A**. On some important causes of constipation in infants. Am J Obstet 2:96, 1869

15 **Ehrenpreis TH**. Megacolon in the newborn. A clinical and roentgenological study with special regard to the pathogenesis. *Acta Chir Scand* 1946; **94** Suppl: 112

16 **Cass D**. Hirschsprung's disease: an historical review. *Prog Pediatr Surg* 1986; **20**: 199-214 [PMID: 3095874 DOI: 10.1007/978-3-642-70825-1_15]

17 **Gee SJ**. Treatment of Intestinal Obstruction. A discussion at the Liverpool Medical Institution. Lancet 3197, 1019-1020, 1884

18 **Bristowe JS**. Clinical Lecture on the Consequences of Long Continued Constipation. *Br Med J* 1885; **1**: 1085-1088 [PMID: 20751277 DOI: 10.1136/bmj.1.1274.1085]

19 **Takawira C**, D'Agostini S, Shenouda S, Persad R, Sergi C. Laboratory procedures update on Hirschsprung disease. *J Pediatr Gastroenterol Nutr* 2015; **60**: 598-605 [PMID: 25564805 DOI: 10.1097/MPG.0000000000000679]

20 **Fernández RM**, Bleda M, Luzón-Toro B, García-Alonso L, Arnold S, Sribudiani Y, Besmond C, Lantieri F, Doan B, Ceccherini I, Lyonnet S, Hofstra RM, Chakravarti A, Antiñolo G, Dopazo J, Borrego S. Pathways systematically associated to Hirschsprung's disease. *Orphanet J Rare Dis* 2013; **8**: 187 [PMID: 24289864 DOI: 10.1186/1750-1172-8-187]

21 **Saeed A**, Barreto L, Neogii SG, Loos A, McFarlane I, Aslam A. Identification of novel genes in Hirschsprung disease pathway using whole genome expression study. *J Pediatr Surg* 2012; **47**: 303-307 [PMID: 22325380 DOI: 10.1016/j.jpedsurg.2011.11.017]

22 **Wang Y**, Wang J, Pan W, Zhou Y, Xiao Y, Zhou K, Wen J, Yu T, Cai W. Common genetic variations in Patched1 (PTCH1) gene and risk of hirschsprung disease in the Han Chinese population. *PLoS One* 2013; **8**: e75407 [PMID: 24073265 DOI: 10.1371/journal.pone.0075407]

23 **Gao H**, Chen D, Liu X, Wu M, Mi J, Wang W. Polymorphisms and expression of the WNT8A gene in Hirschsprung's disease. *Int J Mol Med* 2013; **32**: 647-652 [PMID: 23836442 DOI: 10.3892/ijmm.2013.1433]

P- Reviewer: Agilli M, Kolettis TM
S- Editor: Tian YL **L- Editor**: A **E- Editor**: Jiao XK

World Journal of Clinical Pediatrics

Submit a Manuscript: http://www.wjgnet.com/esps/
Help Desk: http://www.wjgnet.com/esps/helpdesk.aspx
DOI: 10.5409/wjcp.v4.i4.126

World J Clin Pediatr 2015 November 8; 4(4): 126-134
ISSN 2219-2808 (online)
© 2015 Baishideng Publishing Group Inc. All rights reserved.

MINIREVIEWS

Acute encephalitis and encephalopathy associated with human parvovirus B19 infection in children

Toru Watanabe, Hideshi Kawashima

Toru Watanabe, Hideshi Kawashima, Department of Pediatrics, Niigata City General Hospital, Niigata 950-1197, Japan

Author contributions: Watanabe T designed the aim of this mini-review and performed the majority of the writing; Kawashima H coordinated the writing of the manuscript.

Conflict-of-interest statement: We declare that we have no conflicts of interest in the manuscript, including financial, consultant, institutional or other relationships.

Open-Access: This article is an open-access article which was selected by an in-house editor and fully peer-reviewed by external reviewers. It is distributed in accordance with the Creative Commons Attribution Non Commercial (CCBY-NC 4.0) license, which permits others to distribute, remix, adapt, build upon this work non-commercially, and license their derivative works on different terms, provided the original work is properly cited and the use is non-commercial. See: http://creativecommons.org/licenses/by-nc/4.0/

Correspondence to: Toru Watanabe, PhD, Department of Pediatrics, Niigata City General Hospital, 463-7 Shumoku, Chuo-ku, Niigata 950-1197, Japan. twata@hosp.niigata.niigata.jp
Telephone: +81-25-2815151
Fax: +81-25-2815169

Received: June 24, 2015
Peer-review started: June 26, 2015
First decision: August 10, 2015
Revised: August 11, 2015
Accepted: September 10, 2015
Article in press: September 16, 2015
Published online: November 8, 2015

Abstract

Reports of neurologic manifestations of human parvovirus B19 (B19) infection have been on the rise. Acute encephalitis and encephalopathy is the most common, accounting for 38.8% of total B19-associated neurological manifestations. To date, 34 children with B19 encephalitis and encephalopathy have been reported, which includes 21 encephalitis and 13 encephalopathy cases. Ten (29%) were immunocompromised and 17 (39%) had underlying diseases. Fever at the onset of disease and rash presented in 44.1% and 20.6% of patients, respectively. Neurological manifestations include alteration of consciousness occurred in all patients, seizures in 15 (44.1%) patients, and focal neurologic signs in 12 (35.3%) patients. Anemia and pleocytosis in cerebrospinal fluid (CSF) occurred in 56.3% and 48.1% of patients, respectively. Serum Anti-B19 IgM (82.6%) and CSF B19 DNA (90%) were positive in the majority of cases. Some patients were treated with intravenous immunoglobulins and/or steroids, although an accurate evaluation of the efficacy of these treatment modalities cannot be determined. Nineteen (57.6%) patients recovered completely, 11 (33.3%) patients had some neurological sequelae and 3 (8.8%) patients died. Although the precise pathogenesis underlying the development of B19 encephalitis and encephalopathy is unclear, direct B19 infection or NS1protein of B19 toxicity in the brain, and immune-mediated brain injuries have been proposed.

Key words: Encephalitis; Neurological manifestation; Human parvovirus B19; Encephalopathy; Pathogenesis; Complication

© The Author(s) 2015. Published by Baishideng Publishing Group Inc. All rights reserved.

Core tip: Reports of acute encephalitis and encephalopathy associated with human parvovirus B19 (B19) infection have recently increased. B19 DNA has been detected in cerebrospinal fluid samples in approximately 4% patients with etiologically undiagnosed encephalitis. Some patients were treated with intravenous immunoglobulins and/or steroids. More than half of the patients with B19 encephalitis and encephalopathy recovered completely, but some patients developed severe neurological sequelae or died. Although the precise pathogenesis underlying the development of B19

encephalitis and encephalopathy is unclear, direct B19 infection or NS1 protein of B19 toxicity in the brain, and immune-mediated brain injuries have been proposed.

Watanabe T, Kawashima H. Acute encephalitis and encephalopathy associated with human parvovirus B19 infection in children. *World J Clin Pediatr* 2015; 4(4): 126-134 Available from: URL: http://www.wjgnet.com/2219-2808/full/v4/i4/126.htm DOI: http://dx.doi.org/10.5409/wjcp.v4.i4.126

INTRODUCTION

Human parvovirus B19 (B19) is a member of the erythrovirus genus in the family Parvoviridae[1], first discovered by Cossart *et al*[2] in 1975. B19 is a small, single-stranded DNA virus that binds the cellular receptor P antigen on erythrocytes[3]. The viral genome encodes only three proteins of known function, including nonstructural protein 1 (NS1), and two viral capsid proteins, viral protein 1 (VP1) and viral protein 2 (VP2)[1]. NS1 promotes multiple replicative functions and is cytotoxic to host cells[1]. Since Shneerson *et al*[4] reported the first symptomatic febrile patients with B19 infection in 1980, various clinical manifestations of B19 have been identified. These include erythema infectiosum (EI)[5], arthropathy, non-immune hydrops fetalis and congenital anemia, thrombocytopenia, hepatitis, myocarditis and neurologic diseases in healthy hosts, chronic pure red cell aplasia in immunodeficient hosts, and transient aplastic crisis in patients with increased red cell turnover[1,6]. Of these, neurologic manifestations of B19 infection have been increasingly reported, especially in children[7,8].

B19-associated neurologic manifestations include encephalitis, encephalopathy, meningitis, cerebellar ataxia, transverse myelitis, stroke, and peripheral neuropathy[7,8]. Of these, encephalitis and encephalopathy are the most common with 38.8% of total B19-associated neurological manifestations[8]. Furthermore, recent reports reveal that specific forms of encephalopathy also are associated with B19 infection, which include chorea encephalopathy[9-11], mild encephalitis/encephalopathy with reversible splenial lesion (MERS)[12] and posterior reversible encephalopathy syndrome (PRES)[13]. The following is a review of B19 associated encephalitis and encephalopathy (B19 encephalitis and encephalopathy) in children.

DEFINITION OF B19 ENCEPHALITIS AND ENCEPHALOPATHY

Because encephalitis is defined as inflammation of the brain parenchyma, pathologic examination of brain tissue (brain biopsy) is necessary for its diagnosis. However, brain biopsy is rarely done premortem with its potential risk for patients[14]. In this review, we used the Pillai encephalitis definitions[15], as follows. Encephalopathy was defined as an altered or reduced level of consciousness and a change in personality or behavior or confusion lasting ⩾ 24 h. Encephalitis was defined as an acute encephalopathy with 2 or more of the following: fever ⩾ 38 ℃, seizures or focal neurologic signs, cerebrospinal fluid (CSF) pleocytosis (⩾ 5 white blood cells/μL), electroencephalographic (EEG) findings consistent with encephalitis, and neuroimaging suggestive of encephalitis[15]. B19 infection was based on the detection of either B19 DNA or anti-B19 IgM specific antibodies in serum or CSF[8]. Two patients with encephalitis and encephalopathy without laboratory tests confirming B19 infection were included in this review on the basis of clinical presentation of EI[16,17].

EPIDEMIOLOGY

Balfour *et al*[16] reported an 8-year-old boy who developed encephalitis associated with EI in 1970. Seven years later, Breese *et al*[17] reported a 9-mo-old boy with severe encephalopathy during the course of EI who developed permanent neurologic sequelae. In the era of molecular and serological diagnostics for B19 infection, cases of encephalopathy and B19 DNA in sera and in CSF are accruing[18,19]. To date, 34 patients less than 19 years of age with B19 encephalitis or encephalopathy have been reported (Table 1)[9-11,16-31]. This includes 21 patients with encephalitis, five with encephalopathy, four with chorea encephalopathy, three with MERS and one with PRES. Eleven patients have been reported from United Kingdom, eight from Japan, six from Jamaica, three from United States, two from Italy, two from Brazil, one from Germany and one from Turkey. The age of patients ranges from 1 to 15 years (mean of 6.7 years, median of 7 years). Fifteen patients were male, and the male to female ratio was 0.79. 24 (71%) were immunocompetent individuals, and 10 were immunodeficient. Seventeen (39%) patients had underlying diseases, including sickle cell disease, hereditary spherocytosis (HS), congenital heart diseases, acute lymphocytic leukemia, Crigler-Najar syndrome, Cockayne syndrome, Turner syndrome, and post-renal transplantation for nephropathic cystinosis[12,23-26,28,29]. One patient suffered from ulcerative colitis eight years after B19 encephalopathy[20].

Although the prevalence of B19 infection for all encephalitis and encephalopathy is unknown, two studies reported that B19 DNA has been detected in CSF samples in 2 of 43 (4.7%) and 7 of 162 (4.3%) patients with etiologically undiagnosed encephalitis[22,23].

CLINICAL MANIFESTATIONS

Fever at the onset of diseases presented in 15 of 34 (44.1%) patients (Table 2). Rash was reported in seven (20.6%) patients[13,16,17,19,21,29,31]. Rash developed before the onset of CNS manifestations in two patients, simultaneously with the onset in two patients, and

Table 1 Basic characteristics of children with B19 encephalitis and encephalopathy

Case No.	Ref.	Age	Gender	Diagnosis	Underlying disorders	Immunodeficiency
1	[16]	8 yr	M	Encephalitis		-
2	[17]	9 mo	M	Encephalitis		-
3	[19,20]	5 yr	F	Encephalitis		-
4	[23,24]	2 mo	F	Encephalitis		-
5	[23,24]	2 yr	M	Encephalitis	Acute lymphocytic leukemia	+
6	[23,24]	2 yr	F	Encephalitis		-
7	[23,24]	6 yr	F	Encephalitis	Cockayne syndrome	+
8	[23,24]	9 yr	M	Encephalitis		-
9	[23,24]	13 yr	F	Encephalitis	Crigler-Najar syndrome	-
10	[23,34]	13 yr	M	Encephalitis		-
11	[23,34]	15 yr	F	Encephalitis		-
12	[23,24]	1 d	F	Encephalitis	Necrotizing enterocolitis Patent ductus arteriosus Respiratory distress syndrome	+
13	[23,24]	1 d	F	Encephalitis	Ventricular septal defect Atrial septal defect Patent ductus arteriosus Turner syndrome Obstructive jaundice	+
14	[25]	8 yr	F	Encephalitis	Sickle cell disease Nephrotic syndrome	+
15	[25]	8 yr	M	Encephalitis	Sickle cell disease Nephrotic syndrome	+
16	[25]	12 yr	F	Encephalitis	Sickle cell disease Aplastic crisis	+
17	[25]	14 yr	M	Encephalitis	Sickle cell disease Aplastic crisis	+
18	[27]	10 yr	F	Encephalitis		-
19	[28]	9 yr	M	Encephalitis	Nephropathic cystinosis Renal transplant	+
20	[30]	4 yr	F	Encephalitis		-
21	[31]	5 yr	F	Encephalitis and cerebellitis		-
22	[18]	8 yr	F	Encephalopathy		-
23	[19]	5 yr	F	Encephalopathy		-
24	[21]	5 yr	M	Encephalopathy		-
25	[22]	4 yr	M	Encephalopathy	Prader-Willi syndrome	-
26	[26]	13 yr	F	Encephalopathy	Sβ + thalassemia	+
27	[9]	8 yr	F	Chorea encephalopathy		-
28	[10]	1 yr	M	Chorea encephalopathy		-
29	[11]	1 yr	M	Chorea encephalopathy		-
30	[11]	1 yr	F	Chorea encephalopathy		-
31	[29]	9 yr	F	MERS	Hereditary spherocytosis	-
32	[12]	11 yr	M	MERS	Hereditary spherocytosis	-
33	[12]	10 yr	M	MERS	Hereditary spherocytosis	-
34	[13]	9 yr	F	PRES	Acute glomerulonephritis	-

MERS: Clinically mild encephalitis/encephalopathy with reversible splenial lesion; PRES: Posterior reversible encephalopathy syndrome; F: Female; M: Male.

after the onset in three patients. All patients with rash had normal immune function. Three (8.8%) patients complained of arthralgia.

Acute kidney injury occurred in three patients with sickle cell disease, and in one patient with Cockayne syndrome as a part of multiple organ failure[23-25]. Patients experiencing acute B19 infection sometimes develop renal complications[32,33]. These include acute glomerulonephritis, thrombotic microangiopathy and Henoch-Schönlein purpura nephritis, probably due to direct cytopathic effects on glomerular epithelial cells and endothelial cells, and an immune complex mediated mechanism[32,33].

One of the neurological manifestations was a reduced level of consciousness, which occurred in all patients. Seizures developed in 15 (44.1%) patients and two had statue epilepticus[19,27]. Twelve (35.3%) patients exhibited focal neurologic signs (Table 2), which included neurogenic bladder, chorea, loss of vision, ataxia, dysarthria, hemiparesis, and focal seizures[9-11,13,16,22,23,25,30,31].

LABORATORY DATA

B19 infection causes various blood diseases and cytopenias affecting several blood cell lineages, such as red cell aplasia, pancytopenia and hemophagocytic lymphohistiocytosis (HLH)[34]. In patients with B19 encephalitis and encephalopathy, anemia developed in

Table 2 Clinical manifestations of children with B19 encephalitis and encephalopathy

Case	B19 related symptoms			Neurological manifestations			Complications	Sequelae or death
No.	Fever	Rash	Arthralgia	Unconsciousness	Seizure	Focal neurologic signs		
1	+	+	+	+	-	+Neurogenic bladder		Left weakness and clonus
2	+	-	-	+	+	-		Psychomotor retardation
3	+	+	-	+	+	-	Status epilepticus	Epilepsy Mental retardation
4	+	-	-	+	+	-		-
5	+	-	-	+	-	-		Cognitive deficit
6	+	-	-	+	-	+Ataxia		-
7	-	-	-	+	-	-	Multiple organ failure Acute renal failure	Died
8	-	-	-	+	+	-		Cognitive deficit Epilepsy
9	-	-	-	+	-	-		Not determined
10	-	-	-	+	-	+ Right hemiparesis Ataxia		-
11	-	-	-	+	-	-		Cognitive deficit
12	-	-	-	+	-	-		Died
13	-	-	-	+	-	-		Died
14	-	-	-	+	+	+ Right hemiparesis Transient blindness	Acute renal failure Aplastic crisis Acute chest syndrome	-
15	-	-	-	+	+	+ Cortical blindness	Acute renal failure Aplastic crisis Acute chest syndrome	-
16	+	-	-	+	+	+ Focal seizures	Acute renal failure Acute chest syndrome	-
17	+	-	-	+	+	-		-
18	+	-	-	+	+	-	Status epilepticus	Epilepsy
19	-	-	+	+	+	-		-
20	+	-	-	+	+	+ Cerebellar syndrome		Cerebellar syndrome
21	+	+	-	+	+	-		Cerebellar syndrome
22	-	-	+	+	+	-		-
23	-	+	-	+	+	-		-
24	-	-	-	+	-	-	Pancytopenia Liver dysfunction	-
25	-	-	-	+	-	-		Spastic quadriplegia
26	+	-	-	+	-	-	Aplastic crisis	-
27	-	-	-	+	-	+ Chorea		-
28	-	-	-	+	-	+ Chorea		-
29	-	-	-	+	+	+ Left hemiparesis Athetosis		-
30	-	-	-	+	+	+ Left hemiparesis Choreo-athetosis		Global developmental delay
31	+	+	-	+	-	-	Aplastic crisis Pancytopenia	-
32	+	-	-	+	-	-	Aplastic crisis HLH Pancytopenia	-
33	+	-	-	+	-	-	Aplastic crisis HLH Pancytopenia	-
34	+	+	-	+	+	+ Loss of vision	Transient SLE symptoms Hypertension	-

HLH: Hemophagocytic lymphohistiocytosis; SLE: Systemic lupus erythematosus.

18 of 32 (56.3%) patients (Table 3). Aplastic crisis was recorded in five patients with sickle cell disease and three patients with HS. Pancytopenia and HLH occurred in 4 patients and 2 patients, respectively.

CSF examination showed pleocytosis in 13 of 27 (48.1%) patients and increased protein levels in 8 of 20 (40%) patients (Table 3).

Anti-B19 IgM antibodies and B19 DNA were detected in the sera of 19 out of 23 (82.6%) patients and 12 out of 20 (60%) patients, respectively. Anti-B19 IgM antibodies and B19 DNA were detected in the CSF of two out of 11 (18.2%) patients and 18 out of 20 (90%) patients, respectively (Table 3). These results suggest that serum anti-B19 IgM and CSF B19 DNA examinations are useful tools for diagnosing of B19 infection in patients with encephalitis and encephalopathy.

Table 3 Laboratory data and treatment of children with B19 encephalitis and encephalopathy

Case No.	Anemia	Serum B19 markers			CSF B19 markers			CSF		IVIG and/or steroids
		IgM	IgG	DNA	IgM	IgG	DNA	Pleocytosis	Increased protein	
1	-							+	-	-
2	-							-	+	-
3	-	+	+	+			-	+	+	-
4		-	-	-	-	-	+	-		IVIG
5					+	-	-	-	-	-
6	+				-	-	+	-	-	-
7	-				-	-	+			-
8	+	+	-	+	-	-	+			-
9	-						+			-
10	-						+	-		-
11	-						+	+		-
12	+	+	-	+	+	-	+			-
13	+	-	-	-	-	-	+			-
14	+	+	+	+				+		-
15	+	+	+	+				+		-
16	+	+	+	+				+		-
17	+	+	+	+				+		-
18	-	+	-		-	-		+	+	IVIG and steroids
19	+	+		+				+	+	-
20	-	-	-	+	-	-	+	+	-	IVIG and steroids
21	-	+	+	+			+	+	+	Steroids
22	+	+		+			+	-		-
23	-	+	+	+			+	-	+	-
24	+	+	+	+			+	-	+	-
25	-	+	+	+	-	-	+	+	+	-
26	+	+	+	-	-	-		-	-	Steroids
27	+			+			+	-	-	-
28	-	+	+				+	-	-	IVIG and steroids
29	-	+	-							-
30	+	+	-					+	-	-
31	+	-	+	+			+	-	-	Steroids
32	+							-	-	IVIG
33	+							-	-	IVIG
34	+	+	+	+			+	-	-	-

IVIG: Intravenous immunoglobulin; CSF: Cerebrospinal fluid.

IMAGING STUDIES AND EEG

Six of 13 (46.2%) patients had abnormal brain computed tomography findings, which included an enlarged ventricle, brain edema, frontal and occipital vasogenic swelling, and lesions in right parietal, temporal or occipital areas[13,22,23,25]. Brain magnetic resonance images showed abnormal findings in 10 of 15 (66.7%) patients. These findings included high signal intensity in the white matter[13,23,26,30], basal ganglia, and cerebellum in T2 weighted images, high signal intensity in the splenial lesion of corpus callosum in diffusion-weighted images or T2 weighted images, and enlarged ventricles[12,23,26,29,31].

EEG revealed abnormal findings in 15 of 19 (78.9%) patients, which included diffuse or focal slowing of the background activity, encephalopathic changes or epileptic abnormality[10,12,16,17,24,26,27,29,30].

TREATMENT

As discussed elsewhere, direct B19 infection or NS1 toxicity in the brain, and immune-mediated brain injuries have been proposed as pathogenic causes that result in the development of B19 encephalitis and encephalopathy[7,8,35]. Some patients with B19 encephalitis and encephalopathy were treated with intravenous immunoglobulin (IVIG) and/or steroids (Table 3). IVIG and steroids are often used in post-infectious or immune-mediated encephalitis as immuno-modulatory therapies[36]. In addition, IVIG is used for many clinical conditions associated with B19 infection such as chronic anemia, because immunoglobulin preparations are a good source of neutralizating antibodies against B19[6].

Both IVIG and steroids were administrated to three patients[10,25,30], two of them showing neurologic sequelae (epilepsy and cerebellar syndrome). Three patients were treated with IVIG only, and they all recovered completely. Steroids only were administered to two patients, one of whom exhibited neurological sequelae (cerebellar syndrome)[12,23,26,31]. Since there have been only a few reports of B19 encephalitis and encephalopathy with IVIG and/or steroids, an accurate evaluation of the efficacy of these treatment cannot be determined. However, due to the lack of other effective treatments for B19 encephalitis and encephalopathy, Barah *et al*[8] recommended that treatment of severe cases might benefit from a combined regimen of IVIG and steroids.

OUTCOME

Nineteen of 33 (57.6%) patients recovered completely from neurologic disturbances, whereas 11 (33.3%) patients had some neurological sequelae and three (8.8%) patients died (Table 2). Patients with B19 encephalitis had worse prognosis (8 of 20 patients had neurological sequelae, and 3 patients died) than patients with B19 encephalopathy, MERS or PRES (2 of 13 patients had neurological sequelae, and no patient died). Neurological sequelae included psychomotor retardation[11,17,19], cognitive deficit, epilepsy, cerebellar syndrome, hemiparesis and spastic quadriplegia[16,19,22,23,27,30,31]. All of the patients that died were immunodeficient (two neonates and one patient with Cockayne syndrome)[23].

SPECIFIC FORMS OF B19 ENCEPHALOPATHY

Recent reports have revealed that specific forms of encephalopathy are associated with B19 infection, which include chorea encephalopathy, MERS and PRES[9-13].

Chorea encephalopathy

Chorea encephalopathy is characterized extrapyramidal features in the context of self-limiting neurological illness with CSF oligoclonal IgG bands, probably caused by immune-mediated (possibly autoantibody) pathogenic mechanisms[37]. Four patients with B19 associated chorea encephalopathy have been reported to date[9-11]. Grillo *et al*[38] pointed out the clinical similarity between chorea encephalopathy and anti-N-methyl-D-aspartate receptor (NMDAR) encephalitis, which is an autoimmune encephalitis caused by autoantibodies against the NR1 subunit of NMDAR[39], and suggested that some cases of anti-NMDAR encephalitis could be triggered by B19.

Clinically mild encephalitis/encephalopathy with reversible splenial lesion

Clinically MERS is clinically mild encephalitis/encephalopathy characterized by an MRI finding of a reversible lesion with reduced diffusion in the corpus callosum, first proposed by Tada *et al*[40] in 2004. Delirious behavior, impaired consciousness and seizure often occur as neurological symptoms, all of which completely recover within a month[41]. Although a majority of patients with MERS are associated with viruses or bacteria[41], some cases of Kawasaki disease associated with MERS have been reported[42]. The precise pathogenesis of MERS is unknown, intramyelinic edema, interstitial edema in tightly packed fibers and transient inflammatory infiltrate have been postulated[41].

Three patients with B19-associated MERS have been reported[12,29]. Oshima *et al*[29] reported a 9-year-old girl with HS developed MERS and aplastic crisis. They followed the plasma and CSF concentrations of B19 by real-time polymerase chain reaction and found that the symptoms of encephalopathy had occurred at the peak viral load, suggesting that B19 MERS might occur as a result of direct B19 invasion. Suzuki *et al*[12] also reported that two brothers with HS developed B19 MERS and HLH. HLH is due to dysregulated lymphocyte activation, which leads to macrophage hyperactivation and over-expression of pro-inflammatory cytokines, including IL-6[43]. HLH has been reported in 28 patients with B19 infection, most of whom had HS as an underlying disease[43]. Moreover, increased IL-6 levels in CSF have been reported in patients with MERS[44,45]. These findings suggest that B19-induced IL-6 overproduction may lead to MERS and HLH in patients with HS[12].

PRES

PRES is characterized clinically by headaches, impaired consciousness, visual disturbances and seizures, and radiologically by posterior (parieto-occipital) imaging changes predominantly occurring in the sub-cortical white matter[46]. Although the pathophysiology underlying the development of PRES is multifactorial, hypertension plays a major role in the development of PRES through disruption of autoregulation in cerebral blood vessels[46].

Cugler *et al*[13] reported a 9-year-old girl with severe acute glomerulonephritis and PRES associated with B19 infection mimicking systemic lupus erythematosus. Only adequate control of blood pressure and diet led to complete resolution of the patient's symptoms.

PATHOGENIC MECHANISMS

Although the precise pathogenesis underlying the development of B19 encephalitis and encephalopathy is unclear, direct B19 infection or NS1 toxicity in the brain, and immune-mediated brain injuries that include cytokine dysregulation and autoantibody production directed against brain antigens, have been proposed[7,8,35].

Direct B19 infection or NS1 toxicity

Only erythroid progenitor cells are permissive for B19 replication because these cells have both high concentrations of P blood type antigen, the receptor for B19[3] and $\alpha5\beta1$ integrin, the co-receptor for B19[47]. P antigen is also expressed on other cell types including megakaryocytes, granulocytes, lung, heart, liver, kidney, endothelium, and vascular smooth muscle[48]. However, P antigen is necessary for B19 binding but not sufficient for virus entry into cell, which requires $\alpha5\beta1$ integrin as a cellular co-receptor[47]. Because non-erythroid progenitor cells with P antigen do not have $\alpha5\beta1$ integrin, B19 can bind, but cannot infect them. However, the NS1 exerts a cytotoxic effect on the cells it binds without any B19 replication or virion accumulation[49,50]. Therefore, NS1 may directly damage the cerebrovascular endothelium during B19 infection.

B19 DNA has been detected in the brain of two intrauterine deceased fetuses in mothers with recent B19 infection[51,52]. Hobbs *et al*[53,54] reported that B19

DNA was detected in 42% of dorsolateral prefrontal cortex and in 100% of cerebella, of postmortem samples taken from 104 subjects without recent acute B19 infection. Manning *et al*[55] also reported that B19 DNA was detected in 69% of frontal or occipital lobe of postmortem brain tissue samples taken from 29 subjects without recent acute B19 infection.

Although B19 DNA was frequently detected in the CSF of children with B19 acute encephalitis and encephalopathy, B19 detection in the brain has never been reported in children[35]. Kerr *et al*[24] reported that postmortem brain tissue from a child with B19 acute encephalitis was negative for B19 in using *in situ* hybridization method. Skaff *et al*[56] also reported negative immunohistochemistry results for detecting B19 in brain biopsy tissue taken from an immunocompetent adult patient with B19 encephalitis. Meanwhile, B19 DNA was detected in brain biopsy tissues taken from adult patients with B19 encephalitis by PCR[57,58]. There is still controversy regarding whether B19 has direct infection or NS1 toxicity in the brain cells or not[59].

Cytokines dysregulation

B19 infection induces cytokine dysregulation. Wagner *et al*[60] studied concentrations of interleukin (IL)-1β, and IL-6 concentrations and interferon (INF)-γ messenger RNA (mRNA) in peripheral blood mononuclear cells (PBMC) from patients with acute B19 infection and reported that these cytokine genes were activated in PBMC, suggesting systemic monocyte and T cell activation. Moffatt *et al*[61] demonstrated that IL-6 production caused by the B19 NS1 protein was mediated by an NF-κB binding site in the IL-6 promotor region. Kerr *et al*[62,63] reported that serum IL-6, tumor necrosis factor (TNF)-α, IL-1β, IL-4, IL-8, INF-γ, macrophage chemoattractant protein-1(MCP-1), granulocyte-monocyte colony stimulating factor (GM-CSF) levels were increased during acute B19 infection.

Kerr *et al*[24] reported that increased levels of TNF-α, INF-γ, IL-6, INF-γ, GM-CSF and MPC-1 in the serum and CSF of patients with B19 encephalitis and suggested that over-production of inflammatory cytokines might play a role in B19 encephalitis.

Autoantibody production

B19 infection often develops clinical features similar to autoimmune disease and has been associated with the production of antibodies against self-antigens, including nuclear antigens, rheumatoid factor, neutrophils cytoplasmic antigens, and phospholipids[64,65]. Molecular similarities between host and B19 proteins and the induction of inflammatory cytokine production encourage the development of autoimmune reactions during B19 infection[64,65]. B19 chorea encephalitis has been suggested to be caused by autoimmune reactions against brain autoantigens[38].

CONCLUSION

Acute B19 encephalitis and encephalopathy are the most common B19-associated neurological manifestations. Some patients were immunocompromised or had underlying diseases. Impaired consciousness, seizures and focal neurologic signs are the main neurological features. Serum Anti-B19 IgM and CSF B19 DNA examinations are useful tools for diagnosing B19 infection in patients with B19 encephalitis and encephalopathy. Two studies reported that B19 DNA has been detected in CSF samples in approximately 4% of patients with etiologically undiagnosed encephalitis. Serum Anti-B19 IgM and CSF B19 DNA should be examined in patients with etiologically undiagnosed encephalitis and encephalopathy. Some patients with B19 encephalitis and encephalopathy were treated with IVIG and/or steroids; however, an accurate evaluation of the efficacy of these treatment modalities cannot be determined. Although more than half of B19 encephalitis and encephalopathy patients recovered completely, some patients developed severe neurological sequelae or died. While the precise pathogenesis underlying the development of B19 encephalitis and encephalopathy is unclear, direct B19 infection or NS1 toxicity in the brain, and immune-mediated brain injuries have been proposed.

REFERENCES

1 **Young NS**, Brown KE. Parvovirus B19. *N Engl J Med* 2004; **350**: 586-597 [PMID: 14762186 DOI: 10.1056/NEJMra030840]

2 **Cossart YE**, Field AM, Cant B, Widdows D. Parvovirus-like particles in human sera. *Lancet* 1975; **1**: 72-73 [PMID: 46024 DOI: 10.1016/S0140-6736(75)91074-0]

3 **Brown KE**, Hibbs JR, Gallinella G, Anderson SM, Lehman ED, McCarthy P, Young NS. Resistance to parvovirus B19 infection due to lack of virus receptor (erythrocyte P antigen). *N Engl J Med* 1994; **330**: 1192-1196 [PMID: 8139629 DOI: 10.1056/NEJM199404283301704]

4 **Shneerson JM**, Mortimer PP, Vandervelde EM. Febrile illness due to a parvovirus. *Br Med J* 1980; **280**: 1580 [PMID: 7427176 DOI: 10.1136/bmj.280.6231.1580]

5 **Anderson MJ**, Jones SE, Fisher-Hoch SP, Lewis E, Hall SM, Bartlett CL, Cohen BJ, Mortimer PP, Pereira MS. Human parvovirus, the cause of erythema infectiosum (fifth disease)? *Lancet* 1983; **1**: 1378 [PMID: 6134148 DOI: 10.1016/S0140-6736(83)92152-9]

6 **Heegaard ED**, Brown KE. Human parvovirus B19. *Clin Microbiol Rev* 2002; **15**: 485-505 [PMID: 12097253 DOI: 10.1128/CMR.15.3.485-505.2002]

7 **Douvoyiannis M**, Litman N, Goldman DL. Neurologic manifestations associated with parvovirus B19 infection. *Clin Infect Dis* 2009; **48**: 1713-1723 [PMID: 19441978 DOI: 10.1086/599042]

8 **Barah F**, Whiteside S, Batista S, Morris J. Neurological aspects of human parvovirus B19 infection: a systematic review. *Rev Med Virol* 2014; **24**: 154-168 [PMID: 24459081 DOI: 10.1002/rmv.1782]

9 **Fong CY**, de Sousa C. Childhood chorea-encephalopathy associated with human parvovirus B19 infection. *Dev Med Child Neurol* 2006; **48**: 526-528 [PMID: 16700948 DOI: 10.1017/S0012162206001101]

10 **Grillo E**, da Silva RJ. Childhood chorea-encephalopathy and unremarkable MRI: an association suggesting parvovirus B19 infection. *Dev Med Child Neurol* 2009; **51**: 759-761 [PMID: 19583739 DOI: 10.1111/j.1469-8749.2009.03388.x]

11 **Chambers RH**, Gooden MA, Gilbert TD, Jackson ST. Childhood chorea-encephalopathy associated with recent parvovirus B19 infection in two Jamaican children. *Ann Trop Paediatr* 2010; **30**: 339-344 [PMID: 21118630 DOI: 10.1179/146532810X1285895592

1438]
12 **Suzuki H**, Kusaka T, Okada H. Clinically mild encephalitis/encephalopathy with a reversible splenial lesion caused by human parvovirus b19 infection: a case of two brothers with hereditary spherocytosis. *Pediatr Neurol* 2014; **51**: 470-472 [PMID: 25035141 DOI: 10.1016/j.pediatrneurol.2014.05.021]
13 **Cugler T**, Carvalho LM, Facincani I, Yamamoto AY, Silva GE, Costa RS, Ferriani VP. Severe glomerulonephritis and encephalopathy associated with parvovirus B19 infection mimicking systemic lupus erythematosus. *Scand J Rheumatol* 2012; **41**: 79-81 [PMID: 22043904 DOI: 10.3109/03009742.2011.617315]
14 **Venkatesan A**, Tunkel AR, Bloch KC, Lauring AS, Sejvar J, Bitnun A, Stahl JP, Mailles A, Drebot M, Rupprecht CE, Yoder J, Cope JR, Wilson MR, Whitley RJ, Sullivan J, Granerod J, Jones C, Eastwood K, Ward KN, Durrheim DN, Solbrig MV, Guo-Dong L, Glaser CA. Case definitions, diagnostic algorithms, and priorities in encephalitis: consensus statement of the international encephalitis consortium. *Clin Infect Dis* 2013; **57**: 1114-1128 [PMID: 23861361 DOI: 10.1093/cid/cit458]
15 **Pillai SC**, Hacohen Y, Tantsis E, Prelog K, Merheb V, Kesson A, Barnes E, Gill D, Webster R, Menezes M, Ardern-Holmes S, Gupta S, Procopis P, Troedson C, Antony J, Ouvrier RA, Polfrit Y, Davies NW, Waters P, Lang B, Lim MJ, Brilot F, Vincent A, Dale RC. Infectious and autoantibody-associated encephalitis: clinical features and long-term outcome. *Pediatrics* 2015; **135**: e974-e984 [PMID: 25802349 DOI: 10.1542/peds.2014-2702]
16 **Balfour HH**, Schiff GM, Bloom JE. Encephalitis associated with erythema infectiosum. *J Pediatr* 1970; **77**: 133-136 [PMID: 4317884 DOI: 10.1016/S0022-3476(70)80059-2]
17 **Breese C**, Horner FA. Encephalopathy with erythema infectiosum. *Am J Dis Child* 1977; **131**: 65-67 [PMID: 835523]
18 **Zerbini M**, Musiani M, Venturoli S, Gallinella G, Gibellini D, Gentilomi G, La Placa M. Different syndromes associated with B19 parvovirus viraemia in paediatric patients: report of four cases. *Eur J Pediatr* 1992; **151**: 815-817 [PMID: 1468455 DOI: 10.1007/BF01957931]
19 **Watanabe T**, Satoh M, Oda Y. Human parvovirus B19 encephalopathy. *Arch Dis Child* 1994; **70**: 71 [PMID: 8110015 DOI: 10.1136/adc.70.1.71-a]
20 **Watanabe T**. Ulcerative colitis that developed 8 years after human parvovirus B19 encephalopathy. *Eur J Pediatr* 2004; **163**: 341-342 [PMID: 15346923 DOI: 10.1007/s00431-004-1433-x]
21 **Yoto Y**, Kudoh T, Asanuma H, Numazaki K, Tsutsumi Y, Nakata S, Chiba S. Transient disturbance of consciousness and hepatic dysfunction associated with human parvovirus B19 infection. *Lancet* 1994; **344**: 624-625 [PMID: 7914998 DOI: 10.1016/S0140-6736(94)92014-1]
22 **Haseyama K**, Kudoh T, Yoto Y, Suzuki N, Chiba S. Detection of human parvovirus B19 DNA in cerebrospinal fluid. *Pediatr Infect Dis J* 1997; **16**: 324-326 [PMID: 9076823 DOI: 10.1097/00006454-199703000-00013]
23 **Barah F**, Vallely PJ, Chiswick ML, Cleator GM, Kerr JR. Association of human parvovirus B19 infection with acute meningoencephalitis. *Lancet* 2001; **358**: 729-730 [PMID: 11551584 DOI: 10.1016/S0140-6736(01)05905-0]
24 **Kerr JR**, Barah F, Chiswick ML, McDonnell GV, Smith J, Chapman MD, Bingham JB, Kelleher P, Sheppard MN. Evidence for the role of demyelination, HLA-DR alleles, and cytokines in the pathogenesis of parvovirus B19 meningoencephalitis and its sequelae. *J Neurol Neurosurg Psychiatry* 2002; **73**: 739-746 [PMID: 12438480 DOI: 10.1136/jnnp.73.6.739]
25 **Wierenga KJ**, Serjeant BE, Serjeant GR. Cerebrovascular complications and parvovirus infection in homozygous sickle cell disease. *J Pediatr* 2001; **139**: 438-442 [PMID: 11562626 DOI: 10.1067/mpd.2001.117070]
26 **Bakhshi S**, Sarnaik SA, Becker C, Shurney WW, Nigro M, Savaşan S. Acute encephalopathy with parvovirus B19 infection in sickle cell disease. *Arch Dis Child* 2002; **87**: 541-542 [PMID: 12456562 DOI: 10.1136/adc.87.6.541]
27 **Erol I**, Alehan F, Yalçin K. Refractory status epilepticus owing to human parvovirus B19 encephalitis in a child. *J Child Neurol* 2006; **21**: 820-822 [PMID: 16970896 DOI: 10.1177/08830738060210092301]
28 **Laurenz M**, Winkelmann B, Roigas J, Zimmering M, Querfeld U, Müller D. Severe parvovirus B19 encephalitis after renal transplantation. *Pediatr Transplant* 2006; **10**: 978-981 [PMID: 17096771 DOI: 10.1111/j.1399-3046.2006.00599.x]
29 **Oshima K**, Kikuchi A, Mochizuki S, Arai T, Oishi T, Hanada R. Acute encephalopathy with human parvovirus B19 infection in hereditary spherocytosis. *Pediatr Infect Dis J* 2008; **27**: 651-652 [PMID: 18520445 DOI: 10.1097/INF.0b013e3181694fcf]
30 **Greco F**, Barbagallo ML, Chiodo DC, Guglielmino R, Sorge G. Severe ataxia as a complication of human parvovirus B19 acute encephalitis in a child. *J Child Neurol* 2008; **23**: 1078-1080 [PMID: 18487517 DOI: 10.1177/0883073808315420]
31 **Uchida Y**, Matsubara K, Morio T, Kawasaki Y, Iwata A, Yura K, Kamimura K, Nigami H, Fukaya T. Acute cerebellitis and concurrent encephalitis associated with parvovirus B19 infection. *Pediatr Infect Dis J* 2012; **31**: 427 [PMID: 22418658 DOI: 10.1097/INF.0b013e3182481e24]
32 **Watanabe T**. Renal involvement in human parvovirus B19 infection. *Pediatr Nephrol* 2003; **18**: 966-967 [PMID: 12883967 DOI: 10.1007/s00467-003-1232-z]
33 **Waldman M**, Kopp JB. Parvovirus B19 and the kidney. *Clin J Am Soc Nephrol* 2007; **2** Suppl 1: S47-S56 [PMID: 17699510 DOI: 10.2215/CJN.01060307]
34 **Kerr JR**. A review of blood diseases and cytopenias associated with human parvovirus B19 infection. *Rev Med Virol* 2015; **25**: 224-240 [PMID: 25962796 DOI: 10.1002/rmv.1839]
35 **Barah F**, Vallely PJ, Cleator GM, Kerr JR. Neurological manifestations of human parvovirus B19 infection. *Rev Med Virol* 2003; **13**: 185-199 [PMID: 12740833 DOI: 10.1002/rmv.388]
36 **Shulte DJ**. Human parvovirus B19. In: Cherry JM, Demmler-Harrison GJ, Kaplan SL, Holtez PJ, Stein bach WJ. Feigin and Cherry's textbook of pediatric infectious diseases. Philadelphia: Elsevier Saunders, 2014: 1843-1857
37 **Hartley LM**, Ng SY, Dale RC, Church AJ, Martinez A, de Sousa C. Immune mediated chorea encephalopathy syndrome in childhood. *Dev Med Child Neurol* 2002; **44**: 273-277 [PMID: 11995896 DOI: 10.1017/S0012162201002055]
38 **Grillo E**, da Silva RJ. Anti-N-methyl-D-aspartate receptor encephalitis and parvovirus B19: A possible link? *J Pediatr* 2013; **163**: 1233-1234 [PMID: 23919909 DOI: 10.1016/j.jpeds.2013.06.079]
39 **Wright S**, Hacohen Y, Jacobson L, Agrawal S, Gupta R, Philip S, Smith M, Lim M, Wassmer E, Vincent A. N-methyl-D-aspartate receptor antibody-mediated neurological disease: results of a UK-based surveillance study in children. *Arch Dis Child* 2015; **100**: 521-526 [PMID: 25637141 DOI: 10.1136/archdischild-2014-306795]
40 **Tada H**, Takanashi J, Barkovich AJ, Oba H, Maeda M, Tsukahara H, Suzuki M, Yamamoto T, Shimono T, Ichiyama T, Taoka T, Sohma O, Yoshikawa H, Kohno Y. Clinically mild encephalitis/encephalopathy with a reversible splenial lesion. *Neurology* 2004; **63**: 1854-1858 [PMID: 15557501 DOI: 10.1212/01.WNL.0000144274.12174.CB]
41 **Takanashi J**. Two newly proposed infectious encephalitis/encephalopathy syndromes. *Brain Dev* 2009; **31**: 521-528 [PMID: 19339128 DOI: 10.1016/j.braindev.2009.02.012]
42 **Takanashi J**, Shirai K, Sugawara Y, Okamoto Y, Obonai T, Terada H. Kawasaki disease complicated by mild encephalopathy with a reversible splenial lesion (MERS). *J Neurol Sci* 2012; **315**: 167-169 [PMID: 22129937 DOI: 10.1016/j.jns.2011.11.022]
43 **Ansuini V**, Rigante D, Esposito S. Debate around infection-dependent hemophagocytic syndrome in paediatrics. *BMC Infect Dis* 2013; **13**: 15 [PMID: 23324497 DOI: 10.1186/1471-2334-13-15]
44 **Miyata R**, Tanuma N, Hayashi M, Imamura T, Takanashi J, Nagata R, Okumura A, Kashii H, Tomita S, Kumada S, Kubota M. Oxidative stress in patients with clinically mild encephalitis/encephalopathy with a reversible splenial lesion (MERS). *Brain Dev* 2012; **34**: 124-127 [PMID: 21576007 DOI: 10.1016/j.braindev.2011.04.004]

45 **Kometani H**, Kawatani M, Ohta G, Okazaki S, Ogura K, Yasutomi M, Tanizawa A, Ohshima Y. Marked elevation of interleukin-6 in mild encephalopathy with a reversible splenial lesion (MERS) associated with acute focal bacterial nephritis caused by Enterococcus faecalis. *Brain Dev* 2014; **36**: 551-553 [PMID: 23978488 DOI: 10.1016/j.braindev.2013.07.012]

46 **McCoy B**, King M, Gill D, Twomey E. Childhood posterior reversible encephalopathy syndrome. *Eur J Paediatr Neurol* 2011; **15**: 91-94 [PMID: 21074464 DOI: 10.1016/j.ejpn.2010.10.002]

47 **Weigel-Kelley KA**, Yoder MC, Srivastava A. Alpha5beta1 integrin as a cellular coreceptor for human parvovirus B19: requirement of functional activation of beta1 integrin for viral entry. *Blood* 2003; **102**: 3927-3933 [PMID: 12907437 DOI: 10.1182/blood-2003-05-1522]

48 **Cooling LL**, Koerner TA, Naides SJ. Multiple glycosphingolipids determine the tissue tropism of parvovirus B19. *J Infect Dis* 1995; **172**: 1198-1205 [PMID: 7594654 DOI: 10.1093/infdis/172.5.1198]

49 **Ozawa K**, Ayub J, Kajigaya S, Shimada T, Young N. The gene encoding the nonstructural protein of B19 (human) parvovirus may be lethal in transfected cells. *J Virol* 1988; **62**: 2884-2889 [PMID: 2969055]

50 **Srivastava A**, Bruno E, Briddell R, Cooper R, Srivastava C, van Besien K, Hoffman R. Parvovirus B19-induced perturbation of human megakaryocytopoiesis in vitro. *Blood* 1990; **76**: 1997-2004 [PMID: 2146978]

51 **Salimans MM**, van de Rijke FM, Raap AK, van Elsacker-Niele AM. Detection of parvovirus B19 DNA in fetal tissues by in situ hybridisation and polymerase chain reaction. *J Clin Pathol* 1989; **42**: 525-530 [PMID: 2732347 DOI: 10.1136/jcp.42.5.525]

52 **Isumi H**, Nunoue T, Nishida A, Takashima S. Fetal brain infection with human parvovirus B19. *Pediatr Neurol* 1999; **21**: 661-663 [PMID: 10513695 DOI: 10.1016/S0887-8994(99)00055-7]

53 **Hobbs JA**. Detection of adeno-associated virus 2 and parvovirus B19 in the human dorsolateral prefrontal cortex. *J Neurovirol* 2006; **12**: 190-199 [PMID: 16877300 DOI: 10.1080/13550280600827351]

54 **Grant JK**, Yin NC, Zaytoun AM, Waseem H, Hobbs JA. Persistent adeno-associated virus 2 and parvovirus B19 sequences in post-mortem human cerebellum. *Cerebellum* 2009; **8**: 490-498 [PMID: 19585179 DOI: 10.1007/s12311-009-0126-4]

55 **Manning A**, Willey SJ, Bell JE, Simmonds P. Comparison of tissue distribution, persistence, and molecular epidemiology of parvovirus B19 and novel human parvoviruses PARV4 and human bocavirus. *J Infect Dis* 2007; **195**: 1345-1352 [PMID: 17397006 DOI: 10.1086/513280]

56 **Skaff PT**, Labiner DM. Status epilepticus due to human parvovirus B19 encephalitis in an immunocompetent adult. *Neurology* 2001; **57**: 1336-1337 [PMID: 11591864 DOI: 10.1212/WNL.57.7.1336]

57 **Druschky K**, Walloch J, Heckmann J, Schmidt B, Stefan H, Neundörfer B. Chronic parvovirus B-19 meningoencephalitis with additional detection of Epstein-Barr virus DNA in the cerebrospinal fluid of an immunocompetent patient. *J Neurovirol* 2000; **6**: 418-422 [PMID: 11031695 DOI: 10.3109/13550280009018306]

58 **Nolan RC**, Chidlow G, French MA. Parvovirus B19 encephalitis presenting as immune restoration disease after highly active antiretroviral therapy for human immunodeficiency virus infection. *Clin Infect Dis* 2003; **36**: 1191-1194 [PMID: 12715316 DOI: 10.1086/374603]

59 **Hobbs JA**. Parvovirus B19-brain interactions: infection, autoimmunity, or both? *J Clin Virol* 2007; **38**: 364-365 [PMID: 17337241 DOI: 10.1016/j.jcv.2007.01.005]

60 **Wagner AD**, Goronzy JJ, Matteson EL, Weyand CM. Systemic monocyte and T-cell activation in a patient with human parvovirus B19 infection. *Mayo Clin Proc* 1995; **70**: 261-265 [PMID: 7861814 DOI: 10.4065/70.3.261]

61 **Moffatt S**, Tanaka N, Tada K, Nose M, Nakamura M, Muraoka O, Hirano T, Sugamura K. A cytotoxic nonstructural protein, NS1, of human parvovirus B19 induces activation of interleukin-6 gene expression. *J Virol* 1996; **70**: 8485-8491 [PMID: 8970971]

62 **Kerr JR**, Barah F, Mattey DL, Laing I, Hopkins SJ, Hutchinson IV, Tyrrell DA. Circulating tumour necrosis factor-alpha and interferon-gamma are detectable during acute and convalescent parvovirus B19 infection and are associated with prolonged and chronic fatigue. *J Gen Virol* 2001; **82**: 3011-3019 [PMID: 11714978 DOI: 10.1099/0022-1317-82-12-3011]

63 **Kerr JR**, Cunniffe VS, Kelleher P, Coats AJ, Mattey DL. Circulating cytokines and chemokines in acute symptomatic parvovirus B19 infection: negative association between levels of pro-inflammatory cytokines and development of B19-associated arthritis. *J Med Virol* 2004; **74**: 147-155 [PMID: 15258981 DOI: 10.1002/jmv.20158]

64 **Lehmann HW**, von Landenberg P, Modrow S. Parvovirus B19 infection and autoimmune disease. *Autoimmun Rev* 2003; **2**: 218-223 [PMID: 12848949 DOI: 10.1016/S1568-9972(03)00014-4]

65 **Lunardi C**, Tinazzi E, Bason C, Dolcino M, Corrocher R, Puccetti A. Human parvovirus B19 infection and autoimmunity. *Autoimmun Rev* 2008; **8**: 116-120 [PMID: 18700174 DOI: 10.1016/j.autrev.2008.07.005]

P- Reviewer: Anselm CWL, Sangkhathat S
S- Editor: Qiu S **L- Editor**: A **E- Editor**: Jiao XK

World Journal of Clinical Pediatrics

Submit a Manuscript: http://www.wjgnet.com/esps/
Help Desk: http://www.wjgnet.com/esps/helpdesk.aspx
DOI: 10.5409/wjcp.v4.i4.135

World J Clin Pediatr 2015 November 8; 4(4): 135-142
ISSN 2219-2808 (online)
© 2015 Baishideng Publishing Group Inc. All rights reserved.

MINIREVIEWS

Use of corticosteroids during acute phase of Kawasaki disease

Jeong Jin Yu

Jeong Jin Yu, Department of Pediatrics Cardiology, College of Medicine, Ulsan University, Ulsan 680-749, South Korea

Jeong Jin Yu, Department of Pediatrics, Asan Medical Center, Seoul 138-736, South Korea

Author contributions: Yu JJ solely contributed to this manuscript.

Conflict-of-interest statement: I have no relevant financial relationships to disclose or conflicts of interest to resolve.

Open-Access: This article is an open-access article which was selected by an in-house editor and fully peer-reviewed by external reviewers. It is distributed in accordance with the Creative Commons Attribution Non Commercial (CC BY-NC 4.0) license, which permits others to distribute, remix, adapt, build upon this work non-commercially, and license their derivative works on different terms, provided the original work is properly cited and the use is non-commercial. See: http://creativecommons.org/licenses/by-nc/4.0/

Correspondence to: Jeong Jin Yu, MD, PhD, Department of Pediatrics, Asan Medical Center, 88, Olympic-ro 43-gil, Songpa-gu, Seoul 138-736, South Korea. pediatrist@medimail.co.kr
Telephone: +82-2-30103924
Fax: +82-2-4733725

Received: July 2, 2015
Peer-review started: July 8, 2015
First decision: August 25, 2015
Revised: August 28, 2015
Accepted: October 16, 2015
Article in press: October 19, 2015
Published online: November 8, 2015

Abstract

In spite of initial intravenous immunoglobulin (IVIG) treatment, a significant number of patients are unresponsive to it and are at a higher risk for coronary artery lesions. Corticosteroids have been used as a secondary drug or used in combination with IVIG. Three options of using corticosteroids for the treatment of patients during the acute phase of Kawasaki disease, have been considered. The first is their use exclusively for patients unresponsive to IVIG treatment. The second is their use in combination with IVIG as the routine first line therapy for all patients. The last is the use in the combination as the first line therapy for selected patients at a high risk being unresponsive to initial IVIG. However, it is uncertain that the corticosteroids as the second line treatment are better than the additional IVIG in patients unresponsive to initial IVIG. The combination of corticosteroids and IVIG as the routine first line therapy also have not enough evidences. The last option of using corticosteroids - the combination of corticosteroids and IVIG in patients at high risk of unresponsiveness, is a properly reasonable treatment strategy. However, there have been no globally standardized predictive models for the unresponsiveness to initial IVIG treatment. Therefore, future investigations to determine the best predictive model are necessary.

Key words: Kawasaki disease; Methylprednisolone; Corticosteroids; Coronary aneurysm; Immunoglobulins; Prednisolone; Fever

© The Author(s) 2015. Published by Baishideng Publishing Group Inc. All rights reserved.

Core tip: In spite of initial intravenous immunoglobulin (IVIG) treatment, a significant number of patients are unresponsive to it and are at a higher risk for coronary artery lesions. Corticosteroids have been used as a secondary drug or used in combination with IVIG. There are several options of using corticosteroids for the treatment of patients with Kawasaki disease during the acute phase. A thorough review of the use of corticosteroids in acute phase Kawasaki disease was performed in this paper.

Yu JJ. Use of corticosteroids during acute phase of Kawasaki disease. *World J Clin Pediatr* 2015; 4(4): 135-142 Available from: URL: http://www.wjgnet.com/2219-2808/full/v4/i4/135.htm DOI: http://dx.doi.org/10.5409/wjcp.v4.i4.135

INTRODUCTION

Kawasaki disease is an acute, self-limited systemic type of vasculitis which occurs predominantly in young children. Kawasaki[1] firstly reported it in 1967, and it is now acknowledged as a common acquired heart disease of children in many developed countries. The etiology of Kawasaki disease is currently unknown. It is a reasonable open hypothesis that Kawasaki disease is caused by an unidentified microorganism that induces striking immune perturbations in genetically susceptible individuals. Although the efforts to find a causative microorganism have failed[2-4], the suspicion of an association between some unidentified microorganism and Kawasaki disease remains[4-7]. Investigations to identify a genetic susceptibility locus in Kawasaki disease also have been performed recently[8-10]. Several institutes had cooperated and reported a result regarding the genetic susceptibility of Kawasaki disease[11]. A recent review[12] further explains the related genetic studies. The standard first line therapies during the acute phase are an intravenous infusion of immunoglobulin (IVIG) and the administration of a high dose of aspirin[13]. Corticosteroids were used as the first line therapy before Kato *et al*[14] suggested the possibility of an aggravation of coronary artery lesions caused by them. Another report[15] to the contrary was quieted because the strong therapeutic efficacy of IVIG was reported in 1984[16]. More than 10 years after the introduction of IVIG, there were reports of the successful therapeutic application of corticosteroids for children with Kawasaki disease unresponsive to initial IVIG treatment in whom neither significant aggravation of coronary artery lesions nor other adverse effects were found after the administration of corticosteroids[17-19]. In addition, a question about the study by Kato *et al*[14], in which an information about randomization methods was not provided, was raised[17-19].

According to the guidelines of American Heart Association (AHA) in 2004, corticosteroids treatment could be recommended for children in whom ⩾ 2 infusions of IVIG have been ineffective in alleviating the fever and acute inflammation[13]. However, corticosteroids have been occasionally used more early as the second line therapy for patients unresponsive to initial IVIG treatment, as the routine first line therapy in combination with IVIG, or as the first line therapy in combination with IVIG for selected Kawasaki disease patients at a high risk of unresponsiveness to initial IVIG.

THE EXCLUSIVE USE OF CORTICOSTEROIDS IN PATIENTS UNRESPONSIVE TO IVIG TREATMENT

The best second line therapeutic methods for patients unresponsive to initial IVIG treatment is still uncertain. In an investigation of 5633 patients with Kawasaki disease in the United States, methylprednisolone was used as the second line therapy in 196 patients (27.1%) among the 722 patients unresponsive to initial IVIG[20]. IVIG was the second line drug of choice in 466 patients (64.5%) in this investigation. A nationwide survey in Japan showed that steroids were used exclusively in 2.0% of hospitals and that they were used with additional IVIG in 5.1% of hospitals as the second line therapy for patients unresponsive to initial IVIG[21]. Additional IVIG exclusive administration was the second line treatment of choice in 464 hospitals (44.1%) and a combination of additional IVIG and another drug was selected in another 26% of hospitals in this survey. Therefore, the most common second line treatment is additional IVIG administration currently.

Despite initial IVIG treatment, 6.8%-38.3% of patients are unresponsive to it[22-36] and are at a higher risk for coronary artery lesions[30-33,37]. A study based on the United States national database showed that the resistance rate to initial IVIG therapy was 16.3% (hospital range 8.0%-26.8%)[36]. Authors suggested that highly variable rates among pediatric hospitals are possibly associated with variable diagnostic and treatment patterns at individual hospitals[36]. The rate of resistance to second additional IVIG only treatment was 22.2%-48.6%[18,22,24-26,38], and was not lower than that to initial IVIG treatment. Therefore, a consideration of another therapeutic option in patients unresponsive to the initial IVIG treatment is reasonable, and corticosteroids have been considered as an alternative treatment. Several reports of the use of corticosteroids as a treatment in Kawasaki disease patients unresponsive to initial IVIG treatment are presented in Table 1. In these studies, 164-411 patients with Kawasaki disease were observed, and the rate of unresponsiveness to initial IVIG was 13.4%-18.0%. The definition of unresponsiveness is varied by institute. Persistent fever was used commonly as the definition, but the cut-off level of body temperature, the duration of observation for recrudescent fever, and whether or not the CRP level was used were different for each institute. The duration of observation for recrudescent fever is 36 h according to the definition of the AHA[13], and 24 h was suggested in the recent Japanese guideline[39]. Intravenous methylprednisolone pulse therapy for 3 d was applied in all studies[22-26,40]. The dose was 30 mg/kg per day in most of studies[22-24,26,40], except in one[25]. Oral administration of prednisolone was followed after pulse therapy in 3 studies[22,24,26]. In these studies[22-25,40], a comparative analysis between corticosteroid therapy and additional IVIG treatment was performed and showed no significant difference with respect to the occurrence of coronary artery aneurysms. The frequencies of adverse effects of corticosteroids seemed to be relatively higher in reports by Miura *et al*[26,40]. They defined hypothermia as < 35.0 ℃; bradycardia as a heart rate less than the second percentile of the normal standard; hypertension as a systolic/diastolic blood pressure > 95th percentile of normal standard; hyperglycemia as a fasting blood glucose > 6.99 mmol/L; and hyponatremia as a serum Na^+ level < 135 mmol/L[26]. Although any serious adverse

Table 1 Re-treatment with corticosteroids or additional intravenous immunoglobulin in Kawasaki disease patients unresponsive to initial intravenous immunoglobulin

Ref.	No. of patients with KD	Definition of unresponsiveness: BT, obs period, other	No. of patients unresponsive to initial IVIG	Stage of CS Tx	Regimen	No. of patients re-Tx	Tx day after fever onset[1]	No. of patients with response	No. of patients with CAA	No. of patients with adverse effects
[22]	411	36 h after IVIG	63	2nd line	IVMP 30 mg/kg per day, 3 d Followed Pd	44	7 (6-8)	34	5	Hypertension 5, hypothermia 3, bradycardia 3, transient paralysis 1
					IVIG 1-2 g/kg	19	8 (5-11)	12	2	
[40]	NA	⩾ 37.5 ℃, 48 h after IVIG	22	2nd line	IVMP 30 mg/kg per day, 3 d	11	NA	NA	2	Hypertension 10, hypothermia 1, bradycardia 9, hyperglycemia 6, aPTT↓ 3
					IVIG 2 g/kg	11	NA	NA	3	
[23]	164	⩾ 37.5 ℃, 36-48 h after IVIG CRP↓ ⩽ 50%	27	2nd line	IVMP 30 mg/kg per day, 3 d	13	7 ± 1.3	NA	0	Bradycardia 2
					IVIG 2 g/kg	14	8 ± 2.4	NA	3	
[24]	237	⩾ 38 ℃, 36 h after IVIG 37.5 ℃-38 ℃ and CRP ↓ ⩽ 50%	41	2nd line	IVMP 30 mg/kg per day, 3 d Followed Pd	14	7 (7-9)	7	5	Gastrointestinal bleeding 1
					IVIG 2 g/kg	27	8 (5-14)	21	7	
[25]	262	⩾ 37.5 ℃, 48 h after IVIG CRP↓ ⩽ 50%	35	3rd line	IVMP 20 mg/kg per day, 3 d	9	NA	NA	7	NA
					IVIG 1 g/kg	8	NA	NA	5	
[26]	412	48 h after IVIG	74	3rd line	IVMP 30 mg/kg per day, 3 d Followed Pd	21	8 (IQR 8-9)	21	2	Hypertension 17, hypothermia 3, bradycardia 17, hyperglycemia 7, serum Na↓ 4

[1]Median (range), median (IQR), or mean ± SD. IVIG: Intravenous immunoglobulin; KD: Kawasaki disease; BT: Body temperature; obs: Observation; Tx: Treatment; CS: Corticosteroids; CAA: Coronary artery aneurysm; NA: Not available; IVMP: Intravenous methylprednisolone pulse; Pd: Oral prednisolone; IQR: Interquartile range.

Table 2 Risk scoring systems for the selection of patients expected to have unresponsiveness to initial intravenous immunoglobulin treatment

	Cut-off	Points
Kobayashi score (⩾ 4-5 points)[51,54,55]		
Age	⩽ 12 mo	1
Days of illness at initial treatment	⩽ 4	2
Platelet count	⩽ 300 × 10^3/mm^3	1
Neutrophil	⩾ 80%	2
CRP	⩾ 10 mg/dL	1
AST	⩾ 100 IU/L	2
Sodium	⩽ 133 mmol/L	2
Egami score (⩾ 3 points)[52]		
Age	⩽ 6 mo	1
Days of illness at initial treatment	⩽ 4	1
Platelet count	⩽ 300 × 10^3/mm^3	1
CRP	⩾ 8 mg/dL	1
ALT	⩾ 80 IU/L	2
Sano score (⩾ 2 points)[53]		
CRP	⩾ 7 mg/dL	1
AST	⩾ 200 IU/L	1
Total bilirubin	⩾ 0.9 mg/dL	1

IVIG: Intravenous immunoglobulin; CRP: C-reactive protein; AST: Aspartate aminotransferase; ALT: Alanine aminotransferase.

effects of corticosteroids inducing irreversible organ damage have not been reported in these studies[22-26,40], a close monitoring of vital signs, blood glucose level, and serum electrolytes level and supportive administration of medications – heparin infusion (15-20 units/kg per hour) and H2 blocker are needed in Kawasaki disease patients receiving corticosteroids. Meanwhile, a high incidence of adrenal suppression which had resolved within 6 mo was reported in patients treated with corticosteroids[41]. In the view of the reduction of fever, corticosteroids seem to be more effective than IVIG[23,25,42]. However, Furukawa *et al*[22] warned of a tendency for recrudescent fever in patients unresponsive to corticosteroids, which could potentially delay the therapeutic decision-making process. Although Miura *et al*[26] suggested increasing the dose of oral prednisolone following third line pulse therapy for the patients with recrudescent fever, whether this strategy could be applied to second line therapy is currently unclear. In addition, the usefulness of corticosteroids in the view of their medical cost is controversial[23-25], and this issue may be dependent on the therapeutic strategy of an institute and on the health system of a society.

Table 3 Clinical and laboratory variables associated with the unresponsiveness to initial intravenous immunoglobulin treatment

	Risk factors	Ref.
Age	≤ 6-12 mo	[51,52,58]
Sex	Male	[33,61]
Duration of fever	Long duration	[58,69]
Days of illness at initial treatment	≤ 4	[31,33,51,52,58,60,71]
Recurrent Kawasaki disease	Recurrent case	[33]
Principal features/symptoms	Early appearance	[72]
	Polymorphous exanthema	[60]
	Lymphadenopathy	[32]
Other physical findings	Changes around anus	[60]
Brand of IVIG	β-propiolactone	[65,66]
Neutrophil	≥ 80%, or increased	[51,58,60,69,72]
Band form	≥ 20%, or increased	[31,34]
Hemoglobin	Anemia by age, < 10 g/dL	[31,59]
Eosinophil count	High level – good response	[68]
Platelet count	≤ 300 × 10^3/mm^3, or decreased	[51,52,58,72]
	≥ 530 × 10^3/mm^3	[32]
ESR	≥ 75 mm/h, or increased	[32,37]
CRP	≥ 7-10 mg/dL, or increased	[51-53,58-60,69]
Albumin	Lower than normal	[34,61,67]
ALT	≥ 80-84 IU/L	[52,62]
AST	≥ 100-200 IU/L, or increased	[51,53,61,72]
Total bilirubin	≥ 0.9 mg/dL, or increased	[53,62,72]
γGlutamyl transferase	≥ 60 IU/L	[31]
Lactate dehydrogenase	> 590 IU/L	[59]
Sodium	≤ 133 mmol/L	[51]
Imaging studies	Sonographic GB abnormalities	[70]

IVIG: Intravenous immunoglobulin; ESR: Erythrocyte sedimentation rate; CRP: C-reactive protein; NT-proBNP: N-terminal fragment of B-type natriuretic peptide; GB: Gall bladder.

There has been no confirmative evidence of a better usefulness of corticosteroids as the second line treatment compared to additional IVIG. The combination of corticosteroids and additional IVIG as the second line therapy needs further study to confirm its efficacy, in spite of small group study[43] supporting it. By the way, this combination has been tried more frequently as the first line treatment instead.

THE USE OF CORTICOSTEROIDS IN COMBINATION WITH IVIG AS THE ROUTINE FIRST LINE TREATMENT

By about the year 2000, the combination of corticosteroids and IVIG as the first line therapy was reported shortening the duration of fever and/or reducing the severity of systemic inflammation[44-46]. Okada *et al*[46] reported that the levels of cytokines were lower, the duration of fever was shorter, and the C-reactive protein level decreased more quickly in the patient group who underwent the combination treatment than in the patient group who underwent IVIG treatment only. This result implicates a more rapid reduction of inflammatory reactions in the combination treatment. Wooditch *et al*[47] reported that the inclusion of corticosteroids in aspirin-containing regimens with or without IVIG for the first line treatment of Kawasaki disease reduces the incidence of coronary aneurysms in their meta-analysis. In addition, Inoue *et al*[48] reported that the combination of corticosteroids and IVIG as the first line therapy improved the clinical course and coronary artery outcome in their multicenter prospective study with 178 patients. However, the result of a multicenter randomized double-blind placebo-controlled study by Newburger *et al*[49], in which a single dose of methylprednisolone (30 mg/kg) was administrated did not agree with the result by Inoue *et al*[48] The result of another study of 216 patients in which dexamethasone (0.3 mg/kg per day for 3 d) was combined with IVIG showed no significant difference of coronary outcomes between groups[50]. Therefore, it is less likely that the administration of corticosteroids in combination with IVIG as the routine first line therapy in all Kawasaki disease patients reduces coronary artery lesions. However, further studies to determine the most appropriate regimen of corticosteroids should be needed, because the duration of the administration of corticosteroids (prednisolone was selected) including the period of tapering seems to be longer in studies which reported the efficacy of the combination therapy[45,46,48].

THE USE OF CORTICOSTEROIDS IN COMBINATION WITH IVIG AS THE FIRST LINE TREATMENT IN SELECTED PATIENTS

Another strategy of a use of corticosteroids in Kawasaki

disease patients is their administration in combination with IVIG in selected patients who are expected to be unresponsive to initial IVIG treatment. Three risk scoring systems for the selection of patients were proposed in Japan (Table 2)[51-53]. The cut-off level of the sum of points in the Kobayashi scoring was changed from ⩾ 4 points[51] to ⩾ 5 points[39,54,55]. The sensitivity and the specificity for predicting initial IVIG unresponsiveness were 86% and 68% in the Kobayashi scoring model, 78% and 76% in the Egami scoring model, and 77% and 86% in the Sano scoring model, respectively, according to the reports by their respective creators[51-53]. There were following reports showing the efficacy of these three scoring systems[54-57]. The other predictive scoring systems have had no subsequent studies to show their usefulness, or are based on a small number of subjects[31,58-60]. Kobayashi *et al*[51] suggested four different points of their study from the study by Newburger *et al*[49]: the time to start a treatment was 2 d earlier in their study, a the longer duration of the administration of corticosteroids, the selection of patients with a high risk of unresponsiveness to initial IVIG treatment, and the ethnic homogeneity of their subjects[54]. The selection criteria of patients at a high risk have been the most hot issue until recently. The efficacy of the Japanese scoring systems has been tested in other institutes. However, satisfactory results have not been achieved, and an especially low sensitivity has been reported[43,60-63]. The sensitivity and the specificity of the Kobayashi scoring system were 33%-60% and 35%-87%[43,60-63], those of the Egami scoring system were 21.4%-57% and 77%-86.6%[60-62], and those of the Sano scoring system were 40%-60% and 85%-90%[61,62], respectively. These results suggest refinement of the Japanese scoring systems is needed before they can be used effectively. In addition, one recent study whose subjects were patients with incomplete Kawasaki disease, showed that the proportion of patients identified as being at high-risk for IVIG resistance using three Japanese scoring systems were not significantly different between the IVIG resistance group and the IVIG responsive group[64].

Many clinical/laboratory variables have been reported as the predictors of the unresponsiveness to initial IVIG treatment (Table 3)[31-34,37,51-53,58-62,65-73]. The diversity of predictors might be one reason of the low sensitivity of the proposed risk scoring systems. The biomarkers and the genetic variants also have been investigated as the predictors. However, there has been no report in which any aggressive therapy prevented coronary artery lesions in patients at high risk of unresponsiveness predicted by biomarkers and genetic variants. For more information about studies of biomarkers and genetic variants, two recent reviews are informative[74,75].

More-aggressive initial treatment for patients at a high risk of IVIG unresponsiveness after risk stratification using a predictive model has been recommended in the recently updated guidelines for the medical treatment of acute Kawasaki disease in Japan[39]. Future investigations to determine the best predictive model to use are necessary.

CONCLUSION

It is uncertain that the corticosteroids as the second line treatment are better than the additional treatment of IVIG in Kawasaki disease patients unresponsive to initial IVIG. It is also uncertain that the combination of corticosteroids and IVIG is better than the initial IVIG only treatment as the routine first line therapy during the acute phase. The therapeutic strategy that an aggressive treatment including the combination of corticosteroids and IVIG is needed in patients at high risk of unresponsiveness to initial IVIG treatment, is properly reasonable. Future investigations to determine the best predictive model for the unresponsiveness are necessary.

REFERENCES

1 **Kawasaki T**. [Acute febrile mucocutaneous syndrome with lymphoid involvement with specific desquamation of the fingers and toes in children]. *Arerugi* 1967; **16**: 178-222 [PMID: 6062087]

2 **Lehmann C**, Klar R, Lindner J, Lindner P, Wolf H, Gerling S. Kawasaki disease lacks association with human coronavirus NL63 and human bocavirus. *Pediatr Infect Dis J* 2009; **28**: 553-554 [PMID: 19504744]

3 **Kim JH**, Yu JJ, Lee J, Kim MN, Ko HK, Choi HS, Kim YH, Ko JK. Detection rate and clinical impact of respiratory viruses in children with Kawasaki disease. *Korean J Pediatr* 2012; **55**: 470-473 [PMID: 23300502 DOI: 10.3345/kjp.2012.55.12.470]

4 **Rowley AH**, Baker SC, Shulman ST, Rand KH, Tretiakova MS, Perlman EJ, Garcia FL, Tajuddin NF, Fox LM, Huang JH, Ralphe JC, Takahashi K, Flatow J, Lin S, Kalelkar MB, Soriano B, Orenstein JM. Ultrastructural, immunofluorescence, and RNA evidence support the hypothesis of a "new" virus associated with Kawasaki disease. *J Infect Dis* 2011; **203**: 1021-1030 [PMID: 21402552 DOI: 10.1093/infdis/jiq136]

5 **Rodó X**, Curcoll R, Robinson M, Ballester J, Burns JC, Cayan DR, Lipkin WI, Williams BL, Couto-Rodriguez M, Nakamura Y, Uehara R, Tanimoto H, Morguí JA. Tropospheric winds from northeastern China carry the etiologic agent of Kawasaki disease from its source to Japan. *Proc Natl Acad Sci USA* 2014; **111**: 7952-7957 [PMID: 24843117 DOI: 10.1073/pnas.1400380111]

6 **Kim GB**, Park S, Kwon BS, Han JW, Park YW, Hong YM. Evaluation of the Temporal Association between Kawasaki Disease and Viral Infections in South Korea. *Korean Circ J* 2014; **44**: 250-254 [PMID: 25089137 DOI: 10.4070/kcj.2014.44.4.250]

7 **Chang LY**, Lu CY, Shao PL, Lee PI, Lin MT, Fan TY, Cheng AL, Lee WL, Hu JJ, Yeh SJ, Chang CC, Chiang BL, Wu MH, Huang LM. Viral infections associated with Kawasaki disease. *J Formos Med Assoc* 2014; **113**: 148-154 [PMID: 24495555 DOI: 10.1016/j.jfma.2013.12.008]

8 **Xing Y**, Wang H, Liu X, Yu X, Chen R, Wang C, Yu X, Sun L. Meta-analysis of the relationship between single nucleotide polymorphism rs72689236 of caspase-3 and Kawasaki disease. *Mol Biol Rep* 2014; **41**: 6377-6381 [PMID: 24990693 DOI: 10.1007/s11033-014-3517-7]

9 **Chatzikyriakidou A**, Aidinidou L, Giannopoulos A, Papadopoulou-Legbelou K, Kalinderi K, Fidani L. Absence of association of FCGR2A gene polymorphism rs1801274 with Kawasaki disease in Greek patients. *Cardiol Young* 2015; **25**: 681-683 [PMID: 24775607 DOI: 10.1017/S1047951114000626]

10 **Lou J**, Zhong R, Shen N, Lu XZ, Ke JT, Duan JY, Qi YQ, Wang YJ,

Zhang Q, Wang W, Gong FQ, Miao XP. Systematic confirmation study of GWAS-identified genetic variants for Kawasaki disease in a Chinese population. *Sci Rep* 2015; **5**: 8194 [PMID: 25645453 DOI: 10.1038/srep08194]

11 **Chang CJ**, Kuo HC, Chang JS, Lee JK, Tsai FJ, Khor CC, Chang LC, Chen SP, Ko TM, Liu YM, Chen YJ, Hong YM, Jang GY, Hibberd ML, Kuijpers T, Burgner D, Levin M, Burns JC, Davila S, Chen YT, Chen CH, Wu JY, Lee YC. Replication and meta-analysis of GWAS identified susceptibility loci in Kawasaki disease confirm the importance of B lymphoid tyrosine kinase (BLK) in disease susceptibility. *PLoS One* 2013; **8**: e72037 [PMID: 24023612 DOI: 10.1371/journal.pone.0072037]

12 **Yoon KL**. Update of genetic susceptibility in patients with Kawasaki disease. *Korean J Pediatr* 2015; **58**: 84-88 [PMID: 25861330 DOI: 10.3345/kjp.2015.58.3.84]

13 **Newburger JW**, Takahashi M, Gerber MA, Gewitz MH, Tani LY, Burns JC, Shulman ST, Bolger AF, Ferrieri P, Baltimore RS, Wilson WR, Baddour LM, Levison ME, Pallasch TJ, Falace DA, Taubert KA. Diagnosis, treatment, and long-term management of Kawasaki disease: a statement for health professionals from the Committee on Rheumatic Fever, Endocarditis, and Kawasaki Disease, Council on Cardiovascular Disease in the Young, American Heart Association. *Pediatrics* 2004; **114**: 1708-1733 [PMID: 15574639]

14 **Kato H**, Koike S, Yokoyama T. Kawasaki disease: effect of treatment on coronary artery involvement. *Pediatrics* 1979; **63**: 175-179 [PMID: 440805]

15 **Kijima Y**, Kamiya T, Suzuki A, Hirose O, Manabe H. A trial procedure to prevent aneurysm formation of the coronary arteries by steroid pulse therapy in Kawasaki disease. *Jpn Circ J* 1982; **46**: 1239-1242 [PMID: 7131714]

16 **Furusho K**, Kamiya T, Nakano H, Kiyosawa N, Shinomiya K, Hayashidera T, Tamura T, Hirose O, Manabe Y, Yokoyama T. High-dose intravenous gammaglobulin for Kawasaki disease. *Lancet* 1984; **2**: 1055-1058 [PMID: 6209513]

17 **Wright DA**, Newburger JW, Baker A, Sundel RP. Treatment of immune globulin-resistant Kawasaki disease with pulsed doses of corticosteroids. *J Pediatr* 1996; **128**: 146-149 [PMID: 8551407]

18 **Wallace CA**, French JW, Kahn SJ, Sherry DD. Initial intravenous gammaglobulin treatment failure in Kawasaki disease. *Pediatrics* 2000; **105**: E78 [PMID: 10835091]

19 **Dale RC**, Saleem MA, Daw S, Dillon MJ. Treatment of severe complicated Kawasaki disease with oral prednisolone and aspirin. *J Pediatr* 2000; **137**: 723-726 [PMID: 11060542]

20 **Ghelani SJ**, Pastor W, Parikh K. Demographic and treatment variability of refractory kawasaki disease: a multicenter analysis from 2005 to 2009. *Hosp Pediatr* 2012; **2**: 71-76 [PMID: 24510952 DOI: 10.1542/hpeds.2011-00112]

21 **Uehara R**, Yashiro M, Oki I, Nakamura Y, Yanagawa H. Re-treatment regimens for acute stage of Kawasaki disease patients who failed to respond to initial intravenous immunoglobulin therapy: analysis from the 17th nationwide survey. *Pediatr Int* 2007; **49**: 427-430 [PMID: 17587262]

22 **Furukawa T**, Kishiro M, Akimoto K, Nagata S, Shimizu T, Yamashiro Y. Effects of steroid pulse therapy on immunoglobulin-resistant Kawasaki disease. *Arch Dis Child* 2008; **93**: 142-146 [PMID: 17962370]

23 **Ogata S**, Bando Y, Kimura S, Ando H, Nakahata Y, Ogihara Y, Kaneko T, Minoura K, Kaida M, Yokota Y, Furukawa S, Ishii M. The strategy of immune globulin resistant Kawasaki disease: a comparative study of additional immune globulin and steroid pulse therapy. *J Cardiol* 2009; **53**: 15-19 [PMID: 19167633 DOI: 10.1016/j.jjcc.2008.08.002]

24 **Teraguchi M**, Ogino H, Yoshimura K, Taniuchi S, Kino M, Okazaki H, Kaneko K. Steroid pulse therapy for children with intravenous immunoglobulin therapy-resistant Kawasaki disease: a prospective study. *Pediatr Cardiol* 2013; **34**: 959-963 [PMID: 23184018 DOI: 10.1007/s00246-012-0589-9]

25 **Hashino K**, Ishii M, Iemura M, Akagi T, Kato H. Re-treatment for immune globulin-resistant Kawasaki disease: a comparative study of additional immune globulin and steroid pulse therapy. *Pediatr Int* 2001; **43**: 211-217 [PMID: 11380911]

26 **Miura M**, Tamame T, Naganuma T, Chinen S, Matsuoka M, Ohki H. Steroid pulse therapy for Kawasaki disease unresponsive to additional immunoglobulin therapy. *Paediatr Child Health* 2011; **16**: 479-484 [PMID: 23024586]

27 **Durongpisitkul K**, Soongswang J, Laohaprasitiporn D, Nana A, Prachuabmoh C, Kangkagate C. Immunoglobulin failure and retreatment in Kawasaki disease. *Pediatr Cardiol* 2003; **24**: 145-148 [PMID: 12457253]

28 **Han RK**, Silverman ED, Newman A, McCrindle BW. Management and outcome of persistent or recurrent fever after initial intravenous gamma globulin therapy in acute Kawasaki disease. *Arch Pediatr Adolesc Med* 2000; **154**: 694-699 [PMID: 10891021]

29 **Kashef S**, Safari M, Amin R. Initial intravenous gamma-globulin treatment failure in Iranian children with Kawasaki disease. *Kaohsiung J Med Sci* 2005; **21**: 401-404 [PMID: 16248123]

30 **Burns JC**, Capparelli EV, Brown JA, Newburger JW, Glode MP. Intravenous gamma-globulin treatment and retreatment in Kawasaki disease. US/Canadian Kawasaki Syndrome Study Group. *Pediatr Infect Dis J* 1998; **17**: 1144-1148 [PMID: 9877364]

31 **Tremoulet AH**, Best BM, Song S, Wang S, Corinaldesi E, Eichenfield JR, Martin DD, Newburger JW, Burns JC. Resistance to intravenous immunoglobulin in children with Kawasaki disease. *J Pediatr* 2008; **153**: 117-121 [PMID: 18571548 DOI: 10.1016/j.jpeds.2007.12.021]

32 **Wei M**, Huang M, Chen S, Huang G, Huang M, Qiu D, Guo Z, Jiang J, Zhou X, Yu Q, Guo Y, Fu L, Gao W, Li F. A Multicenter Study of Intravenous Immunoglobulin Non-response in Kawasaki Disease. *Pediatr Cardiol* 2015; **36**: 1166-1172 [PMID: 25812827]

33 **Uehara R**, Belay ED, Maddox RA, Holman RC, Nakamura Y, Yashiro M, Oki I, Ogino H, Schonberger LB, Yanagawa H. Analysis of potential risk factors associated with nonresponse to initial intravenous immunoglobulin treatment among Kawasaki disease patients in Japan. *Pediatr Infect Dis J* 2008; **27**: 155-160 [PMID: 18174868 DOI: 10.1097/INF.0b013e31815922b5]

34 **Ashouri N**, Takahashi M, Dorey F, Mason W. Risk factors for nonresponse to therapy in Kawasaki disease. *J Pediatr* 2008; **153**: 365-368 [PMID: 18534243 DOI: 10.1016/j.jpeds.2008.03.014]

35 **Nakada T**. Effects of anti-inflammatory drugs on intravenous immunoglobulin therapy in the acute phase of Kawasaki disease. *Pediatr Cardiol* 2015; **36**: 335-339 [PMID: 25158631 DOI: 10.1007/s00246-014-1010-7]

36 **Moffett BS**, Syblik D, Denfield S, Altman C, Tejtel-Sexson K. Epidemiology of immunoglobulin resistant kawasaki disease: results from a large, national database. *Pediatr Cardiol* 2015; **36**: 374-378 [PMID: 25179461 DOI: 10.1007/s00246-014-1016-1]

37 **Sittiwangkul R**, Pongprot Y, Silvilairat S, Phornphutkul C. Management and outcome of intravenous gammaglobulin-resistant Kawasaki disease. *Singapore Med J* 2006; **47**: 780-784 [PMID: 16924360]

38 **Suzuki H**, Terai M, Hamada H, Honda T, Suenaga T, Takeuchi T, Yoshikawa N, Shibuta S, Miyawaki M, Oishi K, Yamaga H, Aoyagi N, Iwahashi S, Miyashita R, Onouchi Y, Sasago K, Suzuki Y, Hata A. Cyclosporin A treatment for Kawasaki disease refractory to initial and additional intravenous immunoglobulin. *Pediatr Infect Dis J* 2011; **30**: 871-876 [PMID: 21587094 DOI: 10.1097/INF.0b013e318220c3cf]

39 **Research Committee of the Japanese Society of Pediatric Cardiology**, Cardiac Surgery Committee for Development of Guidelines for Medical Treatment of Acute Kawasaki Disease. Guidelines for medical treatment of acute Kawasaki disease: report of the Research Committee of the Japanese Society of Pediatric Cardiology and Cardiac Surgery (2012 revised version). *Pediatr Int* 2014; **56**: 135-158 [PMID: 24730626 DOI: 10.1111/ped.12317]

40 **Miura M**, Ohki H, Yoshiba S, Ueda H, Sugaya A, Satoh M, Yamagishi H. Adverse effects of methylprednisolone pulse therapy in refractory Kawasaki disease. *Arch Dis Child* 2005; **90**: 1096-1097 [PMID: 16177169]

41 **Goto M**, Miyagawa N, Kikunaga K, Miura M, Hasegawa Y. High incidence of adrenal suppression in children with Kawasaki disease

treated with intravenous immunoglobulin plus prednisolone. *Endocr J* 2015; **62**: 145-151 [PMID: 25342092 DOI: 10.1507/endocrj.EJ14-0385]

42 **Yang X**, Liu G, Huang Y, Chen S, Du J, Jin H. A meta-analysis of re-treatment for intravenous immunoglobulin-resistant Kawasaki disease. *Cardiol Young* 2015; **25**: 1182-1190 [PMID: 25597708]

43 **Jibiki T**, Kato I, Shiohama T, Abe K, Anzai S, Takeda N, Yamaguchi K, Kanazawa M, Kurosaki T. Intravenous immune globulin plus corticosteroids in refractory Kawasaki disease. *Pediatr Int* 2011; **53**: 729-735 [PMID: 21342358 DOI: 10.1111/j.1442-200X.2011.03338.x]

44 **Sundel RP**, Baker AL, Fulton DR, Newburger JW. Corticosteroids in the initial treatment of Kawasaki disease: report of a randomized trial. *J Pediatr* 2003; **142**: 611-616 [PMID: 12838187]

45 **Shinohara M**, Sone K, Tomomasa T, Morikawa A. Corticosteroids in the treatment of the acute phase of Kawasaki disease. *J Pediatr* 1999; **135**: 465-469 [PMID: 10518080]

46 **Okada Y**, Shinohara M, Kobayashi T, Inoue Y, Tomomasa T, Kobayashi T, Morikawa A. Effect of corticosteroids in addition to intravenous gamma globulin therapy on serum cytokine levels in the acute phase of Kawasaki disease in children. *J Pediatr* 2003; **143**: 363-367 [PMID: 14517521]

47 **Wooditch AC**, Aronoff SC. Effect of initial corticosteroid therapy on coronary artery aneurysm formation in Kawasaki disease: a meta-analysis of 862 children. *Pediatrics* 2005; **116**: 989-995 [PMID: 16199713]

48 **Inoue Y**, Okada Y, Shinohara M, Kobayashi T, Kobayashi T, Tomomasa T, Takeuchi K, Morikawa A. A multicenter prospective randomized trial of corticosteroids in primary therapy for Kawasaki disease: clinical course and coronary artery outcome. *J Pediatr* 2006; **149**: 336-341 [PMID: 16939743]

49 **Newburger JW**, Sleeper LA, McCrindle BW, Minich LL, Gersony W, Vetter VL, Atz AM, Li JS, Takahashi M, Baker AL, Colan SD, Mitchell PD, Klein GL, Sundel RP. Randomized trial of pulsed corticosteroid therapy for primary treatment of Kawasaki disease. *N Engl J Med* 2007; **356**: 663-675 [PMID: 17301297]

50 **Lim YJ**, Jung JW. Clinical outcomes of initial dexamethasone treatment combined with a single high dose of intravenous immunoglobulin for primary treatment of Kawasaki disease. *Yonsei Med J* 2014; **55**: 1260-1266 [PMID: 25048483 DOI: 10.3349/ymj.2014.55.5.1260]

51 **Kobayashi T**, Inoue Y, Takeuchi K, Okada Y, Tamura K, Tomomasa T, Kobayashi T, Morikawa A. Prediction of intravenous immunoglobulin unresponsiveness in patients with Kawasaki disease. *Circulation* 2006; **113**: 2606-2612 [PMID: 16735679 DOI: 10.1161/CIRCULATIONAHA.105.592865]

52 **Egami K**, Muta H, Ishii M, Suda K, Sugahara Y, Iemura M, Matsuishi T. Prediction of resistance to intravenous immunoglobulin treatment in patients with Kawasaki disease. *J Pediatr* 2006; **149**: 237-240 [PMID: 16887442]

53 **Sano T**, Kurotobi S, Matsuzaki K, Yamamoto T, Maki I, Miki K, Kogaki S, Hara J. Prediction of non-responsiveness to standard high-dose gamma-globulin therapy in patients with acute Kawasaki disease before starting initial treatment. *Eur J Pediatr* 2007; **166**: 131-137 [PMID: 16896641]

54 **Kobayashi T**, Saji T, Otani T, Takeuchi K, Nakamura T, Arakawa H, Kato T, Hara T, Hamaoka K, Ogawa S, Miura M, Nomura Y, Fuse S, Ichida F, Seki M, Fukazawa R, Ogawa C, Furuno K, Tokunaga H, Takatsuki S, Hara S, Morikawa A. Efficacy of immunoglobulin plus prednisolone for prevention of coronary artery abnormalities in severe Kawasaki disease (RAISE study): a randomised, open-label, blinded-endpoints trial. *Lancet* 2012; **379**: 1613-1620 [PMID: 22405251 DOI: 10.1016/S0140-6736(11)61930-2]

55 **Kobayashi T**, Inoue Y, Otani T, Morikawa A, Kobayashi T, Takeuchi K, Saji T, Sonobe T, Ogawa S, Miura M, Arakawa H. Risk stratification in the decision to include prednisolone with intravenous immunoglobulin in primary therapy of Kawasaki disease. *Pediatr Infect Dis J* 2009; **28**: 498-502 [PMID: 19504733]

56 **Ogata S**, Ogihara Y, Honda T, Kon S, Akiyama K, Ishii M. Corticosteroid pulse combination therapy for refractory Kawasaki disease: a randomized trial. *Pediatrics* 2012; **129**: e17-e23 [PMID: 22144699 DOI: 10.1542/peds.2011-0148]

57 **Okada K**, Hara J, Maki I, Miki K, Matsuzaki K, Matsuoka T, Yamamoto T, Nishigaki T, Kurotobi S, Sano T. Pulse methylprednisolone with gammaglobulin as an initial treatment for acute Kawasaki disease. *Eur J Pediatr* 2009; **168**: 181-185 [PMID: 18446365 DOI: 10.1007/s00431-008-0727-9]

58 **Seki M**, Kobayashi T, Kobayashi T, Morikawa A, Otani T, Takeuchi K, Ayusawa M, Tsuchiya K, Yasuda K, Suzuki T, Shimoyama S, Ikeda K, Ishii Y, Arakawa H. External validation of a risk score to predict intravenous immunoglobulin resistance in patients with kawasaki disease. *Pediatr Infect Dis J* 2011; **30**: 145-147 [PMID: 20802375 DOI: 10.1097/INF.0b013e3181f386db]

59 **Fukunishi M**, Kikkawa M, Hamana K, Onodera T, Matsuzaki K, Matsumoto Y, Hara J. Prediction of non-responsiveness to intravenous high-dose gamma-globulin therapy in patients with Kawasaki disease at onset. *J Pediatr* 2000; **137**: 172-176 [PMID: 10931407]

60 **Fu PP**, Du ZD, Pan YS. Novel predictors of intravenous immunoglobulin resistance in Chinese children with Kawasaki disease. *Pediatr Infect Dis J* 2013; **32**: e319-e323 [PMID: 23446442 DOI: 10.1097/INF.0b013e31828e887f]

61 **Sleeper LA**, Minich LL, McCrindle BM, Li JS, Mason W, Colan SD, Atz AM, Printz BF, Baker A, Vetter VL, Newburger JW. Evaluation of Kawasaki disease risk-scoring systems for intravenous immunoglobulin resistance. *J Pediatr* 2011; **158**: 831-835.e3 [PMID: 21168857 DOI: 10.1016/j.jpeds.2010.10.031]

62 **Park HM**, Lee DW, Hyun MC, Lee SB. Predictors of nonresponse to intravenous immunoglobulin therapy in Kawasaki disease. *Korean J Pediatr* 2013; **56**: 75-79 [PMID: 23482814 DOI: 10.3345/kjp.2013.56.2.75]

63 **Davies S**, Sutton N, Blackstock S, Gormley S, Hoggart CJ, Levin M, Herberg JA. Predicting IVIG resistance in UK Kawasaki disease. *Arch Dis Child* 2015; **100**: 366-368 [PMID: 25670405 DOI: 10.1136/archdischild-2014-307397]

64 **Kanamitsu K**, Kakimoto H, Shimada A, Nakata Y, Ochi H, Watanabe H, Iwasaki Y, Tokorodani C, Kanazawa A, Maruyama H, Miyazawa M, Nishiuchi R, Kikkawa K. Verification of risk scores to predict intravenous immunoglobulin resistance in incomplete Kawasaki disease. *Pediatr Int* 2015; Epub ahead of print [PMID: 26190225 DOI: 10.1111/ped.12755]

65 **Lin MC**, Fu YC, Jan SL, Lai MS. Comparative effectiveness of intravenous immunoglobulin for children with Kawasaki disease: a nationwide cohort study. *PLoS One* 2013; **8**: e63399 [PMID: 23650564 DOI: 10.1371/journal.pone.0063399]

66 **Tsai MH**, Huang YC, Yen MH, Li CC, Chiu CH, Lin PY, Lin TY, Chang LY. Clinical responses of patients with Kawasaki disease to different brands of intravenous immunoglobulin. *J Pediatr* 2006; **148**: 38-43 [PMID: 16423595]

67 **Kuo HC**, Liang CD, Wang CL, Yu HR, Hwang KP, Yang KD. Serum albumin level predicts initial intravenous immunoglobulin treatment failure in Kawasaki disease. *Acta Paediatr* 2010; **99**: 1578-1583 [PMID: 20491705 DOI: 10.1111/j.1651-2227.2010.01875.x]

68 **Kuo HC**, Yang KD, Liang CD, Bong CN, Yu HR, Wang L, Wang CL. The relationship of eosinophilia to intravenous immunoglobulin treatment failure in Kawasaki disease. *Pediatr Allergy Immunol* 2007; **18**: 354-359 [PMID: 17584314 DOI: 10.1111/j.1399-3038.2007.00516.x]

69 **Hwang JY**, Lee KY, Rhim JW, Youn YS, Oh JH, Han JW, Lee JS, Burgner D. Assessment of intravenous immunoglobulin non-responders in Kawasaki disease. *Arch Dis Child* 2011; **96**: 1088-1090 [PMID: 20551193 DOI: 10.1136/adc.2010.184101]

70 **Chen CJ**, Huang FC, Tiao MM, Huang YH, Lin LY, Yu HR, Yang KD, Huang YC, Chen CC, Chang WC, Kuo HC. Sonographic gallbladder abnormality is associated with intravenous immunoglobulin resistance in Kawasaki disease. *ScientificWorldJournal* 2012; **2012**: 485758 [PMID: 22792043 DOI: 10.1100/2012/485758]

71 **Muta H**, Ishii M, Egami K, Furui J, Sugahara Y, Akagi T, Nakamura Y, Yanagawa H, Matsuishi T. Early intravenous gamma-globulin treatment for Kawasaki disease: the nationwide surveys

in Japan. *J Pediatr* 2004; **144**: 496-499 [PMID: 15069399 DOI: 10.1016/j.jpeds.2003.12.033]

72 **Cha S**, Yoon M, Ahn Y, Han M, Yoon KL. Risk factors for failure of initial intravenous immunoglobulin treatment in Kawasaki disease. *J Korean Med Sci* 2008; **23**: 718-722 [PMID: 18756064 DOI: 10.3346/jkms.2008.23.4.718]

73 **Tajima M**, Shiozawa Y, Kagawa J. Early Appearance of Principal Symptoms of Kawasaki Disease is a Risk Factor for Intravenous Immunoglobulin Resistance. *Pediatr Cardiol* 2015; **36**: 1159-1165 [PMID: 25753685]

74 **Kuo HC**, Hsu YW, Wu MS, Chien SC, Liu SF, Chang WC. Intravenous immunoglobulin, pharmacogenomics, and Kawasaki disease. *J Microbiol Immunol Infect* 2014; Epub ahead of print [PMID: 25556045 DOI: 10.1016/j.jmii.2014.11.001]

75 **Wakiguchi H**, Hasegawa S, Suzuki Y, Kudo K, Ichiyama T. Relationship between T-cell HLA-DR expression and intravenous immunoglobulin treatment response in Kawasaki disease. *Pediatr Res* 2015; **77**: 536-540 [PMID: 25580740 DOI: 10.1038/pr.2015.12]

P- Reviewer: Gonzalez-Granado LI, Toubi E
S- Editor: Ji FF **L- Editor**: A **E- Editor**: Jiao XK

World Journal of Clinical Pediatrics

Submit a Manuscript: http://www.wjgnet.com/esps/
Help Desk: http://www.wjgnet.com/esps/helpdesk.aspx
DOI: 10.5409/wjcp.v4.i4.143

World J Clin Pediatr 2015 November 8; 4(4): 143-147
ISSN 2219-2808 (online)
© 2015 Baishideng Publishing Group Inc. All rights reserved.

MINIREVIEWS

Limitations of urease test in diagnosis of pediatric *Helicobacter pylori* infection

Ji-Hyun Seo, Ji Sook Park, Kwang Ho Rhee, Hee-Shang Youn

Ji-Hyun Seo, Ji Sook Park, Hee-Shang Youn, Department of Pediatrics, Gyeongsang National Institute of Health Sciences, Gyeongsang National University School of Medicine, Jinju 52727, South Korea

Kwang Ho Rhee, Department of Microbiology, Gyeongsang National Institute of Health Sciences, Gyeongsang National University School of Medicine, Jinju 52727, South Korea

Author contributions: Seo JH wrote the paper; Seo JH, Park JS, Rhee KH, and Youn HS designed and reviewed the paper; Rhee KH and Youn HS had been several researches that were the bases for this paper.

Conflict-of-interest statement: Authors declare no conflict of interests for this article.

Open-Access: This article is an open-access article which was selected by an in-house editor and fully peer-reviewed by external reviewers. It is distributed in accordance with the Creative Commons Attribution Non Commercial (CC BY-NC 4.0) license, which permits others to distribute, remix, adapt, build upon this work non-commercially, and license their derivative works on different terms, provided the original work is properly cited and the use is non-commercial. See: http://creativecommons.org/licenses/by-nc/4.0/

Correspondence to: Hee-Shang Youn, MD, PhD, Department of Pediatrics, Gyeongsang National Institute of Health Sciences, Gyeongsang National University School of Medicine, 15, Jinju-daero 816beon-gil, Jinju 52727, South Korea. hsyoun@gnu.ac.kr
Telephone: +82-55-7508158
Fax: +82-55-7529339

Received: April 18, 2015
Peer-review started: April 21, 2015
First decision: August 5, 2015
Revised: September 1, 2015
Accepted: September 10, 2015
Article in press: September 16, 2015
Published online: November 8, 2015

Abstract

The diagnosis of *Helicobacter pylori* (*H. pylori*) infection is usually based on the results of urease test and histology. The urease test known as a simple and cheap method does not need special skills to perform or to read the result. The time needed for the test to turn positive depends on the concentration of bacteria, and the accuracy is up to the density of *H. pylori* density in the biopsy sample, which is generally lower in children than adolescents and adults. Therefore, there are debates about the sensitivity of the urease test in children. The reason for lower sensitivity of the urease test in children was not identified, but might be related to the low density and patchy distribution of bacteria. In this review, we discuss the limitations of the urease test in children according to age, histology, number of biopsy samples, and biopsy site. In children under 5 years old, the differences in positivity rate when the urease test used one or three biopsy samples, and samples from the antrum or the gastric body, were larger than those in children aged 5-15 years. Thus, three or more biopsy samples from both the antrum and body would improve the sensitivity of *H. pylori* infection diagnosis in children under 5 years old.

Key words: *Helicobacter pylori* infection; Urease test; Children

© The Author(s) 2015. Published by Baishideng Publishing Group Inc. All rights reserved.

Core tip: The diagnosis of *Helicobacter pylori* (*H. pylori*) infection is usually based on the findings of histology and the results of the urease test. However, the sensitivity of urease test in children was lower compared to adults. The lower sensitivity of urease test of children might be related to the low density and patchy distribution of bacteria. In urease test, three or more biopsy samples

from both the antrum and body would improve the sensitivity of *H. pylori* infection diagnosis in children under 5 years old.

Seo JH, Park JS, Rhee KH, Youn HS. Limitations of urease test in diagnosis of pediatric *Helicobacter pylori* infection. *World J Clin Pediatr* 2015; 4(4): 143-147 Available from: URL: http://www.wjgnet.com/2219-2808/full/v4/i4/143.htm DOI: http://dx.doi.org/10.5409/wjcp.v4.i4.143

INTRODUCTION

Helicobacter pylori (*H. pylori*) is the main pathogen of acute and chronic gastritis, peptic ulcer disease, and gastric cancer[1,2]. Although primary *H. pylori* infection occurs during early childhood, most adults eventually become *H. pylori* carriers in developing countries[3,4]. In children, abdominal pain is the most common symptom in *H. pylori* infection[5]. Whether or not *H. pylori*-infected children with recurrent abdominal pain should be treated did not reach consensus[6]. However, a positive family history of gastric cancer is one of the risk factors of adulthood gastric cancer in children with *H. pylori* infection[7]. Thus, a reliable diagnostic test to detect *H. pylori* infection in children is required. The most reliable diagnostic method of *H. pylori* infection in children is endoscopy with gastric biopsy[8].

The diagnosis of *H. pylori* infection is usually based on the findings of histology and the results of the urease test[9]. Histology plays an important role in detecting *H. pylori* and also indicates the degree of chronic and active inflammation in the stomach[10]. The urease test known as a simple and cheap method does not need special skills to perform or to read the result. The urease test uses phenol red, which changes from yellow to pink or red as the pH increases. *H. pylori* can stay alive in the human stomach and activate its own cytoplasmic urease, converting urea into carbon dioxide and ammonia and increasing the pH of the surrounding environment[11]. Buffered urease tests need at least 10^5 organisms so as to produce a positive result[12]. Therefore, the urease test may be negative, if biopsy samples in which the histology reveals only one or two bacteria in the entire section[13]. The time needed for the test to show a positive result depends on the concentration of bacteria[14], and the accuracy of the urease test primarily is up to the density of *H. pylori* in the gastric sample. Generally the *H. pylori* density is found to be lower in children than adolescents and adults[15]. The time of the urease test turns positive is up to the concentration of bacteria and the temperature. Most commercially available urease tests will turn positive within 2-3 h but it is best to hold those that appear negative for 24 h regardless of age[14]. The urease enzyme activity of *H. pylori* at the diagnosis also affects the urease test. Acid suppression by proton pump inhibitor is a well-known cause of the false negative result of urease test[14].

However, there is currently a debate about the sensitivity of the urease test in children without consideration of the urease enzyme activities. A review of the literature about *H. pylori* diagnostic tests in children from 1999-2009 suggested that prompt urease tests have better sensitivity than histology to detect the occurrence of *H. pylori*[16]. In 1590 pediatric patients from 1989 to 2009, urease tests had lower sensitivity (83.4%) and comparable specificity (99.0%) with histology[17]. The reason for this lower sensitivity in children was not identified, but it might be related to the low density and patchy distribution of bacteria[15,18]. In this review, we discuss the limitations of the urease test in children based on the literature reporting on pediatric patients.

AGE OF CHILDREN

Age is another factor influencing the sensitivity of the urease test[17,19,20]. The age ranges of the children in different studies were wide, and varied from ⩽ 15 to ⩽ 18 years of age[5-8]. In children, a low density of *H. pylori* has been reported[15,21], which can be attributable to sampling errors such as very low numbers of *H. pylori* in the tissue samples or patchy distribution of the organism in the stomach's mucosa[22]. Among 530 children infected with *H. pylori*, the urease test was positive in 442, and the rate of urease tests was positively associated with the children aged 5 years old and above compared with those below 5 years old[17]. The false negative rate for the urease test was 16.6% in these children, mostly found in those below 5 years old[17]. In our previous studies, we divided pediatric patients into three age groups: 0-4 years, 5-9 years, and 10-15 years[19,20]. The positivity rate of the urease test increased with each increasing age group, with the lowest rate in the 0-4 years group and highest in the 10-15 years group (Figure 1)[20]. We then compared the time points at which the positive reaction produced, dividing these into 0-1 h, 1-6 h, 6-24 h, and 24-48 h. This was considered within each of 4 age groups: 0-4 years, 5-9 years, 10-14 years, and 20-29 years[20]. Positive results occurred within 1 h in the older age groups, 10-15 years and 20-29 years. Conversely, most positive results occurred at 6-24 h in the 0-4 years group using body biopsy specimens (Figure 1)[20]. This result suggested that a low degree of *H. pylori* colonization in gastric biopsy samples might be more frequent in children under 5 years old.

HISTOPATHOLOGICAL GRADES AND THE POSITIVITY RATE OF THE UREASE TEST

H. pylori infection causes chronic inflammation in stomach mucosa. Histology has been regarded as the golden compass for *H. pylori* detection[9], as it can detect the bacteria as well as the severity of inflammation. However, just as a positive urease test requires approximately 10^5 *H. pylori* in the biopsy sample[12],

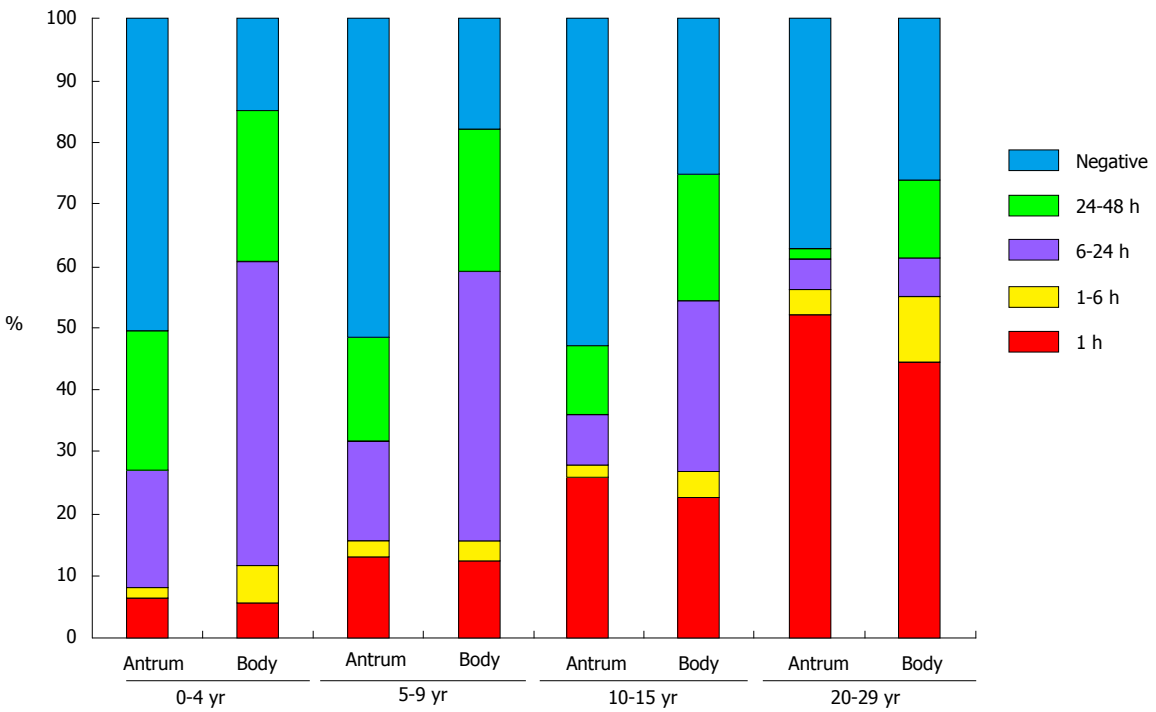

Figure 1 The positivity rate and positive timing of the urease test both in the antrum and body according to age. The positivity rate of the urease test in the antrum was higher in 20-29 years group than that in other three age groups, and the positivity rate of the urease test in the body decreased with increasing age ($P < 0.0001$). The highest positivity timing was within 1 h in the 20-29 years group, and within 6-24 h in children ($P < 0.0001$)[20].

Table 1 The studies about the positivity rate of urease test by comparing to biopsy sites and biopsy numbers

Ref.	Published year	No. subjects	Mean age (yr)	Comparison	Positivity rate of urease test (%)
Siddique *et al*[24]	2008	100 adults	36.1	One biopsy	52
				Two biopsies	68
				Three biopsies	76
				Four biopsies	96
Seo *et al*[19]	2014	255 children	NA	One biopsy	32.2
				Three biopsies	40.1
Moon *et al*[25]	2012	214 adults	53.6	Antrum	58.9
				body	62.1
				Antrum + body	69.2
Lan *et al*[26]	2012	164 adults	NA	Antrum	83.3
				Antrum + corpus	100

NA: Not available.

histopathological results are limited by the distribution and density of the bacteria in the sample. Therefore, the patchy distribution and low density *of H. pylori* in gastric mucosa in children might be related to the absence of bacteria in some histopathological findings. Nevertheless, the positive urease test is highly correlated with the density of bacteria, the severity of chronic gastritis, and the presence of active gastritis, as determined by histopathology[15,17].

When histopathological evaluations found severe degrees of chronic and active gastritis, or *H. pylori* infiltration, the urease tests revealed a quick change of color, indicating positive results in samples from both the antrum and gastric body, regardless of age, compared with those from milder histopathological grades[20]. In 38 children, aged 2-18 years, the accuracy of the rapid urease test was 95% for samples determined to be positive by histology[23]. The accuracy of the urease test is up to the density of *H. pylori* in the gastric sample. However the *H. pylori* density is overall lower in children than in adolescents and adults[15]. Therefore, both histology and a urease test should be performed in children for diagnosis of *H. pylori* infection.

EFFECT OF THE NUMBER OF GASTRIC BIOPSY SPECIMENS

Two or more numbers of gastric biopsies improve the sensitivity and saves the time for the positive result for diagnosis of urease test[19,24]. There were several studies comparing positivity rate of urease test according to the biopsy numbers diagnosis (Table 1): three were

adults studies and one was children study. In children, the positivity rate of the urease test was higher in three biopsy samples than single biopsy sample, in the same child[19]. The discrepancy between positivity rates of the urease test utilizing one *vs* three biopsy samples was elevated in children below 5 years old[21]. Thus, when the urease test is performed on three or more biopsy samples, it is possibly a more accurate diagnostic modality.

In adults, the positivity rate of urease test also increased with using two to four biopsy specimens than a single biopsy specimen[24]. The discrepancy rates of one and two or more biopsy specimens were higher in adults (10.3%, 16.7% and 16%) than in children (7.9%) (Table 1)[19,24-26]. In adults, the time for positive urease test was faster in united test (1.69 h for antrum and body) than in separate test (3.58 h for body or antrum) on average[25]. In children, it is reported to be a low degree of *H. pylori* colonization and more patchy distribution of *H. pylori*[21]. Thus, when the urease test is performed on three or more biopsy samples, it may be a more accurate diagnostic modality.

EFFECT OF BIOPSY SITE ON UREASE TEST RESULTS

Most patients were taken of biopsy specimens from the antrum, as one biopsy from the gastric angle for urease test had the maximum probability for detecting *H. pylori* infection[27]. The use of an additional biopsy from the gastric body can improve the detection rate of *H. pylori* (Table 1)[20,25,26]. In our previous study[20], the discrepancy of urease test results was bigger between the antrum and body in children compared with that in adults, and the most difference was found in the samples that showed a positive color change late in testing, from 6-24 h (Figure 1). In our study, no difference was observed between the speed of a positive reaction in samples from the antrum and from the body in adults[20]. But the time of positive test was 3.58 h for the separate test and 1.69 h for the united test on average[25]. The colonization degree was remarkably lower in the body compared with the antrum[21]. In our previous study, the histopathologic findings of the antrum and body revealed similar degrees of chronic and active gastritis and infiltration of bacteria in children, the positivity rate of the urease test was higher in samples from the body than from the antrum[20]. This result was similar to the study of Korean adults, where the positivity rate of urease test in body was higher than in antrum (Table 1)[25]. In adults, the sensitivity of urease test decreased along with the degree of gastritis with atrophy increasing from 100% in normal, 97% in mild, 91% in moderate to 66% in severe[26]. However additional corpus biopsy resulted in increased sensitivity to 16.67% compared to single antrum biopsy (Table 1)[26]. This might also be related to the patchy distribution of *H. pylori* and low density of the organism in body. There has been a continuing debate about the optimum site and number of gastric biopsies for the diagnosis of *H. pylori*.

CONCLUSION

Early diagnosis of *H. pylori* infection is crucial for symptomatic children with a family history of gastric cancer. In children, endoscopic examination and biopsy for histology and urease test is still the most reliable method for diagnosis of *H. pylori* infection. The difference in the positivity rate of the urease test between using one or three biopsy samples, or using biopsy samples from the antrum or body, were larger in children aged 0-5 years than 5-15 years. Use of three or more biopsy samples from both the antrum and body would improve the sensitivity of *H. pylori* detection in children.

REFERENCES

1 **Queiroz DM**, Carneiro JG, Braga-Neto MB, Fialho AB, Fialho AM, Goncalves MH, Rocha GA, Rocha AM, Braga LL. Natural history of Helicobacter pylori infection in childhood: eight-year follow-up cohort study in an urban community in northeast of Brazil. *Helicobacter* 2012; **17**: 23-29 [PMID: 22221612 DOI: 10.1111/j.1523-5378.2011.00894.x]

2 **Shiotani A**, Cen P, Graham DY. Eradication of gastric cancer is now both possible and practical. *Semin Cancer Biol* 2013; **23**: 492-501 [PMID: 23876852 DOI: 10.1016/j.semcancer.2013.07.004]

3 **Malaty HM**, El-Kasabany A, Graham DY, Miller CC, Reddy SG, Srinivasan SR, Yamaoka Y, Berenson GS. Age at acquisition of Helicobacter pylori infection: a follow-up study from infancy to adulthood. *Lancet* 2002; **359**: 931-935 [PMID: 11918912 DOI: 10.1016/S0140-6736(02)08025-X]

4 **Rhee KH**, Youn HS, Baik SC, Lee WK, Cho MJ, Choi HJ, Maeng KY, Ko KW. Prevalence of Helicobacter pylori infection in Korea. *J Korean Soc Microbiol* 1990; **25**: 475-490

5 **Koletzko S**, Jones NL, Goodman KJ, Gold B, Rowland M, Cadranel S, Chong S, Colletti RB, Casswall T, Elitsur Y, Guarner J, Kalach N, Madrazo A, Megraud F, Oderda G. Evidence-based guidelines from ESPGHAN and NASPGHAN for Helicobacter pylori infection in children. *J Pediatr Gastroenterol Nutr* 2011; **53**: 230-243 [PMID: 21558964 DOI: 10.1097/MPG.0b013e3182227e90]

6 **Ozçay F**, Koçak N, Temizel IN, Demir H, Ozen H, Yüce A, Gürakan F. Helicobacter pylori infection in Turkish children: comparison of diagnostic tests, evaluation of eradication rate, and changes in symptoms after eradication. *Helicobacter* 2004; **9**: 242-248 [PMID: 15165260 DOI: 10.1111/j.1083-4389.2004.00230.x]

7 **Cam S**. Risk of gastric cancer in children with Helicobacter pylori infection. *Asian Pac J Cancer Prev* 2014; **15**: 9905-9908 [PMID: 25520126 DOI: 10.7314/APJCP.2014.15.22.9905]

8 **Gold BD**, Colletti RB, Abbott M, Czinn SJ, Elitsur Y, Hassall E, Macarthur C, Snyder J, Sherman PM. Helicobacter pylori infection in children: recommendations for diagnosis and treatment. *J Pediatr Gastroenterol Nutr* 2000; **31**: 490-497 [PMID: 11144432 DOI: 10.1097/00005176-200011000-00007]

9 **Wong A**, Ching SS, Long AS. The use of a second biopsy from the gastric body for the detection of Helicobacter pylori using rapid urease test. *Singapore Med J* 2014; **55**: 644-647 [PMID: 25630318 DOI: 10.11622/smedj.2014178]

10 **Aydin O**, Egilmez R, Karabacak T, Kanik A. Interobserver variation in histopathological assessment of Helicobacter pylori gastritis. *World J Gastroenterol* 2003; **9**: 2232-2235 [PMID: 14562384]

11 **Berger A**. Scientists discover how helicobacter survives gastric acid. *BMJ* 2000; **320**: 268 [PMID: 10650011 DOI: 10.1136/bmj.320.7230.268]

12 **Mégraud F**, Bessède E, Lehours P. Current methods used for the diagnosis of *Helicobacter pylori* infection. In: Buzás GM.

Helicobacter pylori - A Worldwide Perspective 2014. Oak Park: Bentham Science, 2014: 234-258 [DOI: 10.2174/9781608057375114010014]

13 **Ohkusa T**, Miwa H, Endo S, Okayasu I, Sato N. Helicobacter pylori is a fragile bacteria when stored at low and ultra-low temperatures. *J Gastroenterol Hepatol* 2004; **19**: 200-204 [PMID: 14731131 DOI: 10.1111/j.1440-1746.2004.03266.x]

14 **Uotani T**, Graham DY. Diagnosis of Helicobacter pylori using the rapid urease test. *Ann Transl Med* 2015; **3**: 9 [PMID: 25705641 DOI: 10.3978/j.issn.2305-5839.2014.12.04]

15 **Elitsur Y**, Hill I, Lichtman SN, Rosenberg AJ. Prospective comparison of rapid urease tests (PyloriTek, CLO test) for the diagnosis of Helicobacter pylori infection in symptomatic children: a pediatric multicenter study. *Am J Gastroenterol* 1998; **93**: 217-219 [PMID: 9468245 DOI: 10.1111/j.1572-0241.1998.00217.x]

16 **Guarner J**, Kalach N, Elitsur Y, Koletzko S. Helicobacter pylori diagnostic tests in children: review of the literature from 1999 to 2009. *Eur J Pediatr* 2010; **169**: 15-25 [PMID: 19618211 DOI: 10.1007/s00431-009-1033-x]

17 **Roma-Giannikou E**, Roubani A, Sgouras DN, Panayiotou J, van-Vliet C, Polyzos A, Roka K, Daikos G. Endoscopic tests for the diagnosis of Helicobacter pylori infection in children: Validation of rapid urease test. *Helicobacter* 2010; **15**: 227-232 [PMID: 20557365 DOI: 10.111/j.1523-5378.2010.00756.x]

18 **Midolo P**, Marshall BJ. Accurate diagnosis of Helicobacter pylori. Urease tests. *Gastroenterol Clin North Am* 2000; **29**: 871-878 [PMID: 11190071]

19 **Seo JH**, Park JS, Yeom JS, Lim JY, Park CH, Woo HO, Baik SC, Lee WK, Cho MJ, Rhee KH, Youn HS. Correlation between positive rate and number of biopsy samples on urease test in childhood Helicobacter pylori infection. *J Korean Med Sci* 2014; **29**: 106-109 [PMID: 24431913 DOI: 10.3346/jkms.2014.29.1.106]

20 **Seo JH**, Youn HS, Park JJ, Yeom JS, Park JS, Jun JS, Lim JY, Park CH, Woo HO, Ko GH, Baik SC, Lee WK, Cho MJ, Rhee KH. Influencing Factors to Results of the Urease Test: Age, Sampling Site, Histopathologic Findings, and Density of Helicobacter pylori. *Pediatr Gastroenterol Hepatol Nutr* 2013; **16**: 34-40 [PMID: 24010104 DOI: 10.5223/pghn.2013.16.1.34]

21 **Drumm B**. Helicobacter pylori in the pediatric patient. *Gastroenterol Clin North Am* 1993; **22**: 169-182 [PMID: 8449565]

22 **Carelli AP**, Patrício FR, Kawakami E. Carditis is related to Helicobacter pylori infection in dyspeptic children and adolescents. *Dig Liver Dis* 2007; **39**: 117-121 [PMID: 17196450 DOI: 10.1016/j.dld.2006.10.012]

23 **Jolley CD**, Wagner DA. Comparison of the 13C-urea blood test to histology and rapid urease testing in the diagnosis of Helicobacter pylori infection in children. *J Pediatr Gastroenterol Nutr* 2007; **44**: 68-70 [PMID: 17204956 DOI: 10.1097/01.mpg.0000243426.78721.bc]

24 **Siddique I**, Al-Mekhaizeem K, Alateeqi N, Memon A, Hasan F. Diagnosis of Helicobacter pylori: improving the sensitivity of CLOtest by increasing the number of gastric antral biopsies. *J Clin Gastroenterol* 2008; **42**: 356-360 [PMID: 18277905 DOI: 10.1097/MCG.0b013e31802b650d]

25 **Moon SW**, Kim TH, Kim HS, Ju JH, Ahn YJ, Jang HJ, Shim SG, Kim HJ, Jung WT, Lee OJ. United Rapid Urease Test Is Superior than Separate Test in Detecting Helicobacter pylori at the Gastric Antrum and Body Specimens. *Clin Endosc* 2012; **45**: 392-396 [PMID: 23251887 DOI: 10.5946/ce.2012.45.4.392]

26 **Lan HC**, Chen TS, Li AF, Chang FY, Lin HC. Additional corpus biopsy enhances the detection of Helicobacter pylori infection in a background of gastritis with atrophy. *BMC Gastroenterol* 2012; **12**: 182 [PMID: 23272897 DOI: 10.1186/1471-230X-12-182]

27 **Woo JS**, el-Zimaity HM, Genta RM, Yousfi MM, Graham DY. The best gastric site for obtaining a positive rapid ureas test. *Helicobacter* 1996; **1**: 256-259 [PMID: 9398877]

P- Reviewer: Classen CF
S- Editor: Qiu S **L- Editor**: A **E- Editor**: Jiao XK

World Journal of Clinical Pediatrics

Submit a Manuscript: http://www.wjgnet.com/esps/
Help Desk: http://www.wjgnet.com/esps/helpdesk.aspx
DOI: 10.5409/wjcp.v4.i4.148

World J Clin Pediatr 2015 November 8; 4(4): 148-154
ISSN 2219-2808 (online)
© 2015 Baishideng Publishing Group Inc. All rights reserved.

ORIGINAL ARTICLE

Retrospective Study

Coeliac disease in children in Christchurch, New Zealand: Presentation and patterns from 2000-2010

Adeline Kho, Martin Whitehead, Andrew S Day

Adeline Kho, Andrew S Day, Department of Paediatrics, University of Otago, Christchurch 8140, New Zealand

Martin Whitehead, Department of Pathology, University of Otago, Christchurch 8140, New Zealand

Author contributions: All the authors equally contributed to this work.

Institutional review board statement: This conduct of this retrospective study was approved by the Upper South A Regional Ethics Committee, New Zealand (URA/11/EXP/044).

Informed consent statement: Given the nature of the study (retrospective review of patient charts, with no direct patient contact), specific informed consent was not required (as per the approval of the Regional Ethics Committee).

Conflict-of-interest statement: None of the authors have any conflicts of interest to declare relevant to this study.

Data sharing statement: Not applicable.

Open-Access: This article is an open-access article which was selected by an in-house editor and fully peer-reviewed by external reviewers. It is distributed in accordance with the Creative Commons Attribution Non Commercial (CC BY-NC 4.0) license, which permits others to distribute, remix, adapt, build upon this work non-commercially, and license their derivative works on different terms, provided the original work is properly cited and the use is non-commercial. See: http://creativecommons.org/licenses/by-nc/4.0/

Correspondence to: Andrew S Day, Professor, Department of Paediatrics, University of Otago, Riccarton Avenue, Christchurch 8140, New Zealand. andrew.day@otago.ac.nz
Telephone: +64-3-3640747
Fax: +64-3-3640919

Received: January 6, 2015
Peer-review started: January 7, 2015
First decision: April 27, 2015
Revised: May 16, 2015
Accepted: September 10, 2015
Article in press: September 16, 2015
Published online: November 8, 2015

Abstract

AIM: To evaluate the presentation patterns of a cohort of children diagnosed with coeliac disease (CD) at Christchurch Hospital, New Zealand.

METHODS: Children aged 16 years or less diagnosed with CD at Christchurch Hospital, Christchurch, New Zealand, over the 11 year period between 2000 and 2010 were identified retrospectively. Diagnosis of CD was based upon standard histological criteria of endoscopically-obtained duodenal biopsies. Overlapping search methods were used to identify all relevant diagnoses within the time period. Endoscopy reports and histology findings were reviewed to confirm diagnosis. The numbers of diagnoses per year were calculated and changes in annual rates over the study period were delineated. Available records were reviewed to ascertain presenting symptoms, baseline anthropometry and the indication for referral for each child. In addition, the results of relevant investigations prior to diagnosis were accessed and reviewed. These key investigations included the results of coeliac serology testing (including tissue transglutaminase and endomysial antibodies) as well as the results of tests measuring levels of micronutrients, such as iron. In addition, the histological findings of concurrent biopsies in the oesophagus and stomach were reviewed.

RESULTS: Over the 11 year study period, 263 children were diagnosed with CD at this New Zealand paediatric facility. Children were diagnosed from late infancy to 16.9 years: the largest subgroup of children (n = 111) were diagnosed between 5 and 12 years of age. The numbers of children diagnosed each year increased from 13 per year to 31 per year over the 11 years (P = 0.0095).

Preschool children (aged less than 5 years) were more likely to have low weight, and to have diarrhoea and abdominal pain prior to diagnosis. Older children (over 5 years of age) most commonly presented with abdominal pain. Fifty-six (21.6%) of the 263 children were diagnosed following screening in high risk groups, with 38 of these children having no symptoms at diagnosis. Mean weight Z scores were lower in children aged less than five years than children aged 5-12 years or older children (-0.4096 ± 1.24, *vs* 0.1196 ± 0.966 *vs* 0.0901 ± 1.14 respectively: P = 0.0033).

CONCLUSION: Increasing numbers of children were diagnosed with CD in this New Zealand centre over this time, with varied presentations and symptoms.

Key words: Coeliac disease; Children; Screening; Small bowel biopsy; Antibodies

© The Author(s) 2015. Published by Baishideng Publishing Group Inc. All rights reserved.

Core tip: Coeliac disease (CD) is increasingly diagnosed throughout childhood. Physicians must be aware of the varied presentations of CD in children and consider this diagnosis accordingly.

Kho A, Whitehead M, Day AS. Coeliac disease in children in Christchurch, New Zealand: Presentation and patterns from 2000-2010. *World J Clin Pediatr* 2015; 4(4): 148-154 Available from: URL: http://www.wjgnet.com/2219-2808/full/v4/i4/148.htm DOI: http://dx.doi.org/10.5409/wjcp.v4.i4.148

INTRODUCTION

Coeliac disease (CD) is an autoimmune disease of the small bowel, triggered by dietary exposure to gluten in genetically susceptible individuals[1]. Ingestion of gluten provokes immune-mediated damage to the small intestinal mucosa. Following diagnosis of CD the optimal management currently involves a life-long gluten-free diet (GFD)[2].

Although traditionally felt to be a disease of infancy, presenting with classical symptoms of malabsorption (diarrhoea, abdominal bloating and failure to thrive), it is now clear that CD can develop at any age whilst on a gluten-containing diet[3]. A number of recent reports have documented increasing variability in presentation patterns with more patients presenting with non-specific complaints such as iron deficiency anaemia or lethargy[4-6]. In addition, more individuals are now identified consequent to active screening in groups at higher risk of CD (such as those with positive family history) and a number of these patients may be asymptomatic at diagnosis[7]. Although strategies such as active screening recognise more individuals with CD, it is felt that for every person diagnosed there are still many individuals who are undiagnosed in the community[8-10].

CD is now recognised as a common disease, with prevalence estimated to be at least 1: 100[7]. Locally, a population-based study performed in Christchurch, New Zealand, suggested a prevalence of one in 82 individuals[11]. In addition, a subsequent hospital-based study conducted in the same region demonstrated increasing numbers diagnosed each year over the last years of the twentieth century[12]. The primary aims of this retrospective study were to determine the rates of diagnosis and the presentation patterns of paediatric-onset CD at Christchurch Hospital in the first decade of the 21st century.

MATERIALS AND METHODS

Population

Children aged 16 years or less (defined as diagnosis before their seventeenth birthday) diagnosed with CD at Christchurch Hospital, Christchurch, New Zealand between January 1st 2000 and December 31st 2010 were identified retrospectively. Christchurch Hospital is the sole secondary-level public hospital for the Canterbury region and also provides tertiary paediatric services for surrounding regions. The study population did not include children diagnosed outside Christchurch Hospital.

The Department of Pathology database was searched for the keywords "coeliac disease", "celiac disease" and "gluten sensitive enteropathy". This search returned histology reports of patients who had been investigated for and/or diagnosed with CD. Records available from the Dietetics Department were also reviewed to identify children referred for dietetic education prior to commencement of a GFD. Each patient's hospital records (hard-copy and electronic) was also retrieved and reviewed for the purpose of the study.

The duodenal biopsies taken at Christchurch Public Hospital from 2000-2010 were all analysed by the same medical laboratory, although by different pathologists. Lesions consistent with Marsh-Oberhuber criteria (including increased intraepithelial lymphocytes, partial to complete villous atrophy, crypt hyperplasia and increased lymphocytes in the lamina propria) were considered to be diagnostic[13]. The histological findings in other areas of the upper gastrointestinal tract were also reviewed.

Clinical features

Relevant background features, such as presenting signs and symptoms, risk group status, and anthropometry were extracted from hospital clinical records and where available, GP referral letters and blood test results. In the event of missing data, the patients' last known GP was contacted and asked to provide relevant results and notes where available.

Endoscopy and pathology reports were reviewed. The results of serological tests [anti-gliadin (AGA), anti-

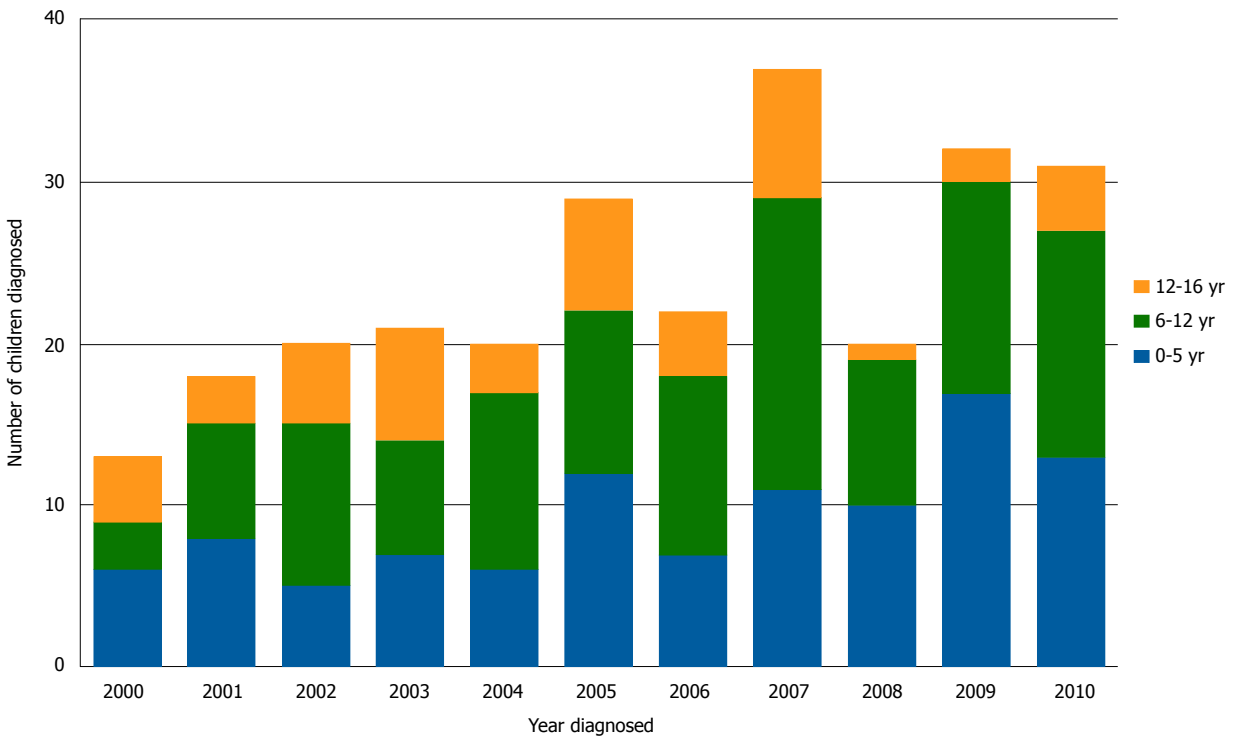

Figure 1 Age distribution of 263 children diagnosed with coeliac disease in Christchurch, New Zealand, between 2000 and 2010.

endomysial antibodies (EMA), tissue transglutaminase (tTG) and deaminated gliadin peptide (DGP)] were obtained. The results of other tests conducted prior to diagnosis (haemoglobin level, iron studies, total IgA level and HLA DQ2/DQ8 status) were also noted where available. Patients were classified as iron deficient in the presence of one or more of the following: serum ferritin levels below normal reference range in the absence of an elevated C-reactive protein; transferrin saturation or serum iron levels below the normal reference range; total iron binding capacity and serum transferrin receptor levels above the normal reference range. Iron deficiency anaemia was defined as a microcytic hypochromic anaemia, with evidence of low iron stores as stated above.

Statistical analysis

Descriptive analyses were executed using Microsoft Excel 14.0.0. Weight and height Z scores were calculated using an online calculator employing data from the National Health and Nutrition Evaluation Survey - (http://www.emmes.com/study/ped/resources/htwtcalc.htm). Statistical analyses were performed using GraphPad InStat 3.0 (GraphPad Software, Inc., La Jolla, CA). One-way analysis of variance (ANOVA), *t* tests and chi-square tests were utilised for data analysis. Statistical significance was defined as a *P* value below 0.05.

RESULTS

Study population

A total of 263 children were diagnosed with CD over the time period. The median age of the study population was 7.88 years (range 0.8-16.9 years) and 169 (64%) were female. Two hundred and sixteen children were aged less than 12 years whilst 26 were aged less than 2 years of age. The largest number of children (42.3%) was aged between 6 and 12 years at diagnosis.

The gender and age distribution of the group did not vary over the study period. However, the numbers of children diagnosed each year increased from 13 in 2000 to 31 in 2010 ($P = 0.009$) (Figure 1).

At least one risk factor for CD was seen in 140 (53.4%) of the 263 children. Positive family history ($n = 92$), Trisomy 21 ($n = 15$) and type 1 diabetes mellitus (T1DM) ($n = 22$) were seen most commonly, whilst other risk groups included Turner's syndrome, autoimmune thyroid disease and William's Syndrome ($n = 11$). Two risk factors, such as positive family history and T1DM, were seen in 7 children. Diagnosis was made after screening in 56 (21%) children: 38 of whom were reported to be asymptomatic. One patient was found to have CD at the time of upper gastrointestinal endoscopy for suspected eosinophilic oesophagitis.

Presenting features

Details of presenting features were available for 260 of the 263 children. Thirty-eight of these 260 children had no reported symptoms at the time of diagnosis. Abdominal pain (44.2%) and diarrhoea (38.9%) were the most commonly reported symptoms in the 222 children presenting with symptoms (Table 1). Most children presented with a combination of intestinal and extra-intestinal symptoms. Whilst diarrhoea (51.5%)

Table 1 Presenting symptoms or signs in 263 children diagnosed with coeliac disease in Christchurch, New Zealand *n* (%)

	Presenting sign or symptom	Children
Gastrointestinal	Abdominal pain	115 (43.6)
	Diarrhoea	101 (38.3)
	Bloating (± increased flatus)	60 (22.7)
	Nausea and vomiting	42 (15.9)
	Constipation	17 (6.4)
Nutritional	Iron deficiency (± anaemia)	84 (31.8)
	Poor weight gains/wasting	65 (24.6)
	Weight loss	27 (10.2)
	Micronutrient deficiency	25 (9.5)
	Short stature	10 (3.8)
Extra-gastrointestinal	Lethargy	36 (13.6)
	Poor health/recurrent infections	12 (4.6)
	Irritability/low mood	11 (4.2)
	Headaches	6 (2.3)
	Pubertal delay	3 (1.1)
	Poor sleep	2 (0.8)
	Neuropsychiatric symptoms	1 (0.4)
Asymptomatic	Identified following screening	38 (14.4)

The presenting features prior to diagnosis were noted. Some children had more than one presenting feature.

and failure to thrive (46.6%) predominated in the children aged less than 5 years of age, abdominal pain was the most common symptom in older children (P = 0.0032).

Growth parameters at diagnosis of CD

Weight measurements were available for 229 of the 263 children, and height measurements available for 184 of the children. Overall, the mean Z score (± SD) for weight was -0.12 ± 0.22, whilst that for height was -0.24 ± 0.31. The children aged less than five years had a lower mean weight z score (-0.4096 ± 1.24) than the children aged 5-12 years (0.1196 ± 0.966) and the older group (0.0901 ± 1.14) (P = 0.0033, ANOVA). There were no differences in the mean height z scores for the three age groupings (Table 2).

Eighteen (7.8%) of the patients had a weight score more than 2 SD below the mean (wasting), and 15 (8.2%) had a height score more than 2 SD below the mean (stunting). More of the children with wasting were aged less than 5 years of age than older than this age (13 *vs* 5; P = 0.005). Stunting was not different across the age ranges (data not shown). Five children (2%) had a weight score more than 2 SD above the mean (overweight). Only three children (1.6%) had a height score more than 2 SD above the mean.

Results of serological tests prior to diagnosis

The results of serological tests were available in 261 children. AGA testing (IgA and IgG) was completed only prior to 2008: IgG AGA was positive in 82.4% of 193 children, whilst IgA AGA was positive in 50.8% of 185 children. EMA testing was positive in 177 (87.6%) of the 202 who had been tested for this antibody. tTG serology was positive in 183 (89.3%) of the 205 children who had been tested. Sixteen children had DGP testing (all since 2008): IgG DGP was positive in 75% and IgA DGP positive in 62.5% of this group.

Twelve children were negative for IgA-based tests (EMA, tTG and AGA): three of these children were IgA deficient. These three children all tested positive for IgG AGA and one was also IgG tTG positive.

Table 2 Nutritional parameters in children diagnosed with coeliac disease, stratified by age

Age group (yr)	Weight Z score (± SD)	Height Z score (± SD)	Iron deficiency (*n*)	Other deficiency (*n*)
0-5	-0.4096 ± 1.24	-0.4210 ± 1.102	41	9
6-12	0.1196 ± 0.966	-0.914 ± 1.125	25	8
> 12	0.0901 ± 1.14	-0.229 ± 1.347	21	7

Children aged less than five years of age had lower weight Z scores than the other groups (P = 0.0033), but there were no differences in height Z scores between the groups. Other deficiencies included those with low levels of folate, vitamin B12, vitamin A, vitamin D, vitamin E or vitamin K.

Results of other investigations completed at diagnosis

Full blood count results were available in 178 children: 25 (14.0%) of these children were found to have a haemoglobin level below the normal reference range, and 12 (6.7%) had microcytosis. Four of the 25 anaemic children did not have assessment of iron status at the time of diagnosis: two were documented as having iron deficiency anaemia in their referral letters to hospital whilst the other two children had normocytic normochromic anaemia.

Iron status was assessed in 153 children: 84 (54.9%) of these children were iron deficient (Table 2). Measurement of other micronutrients was completed only in a small number of children: 24 were found to have deficiency of folate, vitamin B12, vitamin A, vitamin D, vitamin E, and/or vitamin K (Table 2). Genetic testing for HLA DQ2/DQ8 was not routinely undertaken during this period: only 28 children had undergone this investigation, all of whom had positive results. Detailed analysis of this HLA marker was therefore not conducted.

Histological findings

Duodenal biopsies were evaluated by pathologists and diagnosed according to Marsh-Oberhuber criteria[13]. Almost all the children diagnosed with CD also had concurrent biopsies of the oesophagus and the stomach taken during gastroscopy. Distinct abnormalities were seen in 86 children, with some children having more than one other finding. Common findings included reflux oesophagitis (seen in 21 children) and lymphocytic gastritis (n = 16) (Table 3).

DISCUSSION

This retrospective study showed progressive increases in the number of children diagnosed with CD each year

Table 3 Oesophageal and gastric findings in 263 children diagnosed with coeliac disease

	Histological diagnosis	Number of patients	Percentage of patients (%)
Oesophageal findings	Reflux oesophagitis	21	7.9
	Eosinophilic oesophagitis	4	1.5
	Candida oesophagitis	1	0.4
	Non-specific oesophagitis	21	7.9
Gastric findings	Lymphocytic gastritis	16	6.1
	Non-specific gastritis	30	11.4
	Reactive gastritis (bile reflux)	11	4.2
	Active chronic gastritis (*H. pylori*)	1	0.4
	Gastric metaplasia	1	0.4

Eighty-six of the 263 children diagnosed with coeliac disease were found to have one or more oesophageal or gastric findings on review of endoscopic biopsies. *H. pylori*: *Helicobacter pylori*.

in this single New Zealand location over the 11 years of observation. Presenting symptoms varied widely in this group, and a substantial number of children were diagnosed following screening assessments in high risk groups. Preschool children were more likely to have nutritional impairment than older children. Although this study was not designed to define population-specific rates of CD, the results clearly emphasise that CD is an increasingly important condition in New Zealand children.

A prospective population-based study has previously documented that CD is common in adults in this region of New Zealand, with rates of 1:82[11], equivalent to prevalence studies in several other countries[7]. A further study documented increasing rates of diagnosis in children and adults from the same region over the last three decades of the 20th century[12]. That prospective study documented the diagnosis of CD in 62 children aged between 0 and 12 years of age, with increasing numbers in the last years of the 30 year period. In contrast, 216 children aged less than 12 years were diagnosed within the 11 year period of the current study, emphasising the increasing numbers of diagnoses in the same region of New Zealand.

Cumulative incidence rates in children (0-12 years old) in previous New Zealand studies have been low in comparison to corresponding adult rates: 0.10/1000 in Wellington[14], 0.35/1000 in Otago[15] and 0.40/1000 in Canterbury[12]. More recently the prevalence of childhood CD was ascertained in the New Zealand Asthma and Allergy Cohort[16]. This birth-cohort was established between 1997 and 2001, with infants recruited in two New Zealand centres (Christchurch and Wellington). The parents of 916 children in this cohort were asked in 2009 about doctor-diagnosed CD. Nine children were identified, giving a prevalence of 1%. However, this parental report was not validated by detailed review of each patient's medical history.

This pattern of increasing numbers of young children diagnosed with CD in New Zealand may be related in part to enhanced awareness of CD and more recognition of groups at higher risk of developing this condition. Advances in serological tests and diagnostic approaches may be additional factors[17]. Environmental factors, such as infant breast-feeding practices, age at introduction of gluten, and the amount of gluten in the diet, could also be relevant to changes in rates of CD in recent years[18]. It is unlikely, however, that genetic risk will have altered over a period of just a few decades. There may also be a true rise in incidence of CD. Studies from Finland, in particular, indicate a true increase in the incidence of CD over time, with most recent rates estimated to be 2.4%[19]. In the New Zealand setting, deregulation of the New Zealand wheat industry and changes in infant feeding practices could be potential drivers of such a rise in incidence[11]. The retrospective nature of the current study did not allow any clarification of environmental risk factors, such as breast feeding, or of other details including family history of CD.

The current study clearly demonstrated that CD can be diagnosed at any age through childhood, with pain being a predominant presenting symptom, especially in older children. Overall, significant nutritional impairments were not commonly seen, with less than 10% percent being malnourished at diagnosis. However, nutritional impairment was more likely in preschool children than in those of school age. Unfortunately, the presentation patterns and nutritional state of the children diagnosed at the same centre in the preceding three decades were not documented[12]. However, the reduced number of children diagnosed prior to their second birthday in the second cohort compared to the earlier group (12% *vs* 21%) suggests less frequent presentation with classical malabsorptive symptoms.

Previous reports over the last decade from elsewhere in New Zealand[4] and Australia[5,20] also demonstrate similar findings in presentation patterns. Internationally, similar observations have been made, with less preschool children presenting with classical malabsorptive symptoms, and more with gastrointestinal or non-gastrointestinal symptoms[6].

A number of children in the current study had been diagnosed with CD following screening within a high risk group and more than two thirds of the children identified by screening were asymptomatic. Groups at highest risk of CD include those with a first degree family member, children with T1DM and Down syndrome (Trisomy 21)[7]. Children with a first degree family history of CD comprise the largest high risk group in the children diagnosed with CD in the current study. The increased identification of children following focused screening is noted elsewhere also[5,20].

The use of specific serological tests has evolved over the period of the current study. Whereas AGA and EMA were utilised in the last thirty years of the 20th century[12], tTG and EMA were the predominant tests utilised in the current cohort. AGA tests were available for part of the period, whilst DGP were utilised only in the latter years. In this setting, EMA and tTG were

positive in the majority of those children tested.

The recently published European guidelines for the diagnosis of CD include a provision for the diagnosis of CD without obtaining duodenal biopsies[21]. The current study does not permit a detailed assessment of the validity of this protocol to the New Zealand setting. However, a number of children in the current cohort would not have reached diagnostic criteria without completion of duodenal biopsies. Furthermore, less than 15% of the current cohort had estimation of HLA DQ2/DQ8. Whilst best considered as a test to provide risk stratification (negative gene testing reflecting essentially no risk of developing CD), HLA testing is also included in the ESPGHAN guidelines as a requirement for considering diagnosis without duodenal biopsies[21].

A number of the current cohort had additional histological findings present in the upper gut. Whilst the presence of lymphocytic gastritis is well-recognised as a component of CD, the recognition of oesophageal findings is of interest. Several paediatric cohorts have shown an association between CD and eosinophilic oesophagitis[22-24]. Although the reason for this link is as yet unclear[25], it does further illustrate the evolving patterns of CD in children.

The limitations of this study relate principally to its retrospective nature. This limited the availability of all required data, with incomplete data across some key areas. This study did not consider children seen and diagnosed in the private sector, and consequently cannot be considered population-based. However, the small number of additional children diagnosed in the private sector would likely serve to further increase the total numbers diagnosed over time. The included population was seen and diagnosed within a single hospital setting over an 11 year period, and follows directly from an earlier assessment of CD in the same setting[12]. Together, these two datasets cover 41 years of children diagnosed with CD in Christchurch, New Zealand.

In conclusion, these data reflect a large increase in number of children and adolescents diagnosed with CD at this single New Zealand tertiary centre. Common to other reports, the presentation patterns of CD in children are many and varied. Practitioners must consider the diagnosis of CD in children seen with a variety of symptoms. The increased emphasis upon screening in groups at higher risk of CD is likely to lead to even more children diagnosed without symptoms.

COMMENTS

Background

Coeliac disease (CD) may present at any age after commencement of a gluten containing diet. Increasing rates of the diagnosis of CD was previously noted in the Christchurch region over the last three decades of the 20th century. The current study focused on the first 11 years of the 21st century and ascertained annual rates of diagnosis over this time.

Research frontiers

CD may present throughout childhood, with a variety of symptoms. Increasing numbers of children are diagnosed after screening in groups at greater risk of developing CD. Such children may not have any symptoms at the time of screening or diagnosis.

Innovations and breakthroughs

Different symptom patterns may be seen in children of varying age. Screening for CD in children at increased risk of CD (such as those with a first degree family member) may lead to earlier diagnosis and avoid nutritional or other consequences of CD.

Applications

Physicians assessing children must be aware of the myriad different possible presentation patterns of CD. Early investigation in those with possible CD should be undertaken to avoid long term morbidity and adverse outcomes.

Terminology

Genetic risk for the development of CD is attributed to particular *HLA* genes. Serological tests for CD include tissue transglutaminase antibodies (tTG: measured by immunoassay) and endomysial antibodies (EMA: assessed by immunofluorescence).

Peer-review

Increasing numbers of children were diagnosed with CD after screening exercises: a number of these children have no symptoms at the time of diagnosis. Assessment of HLA genetic status was completed in few of the children included in this retrospective study of CD. Consequently, few conclusions could be made about the relevance of these findings.

REFERENCES

1 **Tack GJ**, Verbeek WH, Schreurs MW, Mulder CJ. The spectrum of celiac disease: epidemiology, clinical aspects and treatment. *Nat Rev Gastroenterol Hepatol* 2010; **7**: 204-213 [PMID: 20212505 DOI: 10.1038/nrgastro.2010.23]

2 **Schuppan D**, Junker Y, Barisani D. Celiac disease: from pathogenesis to novel therapies. *Gastroenterology* 2009; **137**: 1912-1933 [PMID: 19766641 DOI: 10.1053/j.gastro.2009.008]

3 **Kennedy NP**, Feighery C. Clinical features of coeliac disease today. *Biomed Pharmacother* 2000; **54**: 373-380 [PMID: 10989976 DOI: 10.1016/s0753-3322(01)80004-4]

4 **Westerbeek E**, Mouat S, Wesley A, Chin S. Coeliac disease diagnosed at Starship Children's Hospital: 1999-2002. *N Z Med J* 2005; **118**: U1613 [PMID: 16132074]

5 **Stone ML**, Bohane TD, Whitten KE, Tobias VH, Day AS. Age related clinical features of childhood coeliac disease in Australia. *BMC Pediatr* 2005; **5**: 11 [PMID: 15907214 DOI: 10.1186/1471-2431-5-11]

6 **Telega G**, Bennet TR, Werlin S. Emerging new clinical patterns in the presentation of celiac disease. *Arch Pediatr Adolesc Med* 2008; **162**: 164-168 [PMID: 18250242 DOI: 10.1001/archpediatrics.2007.38]

7 **Hill ID**, Dirks MH, Liptak GS, Colletti RB, Fasano A, Guandalini S, Hoffenberg EJ, Horvath K, Murray JA, Pivor M, Seidman EG. Guideline for the diagnosis and treatment of celiac disease in children: recommendations of the North American Society for Pediatric Gastroenterology, Hepatology and Nutrition. *J Pediatr Gastroenterol Nutr* 2005; **40**: 1-19 [PMID: 15625418 DOI: 10.1097/00005176-200501000-00001]

8 **Catassi C**, Fabiani E, Rätsch IM, Coppa GV, Giorgi PL, Pierdomenico R, Alessandrini S, Iwanejko G, Domenici R, Mei E, Miano A, Marani M, Bottaro G, Spina M, Dotti M, Montanelli A, Barbato M, Viola F, Lazzari R, Vallini M, Guariso G, Plebani M, Cataldo F, Traverso G, Ventura A. The coeliac iceberg in Italy. A multicentre antigliadin antibodies screening for coeliac disease in school-age subjects. *Acta Paediatr Suppl* 1996; **412**: 29-35 [PMID: 8783752 DOI: 10.1111/j.1651-2227.1996.tb14244.x]

9 **Csizmadia CG**, Mearin ML, von Blomberg BM, Brand R, Verloove-Vanhorick SP. An iceberg of childhood coeliac disease in the Netherlands. *Lancet* 1999; **353**: 813-814 [PMID: 10459972 DOI:

10.1016/S0140-6737(99)00243-3]
10 **Ivarsson A**, Persson LA, Juto P, Peltonen M, Suhr O, Hernell O. High prevalence of undiagnosed coeliac disease in adults: a Swedish population-based study. *J Intern Med* 1999; **245**: 63-68 [PMID: 10095818 DOI: 10.1046/j.1365-2796.1999.00403.x]
11 **Cook HB**, Burt MJ, Collett JA, Whitehead MR, Frampton CM, Chapman BA. Adult coeliac disease: prevalence and clinical significance. *J Gastroenterol Hepatol* 2000; **15**: 1032-1036 [PMID: 11059933 DOI: 10.1046/j.1440-1746.2000.02290.x]
12 **Cook B**, Oxner R, Chapman B, Whitehead M, Burt M. A thirty-year (1970-1999) study of coeliac disease in the Canterbury region of New Zealand. *N Z Med J* 2004; **117**: U772 [PMID: 15014561]
13 **Oberhuber G**, Granditsch G, Vogelsang H. The histopathology of coeliac disease: time for a standardized report scheme for pathologists. *Eur J Gastroenterol Hepatol* 1999; **11**: 1185-1194 [PMID: 10524652 DOI: 10.1097/00042737-199910000-00019]
14 **Ussher R**, Yeong ML, Stace N. Coeliac disease: incidence and prevalence in Wellington 1985-92. *N Z Med J* 1994; **107**: 195-197 [PMID: 8196863]
15 **Carrington JM**, Hewitt CJ, Dowsett LR, Barbezat GO. The prevalence of coeliac disease in Otago. *N Z Med J* 1987; **100**: 460-462 [PMID: 3451125]
16 **Tanpowpong P**, Ingham TR, Lampshire PK, Kirchberg FF, Epton MJ, Crane J, Camargo CA. Coeliac disease and gluten avoidance in New Zealand children. *Arch Dis Child* 2012; **97**: 12-16 [PMID: 22075107 DOI: 10.1136/archdischild-2011-300248]
17 **McGowan KE**, Castiglione DA, Butzner JD. The changing face of childhood celiac disease in north america: impact of serological testing. *Pediatrics* 2009; **124**: 1572-1578 [PMID: 19948628 DOI: 10.1542/peds.2008-2373]
18 **Ivarsson A**, Hernell O, Stenlund H, Persson LA. Breast-feeding protects against celiac disease. *Am J Clin Nutr* 2002; **75**: 914-921 [PMID: 11976167]
19 **Lohi S**, Mustalahti K, Kaukinen K, Laurila K, Collin P, Rissanen H, Lohi O, Bravi E, Gasparin M, Reunanen A, Mäki M. Increasing prevalence of coeliac disease over time. *Aliment Pharmacol Ther* 2007; **26**: 1217-1225 [PMID: 17944736 DOI: 10.1111/j.1365-2036.2007.03502.x]
20 **Aurangzeb B**, Leach ST, Lemberg DA, Day AS. Nutritional status of children with coeliac disease. *Acta Paediatr* 2010; **99**: 1020-1025 [PMID: 20178518 DOI: 10.1111/j.1651-2227.2010.01732.x]
21 **Husby S**, Koletzko S, Korponay-Szabó IR, Mearin ML, Phillips A, Shamir R, Troncone R, Giersiepen K, Branski D, Catassi C, Lelgeman M, Mäki M, Ribes-Koninckx C, Ventura A, Zimmer KP. European Society for Pediatric Gastroenterology, Hepatology, and Nutrition guidelines for the diagnosis of coeliac disease. *J Pediatr Gastroenterol Nutr* 2012; **54**: 136-160 [PMID: 22197856 DOI: 10.1097/MPG.0b013e31821a23d0]
22 **Ooi CY**, Day AS, Jackson R, Bohane TD, Tobias V, Lemberg DA. Eosinophilic esophagitis in children with celiac disease. *J Gastroenterol Hepatol* 2008; **23**: 1144-1148 [PMID: 18070017 DOI: 10.1111/j.1440-1746.2007.05239.x]
23 **Leslie C**, Mews C, Charles A, Ravikumara M. Celiac disease and eosinophilic esophagitis: a true association. *J Pediatr Gastroenterol Nutr* 2010; **50**: 397-399 [PMID: 19841598 DOI: 10.1097/MPG.0b013e3181a70af4]
24 **Thompson JS**, Lebwohl B, Reilly NR, Talley NJ, Bhagat G, Green PH. Increased incidence of eosinophilic esophagitis in children and adults with celiac disease. *J Clin Gastroenterol* 2012; **46**: e6-e11 [PMID: 21778897 DOI: 10.1097/MCG.0b013e318221aefd]
25 **Verzegnassi F**, Bua J, De Angelis P, Dall'oglio L, Di Leo G, Ventura A. Eosinophilic oesophagitis and coeliac disease: is it just a casual association? *Gut* 2007; **56**: 1029-1030 [PMID: 17566042 DOI: 10.1136/gut.2006.117986]

P- Reviewer: Sangkhathat S, Urganci N
S- Editor: Tian YL **L- Editor**: A **E- Editor**: Jiao XK

World Journal of Clinical Pediatrics

Submit a Manuscript: http://www.wjgnet.com/esps/
Help Desk: http://www.wjgnet.com/esps/helpdesk.aspx
DOI: 10.5409/wjcp.v4.i4.155

World J Clin Pediatr 2015 November 8; 4(4): 155-159
ISSN 2219-2808 (online)
© 2015 Baishideng Publishing Group Inc. All rights reserved.

ORIGINAL ARTICLE

Retrospective Study

Use of laparoscopy as the initial surgical approach of impalpable testes: 10-year experience

Kin Wai Edwin Chan, Kim Hung Lee, Hei Yi Vicky Wong, Siu Yan Bess Tsui, Yuen Shan Wong, Kit Yi Kristine Pang, Jennifer Wai Cheung Mou, Yuk Him Tam

Kin Wai Edwin Chan, Kim Hung Lee, Hei Yi Vicky Wong, Siu Yan Bess Tsui, Yuen Shan Wong, Kit Yi Kristine Pang, Jennifer Wai Cheung Mou, Yuk Him Tam, Division of Paediatric Surgery and Paediatric Urology, Department of Surgery, the Prince of Wales Hospital, the Chinese University of Hong Kong, Hong Kong, China

Author contributions: Chan KWE contributed to the study design, literature search, manuscript writing and final revision of the article; Wong HYV, Tsui SYB, Wong YS, Pang KYK and Mou JWC performed the research; Lee KH and Tam YH contributed to supervision.

Institutional review board statement: The study was reviewed and approved by the Joint CUHK-NTEC Clinical Research Ethics Committee (CREC) (CRE Ref. No. 2015.318).

Informed consent statement: As anonymized administrative and clinical data were used for this study, specific written consent was not required to use patient information stored in hospital databases.

Conflict-of-interest statement: The authors declare that there is no conflict of interest to disclose.

Data sharing statement: No additional data are available.

Open-Access: This article is an open-access article which was selected by an in-house editor and fully peer-reviewed by external reviewers. It is distributed in accordance with the Creative Commons Attribution Non Commercial (CC BY-NC 4.0) license, which permits others to distribute, remix, adapt, build upon this work non-commercially, and license their derivative works on different terms, provided the original work is properly cited and the use is non-commercial. See: http://creativecommons.org/licenses/by-nc/4.0/

Correspondence to: Dr. Kin Wai Edwin Chan, MBChB, FRCSEd (Paed), FCSHK, FHKAM (Surgery), Division of Paediatric Surgery and Paediatric Urology, Department of Surgery, the Prince of Wales Hospital, the Chinese University of Hong Kong, Shatin, New Territories, Hong Kong, China. edwinchan@surgery.cuhk.edu.hk

Telephone: +852-26322953
Fax: +852-26324669

Received: May 8, 2015
Peer-review started: May 9, 2015
First decision: July 10, 2015
Revised: July 23, 2015
Accepted: August 13, 2015
Article in press: August 14, 2015
Published online: November 8, 2015

Abstract

AIM: To review the experience in the management of impalpable testes using laparoscopy as the initial approach and the need for inguinal exploration.

METHODS: From January 2004 to June 2014, 339 patients with undescended testes underwent operation in our institute. Fifty patients (15%) had impalpable testes. All children with impalpable testes underwent initial laparoscopy. A retrospective review was conducted on this group of patients and the outcome was analyzed.

RESULTS: Forty children had unilateral impalpable testis. Ten children had bilateral impalpable testes. Thirty-one children (78%) in the unilateral group underwent subsequent inguinal exploration while 4 children (40%) in the bilateral group underwent inguinal exploration ($P < 0.05$). Orchidopexy was performed in 16 children (40%) in the unilateral group and 9 children (90%) in the bilateral group ($P < 0.05$). Regarding the 24 children with unilateral impalpable testis and underwent orchidectomy for testicular nubbin ($n = 19$) or atrophic testes ($n = 2$) or has vanishing testes ($n = 3$); contralateral testicular hypertrophy was noticed in 10 (41%). No intra-operative complication was encountered. Two children after staged Fowler-Stephens

procedure and 1 child after inguinal orchidopexy had atrophic testes.

CONCLUSION: The use of laparoscopy in children with impalpable testes is a safe procedure and can guide the need for subsequent inguinal exploration. Children with unilateral impalpable testis were associated with an increased need for inguinal exploration after laparoscopy. Orchidopexies could be performed successfully in 90% of children with bilateral impalpable testes.

Key words: Laparoscopy; Impalpable; Testis; Inguinal

© The Author(s) 2015. Published by Baishideng Publishing Group Inc. All rights reserved.

Core tip: Among over 300 children with undescended testis underwent operation, 15% of children had impalpable testis. The review studies the use of laparoscopy as the initial management of children with impalpable testes. Compared with children with bilateral impalpable testes, children with unilateral impalpable testis had an increased need for subsequent inguinal exploration and a lower incidence of successful orchidopexy. Laparoscopy is a safe procedure with no intra-operative complication encountered in this study.

Chan KWE, Lee KH, Wong HYV, Tsui SYB, Wong YS, Pang KYK, Mou JWC, Tam YH. Use of laparoscopy as the initial surgical approach of impalpable testes: 10-year experience. *World J Clin Pediatr* 2015; 4(4): 155-159 Available from: URL: http://www.wjgnet.com/2219-2808/full/v4/i4/155.htm DOI: http://dx.doi.org/10.5409/wjcp.v4.i4.155

INTRODUCTION

Cryptorchidism is a common pediatric surgical condition that affected 2%-5% of new born[1]. If left untreated, cryptorchidism poses risk in malignancy and infertility[1-4]. In a child with a palpable testis at inguinal region, orchidopexy is recommended to be performed at 6-12 mo-of-age if spontaneous descend of the testis does not occurred by 6 mo-of-age[3]. On the other hand, in a child with an impalpable testis, ultrasonography of the inguinal canal is required locate the testis in pre-operative evaluation[4].

In the era of minimally invasive surgery, laparoscopy was advocated as the initial surgical approach in children with impalpable testes[5-8]. Laparoscopy can confirm the presence or absence of intra-abdominal testes and can direct the subsequent approach. However, others suggested that inguinal or scrotal exploration should be used as the initial approach in children with unilateral impalpable testis[9-11].

In our institute, all children with impalpable testes underwent initial laparoscopy. This study aimed to study the outcome of children using this approach.

MATERIALS AND METHODS

From January 2004 to June 2014, 339 boys with undescended testes underwent operation in our institute. Fifty children (15%) had impalpable testes. Impalpable testis was defined as the testis was not palpable under general anesthesia. The median age for children at the time of operation with impalpable testis was 26 mo (range: 8-192 mo). They all underwent laparoscopy as the initial procedure.

Operative procedure

All patients were examined again under general anesthesia and confirmed the diagnosis of impalpable testes. A sub-umbilical incision was made and a 5 mm 30 degree laparoscope was used. If the testis was identified intra-abdominally (Figure 1), two 3 or 5 mm ports were inserted over the abdomen; either one-stage laparoscopic or two-staged laparoscopic Fowler-Stephens orchidopexy was performed. If a blind ended vas was located away from the deep ring, the testis was defined vanished. If both vas and testicular vessels entered into the deep ring (Figure 2), an inguinal exploration was then performed. Inguinal orchidopexy was performed for normal looking testis. If a testicular nubbin or an atrophic testis was identified, it would be excised and sent for histological examination. For peeping testis, orchidopexy was performed by either inguinal or laparoscopic approach, depending on the surgeon's preference.

The age of the patients, the laterality of the testes, the presence of any contralateral testicular hypertrophy on physical examination, the laparoscopic findings and the need for inguinal exploration, the incidence of orchidopexy and any intraoperative and post-operative complication were reviewed.

Statistical analysis

Statistical analysis was accomplished using the SPSS program for Windows 21.0 (SPSS, Chicago, Illinois, United States). Fisher exact test was used to compare the categorical data. $P < 0.05$ was considered statistically significant. The statistical methods of this study were reviewed by Yuk Him Tam from the Prince of Wales Hospital.

RESULTS

Forty children had unilateral impalpable testis. Ten children had bilateral impalpable testes. Orchidopexy was performed in 16 children (40%) in the unilateral group and 9 children (90%) in the bilateral group ($P < 0.05$) (Figures 3 and 4).

Unilateral group

Regarding the 16 children who underwent orchidopexy, 12 children underwent inguinal orchidopexy (5 peeping testes), 3 children underwent Fowler-Stephens operation (1 peeping testis) and 1 child underwent laparoscopic

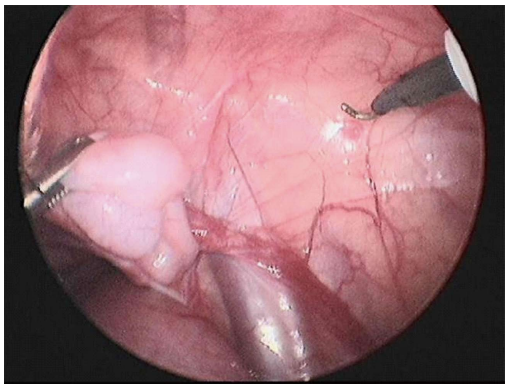

Figure 1 Laparoscopic view of a right undescended testis.

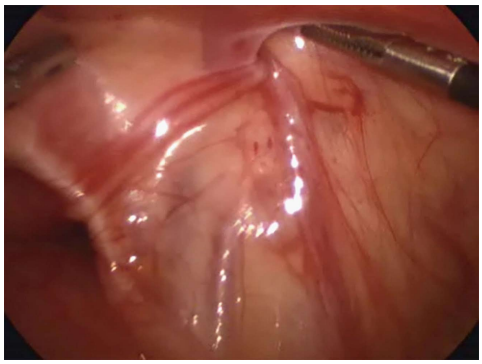

Figure 2 Vas deferens and vessel enter into the right deep ring, a groin exploration is required.

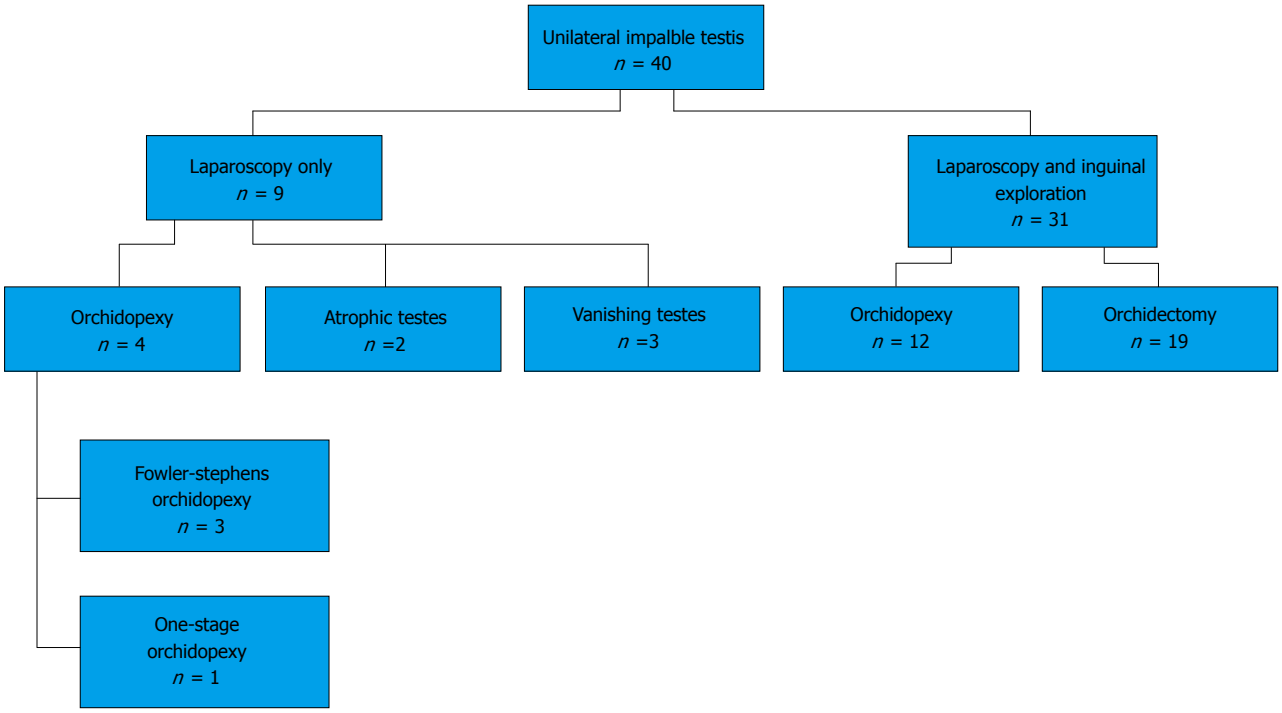

Figure 3 A flow chart showing the management of children with unilateral impalpable testis.

Table 1 The association of the need for inguinal exploration and orchidopexy in children with unilateral or bilateral impalpable testes

		Unilateral impalpable testis n = 40	Bilateral impalpable testis n = 10	P value
Inguinal exploration	Required	31	4	0.03
	Not required	9	6	
Orchidopexy	Performed	16	9	0.005
	Not performed	24	1	

one stage orchidopexy. Twenty-one children have "orchidectomy" performed for the testicular nubbin (n = 19) or atrophic testis (n = 2). Three children had vanishing testes. Out of the 24 children who underwent orchidectomy or has vanishing testes, contralateral testicular hypertrophy was noticed in 10 children (41%). Children with left impalpable testis has a lower rate of orchidopexy (L: 35%, 9/17, R: 50%, 7/7), However the difference did not reach statistical significant (Figure 3, Tables 1 and 2).

Bilateral group

Orchidopexy were performed in 18 testes (90%). Inguinal orchidopexy was performed in 7 testes. Fowler–

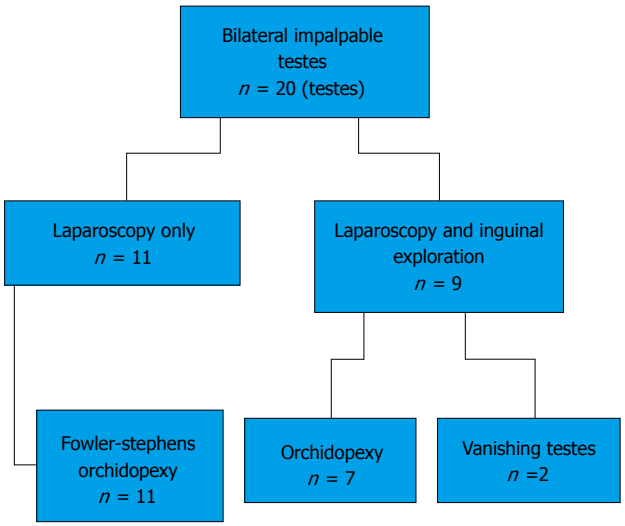

Figure 4 A flow chart showing the management of children with bilateral impalpable testes.

Stephens procedure was performed in 11 testes. One child had bilateral vanishing testes upon inguinal exploration (Figure 4).

Inguinal exploration

Thirty-one children (78%) in the unilateral group underwent subsequent inguinal exploration while only 4 children (40%) in the bilateral group underwent groin exploration ($P < 0.05$). In the unilateral group, children with left impalpable testis had a higher need for inguinal exploration (L: 85%, 22/26, R: 64%, 9/14) but the difference did not reach statistical significance (Tables 1 and 2).

Outcome

No intraoperative complication was encountered. Histological examination showed absence of testicular tissue in all the nubbins. Benign testicular tissues were identified in the 2 atrophic testes. The mean follow up was 53 mo (range 10 to 198 mo). Testicular atrophy was noticed in 2 children after 2nd stage Fowler-Stephen procedure and 1 child after inguinal orchidopexy.

DISCUSSION

There is ongoing debate on the best initial approach for impalpable testis. Our study showed in children with unilateral impalpable testis, 78% of children required an inguinal incision. In reports which used laparoscopy as the initial approach for impalpable testes, the need for inguinal or scrotal exploration for unilateral impalpable testis ranged from 38% to 85%[12,13]. Ethnic, geographic and genetic reasons may account for the difference in the incidence of intra-abdominal testes in children with impalpable testes[13-15]. Although a high proportion of children with unilateral impalpable testes required an inguinal incision, initial laparoscopy directed the subsequent approach without any intraoperative complication encountered in this study.

Table 2 The association of the need for inguinal exploration and orchidopexy with the laterality of testes in children with unilateral impalpable testis

		Left n = 26	Right n = 14	P value
Inguinal exploration	Required	22	9	0.14
	Not required	4	5	
Orchidopexy	Performed	9	7	0.27
	Not performed	17	7	

Regarding the laterality of the unilateral impalpable testis, the testis was more commonly located on the left side (65%). Eighty-five percent of children with left impalpable testis had inguinal exploration while only 64% of children with right impalpable testis had inguinal exploration. Park *et al*[16] had similar finding in their study but other studies did not report the laterality of the testes[7,8]. In children with bilateral impalpable testes, only 40% of children in this study required additional inguinal exploration. Sixty-five percent (13/20) of testes can be managed by laparoscopy alone, including 2 vanishing testes.

Fifty three percent of children with unilateral impalpable testis underwent orchidectomy. Majority of children had either a testicular nubbin or a vanishing testis. Intrauterine loss was the postulated etiology in children with unilateral impalpable testis[17]. Studies showed if contralateral testicular size larger than 1.8 cm predict testicular loss on the symptomatic side[11,17]. In this study, we used subjective manual assessment, which may not be as accurate as the measurement by ultrasonography. Although only 41% of children with unilateral testicular loss showed contralateral testicular hypertrophy, this physical finding can provide additional information in pre-operative counseling.

Germ cell was reported to be present in up to 16% of the testicular nubbin specimen[18]. In this study, pathological study of the testicular nubbin did not detect any testicular tissue. We think it is still a reasonable approach the removed the nubbin in order to confirm the histology.

The success rate after laparoscopic assisted orchidopexy was 87% (13/15). There were reports studying the success rate of different laparoscopic approaches including one-stage laparoscopic repair, one-stage Fowler-Stephens or two-stage Fowler-Stephens repair[19-21]. The assessment on the feasibility of one stage laparoscopic repair may be difficult. Two-stage Fowler-Stephens orchidopexy may be the treatment of choice for all intra-abdominal testes, if there was any doubt in decision of the laparoscopic approach intra-operatively[22].

One of the limitations of this study is on the decision of surgical approach in peeping testis. Five out of 6 peeping testes were managed by inguinal orchidopexy. Both inguinal and laparoscopic approaches were eff-

ective in the management of peeping testis[23]. Our approach increased the number of inguinal exploration in this study.

COMMENTS

Background

In the era of minimally invasive surgery, laparoscopy was advocated as the initial approach in children with impalpable testes. Laparoscopy can confirm the presence or absence of intra-abdominal testes and can direct the subsequent approach.

Research frontiers

Controversies still exist on the best initial approach in the management of impalpable testis. Others suggested that inguinal or scrotal exploration should be used as the initial approach in children with unilateral impalpable testis.

Innovations and breakthroughs

This study showed in children with unilateral impalpable testis, 78% of children required an inguinal incision. Orchidopexies could be performed successfully in 90% of children with bilateral impalpable testes.

Applications

Laparoscopy is a safe procedure with no intra-operative complication encountered in this study. A prospective study is needed to study the best initial approach in unilateral impalpable testis.

Terminology

Cryptorchidism: Impalpable testis or undescended testis. Impalpable testis: The testis is not palpable in scrotum or at groin after general anesthesia. First stage Fowler-Stephens operation: Division of the testicular vessels which aids the development of collateral vessels along the vas deferens. Second stage Fowler-Stephens operation: Mobilization of the testis into the scrotum.

Peer-review

This is a retrospective study of 50 children with impalpable testes who have been managed by laparoscopy as the initial treatment and perhaps the initial diagnostic procedure as well. The paper is well written and the messages are clear.

REFERENCES

1 **Toppari J**, Kaleva M. Maldescendus testis. *Horm Res* 1999; **51**: 261-269 [PMID: 10640886]

2 **Chan E**, Wayne C, Nasr A. Ideal timing of orchiopexy: a systematic review. *Pediatr Surg Int* 2014; **30**: 87-97 [PMID: 24232174 DOI: 10.1007/s00383-013-3429-y]

3 **Thomas RJ**, Holland AJ. Surgical approach to the palpable undescended testis. *Pediatr Surg Int* 2014; **30**: 707-713 [PMID: 24871526 DOI: 10.1007/s00383-014-3518-6]

4 **Vos A**, Vries AM, Smets A, Verbeke J, Heij H, van der Steeg A. The value of ultrasonography in boys with a non-palpable testis. *J Pediatr Surg* 2014; **49**: 1153-1155 [PMID: 24952806 DOI: 10.1016/j.jpedsurg.2013.09.011]

5 **Cisek LJ**, Peters CA, Atala A, Bauer SB, Diamond DA, Retik AB. Current findings in diagnostic laparoscopic evaluation of the nonpalpable testis. *J Urol* 1998; **160**: 1145-1149; discussion 1150 [PMID: 9719296]

6 **Baker LA**, Docimo SG, Surer I, Peters C, Cisek L, Diamond DA, Caldamone A, Koyle M, Strand W, Moore R, Mevorach R, Brady J, Jordan G, Erhard M, Franco I. A multi-institutional analysis of laparoscopic orchidopexy. *BJU Int* 2001; **87**: 484-489 [PMID: 11298039]

7 **Sheikh A**, Mirza B, Ahmad S, Ijaz L, Kayastha K, Iqbal S. Laparoscopic management of 128 undescended testes: our experience. *Afr J Paediatr Surg* 2012; **9**: 106-108 [PMID: 22878756 DOI: 10.4103/0189-6725.99393]

8 **Papparella A**, Parmeggiani P, Cobellis G, Mastroianni L, Stranieri G, Pappalepore N, Mattioli G, Esposito C, Lima M. Laparoscopic management of nonpalpable testes: a multicenter study of the Italian Society of Video Surgery in Infancy. *J Pediatr Surg* 2005; **40**: 696-700 [PMID: 15852282]

9 **Kanemoto K**, Hayashi Y, Kojima Y, Tozawa K, Mogami T, Kohri K. The management of nonpalpable testis with combined groin exploration and subsequent transinguinal laparoscopy. *J Urol* 2002; **167**: 674-676 [PMID: 11792951]

10 **Snodgrass W**, Chen K, Harrison C. Initial scrotal incision for unilateral nonpalpable testis. *J Urol* 2004; **172**: 1742-1745; discussion 1745 [PMID: 15371803]

11 **Snodgrass WT**, Yucel S, Ziada A. Scrotal exploration for unilateral nonpalpable testis. *J Urol* 2007; **178**: 1718-1721 [PMID: 17707015]

12 **Castillo-Ortiz J**, Muñiz-Colon L, Escudero K, Perez-Brayfield M. Laparoscopy in the surgical management of the non-palpable testis. *Front Pediatr* 2014; **2**: 28 [PMID: 24783184 DOI: 10.3389/fped.2014.00028]

13 **Ueda N**, Shiroyanagi Y, Suzuki H, Kim WJ, Yamazaki Y, Tanaka Y. The value of finding a closed internal ring on laparoscopy in unilateral nonpalpable testis. *J Pediatr Surg* 2013; **48**: 542-546 [PMID: 23480909 DOI: 10.1016/j.jpedsurg.2012.09.032]

14 **Papparella A**, Romano M, Noviello C, Cobellis G, Nino F, Del Monaco C, Parmeggiani P. The value of laparoscopy in the management of non-palpable testis. *J Pediatr Urol* 2010; **6**: 550-554 [PMID: 20106723 DOI: 10.1016/j.jpurol.2009.12.010]

15 **Abbas TO**, Hayati A, Ismail A, Ali M. Laparoscopic management of intra-abdominal testis: 5-year single-centre experience-a retrospective descriptive study. *Minim Invasive Surg* 2012; **2012**: 878509 [PMID: 22474586 DOI: 10.1155/2012/878509]

16 **Park JH**, Park YH, Park K, Choi H. Diagnostic laparoscopy for the management of impalpable testes. *Korean J Urol* 2011; **52**: 355-358 [PMID: 21687397 DOI: 10.4111/kju.2011.52.5.355]

17 **Belman AB**, Rushton HG. Is the vanished testis always a scrotal event? *BJU Int* 2001; **87**: 480-483 [PMID: 11298038]

18 **Renzulli JF**, Shetty R, Mangray S, Anderson KR, Weiss RM, Caldamone AA. Clinical and histological significance of the testicular remnant found on inguinal exploration after diagnostic laparoscopy in the absence of a patent processus vaginalis. *J Urol* 2005; **174**: 1584-1586; discussion 1586 [PMID: 16148657]

19 **Mehendale VG**, Shenoy SN, Shah RS, Chaudhari NC, Mehendale AV. Laparoscopic management of impalpable undescended testes: 20 years' experience. *J Minim Access Surg* 2013; **9**: 149-153 [PMID: 24250059 DOI: 10.4103/0972-9941.118822]

20 **Alzahem A**. Laparoscopy-assisted orchiopexy versus laparoscopic two-stage fowler stephens orchiopexy for nonpalpable testes: Comparative study. *Urol Ann* 2013; **5**: 110-114 [PMID: 23798870 DOI: 10.4103/0974-7796.110010]

21 **Singh RR**, Rajimwale A, Nour S. Laparoscopic management of impalpable testes: comparison of different techniques. *Pediatr Surg Int* 2011; **27**: 1327-1330 [PMID: 21882045 DOI: 10.1007/s00383-011-2970-9]

22 **Burjonrappa SC**, Al Hazmi H, Barrieras D, Houle AM, Franc-Guimond J. Laparoscopic orchidopexy: the easy way to go. *J Pediatr Surg* 2009; **44**: 2168-2172 [PMID: 19944228 DOI: 10.1016/j.jpedsurg.2009.06.022]

23 **Elderwy AA**, Kurkar A, Abdel-Kader MS, Abolyosr A, Al-Hazmi H, Neel KF, Hammouda HM, Elanany FG. Laparoscopic versus open orchiopexy in the management of peeping testis: a multi-institutional prospective randomized study. *J Pediatr Urol* 2014; **10**: 605-609 [PMID: 25042877 DOI: 10.1016/j.jpurol.2014.06.006]

P- Reviewer: Eric M, Golffier C, Lee ACW
S- Editor: Ji FF **L- Editor**: A **E- Editor**: Jiao XK

World Journal of Clinical Pediatrics

Submit a Manuscript: http://www.wjgnet.com/esps/
Help Desk: http://www.wjgnet.com/esps/helpdesk.aspx
DOI: 10.5409/wjcp.v4.i4.160

World J Clin Pediatr 2015 November 8; 4(4): 160-166
ISSN 2219-2808 (online)
© 2015 Baishideng Publishing Group Inc. All rights reserved.

SYSTEMATIC REVIEWS

Inflammatory fibroid polyps in children: A new case report and a systematic review of the pediatric literature

Laura Righetti, Filippo Parolini, Paolo Cengia, Giovanni Boroni, Maurizio Cheli, Aurelio Sonzogni, Daniele Alberti

Laura Righetti, Filippo Parolini, Giovanni Boroni, Department of Pediatric Surgery, Spedali Civili Hospital, 25123 Brescia, Italy

Paolo Cengia, Department of Surgery, Spedali Civili Hospital, 25123 Brescia, Italy

Maurizio Cheli, Department of Pediatric Surgery, Papa Giovanni XXXIII Hospital, 24127 Bergamo, Italy

Aurelio Sonzogni, Department of Pathology, Papa Giovanni XXXIII Hospital, 24127 Bergamo, Italy

Daniele Alberti, Department of Pediatric Surgery, Spedali Civili Hospital, University of Brescia, 25123 Brescia, Italy

Author contributions: Righetti L, Parolini F, Cengia P and Boroni G conceptualized and designed the study, designed the data collection instruments, drafted the initial manuscript, reviewed and revised the manuscript; Cheli M, Sonzogni A and Alberti D conceptualized the study and critically reviewed the manuscript; all the authors approved the final manuscript as submitted.

Conflict-of-interest statement: We hereby declare that the following information relevant to this article are true to the best of our knowledge: The above mentioned manuscript has not been published, accepted for publication or under editorial review for publication elsewhere and it won't be submitted to any other journal while under consideration for publication in your Journal; we have no financial relationship relevant to this article to disclose; there isn't any conflict of interest relevant to this article; all authors participated in the concept and design, analysis and interpretation of data, drafting and revising the manuscript, and they have approved the manuscript as submitted.

Data sharing statement: No additional data are available.

Open-Access: This article is an open-access article which was selected by an in-house editor and fully peer-reviewed by external reviewers. It is distributed in accordance with the Creative Commons Attribution Non Commercial (CC BY-NC 4.0) license, which permits others to distribute, remix, adapt, build upon this work non-commercially, and license their derivative works on different terms, provided the original work is properly cited and the use is non-commercial. See: http://creativecommons.org/licenses/by-nc/4.0/

Correspondence to: Filippo Parolini, BS, MD, Department of Paediatric Surgery, Spedali Civili Hospital, Piazzale Spedali Civili 1, 25123 Brescia, Italy. parfil@hotmail.it
Telephone: +39-3-3996201
Fax: +39-3-3996154

Received: July 14, 2015
Peer-review started: July 15, 2015
First decision: July 31, 2015
Revised: September 12, 2015
Accepted: September 29, 2015
Article in press: September 30, 2015
Published online: November 8, 2015

Abstract

AIM: To study that inflammatory fibroid polyps (IFPs) in children are extremely uncommon tumors that may occur throughout the gastrointestinal tract.

METHODS: A systematic review of the pediatric literature and a report of a new case of IFP is also presented. The PubMed database was searched for original studies on pediatric IFPs since 1960, according to "Preferred reporting items for systematic reviews and meta-analyses" guidelines for systematic reviews.

RESULTS: Five studies were finally enclosed, encompassing 6 children with IFPs (mean age 64 mo). Tumors were located in the stomach (2 patients), in the small bowel (2 patients), in the rectum (1 patient) and in the colon (1 patient). Open surgery was performed in all patients and complete excision of the mass was achieved in all cases. All patients are alive and free of symptom. Authors described a further case of a 3-year-

old boy with a large duodenal IFP, in whom the tumor was removed by "en block resection". The presence of IFP throughout the gastrointestinal tract and its variable clinical appearances make it difficult to diagnose. An accurate pre-operative assessment is fundamental in order to differentiate IFP from other more aggressive gastrointestinal tumor, enabling unnecessary demolitive surgery.

CONCLUSION: When complete resection of the IFP is achieved, the prognosis is excellent.

Key words: Inflammatory fibroid polyp; Duodenum; Ultrasound endoscopy; Children; Surgery

© **The Author(s) 2015.** Published by Baishideng Publishing Group Inc. All rights reserved.

Core tip: We present a new case of inflammatory fibroid polyp (IFP) occurring in a 3-year-old child who, to the best of our knowledge, is the first reported case of duodenal IFP in childhood. Below is a detailed systematic review of the literature on paediatric IFPs, focusing on etiopatogenesis, clinical presentation, diagnostic assessment and treatment.

Righetti L, Parolini F, Cengia P, Boroni G, Cheli M, Sonzogni A, Alberti D. Inflammatory fibroid polyps in children: A new case report and a systematic review of the pediatric literature. *World J Clin Pediatr* 2015; 4(4): 160-166 Available from: URL: http://www.wjgnet.com/2219-2808/full/v4/i4/160.htm DOI: http://dx.doi.org/10.5409/wjcp.v4.i4.160

INTRODUCTION

Inflammatory fibroid polyp (IFP) is an uncommon benign lesion that may occur throughout the gastrointestinal tract, even if stomach is the most affected site[1,2]. IFP natural history is unknown but rapid growth of the lesion within few months has been reported. IFP is found in all age groups but its typical presentation is in the 5th to 7th decade of life[2]; occurrence in children is extremely rare, with only 6 reported cases[3-7]. We present a new case of IFP occurring in a 3-year-old child who the best of our knowledge is the first reported case of duodenal IFP in childhood. A detailed systematic review of the literature on pediatric IFPs, focusing on ethiopatogenesis, clinical presentation, diagnostic assessment and treatment is then provided. A 3-year-old boy was referred to our Centre because of asthenia and anorexia. Physical examination was unremarkable. Blood test revealed a microcytic hypochromic anemia and eosinophilia; stools were positive both for heme and Enterobius Vermicularis. Upper GI endoscopy showed a 3.7 cm peduncolated mass of the duodenum. Contrast enhanced Abdominal MRI detected homogeneous enhancement of the mass after contrast (Figure 1). The tumor was close to the pancreatic head, but the common bile duct and the papilla major were spared. Endoscopic ultrasound (EUS), showed an hypoechoic mass located into the submucosa (echo-layer 3), not completely separated from the muscularis propria (echo-layer 4). In some EUS scans, the lesion showed features suggesting origin from the muscular layer, thus mimicking gastrointestinal stromal tumors (GIST) features (Figure 2). Cytological analysis of EUS fine needle aspiration (FNA) was compatible with diagnosis of leiomyoma. At laparotomy the mass deformed the postero-lateral wall of the proximal duodenum; the sero-muscular wall at tumor level was longitudinally severed but the lack of a cleavage with the submucosa did not allow local tumor excision. Intraoperative histological examination showed mesenchymal spindle cells proliferation with an inflammatory eosinophilic infiltrate, without morphological features suggesting malignancy. The tumor was completely removed by partial en block duodenectomy (Figure 3), followed by a duodenal inverted Y plasty. Histological findings were compatible with diagnosis of IFP: stromal looking cells with marked inflammatory eosinophilic infiltrates was evident, with no presence of mitosis or necrotic areas (Figure 4). The lesion was immunoistochemically reactive to vimentin (Figure 4) and CD34, and negative to citocheratins AE1-AE3 and CAM-5.2, LCA, CD20, CD3, ALK1, CD21, CD23, CD35, CD117, S100, CD1a, muscular markers (desmin, smooth and striated muscle), neuro-endocrine markers (cromagranin, sinaptofisin, CD56), D2-40, EMA, Mieloperossidase, CD99, GFAP. Proliferative index Ki67 was 2%. *H. pylori* research was negative. The postoperative course was unremarkable, and the patient was discharged home on post-operative day-7. Radio-allergo-absorbent test 6 mo later was positive for cow's milk protein allergy. At 4-year-follow-up the child is doing well.

MATERIALS AND METHODS

Data sources and study selection

For this systematic review we adhered to Preferred reporting items for systematic reviews and meta-analyses guidelines[8,9]. The PubMed database was searched for studies on IFP that were published since 1960. The date of the last search was December 2014. Inclusion criteria were English articles that reported original data on IFPs in pediatric setting. Eligible study designs were case report, case series and review. We omitted reports in which titles or abstracts indicated that they were on adult population (> 18 years) and they not clearly reported the method of diagnosis and treatment. We then evaluated the full text of the passed articles. Titles and abstracts of identified publications were checked and reviewed against the predefined inclusion criteria, and afterward, the full text articles was similarly

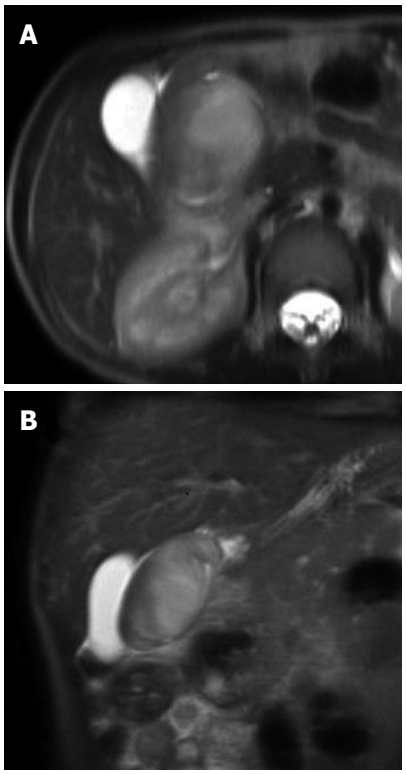

Figure 1 T2- weighted magnetic resonance image in axial (A) and coronal (B) scans, showing the solid mass arising from the duodenum.

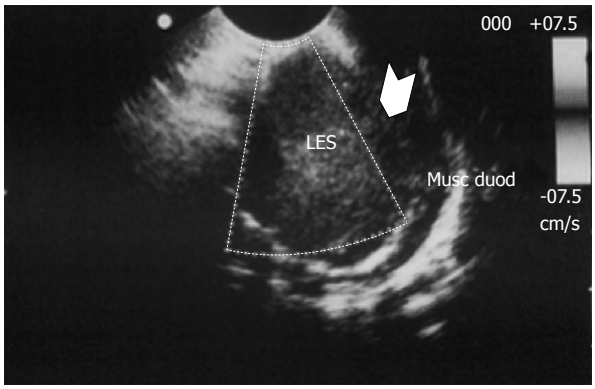

Figure 2 Endoscopic ultrasound showed an homogeneous, hypoechoic mass of 36 mm located into the echo-layer 3 (submucosa), but not completely separated from the muscularis propria (echo-layer 4); in some endoscopic ultrasound scans, the lesion showed features suggesting origin from the muscular layer, thus mimicking gastrointestinal stromal tumors features. The wall of the lesion was homogeneous and the external part showed hyperechoic spots, suggestive of microcalcifications.

assessed for eligibility.

Data extraction and quality assessment

Two independent authors extracted information related to the study. Methodological quality of the studies was assessed with the level of evidence and the strength of guideline recommendations in diagnosis scales[8]. For each study, data were extracted for age at presentation, sex, clinical presentation, size and location, diagnostic assessment, treatment, pathological examination and outcome.

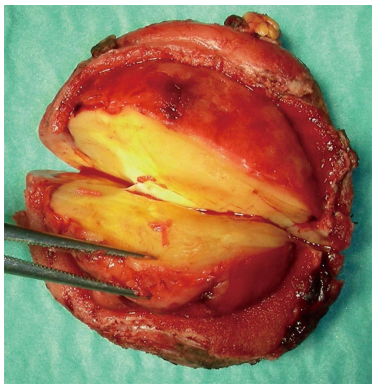

Figure 3 Gross examination: Firm round yellowish mass without necrosis and with an overlying area of mucosal ulceration.

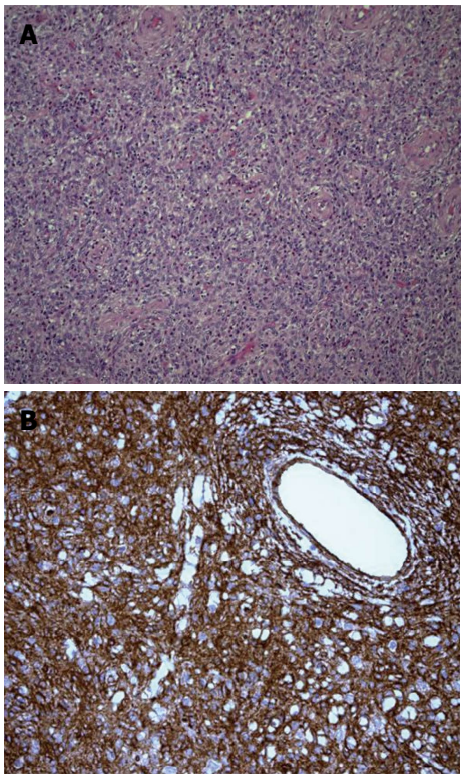

Figure 4 Stromal looking cells has no presence of mitosis or necrotic areas and the lesion was immunoistochemically reactive to vimentin. A: Stromal looking cells intermixed with marked inflammatory infiltrates rich in eosinophils granulocytes (40 ×); B: Marked immunohistochemical positivity to vimentin.

RESULTS

Description of studies

The initial PubMed search yielded 126 potentially relevant articles. Finally, 5 eligible articles met all the inclusion criteria and were enclosed in the review, encompassing a total of 6 cases. All reviewed studies were case reports (classes of evidence Ⅲ and rating scales of evidence E)[8].

Table 1 Demographics, clinical characteristics, diagnostic tools and treatment of inflammatory fibroid polyp in children

Ref.	Sex	Age (yr)	Clinical/laboratory	Diagnostic tools	Location	Size (cm)	Morphology	Treatment	Histology/immunohistochemistry	Follow-up
Samter *et al*[3]	Male	4	Acute abdomen	X-ray	Transverse colon	3.5 × 3.5 × 3	Peduncolated	Resection of transverse colon (7 cm), including a perforated diverticulum proximal to an obstructive intraluminal polyp	Granulation tissue containing an infiltrate of plasma cells Europhiles, lymphocytes and eosinophils; the predominant cells were stellate and spindle-shaped cells with plump vesicular nuclei an even chromatin distribution; numerous blood vessels	Alive and free from disease
Samter *et al*[3]	Female	8	Vomiting, diarrhea, cherry colored stools, palpable mass in RLQ1, hypochromic anemia	X-ray	Jejunum	5 × 3.7 × 3	Sessile	Resection of jejunum (12 cm)	Closely packed collagen fibers, and spindle-shaped cells with vesicular nuclei; inflammatory infiltrated composed by neutrophils, lymphocytes and eosinophils	Alive and free from disease
Persoff *et al*[4]	Male	3	Intermittent crampy abdominal pain and vomiting	X-ray Upper gastrointestinal series	Ileum	3	Peduncolated	Resection of ileum, including an ileo-ileal intussusception on intraluminal polyp	Proliferating edematous fibro vascular tissue diffusely infiltrated with inflammatory cells, many of with eosinophils, that involved all layers of the bowel wall except the mucosa	Alive and free from disease
Pollice *et al*[5]	Male	8	Recurrent enterorrhagy, anemia	Colonoscopy	Rectum	3 × 1.5	Sessile	Resection of rectum (7 cm)	Fibrous connective tissue with collagenous fibers arranged in large bundles; the inflammatory infiltrates consisted mainly of plasma cells and lymphocytes; numerous thin walled capillaries, sometimes dilated	Alive and free from disease
Schroeder *et al*[6]	Female	5	Epigastric pain, weakness, splenomegaly, hypocromic anemia	Ultrasound, CT	Stomach	Several cm	Endoexophytic	Subtotal gastrectomy	Not reported	Alive and free from disease
Chongsrisawat *et al*[7]	Female	4	Fever, arthralgia and severe anemia (Hb 3.9 g/dL)	Upper gastrointestinal series	Stomach	5 × 8	Sessile	Partial gastrectomy	Proliferative fibroblast and blood vessels admixed with mixed inflammatory cell infiltrated in stroma	Alive and free from disease
Our patient	Male	3	Asthenia, anorexia, hypochromic anemia, eoshinophylia	Upper GI endoscopy MRI EUS with FNA	Duodenum	3.7	Sessile	Partial "*en bloc*" with the tumor duodenectomy	Inflammatory infiltrates rich in eosinophils and stromal spindle-shaped cells, with no evidence of mitosis and necrotic areas	Alive and free from disease

CT: Computed tomography; GI: Glycemic index; MRI: Magnetic resonance imaging; EUS: Endoscopic ultrasound; FNA: Fine needle aspiration.

Systematic review

In this series, IFPs affected both sex equally. Mean age of presentation was 64 (SD 2.16) mo, with a different distribution throughout the GI tract: in 2 patients (33%) IFP arose in the stomach, in 2 (33%) in the small bowel, and in remaining 2 patients, one IFP was in the rectum and one in the colon. In 2 patients (33%) the polyp was pedunculated, in 2 (33%) was sessile, and endoexophytic in the remaining 2 (Table 1).

Abdominal pain is the most common referred symptom, although physical examination was generally unremarkable in this series, except for in an 8-year-old girl who displayed a palpable mass in right lower quadrant[3]. Chronic anemia was the most common sign, present in 4 patients (67%). Recurrent enterhorragy and vomiting were also frequent. Chongsrisawat *et al*[7] reported a 4-year-old girl with atypical presentation, with chronic fever, arthralgia of knees and ankles, iron deficiency anemia, and hypoalbuminemia. One patient presented intermittent crampy abdominal pain and vomiting, and ileo-ileal intussusception was subsequently diagnosed[4]. Samter *et al*[3]

reported one case of peritonitis caused by perforation of colonic IFP.

Considering the diagnostic assessment, peripheral blood eosinophilia was never reported in this series. Although abdominal X-ray may provide some clue of the disease, gastrointestinal endoscopy and EUS was the preferred method for IFP diagnosis in adult population.

Most of the studies in adult population agreed that complete resection is the treatment of choice for IFPs. Nevertheless in this pediatric series all the masses were larger than 3 cm of diameter, and no endoscopic polypectomy was performed (Table 1). Open surgery was performed in all patients, and complete excision of the mass was achieved in all cases (Table 1). The 2 patients with gastric IFP underwent partial gastrectomy. The patients with IFP arising in the small bowel underwent resection and primary anastomosis. The patient with colonic IFP underwent colonic resection and primary colo-colonic anastomosis[7]. The remnant patient underwent resection (7 cm) of the rectum. All but one studies[6] reported data on pathological examination. A variable grade of inflammatory infiltrate was evident in all patients, while eosinophilic infiltrate was present in three (50%). At follow-up all patients are alive and present no symptom recurrence.

DISCUSSION

Demographics and tumor location

IFP was firstly described by Vanek[1] in 1949. Although at least 1000 IFP cases have been reported in literature, only 6 cases have been described in pediatric patients (Table 1)[3-7]. Both sexes appear equally affected. Mean age of presentation was 5 ± 2 years (range 3-8), IFPs were about equally distributed throughout the GI tract: 29% respectively into the stomach, small bowel and colon-rectum and 13% into the duodenum. That differs from adults in whom 70% of cases were found in the stomach[2-8].

Clinical characteristics

IFPs present in a variety of ways depending on their size, location and adjacencies. Polyps in the stomach usually cause pyloric obstruction, while IFPs located on the small bowel cause chronic episodes of colicky abdominal pain, lower gastrointestinal bleeding, anemia and intermittent episodes of intestinal bowel intussusceptions[1-3]. In pediatric population the most frequent symptom was asthenia and anemia related to the mass bleeding, but they are unspecific findings[1-5]. Rupture of colonic IFP has been described in a 4-year-old boy[3]. Physical examination is generally not conclusive (Table 1).

Etiopathogenesis

Etiopathogenesis of IFPs is still largely unknown. An allergic hypothesis has been firstly proposed, on the base on eosinophilic infiltrate[1]. The role of parasite or chronic *H. Pylori* infection has been also reported[8-11]. Although IFPs have been regarded as inflammatory and reactive phenomenon occurring in response to unknown irritants or allergic factors[1], recent data show that the spindle cells express platelet-derived growth factor receptor alpha (PDGFRA), and the majority of IFP harbor activating PDGFRA mutations configuring IFPs as true mesenchymal tumors[12].

Diagnosis

Peripheral blood eosinophilia has been reported in adults[10,11], this finding was also observed in our patient, but it was never described in the other children of the series (Table 1). Ultrasonography (US) and computed tomography scan are usually requested; however, they fail to differentiate IFP from other more common lesions[4]. At GI Tract Endoscopy IFPs are seen as protruding intraluminal masses with a smooth and often ulcerated mucosa. As most IFPs are submucosal lesions, it is almost impossible to obtain a completely diagnostic endoscopic biopsy. EUS is the gold standard for diagnosis of IFPs in adults. The tumour presented as a hypoechogenic and homogeneous mass, located within the second or third sonographic layer of the GI tract wall, with an intact fourth layer. Ours was the first case in which EUS was performed in a child with IFP. However, EUS findings in our patient were wrongly suggestive of leiomyoma rather than IFP, due to the strong adherence of the proliferating mass to the muscular layer. These findings led us to perform FNA in order to confirm clinical suspicion and to rule out a GIST; unfortunately, as reported in the literature, the result of biopsy was non-diagnostic.

Histopathology

The striking features of IFPs are the characteristic arrangement of fibrous and vascular elements ("perivascular onion skinning") associated with marked inflammatory eosinophilic infiltrate[2,8]. IFPs were suggested to show different appearance according to the different part of GI tract from which they arise. Gastric IFPs seem to arise at the base of the lamina propria, extending through and disrupting the muscularis mucosa. Ileal IFPs are intramural proliferations that push against the muscularis mucosae, eventually disrupting it and extending into the mucosa often ulcerating it. They obliterate the submucosa and muscularis propria often invading the mesentery. Gastric IFPs have less stromal edema and therefore they appear more solid in comparison with the ileal ones. Furthermore, gastric IFPs typically have also a prominent perivascular orientation of the different cells and eosinophils infiltration is more prominent than in ileal IFPs[13]. For duodenal IFPs it has been suggested they display the same histological feature of gastric IFPs; they arise in the lower layer of the lamina propria, causing splitting fraying and atrophy of the muscle wall layer[14,15]. That was observed also in our case in which the tumor was composed of stromal looking cells,

embedded in a mixed matrix intermixed with marked inflammatory infiltrates extremely rich in eosinophils granulocytes. Nevertheless, in IFPs the degree of eosinophilic infiltration is variable and of doubtful significance. The different histological patterns and the variable degree of stromal eosinophilic infiltration have been correlated with the evolutive stages of the lesion. Both IFPs of the GI tract and the eosinophilic gastroenteritis have been also considerate as variants of the same disease[10,11]. Immunohistochemical investigations give little help in the diagnosis of IFPs, mainly by excluding mesenchymal and myogenic tumors that should be considered in differential diagnosis[8-10].

Treatment

Complete resection is the treatment of choice for IFPs, in order to relieve symptoms and resolve diagnostic uncertainty. In adults, accessible pedunculated IFPs can be removed by endoscopy (endoscopic submucosal dissection is required), since most of the polyps are smaller than 2 cm[13,16-18]. This is uncommon in children in whom all polyps were larger than 2 cm, making endoscopic polypectomy impracticable, as in our case. As IFPs arise from the submucosa and may be sessile, endoscopic resection may result in perforation or incomplete resection in larger lesions. Surgeons should be aware of the existence of this rare benign entity, which may mimic spindle cell tumours such as GIST, leiomyoma, leiomyosarcoma and schwannoma[2-17]. EUS with fine needle biopsy might improve the accuracy of the preoperative diagnosis of duodenal IFPs, enabling local "*en bloc* resection" and avoiding unnecessary pancreatoduodenectomy[18]. According to the limited pediatric experience, when complete excision of the tumour is achieved, the prognosis is excellent. Unlike adults patients with IFPs, recurrence or metastazisation in children was never reported.

COMMENTS

Background

Inflammatory fibroid polyp (IFP) is an uncommon benign lesion that may occur throughout the gastrointestinal tract, even if stomach is the most affected site. IFP natural history is unknown but rapid growth of the lesion within few months has been reported.

Research frontiers

IFP is found in all age groups but its typical presentation is in the 5th to 7th decade of life; occurrence in children is extremely rare, with only 6 reported cases.

Innovations and breakthroughs

The authors present a new case of IFP occurring in a 3-year-old child who the best of their knowledge is the first reported case of duodenal IFP in childhood. A detailed systematic review of the literature on pediatric IFPi is then provided.

Applications

The study provide a detailed systematic review of the literature on pediatric IFPs, focusing on ethiopatogenesis, clinical presentation, diagnostic assessment and treatment.

Terminology

IFP was firstly described by Vanek in 1949. Etiopathogenesis of IFPs is still largely unknown. An allergic hypothesis has been firstly proposed, on the base on eosinophilic infiltrate. The role of parasite or chronic *H. pylori* infection has been also reported. Now IFP is considered a benign reactive phenomenon similar to granulomata, occurring in response to unknown irritant or allergic factors. Recently mutations in platelet-derived growth factor receptor alpha have been identified in adult patients with IFP.

Peer-review

The manuscript is well written and very interesting.

REFERENCES

1 **Vanek J**. Gastric submucosal granuloma with eosinophilic infiltration. *Am J Pathol* 1949; **25**: 397-411 [PMID: 18127133]

2 **Savargaonkar P**, Morgenstern N, Bhuiya T. Inflammatory fibroid polyp of the ileum causing intussusception: report of two cases with emphasis on cytologic diagnosis. *Diagn Cytopathol* 2003; **28**: 217-221 [PMID: 12672099 DOI: 10.1002/dc.10258]

3 **Samter TG**, Alstott DF, Kurlander GJ. Inflammatory fibroid polyps of the gastrointestinal tract. A report of 3 cases, 2 occurring in children. *Am J Clin Pathol* 1966; **45**: 420-436 [PMID: 5910046]

4 **Persoff MM**, Arterburn JG. Eosinophilic granuloma causing intussusception in a three year old child. *Am J Surg* 1972; **124**: 676-678 [PMID: 5079807 DOI: 10.1016/0002-9610(72)90112-2]

5 **Pollice L**, Bufo P. Inflammatory fibroid polyp of the rectum. *Pathol Res Pract* 1984; **178**: 508-512 [PMID: 6462954 DOI: 10.1016/S0344-0338(84)80012-6]

6 **Schroeder BA**, Wells RG, Sty JR. Inflammatory fibroid polyp of the stomach in a child. *Pediatr Radiol* 1987; **17**: 71-72 [PMID: 3822586 DOI: 10.1007/BF02386601]

7 **Chongsrisawat V**, Yimyeam P, Wisedopas N, Viravaidya D, Poovorawan Y. Unusual manifestations of gastric inflammatory fibroid polyp in a child. *World J Gastroenterol* 2004; **10**: 460-462 [PMID: 14760782]

8 **Moher D**, Liberati A, Tetzlaff J, Altman DG. Preferred reporting items for systematic reviews and meta-analyses: the PRISMA statement. *Int J Surg* 2010; **8**: 336-341 [PMID: 20171303 DOI: 10.1016/j.ijsu.2010.02.007]

9 **Cooper HM**, Hedges LV, Valentine JC, editors. The handbook of research synthesis and meta-analysis. 2nd ed. New York, NY, Russell Sage, 2009

10 **Trillo AA**, Rowden G. The histogenesis of inflammatory fibroid polyps of the gastrointestinal tract. *Histopathology* 1991; **19**: 431-436 [PMID: 1757082 DOI: 10.1111/j.1365-2559.1991.tb00233.x]

11 **Wille P**, Borchard F. Fibroid polyps of intestinal tract are inflammatory-reactive proliferations of CD34-positive perivascular cells. *Histopathology* 1998; **32**: 498-502 [PMID: 9675587 DOI: 10.1046/j.1365-2559.1998.00433.x]

12 **Schildhaus HU**, Cavlar T, Binot E, Büttner R, Wardelmann E, Merkelbach-Bruse S. Inflammatory fibroid polyps harbour mutations in the platelet-derived growth factor receptor alpha (PDGFRA) gene. *J Pathol* 2008; **216**: 176-182 [PMID: 18686281 DOI: 10.1002/path.2393]

13 **Rossi P**, Montuori M, Balassone V, Ricciardi E, Anemona L, Manzelli A, Petrella G. Inflammatory fibroid polyp. A case report and review of the literature. *Ann Ital Chir* 2012; **83**: 347-351 [PMID: 22759473]

14 **Kolodziejczyk P**, Yao T, Tsuneyoshi M. Inflammatory fibroid polyp of the stomach. A special reference to an immunohistochemical profile of 42 cases. *Am J Surg Pathol* 1993; **17**: 1159-1168 [PMID: 8214261 DOI: 10.1097/00000478-199311000-00009]

15 **Benjamin SP**, Hawk WA, Turnbull RB. Fibrous inflammatory polyps of the ileum and cecum: review of five cases with emphasis on differentiation from mesenchymal neoplasm. *Cancer* 1977; **39**: 1300-1305 [PMID: 912661 DOI: 10.1002/1097-0142(197703)39:3

<1300::AID-CNCR2820390342>3.0.CO;2-4]

16 **Liu TC**, Lin MT, Montgomery EA, Singhi AD. Inflammatory fibroid polyps of the gastrointestinal tract: spectrum of clinical, morphologic, and immunohistochemistry features. *Am J Surg Pathol* 2013; **37**: 586-592 [PMID: 23426127]

17 **Abboud B**. Vanek's tumor of the small bowel in adults. *World J Gastroenterol* 2015; **21**: 4802-4808 [PMID: 25944993]

18 **Wysocki AP**, Taylor G, Windsor JA. Inflammatory fibroid polyps of the duodenum: a review of the literature. *Dig Surg* 2007; **24**: 162-168 [PMID: 17476106]

P- Reviewer: Dehghani SM, Romano C, Watanabe T
S- Editor: Qiu S **L- Editor**: A **E- Editor**: Jiao XK

Published by **Baishideng Publishing Group Inc**
8226 Regency Drive, Pleasanton, CA 94588, USA
Telephone: +1-925-223-8242
Fax: +1-925-223-8243
E-mail: bpgoffice@wjgnet.com
Help Desk: http://www.wjgnet.com/esps/helpdesk.aspx
http://www.wjgnet.com

© 2015 Baishideng Publishing Group Inc. All rights reserved.